

1 **The Popliteus Tendon Provides a Safe and Reliable Location for**  
2 **Anchor Placement: Outcome of 200 Posterior Horn Lateral Meniscal**  
3 **Repairs Performed at the Time of ACL Reconstruction**  
4  
5

6 **ABSTRACT**

7

8 **Background:** Tears of the posterior horn of the lateral meniscus are challenging to  
9 repair because, in contrast to medial meniscal repairs, the capsule and its attachment  
10 are thin.

11 **Purpose:** To evaluate the clinical results of an arthroscopic all-inside repair technique  
12 for unstable, vertical, lateral meniscus tears, using a suture anchor device placed  
13 directly into the popliteus tendon.

14 **Study Design:** Case Series; Level of evidence, 4.

15 **Methods:** A retrospective analysis of prospectively collected data from the \*\*\*\*\*  
16 database was performed. All patients who had undergone combined ACL  
17 reconstruction with lateral meniscus all-inside repair, using sutures placed in the  
18 popliteus tendon, between January 2011 and February 2015, were included. At final  
19 follow-up, all patients were contacted by telephone to identify if they underwent  
20 further surgery or had pain, locking or effusion. Symptomatic patients were recalled  
21 for clinical/imaging evaluation. Operative notes for those undergoing further surgery  
22 were reviewed and rates and type of re-operation, including for failed lateral meniscal  
23 repair were recorded.

24 **Results:** Two hundred patients (mean age,  $28.6 \pm 10.2$  years) with a mean follow-up  
25 of  $45.5 \pm 12.8$  months (range, 24.7-75.2) were included. The mean Subjective  
26 International Knee Documentation Committee (IKDC) at final follow-up was  $85.0 \pm$   
27  $11.3$ . The post-operative mean side-to-side laxity measured at one year was  $0.6 \pm 1.0$   
28 mm. Twenty-six patients underwent re-operation (13%) at a mean follow-up of  $14.8 \pm$   
29  $7.8$  months. The ACL graft rupture rate was 5.0%. Other causes for re-operation  
30 included medial meniscus tear (2.5%), cyclops lesion (1.5%) and septic arthritis

31 (0.5%). The lateral meniscus repair failure rate was 3.5%. No specific complications  
32 relating to placement of suture anchors in the popliteus tendon were identified.

33 **Conclusion:** Arthroscopic all-inside repair of unstable, vertical, lateral meniscal tears  
34 using a suture anchor placed in the popliteus tendon is a safe, efficient and  
35 reproducible technique. It is associated with a very low failure rate without specific  
36 complications.

37

38

39 **Key-Words:** ACL rupture, lateral meniscus tears, all-inside repair, meniscal repair,  
40 popliteus tendon

41

42 **What is known about the subject:** Tears of the posterior horn of the lateral meniscus  
43 can be challenging to repair. In contrast to medial meniscal repairs, the capsule and its  
44 attachment are thin. Using popliteus as a location for anchor placement is an option  
45 for improving the biomechanics of the repair but there is concern that anchor  
46 placement in popliteus may cause iatrogenic injury or irritation to this structure or  
47 result in premature suture failure. However, to the authors knowledge, there is no  
48 clinical data to support this. In contrast, there is laboratory evidence to demonstrate  
49 that loosening does not occur in sutures placed in popliteus after 1000 loading cycles  
50 and there are some small case series reporting that the technique is safe

51

52

53 **What this study adds to existing knowledge:** This study is the first large series to  
54 comprehensively report outcomes in a large series of patients undergoing repair of  
55 unstable, vertical, lateral meniscal tears with a suture placed in popliteus at the time of

56 ACL reconstruction. The excellent clinical results and lack of complications serves to  
57 dispel the myth that popliteus should not be used as a location for anchor placement  
58 and gives surgeons the confidence to add this useful, safe and reliable technique to  
59 their armamentarium for dealing with these repairs.

60

61

62 **Introduction**

63

64 The association of concurrent meniscal tears with anterior cruciate ligament (ACL)  
65 rupture represents a common and severe injury pattern that typically occurs in young,  
66 active individuals.<sup>6,9,22,23,35</sup> Approximately 65% of ACL injured knees are reported to  
67 occur in combination with a meniscal injury but not all of these require treatment.<sup>40</sup> In  
68 particular, stable posterior horn tears of the lateral meniscus left in-situ at the time of  
69 ACL reconstruction are reported to demonstrate satisfactory healing with functional  
70 restoration.<sup>16</sup> In contrast, unstable tears have important biomechanical consequences  
71 and warrant treatment.<sup>1,25,33</sup> This can include repair or meniscectomy, but it is clear  
72 that the latter should be avoided when possible. This is because meniscectomy is  
73 associated with abnormal joint kinematics, significant increases in articular cartilage  
74 peak contact pressures, elevated shear stresses, a predisposition to early degenerative  
75 change and even rapid chondrolysis.<sup>5,12,20,26,29</sup> Consequently, meniscal repair is widely  
76 considered to be the treatment of choice for these lesions.<sup>40</sup> When a repair is  
77 performed at the same time as ACL reconstruction, good long-term repair  
78 survivorship is reported with only a 14% failure rate for both medial and lateral  
79 repairs at 6-years follow-up.<sup>40</sup>

80

81 The all-inside repair technique is the most frequently used in current clinical  
82 practice.<sup>40</sup> Uchida, *et al.* demonstrated that good fixation can be reliably achieved  
83 with an all-inside technique in medial meniscal repair because most anchors placed  
84 were found to be located securely on the capsule.<sup>38</sup> In contrast, on the lateral side,  
85 only anchors fixed in the area posterior to the popliteus tendon, in the posterior part of  
86 the popliteal hiatus, reliably provided secure fixation on the capsule. More  
87 posteriorly, all anchors were located intra-capsularly. This was attributed to the fact  
88 that the capsule is not as tightly opposed to the lateral meniscal body as it is to the  
89 medial meniscus.<sup>38</sup> Furthermore, the capsule around the posterior root attachment of  
90 the lateral meniscus is quite thin.<sup>38</sup> Although the authors also secured anchors within  
91 the popliteus tendon, they advised against this because of theoretical concerns  
92 regarding iatrogenic injury or irritation to this structure and suture loosening during  
93 knee movement.

94

95 The purpose of this study was to evaluate the clinical results of arthroscopic all-inside  
96 repair of unstable vertical lateral meniscus tears, using a suture anchor device placed  
97 in the popliteus tendon. It was hypothesized that this technique would be  
98 reproducible, safe and associated with a low re-operation rate for failure of repair.

99

100

101

102 **Methods**

103 This study received institutional review board approval and was performed in  
104 accordance with the Declaration of Helsinki ethical standards.

105

106 Between January 2011 and February 2015, the senior surgeon (\*\*\*) performed 1835  
107 anterior cruciate ligament reconstruction (ACLR) procedures. All patients had  
108 sustained a knee injury with a diagnosis of ACL rupture based on clinical examination  
109 and magnetic resonance imaging (MRI). A retrospective analysis of prospectively  
110 collected data from the \*\*\*\*\* database was performed. All patients who had  
111 undergone combined ACLR and all-inside repair of the lateral meniscus using sutures  
112 placed in the popliteus tendon were identified. Failure was defined as the need for  
113 revision repair or meniscectomy for the lateral meniscus. The following groups of  
114 patients were excluded from the study: multi-ligament injuries, revision ACLR, other  
115 major concomitant procedures (e.g. high tibial osteotomy), discoid lateral meniscus,  
116 complex lesions of the lateral meniscus (posterior root avulsion, radial tear or bucket  
117 handle) and paediatric cases.

118

119 The indication for all-inside repair of the lateral meniscus using sutures placed in the  
120 popliteus tendon was anterior displacement of the posterior meniscal segment under  
121 the central part of the femoral condyle on probing. This is indicative of an unstable  
122 tear, and synonymous with pathological hypermobility that could result in pain and  
123 locking.

124

125

126  
127  
128  
129  
130

131 *Surgical technique:*

132 Patients were positioned supine in the standard arthroscopy position. A lateral post  
133 was placed just proximal to the knee, at the level of the padded tourniquet, and a foot  
134 roll was used to prevent the hip from externally rotating and to maintain 90° of knee  
135 flexion. In this way, the knee could be moved freely through the full range of motion.

136

137 The anterolateral portal was created adjacent to the lateral edge of the patellar tendon  
138 and the inferior border of the patella. The anteromedial portal was positioned just  
139 below the inferior border of the patella and approximately 4 mm medial to the medial  
140 border of the patellar tendon. A full diagnostic arthroscopy was performed and  
141 meniscal and cartilage procedures were undertaken prior to ACL reconstruction.

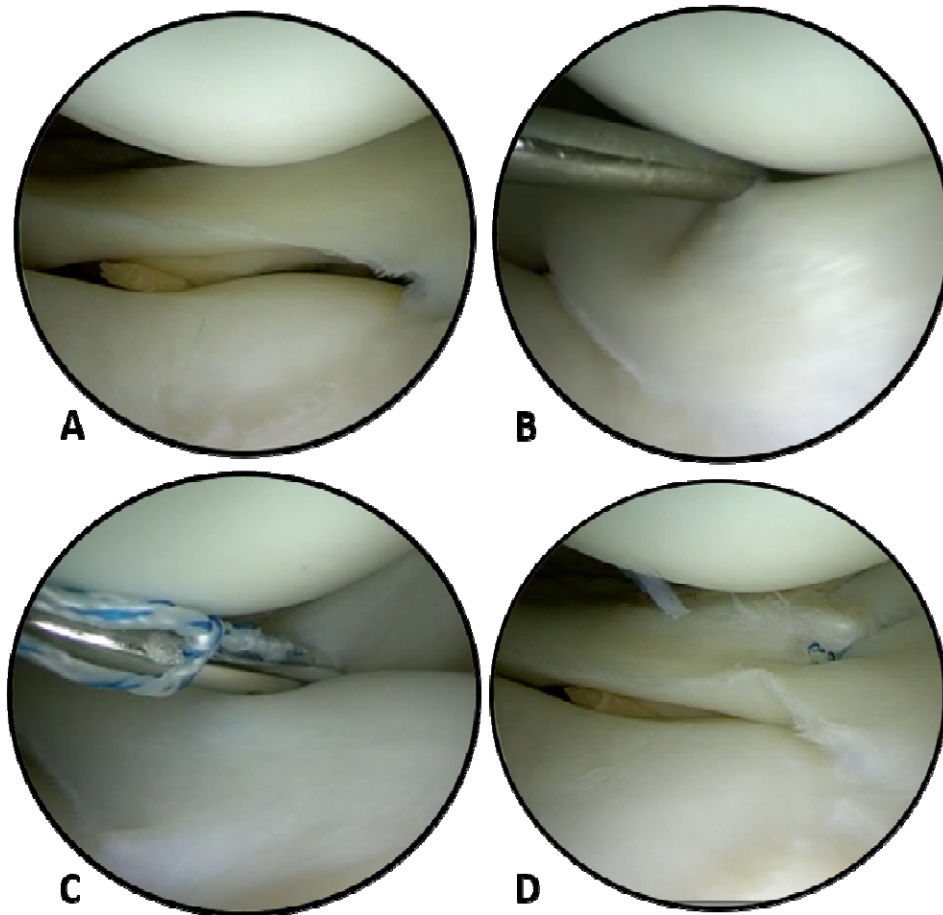
142

143 For assessment of the lateral compartment, the knee was placed in the “figure of four”  
144 position and the lateral meniscus was probed. When an unstable tear of the posterior  
145 horn of the lateral meniscus was identified, a simple all-inside meniscal repair device  
146 (Ultra Fast-Fix®, Smith & Nephew, Andover, USA) was introduced through the  
147 anteromedial portal, and a suture was placed in the popliteus tendon after debridement  
148 of the tear (Figure 1).

149

150





151  
152

153 FIGURE 1: Arthroscopic view of lateral compartment of a left knee via anterolateral  
154 portal.

155 A: Posterior horn, vertical, lateral meniscal tear. B: Probing reveals tear is unstable.  
156 C: Placement of meniscal suture device into popliteus tendon. D: Final appearance of  
157 repair

158

159 For medial meniscus tears, an all-inside or outside-in technique was used for ruptures  
160 in the body and posterior horn of the meniscus. A systematic arthroscopic exploration  
161 of the posteromedial portion of the meniscus was performed to identify any additional  
162 lesions. These were treated using an all-inside technique through a posteromedial  
163 portal, as previously described.<sup>2,21</sup> Finally, ACLR was performed using either bone-  
164 patella tendon-bone or hamstring tendon autograft. Some patients also underwent a  
165 lateral extra-articular tenodesis.<sup>30,31</sup>

166

### 167 *Rehabilitation*

168 Postoperatively, the active and passive range of motion was limited from 0° to 90° in  
169 the first 4 weeks, with immediate full weight-bearing. Jogging was permitted after 3

170 months, pivoting activities at 6 months, and full activity at 9 months.

171

## 172 *Outcomes*

173 Examinations were conducted pre-operatively and at the following post-operative  
174 intervals: 3 and 6 weeks and at 3, 6, and 12 months. Patient demographics such as  
175 gender, age and BMI were recorded as well as Lachman's test. At 6 months post-  
176 operatively, all patients underwent isokinetic testing prior to returning to sport. When  
177 the isokinetic test showed a deficit greater than 20% in the eccentric or concentric  
178 hamstring strength or any quadriceps deficit, return to sport was deferred and repeat  
179 testing was performed 2 months later. Side-to-side laxity was evaluated at 12 months  
180 follow-up for all patients using the Rolimeter Arthrometer® (Aircast, Europe).

181

182 At the end of the study period all patients underwent a telephone interview, performed  
183 by a physician who was not the primary surgeon (XX). This comprised the following  
184 standardized questions:

185

- 186 - Subjective IKDC questionnaire.
- 187 - Did you return to sport? If yes, which sport and at what level?
- 188 - Did you have a second operation / revision after your ACLR?
- 189 - Did you have a contralateral ACL rupture or contralateral ACLR after the  
190 index procedure?
- 191 - Do you have any swelling? Do you have any locking sensation? Do you have  
192 any pain?

193 Operative records were reviewed for all patients who underwent further surgery. If  
194 patients reported knee pain, effusion, or symptoms of locking they were recalled for  
195 clinical review and imaging if indicated.

196

## 197 **Statistical Analysis**

198 Therapeutic variables (surgery, adjuvant therapy, and function) and demographic  
199 variables (sex, age, and follow-up) were examined. Descriptive data (mean, median,  
200 range, proportions) are reported for the entire patient cohort. Differences between  
201 means were tested with the t-test for continuous variables; or with the Mann-Whitney  
202 test when data were not normally distributed. Categorical variables were tested with  
203 the Chi<sup>2</sup> test or the Fischer exact test. A probability value of  $p \leq 05$  was considered

204 statistically significant. A Kaplan-Meier survivorship analysis of LM repair using re-  
205 operation as an endpoint was performed using GraphPad software (Version Prism 7,  
206 GraphPad Software Inc., California, USA). All other calculations were made using  
207 SPSS software (Version 20.0, SPSS Inc., Chicago, IL).

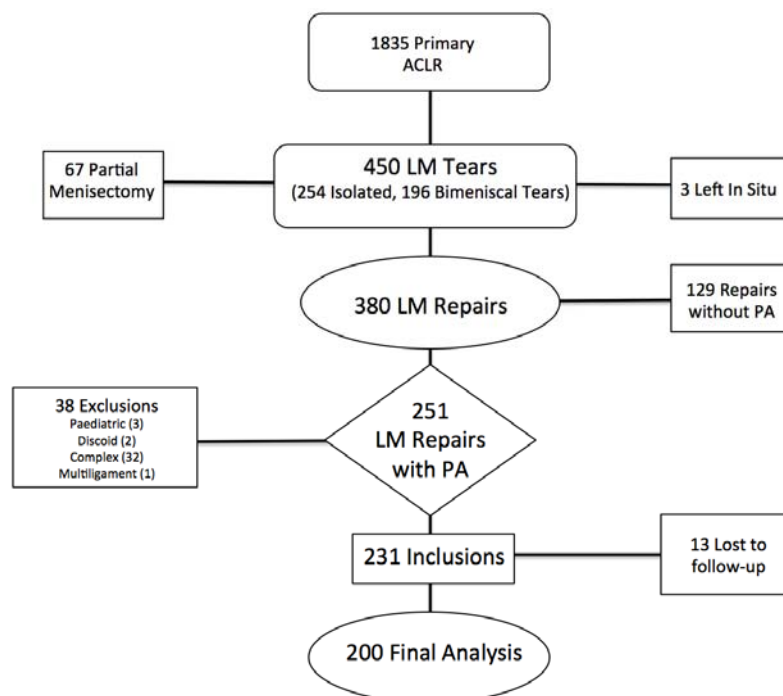
208

## 209 **Results**

210

211 The overall study population comprised 1835 primary ACLRs. Figure 2 illustrates the  
212 flow of patients. Lateral meniscal tears were identified in 450 patients, of which 380  
213 (84.4%) underwent repair. Of the lateral meniscal repairs, 251 had all-inside repairs  
214 using sutures placed in the popliteus tendon. After application of the exclusion  
215 criteria, 213 repairs were included in the study. Thirteen patients (6.1%) were lost to  
216 follow up despite attempts to contact them by telephone, mail and via their general  
217 practitioner. The final study population therefore comprised 200 patients who had  
218 undergone primary ACLR and a lateral meniscus repair using a suture anchor in the  
219 popliteus tendon.

220



221

222 **FIGURE 2.** Flowchart illustrating the flow of patients through the study; ACLR  
223 (Anterior Cruciate Ligament Reconstruction), LM (Lateral Meniscus), PA (anchor  
224 placed in popliteus tendon).

225

226

227

228 *Demographic data*

229 Demographic data including age, gender distribution, BMI, time between injury and  
230 surgery and duration of follow up are reported in Table 1. Details of the surgical  
231 procedures including ACL graft type, and the management/type of meniscal  
232 pathology is reported in Table 2.

233 TABLE 1: Patient Demographics

234

	All Patients (N=200)
Follow-up, mean $\pm$ SD (range), months	45.5 $\pm$ 12.8 (24.7-75.3)
Male sex, n (%)	139 (69.5)
Age, mean $\pm$ SD (Range), years	28.6 $\pm$ 10.2 (14-60)
Time from injury to surgery, mean $\pm$ SD (Range), months	16.8 $\pm$ 50.4 (0.1-364.1)
Weight (kg)	75 $\pm$ 14.6 (47-125)
Height (cm)	175.3 $\pm$ 9 (150-200)
BMI (kg/m <sup>2</sup> )	24.3 $\pm$ 3.6 (15.3-36)

235

236

237 *Clinical results*

238 The pre operative antero posterior side to side laxity was 7.4 mm  $\pm$  1.5 (4-12). At 12  
239 months follow-up, the mean residual side to side laxity was 0.6 mm  $\pm$  1 (-3 to 3). At a  
240 mean final follow-up of 45.5  $\pm$  12.8 months (range, 24.7-75.2), the mean subjective  
241 IKDC score was 85.0  $\pm$  11.3 (37.9 to 100). 180 patients returned to sports activity  
242 with 97 returning to competition.

243

244

245

246

247

248

249

250

251

252 TABLE 2: Summary of surgical procedures performed  
 253  
 254 BPTB: Bone-Patellar Tendon-Bone  
 255 4HT: Hamstring Tendon (Semitendinosus + gracilis)  
 256 ST: Semitendinosus  
 257 EAT: Extra Articular Tenodesis  
 258 LM (Lateral Meniscus), MM (Medial Meniscus)  
 259  
 260  
 261

ACL		
Graft Type	N	Lateral Tenodesis N
BPTB	21	3
Classic 4HT	72	6
Single ST	27	2
HT + EAT	80	80
<b>TOTAL</b>	<b>200</b>	<b>91</b>
MENISCAL TEARS		
Type	N	%
Isolated Vertical Unstable LM Tear	116	58
Vertical Unstable LM Tear + MM Tear (67 MM Repairs + 17 Medial Meniscectomies)	84	42
LM Tear sutured with 1 Fast fix	111	55
LM tear sutured with more than 1 fast fix	89	45

262  
 263 *Re-operation*  
 264 Twenty-six patients (13%) underwent ipsilateral re-operation at a mean follow up of  
 265  $14.8 \pm 7.8$  (5.9-43.5) months. Failure of lateral meniscal repair occurred in 7 knees  
 266 (3.5%) at a median follow-up of  $24.2 \pm 15.3$  (8.7-43.5) months. ACL graft failure  
 267 leading to revision surgery occurred in 10 knees at a median of  $16.7 \pm 7.1$  (8.4-26)  
 268 months after the index procedure. There were 9 ipsilateral re-operations for  
 269 indications other than graft rupture and lateral meniscal repair failure (medial  
 270 meniscus n=5, cyclops syndrome n=3, arthroscopic lavage with infection n=1). With  
 271 respect to the contralateral knee, 14 patients (7%) had a contralateral ACL rupture  
 272 after the index procedure (Table 3).

273 TABLE 3: Complications  
 274  
 275

	<b>N (%)</b>	<b>Time to Revision (Months)</b>	<b>Procedure</b>
LM Suture Failure	7 (3.5%)	24.2 ± 15.3 (8.7-43.5)	LM Re-suture (N=4) or LM Meniscectomy (N=3)
MM tear	5 (2.5%)	9.8 ± 3.9 (6.3-16)	MM Meniscectomy
ACL Re-rupture	10 (5%)	16.7 ± 7.1 (8.4-26)	ACL Revision
Cyclops	3 (1.5%)	6.1 ± 0.3 (5.9-6.5)	Arthroscopic Arthrolysis
Septic Arthritis	1 (0.5%)	11.74	Lavage + ATB
Complex Regional Pain Syndrome	1 (0.5%)	No Revision	Medical Treatment
Contralateral ACLR	14 (7%)	No Revision	ACL Reconstruction
<i>Total Number of Re-operations</i>	26 (13%)	14.8 ± 7.8 (5.9-43.5)	

276  
 277  
 278 LM (lateral meniscus), MM (medial meniscus), ACL (anterior cruciate ligament  
 279 reconstruction)  
 280  
 281 The re-operation rate for failure of LM repair (3.5%) was lower than the failure rate  
 282 of MM repair (7.5%), but this difference was not significant (p = 0.18, Fischer exact  
 283 test). Patients who underwent both medial and lateral meniscal repairs at the index  
 284 procedure were significantly more likely to undergo re-operation for failure of LM  
 285 repair (p= 0.0021, Fischer exact test). Furthermore, the overall reoperation rate (for  
 286 any indication) in patients who underwent both medial and lateral repairs (22.4%) was  
 287 greater than in patients who underwent isolated LM repair (9%) and this difference  
 288 was significant (p= 0.005 Chi<sup>2</sup>).  
 289

290 The re-operation rate for failure of LM repair in patients who underwent lateral  
291 tenodesis (2.2%) was lower than in patients without lateral tenodesis (4.6%) but this  
292 was not significant ( $p= 0.5$ , Fischer exact test). Patients whose LM tear was repaired  
293 with more than one Fast-Fix placed in popliteus had a failure rate of 5.6% versus  
294 1.8% in patients whose repair was performed with only one Fast-Fix device. This  
295 difference was not significant ( $p=0.1$  Fischer exact test).

296

#### 297 *Knee pain at final follow-up*

298 This criterion was evaluated after excluding the patients who underwent re-operation.  
299 Of 174 patients, twenty-nine reported discomfort, or some pain in the knee, with a  
300 mean visual analogue scale of 3.6 out of 10. Only, 3 patients reported pain on the  
301 lateral side of the knee. In those 3 patients, the clinical assessment revealed specific  
302 pain localised proximal to the femoral lateral epicondyle. There was no tenderness on  
303 joint line palpation and no indication for further imaging. All 3 patients received an  
304 extra-articular corticosteroid injection and remain pain free at final follow-up. No  
305 patients reported posterior pain in the region of the popliteus anchors.

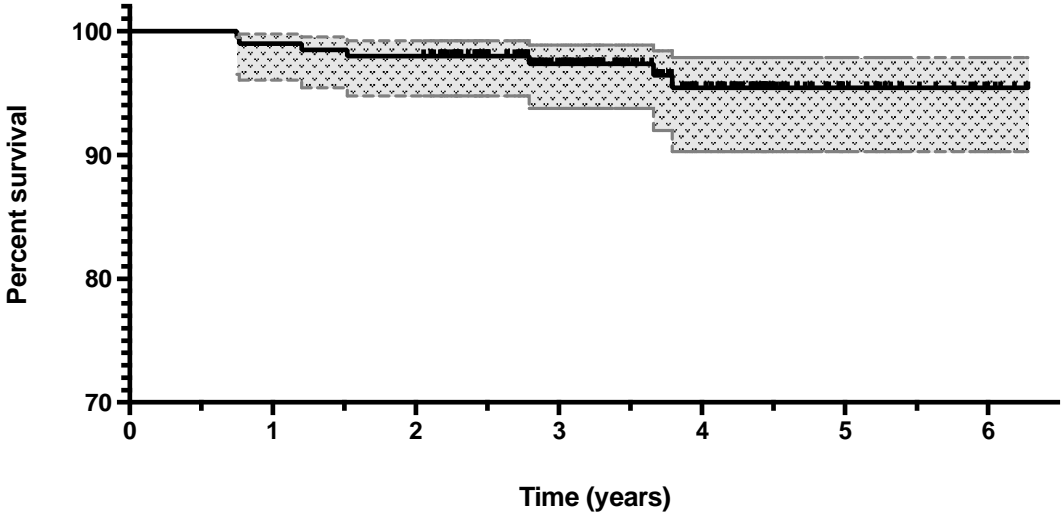
306

#### 307 *Specific complications of sutures placed in the popliteus tendon*

308 No complications were directly related to anchors placed in the popliteus tendon.  
309 Specifically, no patients had surgery to remove a symptomatic device placed within  
310 the popliteus tendon. 7 patients (3.5%) required re-operation for failed lateral  
311 meniscus repair. Intra-operative findings comprised horizontal tears of the posterior  
312 horn ( $n=3$ ) or the body ( $n=2$ ), flap tear of the posterior horn ( $n=1$ ) and recurrent  
313 vertical unstable lesion ( $n=1$ ). At surgery, a revision repair was performed in 3  
314 patients and a partial meniscectomy was performed in the remaining 4 patients.  
315 Among the other 19 re-operations, 10 patients sustained a new knee injury that  
316 resulted in graft failure and revision ACLR. A recurrent traumatic lesion of the lateral  
317 meniscus was found in 8 patients leading to either repair ( $n=6$ ) or meniscectomy  
318 ( $n=2$ ). In other re-operations, the lateral meniscus repair was found to be completely  
319 healed with the hiatus recreated, as previously reported by other authors.<sup>39</sup> There were  
320 no cases of popliteus tendon tear, or neurological injury.

321

322 Figure 3 shows the cumulative survivorship of lateral meniscal repairs derived from  
323 Kaplan-Meier analysis when using re-operation for lateral meniscal pathology as an  
324 endpoint.  
325



326  
327  
328 FIGURE 3: Kaplan-Meier plot showing survivorship of lateral meniscal repairs  
329 (performed with a suture placed into the popliteus tendon) when using re-operation  
330 for lateral meniscal pathology as an endpoint.  
331  
332  
333  
334



335 **Discussion**

336 The most important finding of this study is that all-inside repair of peripheral,  
337 vertically unstable, lateral meniscal tears using suture anchors placed in the popliteus  
338 tendon is safe, reproducible and associated with excellent clinical outcomes. A low  
339 failure rate of meniscal repair (3.5%) at a mean follow up of 45 months (range 24.7-  
340 75.3), without any specific complications was observed. To the author's knowledge,  
341 this is the first clinical study of a large series of lateral meniscal repairs performed  
342 with suture anchors placed in the popliteus tendon.

343

344 Previous authors have drawn attention to the concern that anchors placed in popliteus  
345 may become loose or cause pain and irritation with knee motion.<sup>17,38,42</sup> However, a  
346 literature search performed for the current study did not reveal any clinical studies to  
347 support this concept. These results are consistent with the outcomes of the current  
348 study in which no cases of pain or irritation due to implant breakage, articular  
349 migration, foreign-body reaction, cyst formation or popliteus irritation were  
350 encountered.

351

352 The dynamic and static roles of the intra-articular portion of the popliteus tendon are  
353 still debated. LaPrade *et al.* demonstrated that the popliteus tendon has important  
354 dynamic and static stabilizing functions and named it "the fifth ligament of the  
355 knee".<sup>15</sup> In contrast, other authors have reported that the popliteus muscle-tendon unit  
356 has extensive fibular, capsular-meniscal and tibial attachments.<sup>24,36,37</sup> As such it is  
357 considered that the intra-articular portion of the popliteus tendon is very stable and  
358 relatively immobile in the segment from the popliteus fossa to the arcuate ligament.  
359 This is supported by additional studies which demonstrate minimal motion of the  
360 intra-articular portion of popliteus during knee motion.<sup>13,32</sup> Furthermore, Lopez *et al.*  
361 demonstrated in a cadaveric, biomechanical study that sutures placed in the popliteus  
362 tendon did not show any macroscopic sign of failure or gapping of the repair after  
363 1000 gait cycles. It was concluded that closure of the popliteal gap during a lateral  
364 meniscus repair probably has minimal repercussions on the kinematics of the  
365 posterolateral knee angle and in some cases, may imply a greater repair strength.<sup>19</sup>

366

367 The role of the popliteus tendon may be further delineated if we look closely at its  
368 phylogeny. Interestingly, the fibula in protomammals receded distally from its

369 position at the femorotibial joint line, to the position where it currently exists in  
370 modern mammals. With fibular recession, the popliteus muscle attachment that  
371 previously was connected directly to the proximal fibula, became attached to the  
372 lateral femoral condyle through a tendinous transformation of the primitive  
373 femorofibular meniscus that was present in earlier tetrapod species.<sup>8</sup> This concept was  
374 previously described by Kaplan.<sup>13</sup> Given that the popliteus tendon is derived from a  
375 relatively static primitive meniscus structure may explain why it is a suitable  
376 anchoring point for an unstable lateral meniscus. The authors believe that the  
377 popliteus tendon used in this way acts as a temporary brace for the lateral meniscus  
378 during healing.<sup>4</sup>

379

380 The concept of using the popliteus tendon for anchor fixation has previously been  
381 described in the literature.<sup>4,19,28,39</sup> Verdonk *et al.* reported using this strategy when  
382 performing lateral meniscus allograft transplantation. They described that in second-  
383 look arthroscopies, the popliteal hiatus had recreated itself naturally.<sup>39</sup> Shelbourne *et*  
384 *al.* reported a low failure rate using the popliteus tendon as a location for anchor  
385 placement when repairing unstable lateral meniscal tears combined with ACL  
386 reconstruction (2% failure rate on unpublished data from 2011).<sup>28</sup> Similarly, Ahn *et*  
387 *al.* reported satisfactory clinical results in a series of 24 arthroscopic lateral meniscal  
388 repairs at 41 months follow-up.<sup>3</sup> In their technique, they describe an all-inside repair  
389 for posterior horn lesions and note that “when the posterolateral capsule was weak,  
390 the suture was applied between the meniscus of the posterior horn and capsule,  
391 including the popliteus tendon.” They had no re-operations and concluded that their  
392 technique was safe.

393

394 Lateral meniscal tears in the region of the popliteus tendon have been regarded as a  
395 difficult area to repair.<sup>34</sup> Horibe *et al.* noted low healing rates (19 of 30, 63%) on  
396 second look arthroscopy with meniscal tears in the region of the popliteus tendon, in a  
397 series of 278 meniscal repairs using an inside-out technique.<sup>11</sup> They suggested it may  
398 be due to the absence of a synovial fringe seen on microangiographic studies of this  
399 region.<sup>11</sup> However, it is also recognised that tears near the popliteal hiatus are  
400 challenging because the lateral meniscus has a weak attachment posteriorly. This is  
401 not ideal for secure anchor fixation. Uchida *et al.* demonstrated that in this region  
402 there is a high rate of failure to capture the capsule with an all-inside device.<sup>87</sup> This

403 appears consistent with the study of Kashihara *et al.* who reported that all-inside  
404 lateral meniscal repairs are associated with significant increases in post-operative  
405 radial meniscal extrusion.<sup>14</sup> They suggested that the reasons for this are multifactorial,  
406 but included that it was because the suture device moves the meniscus to where it is  
407 captured on the peripheral joint capsule.<sup>14</sup> This is an important consideration because  
408 meniscal extrusion increases joint contact pressures and predisposes to early  
409 degenerative change.<sup>7</sup> It therefore seems logical to try and improve the stiffness of  
410 meniscal repair in tears around the popliteal hiatus.

411

412 The current study demonstrates that placing sutures in the popliteus tendon is safe and  
413 associated with good results. Further study is required to determine whether it has any  
414 influence on meniscal extrusion or joint contact pressures when compared to other  
415 techniques. The main finding from this study is that the previously widespread belief  
416 that suture placement in the popliteal tendon should be avoided is not supported by  
417 clinical results from a large series. However, there was a non-significant trend  
418 towards an increased failure rate of LM repair when two anchors were placed in  
419 popliteus rather than one. The indication for the placement of two anchors was not  
420 precisely defined and was based on surgeon preference. Interpretation of this finding  
421 is therefore somewhat limited. It is postulated that placement of two anchors may  
422 overconstrain the meniscus thus predisposing to failure of the repair. However, this  
423 requires further study. Despite this trend towards increased failure, even in the two  
424 anchor group, the re-operation rate for LM repair failure was low at 5.6%, at a mean  
425 follow up of over 45 months.

426

427 This study has some limitations. Firstly, it involved a retrospective review of  
428 prospectively collected information, without a control group, and relied on a  
429 telephone-based questionnaire for initial assessment of patients, rather than clinical  
430 examination. However, recalling young geographically mobile, asymptomatic patients  
431 is difficult and previous authors have used telephone questionnaires in similar  
432 populations.<sup>10</sup> We did not perform routine second-look arthroscopy or MRI imaging  
433 in asymptomatic patients and so the true failure rate is likely to have been higher than  
434 the rate that was clinically apparent. Furthermore, the minimum length of follow-up  
435 was relatively short (24.7 months) particularly as it is recognized that the risk of  
436 symptomatic meniscal lesions developing after ligament reconstruction is highest

437 within the first 4 years after the index procedure.<sup>18,27</sup> Despite these limitations, the  
438 strength of this study is the large number of consecutive patients that underwent repair  
439 of vertical, unstable, posterior horn lateral meniscus tears using the same technique.

440

441 **Conclusion:**

442 Arthroscopic all-inside repair of unstable, vertical lateral meniscus tears using a  
443 suture anchor device placed in the popliteus tendon is a safe technique. It is associated  
444 with a very low failure rate without specific complications. A longer follow-up study  
445 is necessary to confirm these promising mid-term clinical results.

446 **References:**

447

- 448 1. Ahn JH, Bae TS, Kang KS, Kang SY, Lee SH. Longitudinal tear of the  
449 medial meniscus posterior horn in the anterior cruciate ligament-deficient  
450 knee significantly influences anterior stability. *Am J Sports Med.*  
451 2011;39(10):2187-2193.
- 452 2. Ahn JH, Kim SH, Yoo JC, Wang JH. All-inside suture technique using two  
453 posteromedial portals in a medial meniscus posterior horn tear. *Arthroscopy.*  
454 2004;20(1):101-108.
- 455 3. Ahn JH, Yoo JC, Lee SH. Posterior horn tears: all-inside suture repair. *Clin*  
456 *Sports Med.* 2012;31(1):113-134.
- 457 4. Beaufils P, Verdonk R. The Meniscus. *Springer, Paris.* 2010
- 458 5. Charrois O, Ayrat X, Beaufils P. [Rapid chondrolysis after arthroscopic  
459 external meniscectomy. Apropos of 4 cases]. *Rev Chir Orthop Reparatrice*  
460 *Appar Mot.* 1998;84(1):88-92.
- 461 6. Church S, Keating JF. Reconstruction of the anterior cruciate ligament:  
462 timing of surgery and the incidence of meniscal tears and degenerative  
463 change. *J Bone Joint Surg Br.* 2005;87(12):1639-1642.
- 464 7. Crema MD, Roemer FW, Felson DT, Englund M, Wang K, Jarraya M, Nevitt  
465 MC, Marra MD, Torner JC, Lewis CE, Guermazi A. Factors associated with  
466 meniscal extrusion in knees with or at risk for osteoarthritis: the Multicenter  
467 Osteoarthritis study. *Radiology.* 2012;264(2):494-503.
- 468 8. Dye SF. Functional morphologic features of the human knee: an evolutionary  
469 perspective. *Clin Orthop Relat Res.* 2003;(410):19-24.

- 470 9. Granan LP, Bahr R, Lie SA, Engebretsen L. Timing of anterior cruciate  
471 ligament reconstructive surgery and risk of cartilage lesions and meniscal  
472 tears: a cohort study based on the Norwegian National Knee Ligament  
473 Registry. *Am J Sports Med.* 2009;37(5):955-961.
- 474 10. Hettrich CM, Dunn WR, Reinke EK; MOON Group, Spindler KP. The rate of  
475 subsequent surgery and predictors after anterior cruciate ligament  
476 reconstruction: two- and 6-year follow-up results from a multicenter cohort.  
477 *Am J Sports Med.* 2013;41(7):1534-1540.
- 478 11. Horibe S, Shino K, Nakata K, Maeda A, Nakamura N, Matsumoto N.  
479 Second-look arthroscopy after meniscal repair. Review of 132 menisci  
480 repaired by an arthroscopic inside-out technique. *J Bone Joint Surg Br.*  
481 1995;77(2):245-249.
- 482 12. Ishida K, Kuroda R, Sakai H, Doita M, Kurosaka M, Yoshiya S. Rapid  
483 chondrolysis after arthroscopic partial lateral meniscectomy in athletes: a case  
484 report. *Knee Surg Sports Traumatol Arthrosc.* 2006;14(12):1266-1269.
- 485 13. KAPLAN EB. Surgical approach to the lateral (peroneal) side of the knee  
486 joint. *Surg Gynecol Obstet.* 1957;104(3):346-356.
- 487 14. Kashihara N, Furumatsu T, Kodama Y, Tanaka T, Ozaki T. Concurrent  
488 Lateral Meniscal Repair with Anterior Cruciate Ligament Reconstruction  
489 Induces the Extrusion of the Lateral Meniscus: Assessments of Magnetic  
490 Resonance Images. *Acta Med Okayama.* 2016;70(6):441-448.
- 491 15. LaPrade RF, Wozniczka JK, Stellmaker MP, Wijdicks CA. Analysis of the  
492 static function of the popliteus tendon and evaluation of an anatomic  
493 reconstruction: the "fifth ligament" of the knee. *Am J Sports Med.*  
494 2010;38(3):543-549.

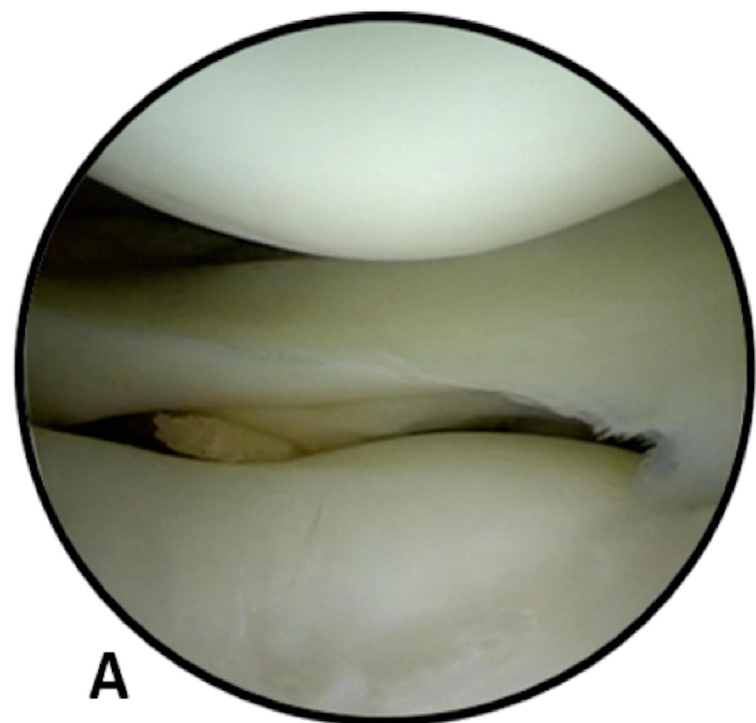
- 495 16. Lee DW, Jang HW, Lee SR, Park JH, Ha JK, Kim JG. Clinical, radiological,  
496 and morphological evaluations of posterior horn tears of the lateral meniscus  
497 left in situ during anterior cruciate ligament reconstruction. *Am J Sports Med.*  
498 2014;42(2):327-335.
- 499 17. Likes RL, Julka A, Aros BC, Pedroza AD, Kaeding CC, Jones GL, Flanigan  
500 DC. Meniscal repair with the MaxFire device: a cadaveric study. *Orthop*  
501 *Surg.* 2011;3(4):259-264.
- 502 18. Logan M, Watts M, Owen J, Myers P. Meniscal repair in the elite athlete:  
503 results of 45 repairs with a minimum 5-year follow-up. *Am J Sports Med.*  
504 2009;37(6):1131-1134.
- 505 19. López XP, Tey Pons M, Reina de la Torre F, Verdier LP, Alier Fabregó A,  
506 Pavlovich RI, Monllau García JC. [Study of the feasibility of lateral meniscal  
507 repair including the popliteal tendon with a knee simulator]. *Acta Ortop Mex.*  
508 2010;24(3):182-186.
- 509 20. Mariani PP, Garofalo R, Margheritini F. Chondrolysis after partial lateral  
510 meniscectomy in athletes. *Knee Surg Sports Traumatol Arthrosc.*  
511 2008;16(6):574-580.
- 512 21. Morgan CD. The "all-inside" meniscus repair. *Arthroscopy.* 1991;7(1):120-  
513 125.
- 514 22. Noyes FR, Barber-Westin SD. Treatment of meniscus tears during anterior  
515 cruciate ligament reconstruction. *Arthroscopy.* 2012;28(1):123-130.
- 516 23. Papastergiou SG, Koukoulis NE, Mikalef P, Ziogas E, Voulgaropoulos H.  
517 Meniscal tears in the ACL-deficient knee: correlation between meniscal tears  
518 and the timing of ACL reconstruction. *Knee Surg Sports Traumatol Arthrosc.*  
519 2007;15(12):1438-1444.

- 520 24. Pasque C, Noyes FR, Gibbons M, Levy M, Grood E. The role of the  
521 popliteofibular ligament and the tendon of popliteus in providing stability in  
522 the human knee. *J Bone Joint Surg Br.* 2003;85(2):292-298.
- 523 25. Peltier A, Lording T, Maubisson L, Ballis R, Neyret P, Lustig S. The role of  
524 the meniscotibial ligament in posteromedial rotational knee stability. *Knee*  
525 *Surg Sports Traumatol Arthrosc.* 2015;23(10):2967-2973.
- 526 26. Peña E, Calvo B, Martinez MA, Palanca D, Doblaré M. Why lateral  
527 meniscectomy is more dangerous than medial meniscectomy. A finite  
528 element study. *J Orthop Res.* 2006;24(5):1001-1010.
- 529 27. Rochcongar G, Cucurulo T, Ameline T, Potel JF, Dalmay F, Pujol N, Sallé de  
530 Chou É, Lutz C, Ehkirch FP, Le Henaff G, Laporte C, Seil R, Gunepin FX,  
531 Sonnery-Cottet B; la SFA. Meniscal survival rate after anterior cruciate  
532 ligament reconstruction. *Orthop Traumatol Surg Res.* 2015;101(8  
533 Suppl):S323-6.
- 534 28. Shelbourne KD, Gray T. Meniscus tears that can be left in situ, with or  
535 without trephination or synovial abrasion to stimulate healing. *Sports Med*  
536 *Arthrosc.* 2012;20(2):62-67.
- 537 29. Sonnery-Cottet B, Archbold P, Thaunat M, Carnesecchi O, Tostes M,  
538 Chambat P. Rapid chondrolysis of the knee after partial lateral meniscectomy  
539 in professional athletes. *Knee.* 2014;21(2):504-508.
- 540 30. Sonnery-Cottet B, Daggett M, Helito CP, Fayard JM, Thaunat M. Combined  
541 anterior cruciate ligament and anterolateral ligament reconstruction. *Arthrosc*  
542 *Tech.* 2016;5(6):e1253-1259.
- 543 31. Sonnery-Cottet B, Freychet B, Murphy CG, Pupim BH, Thaunat M. Anterior  
544 Cruciate Ligament Reconstruction and Preservation: The Single-

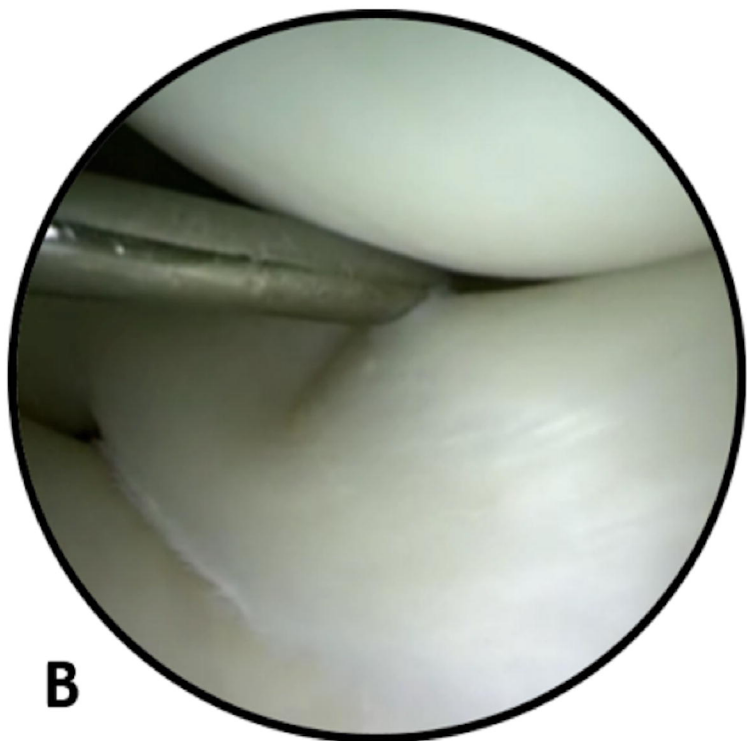


- 545 Anteromedial Bundle Biological Augmentation (SAMBBA) Technique.  
546 *Arthrosc Tech.* 2014;3(6):e689-693.
- 547 32. Stäubli HU, Birrer S. The popliteus tendon and its fascicles at the popliteal  
548 hiatus: gross anatomy and functional arthroscopic evaluation with and  
549 without anterior cruciate ligament deficiency. *Arthroscopy.* 1990;6(3):209-  
550 220.
- 551 33. Stephen JM, Halewood C, Kittl C, Bollen SR, Williams A, Amis AA.  
552 Posteromedial Meniscocapsular Lesions Increase Tibiofemoral Joint Laxity  
553 With Anterior Cruciate Ligament Deficiency, and Their Repair Reduces  
554 Laxity. *Am J Sports Med.* 2016;44(2):400-408.
- 555 34. Swiontkowski M, Resnick L. Getting a Good Grip Is Key to All-Inside  
556 Meniscal Repair. *JBJS Case Connect.* 2015;22;5(3):e61.
- 557 35. Tandogan RN, Taşer O, Kayaalp A, Taşkıran E, Pinar H, Alparslan B,  
558 Alturfan A. Analysis of meniscal and chondral lesions accompanying anterior  
559 cruciate ligament tears: relationship with age, time from injury, and level of  
560 sport. *Knee Surg Sports Traumatol Arthrosc.* 2004;12(4):262-270.
- 561 36. Thauinat M, Pioger C, Chatellard R, Conteduca J, Khaleel A, Sonnery-Cottet  
562 B. The arcuate ligament revisited: role of the posterolateral structures in  
563 providing static stability in the knee joint. *Knee Surg Sports Traumatol*  
564 *Arthrosc.* 2014;22(9):2121-2127.
- 565 37. Tria AJ Jr, Johnson CD, Zawadsky JP. The popliteus tendon. *J Bone Joint*  
566 *Surg Am.* 1989;71(5):714-716.
- 567 38. Uchida R, Mae T, Hiramatsu K, Iuchi R, Kinugasa K, Shino K, Yoshikawa  
568 H, Nakata K. Effects of suture site or penetration depth on anchor location in  
569 all-inside meniscal repair. *Knee.* 2016;23(6):1024-1028.

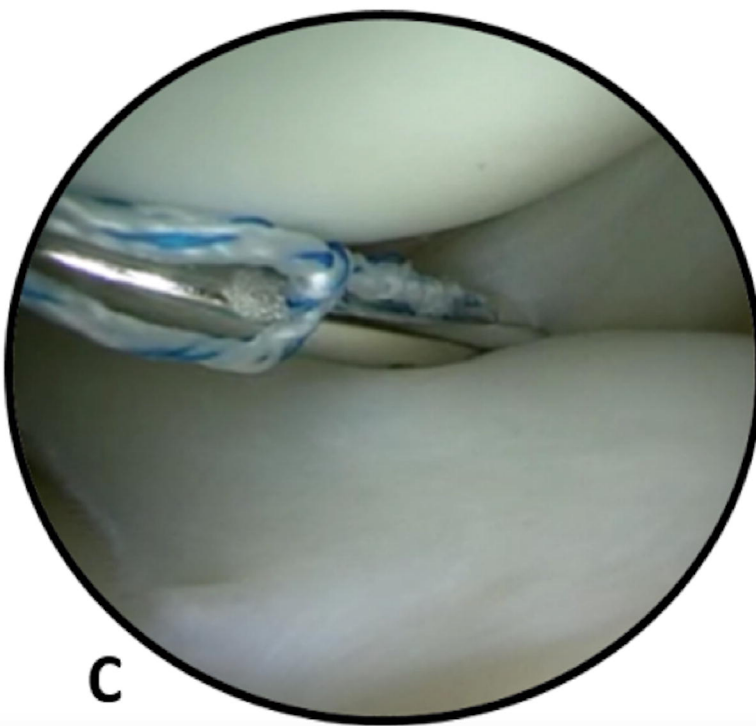
- 570 39. Verdonk PC, Demurie A, Almqvist KF, Veys EM, Verbruggen G, Verdonk  
571 R. Transplantation of viable meniscal allograft. Surgical technique. *J Bone*  
572 *Joint Surg Am.* 2006;88 Suppl 1 Pt 1:109-118.
- 573 40. Westermann RW, Wright RW, Spindler KP, Huston LJ; MOON Knee Group,  
574 Wolf BR. Meniscal repair with concurrent anterior cruciate ligament  
575 reconstruction: operative success and patient outcomes at 6-year follow-up.  
576 *Am J Sports Med.* 2014;42(9):2184-2192.
- 577 41. Xu C, Zhao J. A meta-analysis comparing meniscal repair with meniscectomy  
578 in the treatment of meniscal tears: the more meniscus, the better outcome?  
579 *Knee Surg Sports Traumatol Arthrosc.* 2015;23(1):164-170.
- 580 42. Yang JH, Jeong HI, Kim TS, Park SC, Yoon JR. The management of the  
581 popliteus hiatus during lateral meniscal transplantation. *Knee.*  
582 2012;19(6):959-961.
- 583



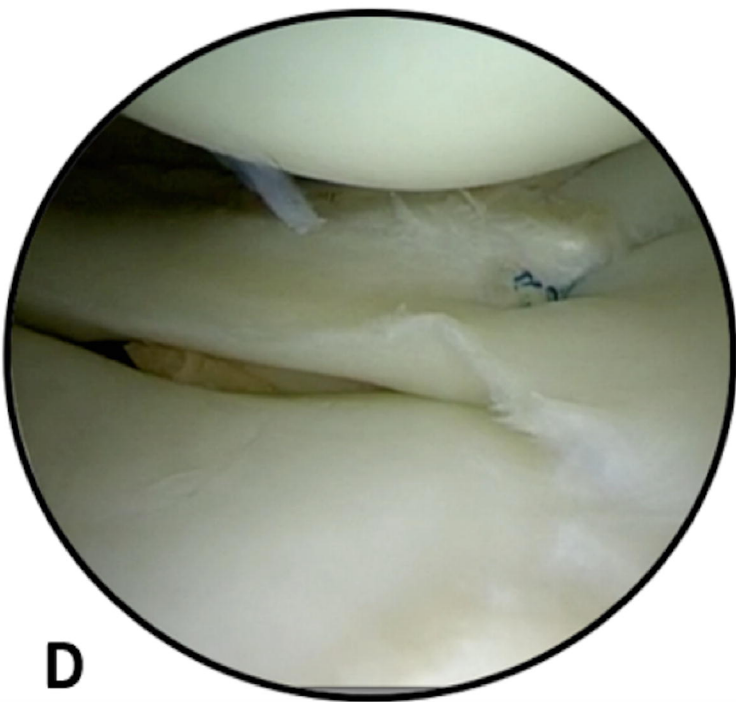
**A**



**B**



**C**



**D**

