



Fowler, T., Whitehouse, M., Riddick, A., Khan, U., & Kelly, M. (2019). A Retrospective Comparative Cohort Study Comparing Temporary Internal Fixation to External Fixation at the First Stage Debridement in the Treatment of Type IIIB Open Diaphyseal Tibial Fractures. *Journal of Orthopaedic Trauma*, 33(3), 125-130.  
<https://doi.org/10.1097/BOT.0000000000001362>

Peer reviewed version

Link to published version (if available):  
[10.1097/BOT.0000000000001362](https://doi.org/10.1097/BOT.0000000000001362)

[Link to publication record in Explore Bristol Research](#)  
PDF-document

This is the author accepted manuscript (AAM). The final published version (version of record) is available online via Wolters Kluwer Health Inc at [https://journals.lww.com/jorthotrauma/Fulltext/2019/03000/A\\_Retrospective\\_Comparative\\_Cohort\\_Study\\_Comparing.4.aspx](https://journals.lww.com/jorthotrauma/Fulltext/2019/03000/A_Retrospective_Comparative_Cohort_Study_Comparing.4.aspx). Please refer to any applicable terms of use of the publisher.

## University of Bristol - Explore Bristol Research

### General rights

This document is made available in accordance with publisher policies. Please cite only the published version using the reference above. Full terms of use are available: <http://www.bristol.ac.uk/red/research-policy/pure/user-guides/ebr-terms/>

## **TITLE**

A Retrospective Comparative Cohort Study Comparing Temporary Internal fixation to External Fixation at the First Stage Debridement in the Treatment of Type IIIB Open Diaphyseal Tibial Fractures.

## **AUTHORS**

Mr Timothy Fowler MRCS<sup>1,2,3</sup>, Mr Michael Whitehouse PhD, FRCS<sup>1,2,3</sup>, Mr Andrew Riddick FRCS<sup>1</sup>, Mr Umraz Khan FRCS<sup>4</sup>, Mr Michael Kelly FRCS<sup>1</sup>

## **AFFILIATIONS**

1. Department of Trauma and Orthopaedic Surgery, Southmead Hospital, North Bristol NHS Trust, Bristol, UK
2. Musculoskeletal Research Unit, Translational Health Sciences, Bristol Medical School, 1st Floor Learning & Research Building, Southmead Hospital, Bristol, BS10 5NB
3. National Institute for Health Research Bristol Biomedical Research Centre, University of Bristol
4. Department of Plastic Surgery, Southmead Hospital, North Bristol NHS Trust, Bristol, UK

## **CORRESPONDENCE**

Mr T J Fowler; Department of Trauma and Orthopaedic Surgery Offices, Level 2 Brunel Building, Southmead Hospital, Southmead Road, Westbury-on-Trym, Bristol, BS10 5NB. Tel: +44 (0)7590768162; E-mail: [tfowler@doctors.org.uk](mailto:tfowler@doctors.org.uk)

## **CONFLICTS OF INTEREST AND SOURCES OF FUNDING**

This study was supported by the NIHR Biomedical Research Centre at the University Hospitals Bristol NHS Foundation Trust and the University of Bristol. The views expressed in this publication are those of the author(s) and not necessarily those of the NHS, the National Institute for Health Research or the Department of Health.

## ABSTRACT

**Objectives:** To compare the rates of deep infection, flap failure and nonunion after temporary internal fixation (TIF), with temporary external fixation (ex-fix) in the management of Gustilo-Anderson (GA) type IIIB open tibia fractures.

**Design:** Retrospective comparative cohort.

**Setting:** Level 1 trauma center.

**Patients/Participants:** 64 consecutive patients with a GA type IIIB open diaphyseal tibia fracture (OTA/AO 42) were treated between May 2014 and May 2016. 47 patients (TIF = 24; ex-fix = 23) met the inclusion criteria and underwent two-stage reconstruction. Definitive fixation was with an intramedullary nail.

**Intervention:** Temporary fracture stabilization at the first stage debridement was achieved with either TIF with a plate, or ex-fix.

**Main Outcome Measurement:** Deep infection

**Results:** There were 4 complications in the ex-fix group (3 infection and 1 nonunion) and 2 complications in the TIF group (1 infection and 1 flap failure). Multiple regression modelling revealed infection ( $p=0.610$ ), nonunion ( $p=0.918$ ) and flap failure ( $p=0.112$ ) were not significantly associated with the mode of temporary fixation or other demographic and treatment variables. The odds ratio of patients treated with TIF developing an infection compared to those treated with an ex-fix was 0.29 (95% CI 0.03 to 3.01).

**Conclusion:** TIF of type IIIB open diaphyseal tibial fractures appears to be a safe alternative to conventional external fixation.

**Level of Evidence:** Therapeutic Level III

## INTRODUCTION

Fractures of the tibial diaphysis are a common injury with a reported incidence of between 17 and 22 per 100,000 population per year.<sup>1-2</sup> Open fractures account for approximately 20% of diaphyseal tibial fractures (3.4 per 100,000 population per year) and recent epidemiological data suggest that approximately 20% of these are Gustilo-Anderson (GA) IIIB.<sup>3</sup> These severe osteocutaneous injuries are associated with high rates of complications and present a reconstructive challenge.<sup>4</sup>

Definitive limb salvage is rarely undertaken at the first operation in favor of a staged approach involving debridement of the zone of injury and delayed definitive reconstruction.<sup>5-6</sup> Temporary stabilization of comminuted fractures requires careful planning to avoid jeopardizing definitive fixation and soft tissue coverage. Conventional practice favors the use of an external fixation device (ex-fix) with pins away from the zone of injury, which ideally do not interfere with the requirements of the definitive methods of stabilization and soft tissue reconstruction. It is not known if temporary internal fixation with a small fragment 3.5mm plate (TIF) is effective in place of traditional strategies of external fixation.

This study was undertaken in a unit where and the vast majority of type IIIB open tibia fractures undergo a two-stage approach.<sup>7-9</sup> The first stage is a thorough debridement by senior orthopaedic and plastic surgeons, prior to temporary stabilization with either TIF, or ex-fix. The second is a combined approach where the definitive fixation and soft tissue reconstruction is performed in the same operative episode; an approach which has previously been referred to as 'fix and flap'.<sup>10-11</sup>

We used a retrospective contemporaneous comparative cohort design to compare the outcomes of patients who had acute reconstruction of a type IIIB open diaphyseal tibia fracture (OTA/AO 42), with either TIF, or ex-fix used for temporary stabilization at the initial debridement.<sup>12</sup> All patients were treated in a single, dedicated orthopaedic center, where the definitive '*fix and flap*' operation was performed in a single procedure at the second-stage. The definitive method of fixation was with an intramedullary (IM) nail, according to established principles.

<sup>13</sup> The primary research question was: 'Is there a difference in the rates of deep infection in patients with a type IIIB open diaphyseal tibial fracture, who have temporary stabilization with TIF, compared to those who have tem-

porary stabilization with an ex-fix? The rates of flap failure and nonunion were investigated as secondary outcome measures.

## **PATIENTS AND METHODS**

In a two-year period between May 2014 and May 2016, data were prospectively collected for 64 consecutive patients with a GA type IIIB open diaphyseal tibia fracture (OTA/AO 42), who presented to the study center with an injury that met the British Orthopaedic Association Audit Standards for Trauma (BOAST) 4 criteria.<sup>8</sup> The BOAST guidelines on open fracture management outline the nationally-agreed standards for best practice. Case notes, operation notes, follow-up clinic letters, radiographic investigations and the national Trauma Audit and Research Network (TARN) database were reviewed for all patients. TARN was used for identifying the timing of injuries, the transfer status and the Injury Severity Score (ISS). Of the initial cohort of 64 patients, 1 died before reconstruction, 2 were primarily treated with bone transport and 2 had a total knee arthroplasty in situ and were definitively plated; these 5 patients were excluded. 12 patients had initial debridement, definitive fixation and soft tissue reconstruction with a local flap in a single procedure; these patients were also excluded. The remaining 47 patients had two-stage management of a type IIIB open diaphyseal tibia fracture and further analysis was performed on this cohort (Fig. 1). All 47 patients had definitive fixation with an IM nail. TIF was used in 24 patients and ex-fix in 23 patients.

Three classes of open fracture-related complications were identified: deep infection, nonunion and flap failure. These were diagnosed according to the following definitions:

### ***Deep infection***

The diagnosis of deep infection was made according to criteria, which are outlined in detail in Fig. 2. Infection occurred at any point in the study period and appeared to be related to the initial injury, or operation. The diagnosis was dependent on involvement of deep soft tissues. Of note the diagnosis was not reliant on positive deep cultures and assumed that any surgical intervention, revision, or antibiotic use was indicative of infection.<sup>14</sup>

### ***Nonunion***

Diagnosis of nonunion was based on clinical and radiological findings over a minimum follow-up period of >1.2 years. A fracture was not considered to be a nonunion until 12 months after the injury, in order to account for potential cases of delayed union. The clinical criteria used to define nonunion included the presence of pain and, or motion in response to physiological strain of the affected limb (e.g. the inability to fully weight bear without pain). The radiographic confirmation of union relied on the presence of bridging callus in at least three of four cortices assessed on anteroposterior and lateral radiographs.<sup>15-16</sup>

### ***Flap failure***

Flap failure was defined as total or partial necrosis of the transferred tissue. This complication always requires return to theatre for excision of the necrotic tissue.

### **Management Protocol**

We aimed to achieve early transfer of all patients with open tibial fractures from referring hospitals as set out by local protocols. All cases were managed pre-operatively according to national guidelines, including prompt intravenous antibiotics and tetanus prophylaxis.<sup>8</sup> Antibiotics were started as soon as possible, either pre-hospital, or on admission to the emergency department (ideally within 1 hour of injury). The choice of antibiotics was according to local antimicrobial policy and continued for 72 hours, or until definitive soft tissue coverage was achieved. The first-line for antibiotic prophylaxis was flucloxacillin 1g IV four times per day and gentamicin 5mg/kg once daily. The initial surgical treatment (debridement and temporary stabilization) was performed in the specialist center in all cases. All cases considered here were definitely treated in two operations consisting of: Stage 1) Debridement and temporary fixation; Stage 2) Definitive fixation and soft tissue coverage (*'fix and flap'*).

### ***Debridement and temporary fixation (Stage 1)***

The initial surgical treatment was debridement and temporary fixation, which was performed as a combined procedure between senior orthopaedic and plastic surgeons on a planned trauma operating list within normal working hours. We aimed to achieve this within 24 hours of injury, regardless of whether the patient was a primary transfer from the scene of injury, or a secondary transfer from a local referring hospital.

Aggressive debridement of all devitalized soft tissues was routinely performed with wound extension along fasciotomy lines where possible.<sup>8</sup> Bone ends were exposed, debrided and underwent copious irrigation with a minimum of 5000ml of normal saline. Temporary fracture stabilization was either achieved with an ex-fix device, or TIF with a 3.5mm small fragment plate (e.g. DCP/LCP according to surgeon preference), which was applied with bicortical screw fixation. TIF was achieved after soft tissue debridement, with no additional incisions required for bone exposure (Fig. 3A & Fig. 4B). The plate was most commonly placed on the anteromedial aspect of the tibia. Note that in all cases where TIF was employed, the plate was removed and discarded with further full debridement during the definitive second-stage procedure. The choice of method of temporary stabilization was according to the surgeon's preference. A temporary dressing was either negative pressure wound therapy (NPWT), or standard wound dressings and all patients who had TIF were put in a plaster of Paris backslab.

The assessment of the GA classification of the injury was made by the operating surgeons during the initial debridement and documented at the end of the procedure when the full extent of the injury was clear. In each case, the formal assessment of the GA classification was made and documented by a senior plastic surgeon and a senior orthopaedic surgeon.

### ***Definitive fixation and soft tissue coverage (Stage 2)***

Following initial debridement and temporary fixation, we aimed to achieve definitive fracture fixation and soft tissue reconstruction within 72 hours of injury. All patients were listed on a dedicated orthoplastic theatre list with input from senior orthopaedic and plastic surgeons. In all cases, fracture fixation was achieved with a reamed and statically locked IM nail (Stryker T2™, Mahwah, NJ, USA). Furthermore, in all cases, the definitive fracture fixa-

tion and soft tissue coverage was achieved during the same operation. Soft tissue reconstruction was achieved with a range of local and free flap options. Where local flaps were used, these were fasciocutaneous flaps. However, the most commonly used method of soft tissue reconstruction was the anterolateral thigh (ALT) free flap (Fig. 3B). As described, the GA classification of each injury was clearly documented prior to soft tissue reconstruction and only IIIB injuries were included in this study. The choice of flap used for soft tissue reconstruction was made on a case-by-case basis by the senior operating plastic surgeon. Examples of factors considered in flap selection included: the relevant vascular anatomy, the specific injury pattern, the availability of suitable soft tissue at the donor site, the injury severity status and the patient's medical comorbidities.

### ***Follow-up***

Follow-up was in a combined orthoplastic clinic, with patients reviewed by senior surgeons from both specialties. There was no blinding in the follow-up process with regards to the method of temporary stabilization.

### **Statistical Analysis**

For categorical data, descriptive statistics were used and chi-squared of comparison. For continuous data, data distribution was assessed with a D'Agostino and Pearson omnibus normality test. Where data was normally distributed, data is described by the mean and standard deviation (SD) and compared with unpaired two-tailed t-tests. Non-normally distributed data was described by the median, inter-quartile range (IQR) and range and compared with two-tailed Mann-Whitney U tests. Multiple regression models were constructed for the outcomes of infection, nonunion and flap failure. The independent variables considered were the type of temporary fixation (ex-fix or TIF), flap type (local or free (ALT, radial, scapular or gracilis), period of follow up, whether the patient was a secondary transfer, time to debridement, time to definitive fix and flap, age at the time of injury, gender, side, smoking status, diabetes, ISS and NISS. The models were assessed for multicollinearity using an  $R^2$  statistic, the  $R^2$  demonstrated that multicollinearity was a problem between the ISS and NISS ( $R^2 > 0.86$ ) and therefore the NISS was removed from the models. The odds ratios and 95% confidence intervals (95% CI) were calculated for the TIF treatment group compared to the ex-fix treatment group.



## RESULTS

### *Demographics*

Of the 47 patients included, 31 were male and 16 female. The median age was 41 years (IQR 25.0-67.5; range 17.5-92.8). 11 patients were smokers, 3 were diabetic and the median ASA grade at the time of initial surgery was 2 (IQR 1-2; range 1-4). The median ISS score was 9 (IQR 9-10; range 9-34). Patients were followed up for a mean of 2.1 years (SD 0.57) from the date of definitive surgery (minimum 1.2 years). The TIF and ex-fix groups had comparable demographics, as demonstrated in Table 1.

### *Time of surgery*

19 patients were transferred in from regional referring centers. 40 patients (85%) had initial surgical debridement within 24 hours of injury. 29 patients (62%) had definitive fixation and wound cover within 72 hours and 96% within 7 days. The median time to first debridement was 17 hours (IQR 10.5-21.6; range 2.5-86.2). The median time to definitive fix and flap was 67 hours (IQR 51.3-91.0; range 22.3-366.3).

### *Dressings*

The UK Wound Management of Open Lower Limb Fractures (UK WOLLF) trial was recently conducted to compare the outcomes of NPWT and standard dressings in patients with this injury pattern. The study demonstrated that there was no difference in disability, infection rates, or cost in association with the use of NPWT when compared to standard dressings. As one of the contributing centres to this study we have not included the dressing type as an independent variable in our model.<sup>17</sup>

### *Temporary internal fixation vs. external fixation*

With regards to temporary skeletal stabilization, 23 patients had an ex-fix and 24 had TIF with a small fragment plate and backslab (Table 2). There were 4 open fracture related complications (17%) recorded in the ex-fix group: 3 episodes of deep infection and 1 episode of nonunion. Two of these episodes of deep infection also resulted in loss of the overlying free flap. For the purpose of overall rates of complications, we have reported these as an episode of deep infection according to the primary underlying etiology. Further details of flap complications are recorded separately in Table 3. In contrast, there were 2 complications (8%) recorded in the TIF group: 1 episode of deep infection and 1 episode of flap failure.

### *Soft tissue coverage*

Various methods of definitive soft tissue coverage were used, as documented in Table 3. Overall, 6 patients (13%) had a local flap and 41 patients (87%) had a free flap. Of those who had soft tissue reconstruction with a free flap, 31 patients (76%) had an anterolateral thigh (ALT) flap. Gracilis, scapular/parascapular and radial forearm flaps were also used.

### *Overall Open fracture related complication rates*

There were a total of 6 patients affected by the reported complications (13%). Four cases were complicated by deep infection reflecting an overall rate of 9%. The rate of deep infection was 13% and 4% in the ex-fix and TIF groups, respectively. Three cases were complicated by flap failure (6%). There was only a single case of isolated flap failure, which was related to a microvascular complication and occurred at <24 hours post-op. Two of the episodes of flap failure were delayed (>1 month) and associated with deep infection. As previously noted, for the purpose of overall complication rates, we have reported these two cases as episodes of infection according to the primary underlying etiology. There was a single case of nonunion (2%).

The rate of infection was not significantly predicted by the model ( $p=0.610$ ), nor were the rate of flap failure ( $p=0.112$ ) nor nonunion ( $p=0.918$ ).

The odds ratio of patients treated with TIF (compared to patients treated with an ex-fix) developing an infection was 0.29 (95% CI 0.03 to 3.01), of developing flap failure was 0.46 (95% CI 0.04 to 5.41) and of developing nonunion was 0.31 (95% CI 0.01 to 7.91).

## **DISCUSSION**

The acute reconstruction of severe open lower limb injuries is rarely undertaken at the first operation in favor of a staged approach that necessitates a form of temporary skeletal stabilization. The conventional method of choice is an external fixation device. This study compares the conventional approach to the use of a small fragment plate and backslab. The data presented demonstrate that in the context of a combined orthoplastic approach, temporary internal stabilization of open tibial fractures offers a safe and effective alternative to external fixation with lower rates of complications (8% vs. 17%) in this cohort. This has led to a wholesale change in practice in our unit, where TIF is now used as the standard approach to temporary stabilization in open lower limb fractures.

The overall deep infection rate in this cohort was 9%. It was 4% and 13% in the TIF and ex-fix groups, respectively. While the primary outcome measure of deep infection was lower in the TIF group, this was not predicted by the statistical model. The rates of deep infection and overall complications reported in this study compare favorably to recently published data in larger cohorts. The LEAP studies reported a deep infection rate of 25.2% for IIIB tibia fractures (n=135; 11.1% osteomyelitis; 14.1% other infection). Furthermore, they reported a nonunion rate of 28.9% in the same cohort.<sup>18</sup> In a prospective cohort study of 737 open lower limb fractures, Weber et al. published a deep infection rate in type IIIB open tibial fractures (n=413) of 18%.<sup>19</sup> It is important to note that our approach differed from those described in these studies, in that we used a two-stage approach, in which the definitive fixation and soft tissue reconstruction was performed in a single procedure at the second stage; an approach which itself has been shown to reduce the risk of developing deep infection.<sup>9-10</sup> Furthermore, we emphasize the importance of an aggressive initial debridement.<sup>20</sup> The use of temporary internal fixation in this context is not widely reported. However, data presented by Tornetta et al. at the OTA in Vancouver (2017) support our findings and suggest that TIF does not increase the risk of infection.<sup>21</sup>

The TIF approach described in this paper is attractive for a number of reasons. Plate fixation is familiar to all orthopaedic surgeons and is a technique that the majority of surgeons would use more commonly in their practice than external fixation. The familiarity of the surgeon and operating theatre staff with the equipment and techniques is of benefit when treating complex injuries, even in high volume centers. There were initial concerns that TIF would cause additional, or even excessive periosteal and soft tissue stripping. However, we propose that this technique mandates extension of the traumatic wound to reveal the entire zone of injury, thereby facilitating a much more thorough debridement, which reduces the risk infection by aiding the elimination of contaminated and devitalized tissues. Furthermore, there are notable cost implications, with plate fixation generally being a cheaper option than external fixation. However, a formal health economic analysis is not within the scope of this paper, thus has not been included as simply considering the costs of the surgical procedure does not account for the majority of the healthcare associated costs in treatments such as this and would hence be misleading. One further advantage is the ease of nursing TIF patients on the ward, compared to the obvious practical issues posed by bulky external fixators.

Our paper has a number of strengths. The comparative cohorts are contemporaneous and procedures were carried out by a number of different orthopaedic and plastic surgeons in the unit, increasing the generalizability of the approach to other orthoplastic units; this is not a technique only being performed by one or two pairs of surgeons. We have looked at a number of different outcomes to establish the safety of the technique and although no significant differences between the groups were demonstrated, the trends are reassuring that the TIF technique is safe and repeatable in the context of an established orthoplastic service.

Our paper does have limitations, the design of the study is retrospective and allocation was not randomized, leading to the potential for selection bias being introduced. In addition, there was no blinding in the follow-up process, leading to the potential for observer bias. With regards to the patient demographics, while these were comparable (Table 1) patients in the ex-fix group were younger, which one might have expected to introduce bias in favor of this group. We are able to demonstrate association with this study design but not definitively show causation due to the mode of temporary fixation. There is the possibility that patients underwent further treatments in other units

of which we were unaware, but given the specialty referral nature of our center, the close follow-up of these patients in a dedicated limb reconstruction clinic and the multiple information sources reviewed, we feel that this is unlikely. We have not examined functional outcomes, or patient reported outcome measures as part of this study design. Furthermore, we acknowledge that number of patients in each study group was relatively low. However, the data in this study have enabled us to perform a power calculation, which indicates that if a prospective randomized study were to be performed with a primary outcome of infection, the rates in this study (1/24 in in-fix group and 3/23 in ex-fix group) would give an effect size of 0.27. Assuming an alpha value of 0.05 and a power of 0.8, a total sample size of 180 (90 in each group) would be required to detect a significant difference.

In conclusion, our study evaluating temporary internal fixation of type IIIB open diaphyseal tibial fractures does not appear to increase the risk of deep infection when compared to external fixation in the context of a combined orthoplastic service performing “fix and flap”. It appears to be at least as safe as external fixation and may confer some additional advantages in terms of longer term deep infection. The comparison between these two interventions in this context warrants further study with a prospective randomized trial with greater numbers of patients.

## REFERENCES

1. Larsen P, Elsoe R, Hansen SH, et al. Incidence and epidemiology of tibial shaft fractures. *Injury*. 2015 Apr 30;46(4):746-50.
2. Court-Brown CM, Caesar B. Epidemiology of adult fractures: a review. *Injury*. 2006 Aug 31;37(8):691-7.
3. Court-Brown CM, Bugler KE, Clement ND, et al. The epidemiology of open fractures in adults. A 15-year review. *Injury*. 2012 Jun 30;43(6):891-7.
4. Obremesky W, Molina C, Collinge C, et al. Current practice in the management of open fractures among orthopaedic trauma surgeons. Part A: initial management. A survey of orthopaedic trauma surgeons. *Journal of Orthopaedic Trauma*. 2014 Aug 1;28(8):e198-202.
5. Khan U, Kelly MB, Pleat J, et al. Orthoplastics: an integral evolution within comprehensive trauma care. *Injury*. 2011 Oct 1;42(10):969-71.
6. Khan U, Boriani F, Baldini N. Orthoplastics: an evolving concept for integrated surgical care of complex limb trauma and abnormality. *Plastic and reconstructive surgery*. 2013 Feb 1;131(2):313e-4e.
7. BOA/BAPRAS Standards for the management of open fractures of the lower limb. Available at: <http://www.bapras.org.uk/docs/default-source/commissioning-and-policy/standards-for-lower-limb.pdf?sfvrsn=0> [accessed 7/14/2017]
8. British Orthopaedic Association and British Association of Plastic, Reconstructive and Aesthetic Surgeons Standards from Trauma 4 (BOAST 4). Available at: <https://www.boa.ac.uk/wp-content/uploads/2017/12/BOAST-Open-Fractures.pdf> [accessed 15/05/2018]
9. Mathews JA, Ward J, Chapman TW, et al. Single-stage orthoplastic reconstruction of Gustilo–Anderson Grade III open tibial fractures greatly reduces infection rates. *Injury*. 2015 Nov 30;46(11):2263-6.
10. Gopal S, Majumder S, Batchelor AG et al. Fix and flap: the radical orthopaedic and plastic treatment of severe open fractures of the tibia. *Bone & Joint Journal*. 2000 Sep 1;82(7):959-66.
11. Godina M. Early microsurgical reconstruction of complex trauma of the extremities. *Orthopedic Trauma Directions*. 2006 Sep;4(05):29-35.

12. Marsh JL, Slongo TF, Agel J, et al. Fracture and Dislocation Classification Compendium - 2007: Orthopaedic Trauma Association Classification, Database and Outcomes Committee. *Journal of Orthopaedic Trauma*. 2007;21 Supplement 10 pp: S1-S163.
13. Sanders R, Jersinovich I, Anglen J, et al. The treatment of open tibial shaft fractures using an interlocked intramedullary nail without reaming. *Journal of Orthopaedic Trauma*. 1994 Dec;8(6):504-10.
14. CDC Criteria for Deep Surgical Site Infections. Available at: <https://www.cdc.gov/nhsn/pdfs/pscmanual/9pscscscurrent.pdf> [accessed 09/17/2018]
15. Whelan DB, Bhandari M, Stephen D, et al. Development of the radiographic union score for tibial fractures for the assessment of tibial fracture healing after intramedullary fixation. *Journal of Trauma and Acute Care Surgery*. 2010 Mar 1;68(3):629-32.
16. Kooistra BW, Dijkman BG, Busse JW, et al. The radiographic union scale in tibial fractures: reliability and validity. *Journal of Orthopaedic Trauma*. 2010 Mar 1;24:S81-6.
17. Costa M, Fernandez M. UK Wound Management of Open Lower Limb Fractures (UK WOLLF): A Randomized Control Trial of Standard Wound Management versus Negative Pressure Wound Therapy in the Treatment of Adult Patients with an Open Wound Fracture of the Lower Limb. Orthopaedic Trauma Association, Vancouver 2017 Oct. Paper 65.
18. Bosse MJ, MacKenzie EJ, Kellam JF et al. An analysis of outcomes of reconstruction or amputation after leg-threatening injuries. *New England Journal of Medicine*. 2002 Dec 12;347(24):1924-31.
19. Weber D, Dulai S, Bergman J et al. Time to Initial Operative Treatment Following Open Fracture Does Not Impact Development of Deep Infection: A Prospective Cohort Study of 736 Subjects. *Journal of Orthopaedic Trauma*. 2014 Nov; Vol 28:613-619.
20. Khan U. An orthoplastic approach to bone infection after trauma. *Trauma*. 2017 Oct;19(4):254-63.
21. Tornetta P, Kuripala C, Koh J, et al. Timing of Definitive Fixation with Respect to Flap Coverage in Open Tibia Fractures. Orthopaedic Trauma Association, Vancouver 2017 Oct. Paper 122.

## FIGURE LEGENDS

Fig. 1. Flow diagram illustrating the cohort. Further analysis was performed on 47 patients with a type IIIB open fracture of the tibial diaphysis (OTA/AO 42), who had two-stage management of their injury, with IM nail fixation and soft tissue coverage performed in the second-stage procedure.

Fig. 2. Diagnostic criteria for deep infection.

Figure 3. Photographic illustration of typical debridement of devitalized soft tissues and temporary internal fixation within the zone of injury (A). Postoperative appearance of soft tissues following free flap (ALT) reconstruction (B).

Fig. 4. Radiographic illustration of temporary internal fixation (B) of an open diaphyseal tibial fracture (A).



Figure 1.

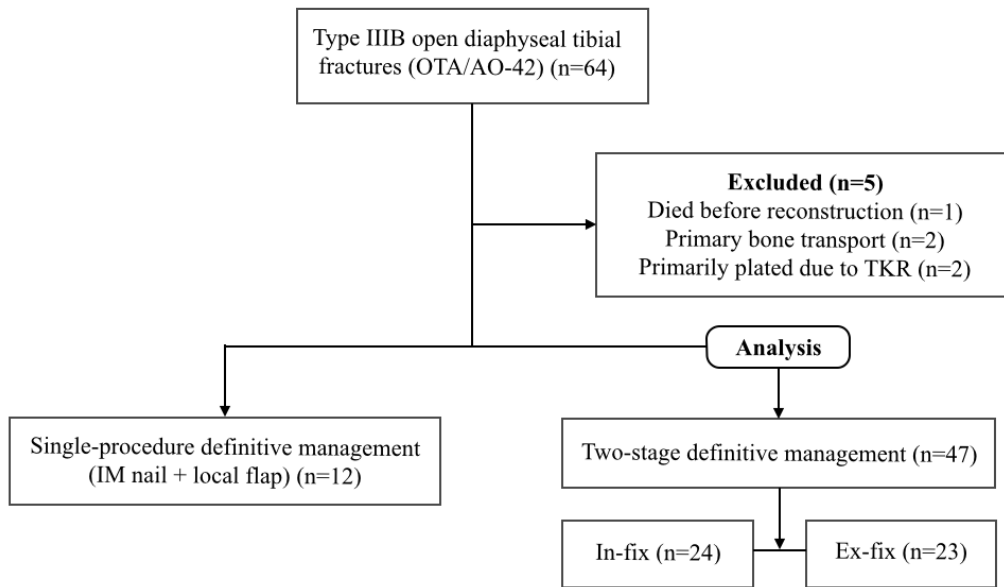


Figure 2.

Infection occurred at any point in the study period and appeared to be related to the initial injury, or operation. The diagnosis of deep infection was not reliant on positive deep cultures and assumed that any surgical intervention, revision, or antibiotic use was indicative of infection.

*and* infection involved the deep soft tissues (e.g. fascial and muscle layers) of the incision.

*and* at least one of the following:

1. Purulent drainage from the deep incision.
2. The deep incision spontaneously dehiscenced, or was deliberately opened by a surgeon when the patient had at least one of the following signs or symptoms: fever ( $>38^{\circ}\text{C}$ ), localized pain, or tenderness.
3. An abscess or other evidence of infection involving the deep incision was found on clinical examination, during reoperation, or by histopathological/radiological examination.

Figure 3.

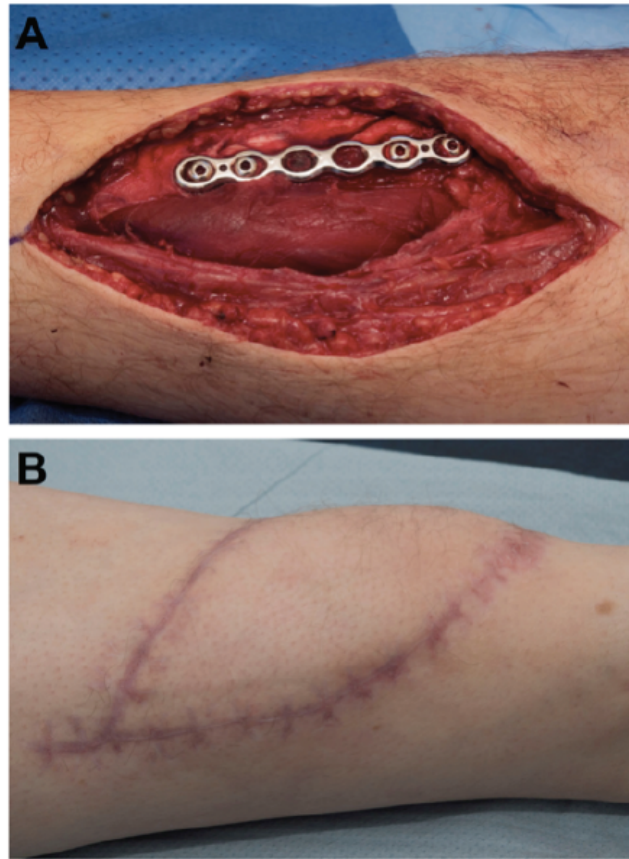
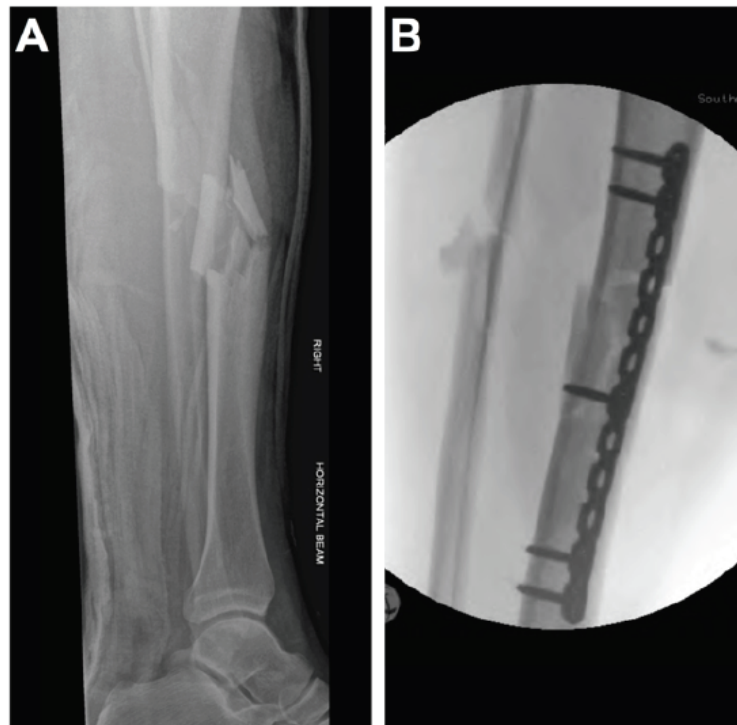

Figure 4.



**Table 1.**

<b>TABLE 1. Patient Demographics</b>			
	<b>Ex-fix</b>	<b>TIF</b>	<b><i>p</i>-value</b>
n	23	24	
Male:Female	15:8	16:8	0.92
Median age (IQR)	31.7 (23.4-49.8)	58.0 (36.8-71.1)	0.02
Median ASA grade (IQR)	1 (1-2)	2 (1-2)	0.07
Smokers	7 (30%)	4 (17%)	0.27
Diabetic	1 (4%)	2 (8%)	0.58
Median Injury Severity Score (ISS) (IQR; range)	9 (9-10; 9-34)	9 (9-13; 9-34)	0.91
Median time to debridement (hours) (IQR)	14.7 (6.2-21.5)	18.85 (14.8-22.8)	0.08
Median time to definitive 'fix and flap' (hours) (IQR)	68.4 (48.0-93.3)	66.46 (56.4-88.6)	0.81
Definitive fixation within 72 hours	16/23 (70%)	14/24 (58%)	0.42

**Table 2.**

<b>TABLE 2. Overall Rates of Complications</b>					
	<b>Number of cases</b>	<b>Complications</b>	<b>Deep infection</b>	<b>Flap failure</b>	<b>Nonunion</b>
Ex-fix	23	4	3 (13%)	0 (0%)	1 (4%)
TIF	24	2	1 (4%)	1 (4%)	0 (0%)
Total	47	6	4 (9%)	1 (2)	1 (2%)

**Table 3.****TABLE 3. Methods and Complications of Soft Tissue Reconstruction**

<b>Type of soft tissue coverage</b>	<b>Number of cases (%)</b>	<b>Episodes of flap failure</b>
Local flap	6 (12.8%)	0
Free flap	41 (87.2%)	3

<b>Types of free flap</b>	<b>Number of cases (%)</b>	<b>Episodes of flap failure</b>	<b>Etiology of flap failure</b>
ALT	31 (75.6%)	3	1 microvascular complication at <24 hours 2 infected >1 month post-op
Scapular/Parascapular	5 (12.2%)	0	
Gracilis	3 (7.3%)	0	
Radial forearm	2 (4.9%)	0	