

PDF hosted at the Radboud Repository of the Radboud University Nijmegen

The following full text is a publisher's version.

For additional information about this publication click this link.

<http://hdl.handle.net/2066/88617>

Please be advised that this information was generated on 2017-12-06 and may be subject to change.

Extensive segmental acanthosis nigricans form of epidermal nevus

Anne C de Waal MD, Michelle M van Rossum MD PhD, H Jorn Bovenschen MD PhD
Dermatology Online Journal 16 (6): 7

Department of Dermatology, The Netherlands. j.bovenschen@derma.umcn.nl

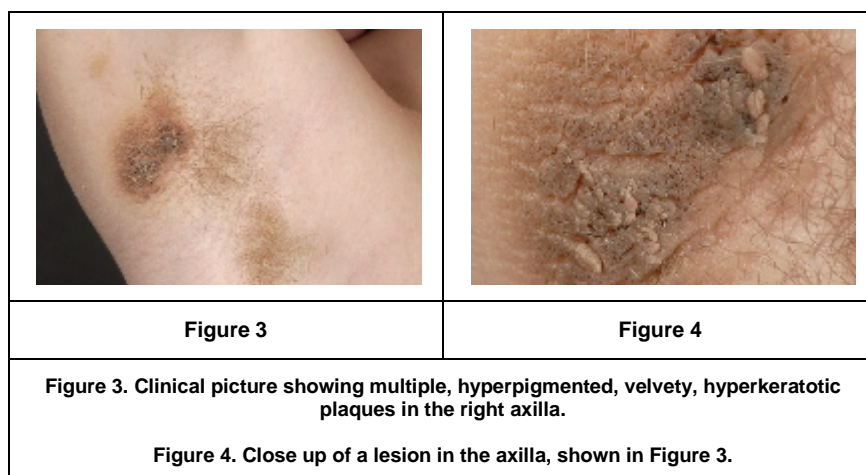
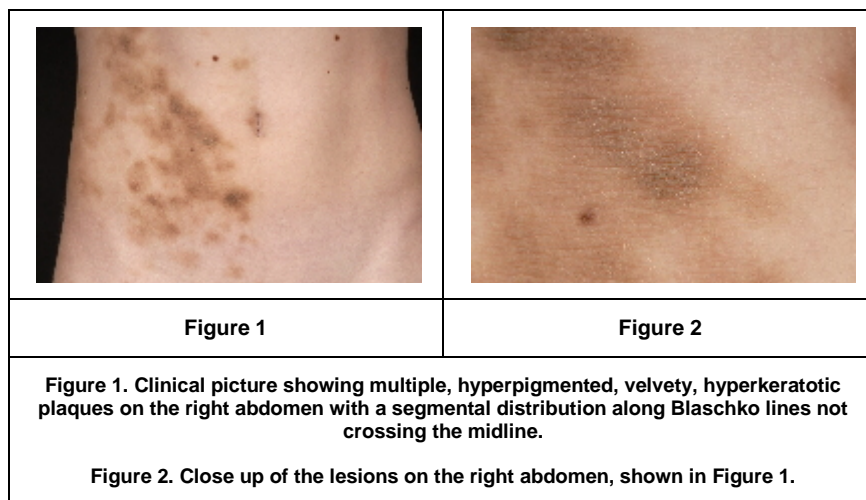
Abstract

Eight cases of the acanthosis nigricans form of epidermal nevus have been described in literature. The present case is impressive and has an extensive segmental distribution. Although etiological factors, such as mutations in the FGFR3 gene, are becoming recognized, treatment options remain limited. We present a case of a 14-year-old male with multiple hyperpigmented, hyperkeratotic plaques on the upper body, axillae, and groin with a segmental distribution following Blaschko lines. Histopathological investigation showed aspects of both acanthosis nigricans and epidermal nevus. So far, screening has not revealed any internal abnormalities. As previous cases show a clear association with internal diseases, repetitive screening for internal diseases and syndromes is suggested in the case of the acanthosis nigricans form of epidermal nevus. Treatment of the condition remains a challenge.

Introduction

Eight cases of the acanthosis nigricans (AN) form of epidermal nevus (EN) have been described in the literature. These patients share clinical and histopathological features of both AN and EN. Associations with other diseases have been reported in the literature. Furthermore, the treatment of these conditions is a real challenge. Hence we describe this patient to discuss both potential underlying pathology and treatment options.

Case report



A 14-year-old male presented with multiple, hyperpigmented, hyperkeratotic plaques on the right abdomen, groin, axilla and back with a segmental distribution following Blaschko lines (Figures 1 through 4). The lesions were first observed on his abdomen at the age of 2½ years, but progressive involvement developed in the axilla and groin. The plaques expanded gradually in size and number, in a linear pattern. The lesions became darker over time. No other skin, hair, or nail abnormalities were observed. The patient had no history of endocrinopathies, such as thyroid disease, diabetes mellitus, Cushing disease, acromegaly, or Addison disease. Syndromal features were lacking. Family history was negative for epidermal nevus, acanthosis nigricans or any other skin disease; there were no malignancies or genetic syndromes in his family. The family history was negative for endocrinopathies except for two grandparents who had diabetes mellitus type II.

Two biopsies were taken with a differential diagnosis of acanthosis nigricans and segmental epidermal nevus. Histopathology consistently revealed epidermal acanthosis, papillomatosis, and intrafollicular hyperkeratosis with hyperpigmentation of the basal and suprabasal lamina, without signs of epidermolysis. A dermal lymphocytic infiltrate was observed perivascular and at the basal membrane zone (Figure 5). Electron microscopy of the epidermis did not show any signs of epidermolysis. However, there were irregularly distributed tonofilaments and only sparsely observed lamellar bodies and keratohyalin granules. Clinicopathological correlation culminated in a diagnosis of non-epidermolytic acanthosis nigricans form of epidermal nevus.

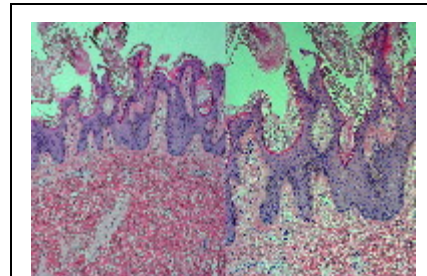


Figure 5

Figure 5. Histological picture (H&E, (A) x50 and (B) x100) showing acanthosis, papillomatosis, and intrafollicular hyperkeratosis with hyperpigmentation of the basal and suprabasal lamina, without signs of epidermolysis. A lymphocytic infiltrate was observed to be perivascular and at the basal membrane zone.

Discussion

Acanthosis nigricans (AN) is a skin disorder characterized by hyperpigmented velvety plaques symmetrically distributed on the sides of the neck, axillae and groins. Skin hyperplasia may result from the stimulation of insulin-like growth receptors. It is associated with obesity, endocrinopathies (insulin resistant diabetes mellitus, Cushing disease and acromegaly), and visceral malignancies. Acanthosis nigricans maligna is a rare form of AN that is associated with adenocarcinomas [1].

Epidermal nevi (EN) are congenital skin lesions that are characterized by hyperplasia of the epidermis and skin adnexa, resulting in a collection of hyperpigmented papules and plaques along Blaschko lines. These lines are believed to trace the migration of embryonic cells and are invisible under normal conditions. Inherited and acquired skin diseases may manifest themselves according to these embryonic lines, creating the visual appearance of lines, usually forming linear patterns on extremities, “V” shapes over the back and “S” shapes over the chest and abdomen. The cause of the formation of these lines, is thought to result from mosaicism, in which a postzygotic mutation occurs in gonadal or somatic cells, leading to two or more genetically different cell populations.

Epidermolytic hyperkeratosis may be observed in epidermal nevi with a keratin 1 or 10 mutation. Patients with these nevi have a mosaic form of bullous congenital ichthyosiform erythroderma (BCIE), which may arise in a generalized form in patients' offspring [2]. No epidermolytic hyperkeratosis was observed in our patient.

In 2006, Ersoy-Evans et al. described four individuals with an AN form of EN, with a segmental distribution and clinical and histopathological features of both AN and EN, as in the present case [3]. Four additional cases were found in the literature. In four of these eight individuals, mucoepidermoid carcinoma, EN syndrome, Hashimoto thyroiditis, and amenorrhea with obesity were observed. Four other cases had no associated diseases [3]. Because of this association with underlying conditions, our patient was screened by a pediatrician for endocrinopathies, syndromes, and malignancies. Physical examination and extensive laboratory evaluation of blood glucose, insulin, and lipids did not reveal any abnormalities in our patient. Because of the extensive manifestation of this AN form of EN our patient and his parents received instructions to consult a physician should any signs of underlying disease develop and he will continue to be monitored.

It has become clear that germline mutations of the fibroblast-growth-factor receptor (FGFR) are associated with skeletal dysplasia syndromes and dwarfism. In some of these syndromes acanthosis nigricans is manifest. The FGFR family comprises 4 major transmembrane receptor tyrosine kinases and is involved in embryogenesis, angiogenesis, and tissue homeostasis. Theorizing that the histopathological resemblance of AN with EN may deflect a similar genetic causality, Hafner et al. identified activating FGFR3 mutations in affected skin in 11 of 33 patients with nonepidermolytic epidermal nevi. In 4 of these cases, samples of adjacent unaffected skin could be analyzed, and FGFR3 mutations were absent. They concluded that a large proportion of human epidermal nevi are therefore caused by mosaicism of postzygotic activating FGFR3 mutations in human epidermis [4]. However, the study did not include patients with the acanthosis nigricans form of epidermal nevus.

Epidermal nevus syndromes are characterized by epidermal nevi accompanied by skeletal and nervous system abnormalities and some associated malignancies; these may be caused by a more widespread mosaicism of FGFR3 mutations.

The current standard therapy for epidermal nevi is surgery or ablative CO2 laser treatment. Topical tretinoin cream (0.02 or 0.05) percent and 5-fluorouracil cream have been used in the treatment of both acanthosis nigricans and epidermal nevi with variable results [5]. Treatment with topical tretinoin cream 0.02 percent once daily was not effective in the present patient. Therefore, CO2 laser treatment will be initiated in the future. Furthermore, several small molecule tyrosine kinase inhibitors of FGFR3 are available and being evaluated for the treatment of acute myeloid leukemia. These drugs may also be useful in the treatment of other disorders associated with FGFR3 mutations, such as benign skin lesions.

In conclusion, the AN form of EN may be associated with underlying pathology. Hence, internal screening and follow up is warranted. Treatment of these lesions remains an ultimate challenge.

References

1. Higgins SP, Freemark M, Prose NS. Acanthosis nigricans: a practical approach to evaluation and management. *Dermatol Online J* 2008; 14(9): 2. [[PubMed](#)]
2. Paller AS. Piecing together the puzzle of cutaneous mosaicism. *J Clin Invest* 2004; 114(10): 1407-9. [[PubMed](#)]
3. Ersoy-Evans S, Sahin S, Mancini AJ, Paller AS, Guitart J. The acanthosis nigricans form of epidermal nevus. *J Am Acad Dermatol* 2006; 55(4): 696-8. [[PubMed](#)]
4. Hafner C, van Oers JM, Vogt T, Landthaler M, Stoehr R, Blaszyk H, Hofstaedter F, Zwarthoff EC, Hartmann A. Mosaicism of activating FGFR3 mutations in human skin causes epidermal nevi. *J Clin Invest* 2006;116(8): 2201-7. [[PubMed](#)]
5. Kim JJ, Chang MW, Shwayder T. Topical tretinoin and 5-fluorouracil in the treatment of linear verrucous epidermal nevus. *J Am Acad Dermatol* 2000; 43: 129-32. [[PubMed](#)]