

PDF hosted at the Radboud Repository of the Radboud University Nijmegen

The following full text is a publisher's version.

For additional information about this publication click this link.

<http://hdl.handle.net/2066/86681>

Please be advised that this information was generated on 2017-12-06 and may be subject to change.

Spontaneous coronary artery dissection during pregnancy and post partum

D. J. BAC*, F. K. LOTGERING†, A. P. K. VERKAAIK‡ AND J. W. DECKERS

*Thoraxcenter, Division of Cardiology, †Department of Gynaecology and Obstetrics, ‡Department of Anaesthesiology, Erasmus University and University Hospital, 'Dijkzigt', The Netherlands

KEY WORDS: Myocardial infarction, pregnancy, dissection.

This report describes a 35-year-old 40 week pregnant woman who was hospitalized with a diagnosis of acute anteroseptal myocardial infarction. She sustained another, infero-posterior, infarction 4 days later. Coronary arteriography performed after successful Cesarean section displayed primary dissections of the right as well as both left coronary arteries. Her subsequent clinical course was uneventful with medical therapy. This patient is the first non-surgically treated survivor of peripartum spontaneous coronary artery dissection with a myocardial infarction prior to delivery.

Introduction

Spontaneous coronary artery dissection is a rare event^[1-3]. A total of 28 cases of peripartum coronary artery dissection have been described, most of which occurred during the last trimester of pregnancy or post-partum^[4-13]. A review of these cases is provided, including the novel description of a pregnant patient with dissection in the right and left coronary arteries, culminating in consecutive anterior and inferior myocardial infarctions just prior to delivery.

Case report

A 35-year-old primigravida, 40 week pregnant woman, was admitted with a diagnosis of myocardial infarction. Her previous history was unremarkable. No relevant abnormalities were observed on physical examination. Cardiac enzyme levels were elevated (creatinine kinase 1154 IU .⁻¹), and Q waves were present in precordial leads V₁-V₄. Because onset of her symptoms had occurred more than 12 h prior to admission, thrombolytic therapy was not considered. Treatment consisted of i.v. heparin and nitroglycerine. Four days later, the patient developed a second myocardial infarction, this time located infero-posteriorly. Because of fetal distress, Caesarean section was performed the next day under epidural anaesthesia, and a healthy female of 3400 g was delivered.

The patient again experienced chest pain the following day and urgent diagnostic cardiac catheterization was performed. Angiographic evidence of dissections proximal in the right coronary artery (not illustrated), in the first diagonal branch of the anterior descending as well as proximal in the circumflex coronary artery were found (Fig. 1(a)). Anticoagulation and nitroglycerine

were continued and the subsequent course was uneventful. The patient remained hospitalized for 4 weeks. Coronary angiography repeated at that time demonstrated no change in severity of the dissections. No evidence of ischaemia was found with dobutamine stress testing and the patient was subsequently discharged. During follow-up, she has remained free from anginal symptoms. Repeat angiography at 6 months displayed normal luminal aspects of the previously affected coronary vessels (Fig. 1(b)).

Discussion

Spontaneous (primary) coronary artery dissection has been reported as a cause of myocardial infarction during pregnancy and the puerperium^[1,2,14-16]. The left coronary artery is most commonly affected and the dissection typically arises within 2 cm of the coronary ostium^[3]. About a hundred cases of spontaneous coronary artery dissection have been described, 75% of which were in women. About one third of these happened in the post partum period, between 1 day and 4 months following delivery. We found 28 cases of peripartum spontaneous coronary artery dissection in the literature. In only 11 of these was the diagnosis made ante mortem. Therapeutic approaches have ranged from heart-transplantation in two subjects^[11,12], to coronary artery bypass grafting^[4,6], and PTCA^[9]. One subject treated with a thrombolytic agent died shortly after the infarction^[2], while another patient, in whom thrombectomy was performed 2 weeks post partum, made a full recovery^[7]. The remaining four patients were treated conservatively: one of whom died after 4 years^[1,5,8,10].

Several hypotheses have been put forward to explain why spontaneous coronary artery dissection has such a predilection for pregnant women. Hormonal changes and haemodynamic stresses related to pregnancy, labour and delivery have been implicated and documented^[17]. In one patient with post partum spontaneous coronary artery dissection, a reduced total collagen synthesis was

Submitted for publication on 8 June 1993, and in revised form 5 April 1994.

Correspondence: Jaap W. Deckers, MD, Thoraxcenter, Division of Cardiology, Erasmus University and University Hospital 'Dijkzigt', Dr Molewaterplein 40, 3015 GD Rotterdam, The Netherlands.

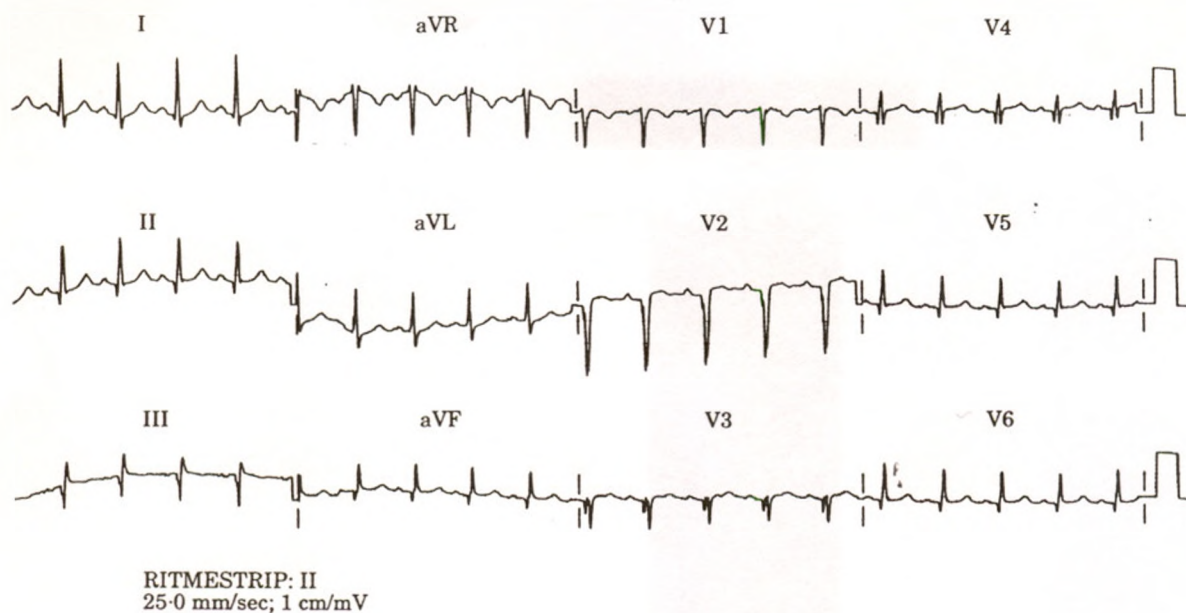


Figure 1 The electrocardiogram recorded on admission. For details, see text.

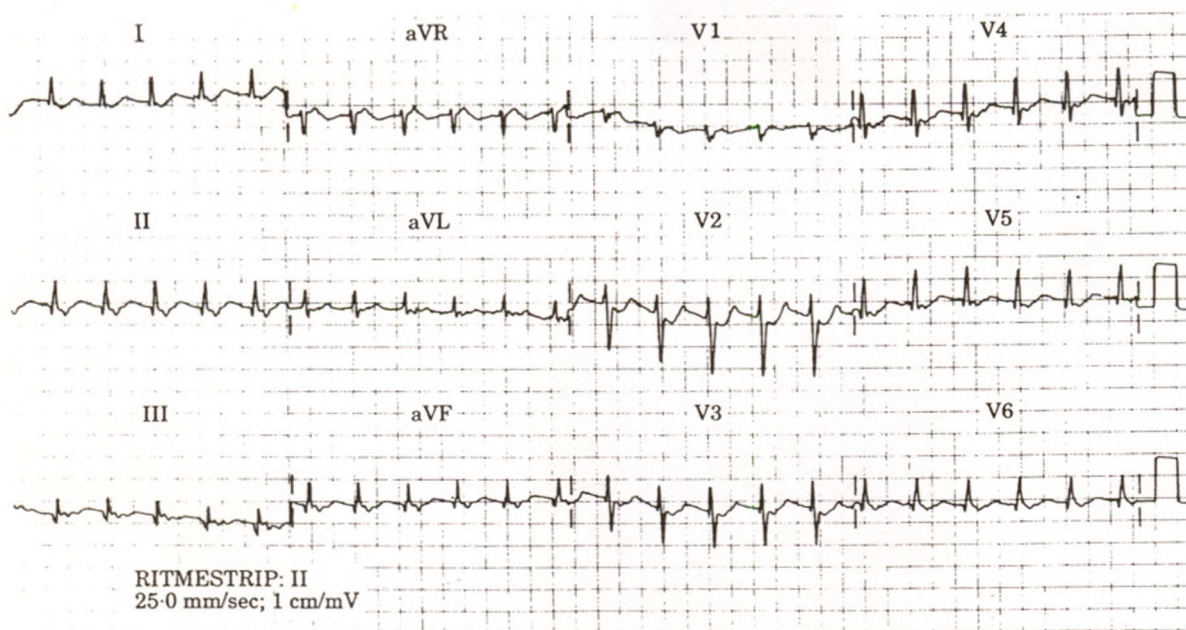
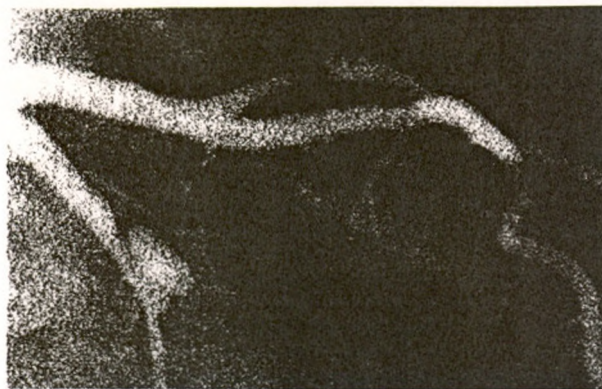

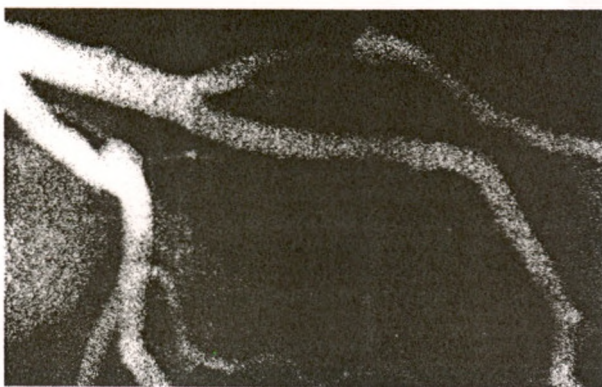
Figure 2 The electrocardiogram recorded at the time of the second myocardial infarction.

found in cultured skin fibroblast^[6]. However, it is unknown whether these in vitro observations truly reflect physiological changes. An eosinophilic infiltrate in the adventitia has been described in eight patients who died from spontaneous coronary artery dissection and a cause and effect relationship was suggested^[13]. This observation was not confirmed in later cases, notably not in the two subjects undergoing heart transplantation^[11,12,18]. Lastly, because degenerative changes observed in the media of the vessel wall at the

dissection sites resemble the characteristic pathological signs of cystic necrosis, a genetic defect predisposing to cystic medial necrosis has been suggested^[19]. However, such histopathological changes in the vessel wall are minimal and have not consistently been found in all cases^[20]. The most likely explanation for spontaneous coronary artery dissection during or shortly after pregnancy seems to be the induction of morphological changes of the arterial wall by hormonal influences or connective tissue.



(a)



(b)

Figure 3 Coronary angiogram obtained 1 day after delivery, demonstrating dissections in the left circumflex and the diagonal branch of the left anterior descending coronary artery (at right). (b) Coronary angiogram at 6 months demonstrates that the dissections, although still discernible, have healed.

Our patient is the first non-surgically treated survivor of spontaneous coronary artery dissection provoking acute myocardial infarction prior to delivery^[21]. The management of patients with spontaneous coronary artery dissection has been extremely variable. The present case history illustrates that spontaneous cure of coronary dissection can occur and that, in the absence of ongoing ischemia or severe left ventricular impairment, some patients with coronary artery dissection can be managed with medical therapy.

The authors thank Mrs Cecile Sweers-Kuijper and Dr David P. Foley for their help.

References

- [1] DeMaio SJ, Kinsella SH, Silverman ME. Clinical course and long-term prognosis of spontaneous coronary artery dissection. *Am J Cardiol* 1989; 64: 471-4.
- [2] Mattfeldt T, Schwarz F, Kubler W. Isolierte spontane koronararterien-dissektion. *Klin wochschr* 1986; 64: 186-93.
- [3] Thayer JO, Healy RW, Maggs PR. Spontaneous coronary artery dissection. *Ann Thorac Surg* 1987; 44: 97-102.
- [4] Razavi M. Unusual forms of coronary artery disease. *Cardiovasc Clin* 1975; 7: 25-46.
- [5] Shaver PJ, Carrig TF, Baker WP. Postpartum coronary artery dissection. *Br Heart J* 1978; 40: 83-6.
- [6] Bonnett J, Aumailley M, Thomas D, Grosgeat Y, Broustet JP, Bricaud H. Spontaneous coronary artery dissection: Case report and evidence for a defect in collagen metabolism. *Eur Heart J* 1986; 7: 904-9.
- [7] Vicari R, Eybel C, Monson D. Survival following spontaneous coronary artery dissection: Surgical repair by extraction of intramural hematoma. *Am Heart J* 1986; 111: 593-4.
- [8] Nishikawa H, Nakanishi S, Nishiyama S, Nishimura S, Seki A, Yamaguchi H. Primary coronary artery dissection observed at coronary angiography. *Am J Cardiol* 1988; 61: 645-61.
- [9] Gonzalez JJ, Hill JA, Conti CR. Spontaneous coronary artery dissection treated with percutaneous transluminal angioplasty. *Am J Cardiol* 1989; 63: 885-6.
- [10] Lette J, Gagnon A, Cerino M, Prenovault P. Apical hypertrophic cardiomyopathy with spontaneous post partum coronary artery dissection. *Can J Cardiol* 1989; 5: 311-4.
- [11] Movsesian MA, Wray RB. Postpartum myocardial infarction. *Br Heart J* 1989; 62: 154-6.
- [12] Curiel P, Spinelli G, Petrella A, et al. Postpartum coronary artery dissection followed by heart transplantation. *Am J Obstet Gynecol* 1990; 163: 538-9.
- [13] Robinowitz M, Virmani R, McAllister H. Spontaneous coronary dissection and eosinophilic inflammation: A cause and effect relationship? *Am J Med* 1982; 72: 923-8.
- [14] Hands ME, Johnson MD, Saltzman DH, Rutherford JD. The cardiac, obstetric, and anesthetic management of pregnancy complicated by acute myocardial infarction. *J Clin Anesth* 1990; 2: 258-68.
- [15] Hankins GDV, Wendel GD, Leveno KL, Stoneham J. Myocardial infarction during pregnancy: a review. *Obstet Gynecol* 1985; 65: 139-46.
- [16] Samra D, Samra Y, Hertz M, Maier M. Acute myocardial infarction in pregnancy and puerperium. *Cardiology* 1989; 76: 455-60.
- [17] Manalo-Estrella P, Barker AN, Evanston BS. Histopathologic findings in human aortic media associated with pregnancy. *Arch Pat* 1967; 83: 336-41.
- [18] Dowling GP, Buja LM. Spontaneous coronary artery dissection occurs with and without periadventitial inflammation. *Arch Pathol Lab Med* 1987; 111: 470-2.
- [19] Smith JC. Dissecting aneurysms of coronary arteries. *Arch Pathol* 1975; 117-21.
- [20] Geswend J, Amann FW, Steinbrunn W. Die isolierte spontane koronar dissektion. *Schweiz Med Wschr* 1989; 119: 1875-8.
- [21] Hayden J, Mort T, Rintel T. Acute coronary dissection during pregnancy. *Int J Obstet Anesth* 1991; 1: 43-5.