

PDF hosted at the Radboud Repository of the Radboud University Nijmegen

The following full text is a publisher's version.

For additional information about this publication click this link.

<http://hdl.handle.net/2066/86673>

Please be advised that this information was generated on 2017-12-06 and may be subject to change.

EHD 00832

Fetal blood flow velocity waveforms in relation to changing peripheral vascular resistance

M.J. Noordam^a, J.W. Wladimiroff^a, F.K. Lotgering^a,
P.C. Struijk^b and H.M. Tonge^a

^aDepartment of Obstetrics & Gynaecology and ^bDepartment of Central Research, Erasmus
University Rotterdam, The Netherlands

Accepted for publication 8 December 1986

Summary

In an acute experiment in Texel ewes, Doppler flow velocity waveforms from the fetal descending aorta were related to peripheral vascular resistance as calculated from perfusion pressure divided by electromagnetically measured volume flow in the descending aorta. Vascular resistance was increased by stepwise embolization of the peripheral circulation via repeated bolus administration of Sephadex G-25 microspheres. A rise in peripheral vascular resistance was associated with a reduction in peak and end-diastolic flow velocity and an increase in Pulsatility Index. Clinically, if similar changes are observed in growth retarded fetuses, the findings are usually interpreted to represent 'uteroplacental insufficiency'. Present data provide direct evidence that raised peripheral vascular resistance does indeed produce such waveform changes.

Doppler flow velocity waveform; peripheral vascular resistance; placental embolization

Introduction

Several clinical studies, in which pulsed Doppler Ultrasound equipment was used, suggest that an increase in peripheral vascular resistance (PVR) at the level

Address for correspondence: J.W. Wladimiroff, M.D., Professor of Obstetrics & Gynaecology, Academic Hospital Rotterdam-Dijkzigt, Erasmus University Rotterdam, Dr. Molewaterplein 40, 3015 GD Rotterdam, The Netherlands.

of the placenta results in characteristic changes in the blood flow velocity waveform in the descending aorta of the human fetus [5,6,9]. These changes are a lowering or absence of the (EDV) and an elevation of the Pulsatility Index (PI). Although lowering or absence of the EDV in the umbilical artery has been closely associated with obliteration of small muscular arteries in the tertiary stem villi of the placenta [2], the assumption that these flow changes reflect largely an increase in PVR has not been validated. For obvious ethical and technical reasons PVR can neither be experimentally modified nor calculated in the human fetus.

In an effort to attribute some experimental evidence, we studied the effect of increased PVR by acute stepwise embolization of the lower body vascular bed on the blood flow velocity waveform in the fetal lamb descending aorta.

Material and Methods

Animals

Five Texel ewes with singleton pregnancies were studied at 120–135 days of gestation (term 147 days). At autopsy mean total fetal weight was 2.9 ± 0.8 kg. All animals appeared healthy and unstressed at the onset of the experiments.

Surgery

After induction of anaesthesia with Ketamine hydrochloride (1000 mg), atropin (0.5 mg) and phenobarbital sodium (300 mg) intravenously, the ewes were intubated. Throughout surgery they were ventilated with a mixture of nitrous oxide (4:1) and oxygen (2:1) supplemented by enflurane (0.5–2 vol.%). Following laparotomy and hysterotomy, one catheter was inserted into the fetal descending aorta and one into the inferior vena cava via vessels in the hind limbs. Through an incision in the fetal flank, a precalibrated right-angled electromagnetic flow probe (Skalar Instruments, Delft, The Netherlands) of appropriate size (5–7 mm i.d.) was placed around the fetal descending aorta, 1 cm above the bifurcation. The incisions in the fetus, the membranes and the uterus were closed.

Experiments

The experiments were commenced 15–30 min following closure of the uterus. No bloodgas samples were taken. Descending aortic blood flow was measured continuously from the electromagnetic flow probe and blood pressure recordings were taken from the descending aorta and inferior vena cava. PVR (mm Hg/ml/kg/s) was calculated from the perfusion pressure (mm Hg) divided by blood flow volume (ml/kg/s) and averaged over a period of 5 s using a computer (Digital PDP 11/70 BMDP).

A combined linear-array real-time scanner and pulsed Doppler system [1] was used for the recording of the blood flow velocity in the fetal descending aorta immediately above the electromagnetic flow meter, which could be visualized on the 2D real-time image. The blood flow velocity waveform was recorded during fetal apnoea, over a 5-s period, which included an average of 15–20 consecutive cardiac cycles. In each flow velocity recording at least ten optimal cardiac cycles

TABLE I

PVR before and after repeated embolizations of the peripheral vascular bed

Lamb pressure no.	No. of Sephadex administration	No. of flow measurements	Fetal wt. (kg)	Perfusion pressure (mm Hg)		Aortic volume flow (ml/kg/s)		PVR (mm Hg/ml/kg/s)	
				Control	Final	Control	Final	Control	Final
1	3	8	3.7	68	89	2.3	1.1	7.9	21.7
2	3	10	2.7	54	65	3.3	3.0	6.1	7.9
3	7	18	3.8	40	55	4.6	2.8	2.3	5.2
4	12	35	2.2	51	51	2.4	1.0	9.6	24.3
5	9	26	2.2	71	79	2.2	1.4	14.5	25.5

were selected and the mean value for the peak velocity (PV, cm/s), time-averaged velocity (AV, cm/s), end-diastolic velocity (EDV, cm/s) and instantaneous fetal heart rate (FHR) was calculated using an Apple microcomputer. The PI was calculated according to Gossling and King [3].

Embolization of the placental circulation was achieved by repeated bolus injections of Sephadex G-25 microspheres (particle size, 20 μ m), 12.5 mg suspended in 1 ml 0.9% saline solution [8] via the pressure catheter situated in the descending aorta. The time interval between subsequent Sephadex administrations was determined by the return of a steady state situation for all measured parameters over a period of at least 15 min following a bolus Sephadex injection. During this steady state period a maximum of four pressure and flow recordings for further analysis was obtained.

Results

Tables I and II present for each fetal lamb the control and final data for all measured variables. Control values showed a wide variation between individual

TABLE II

Flow velocity waveform characteristics before and after repeated embolizations of the peripheral vascular bed

Lamb no.	PV (cm/s)		EDV (cm/s)		AV (cm/s)		PI	
	Control	Final	Control	Final	Control	Final	Control	Final
1	66	48	7	-10	25	10	2.4	5.8
2	70	56	14	-1	30	22	1.9	2.6
3	57	35	15	2	31	15	1.4	2.2
4	41	32	4	-3	16	8	2.3	4.4
5	46	30	6	-1	19	3	2.1	10.3

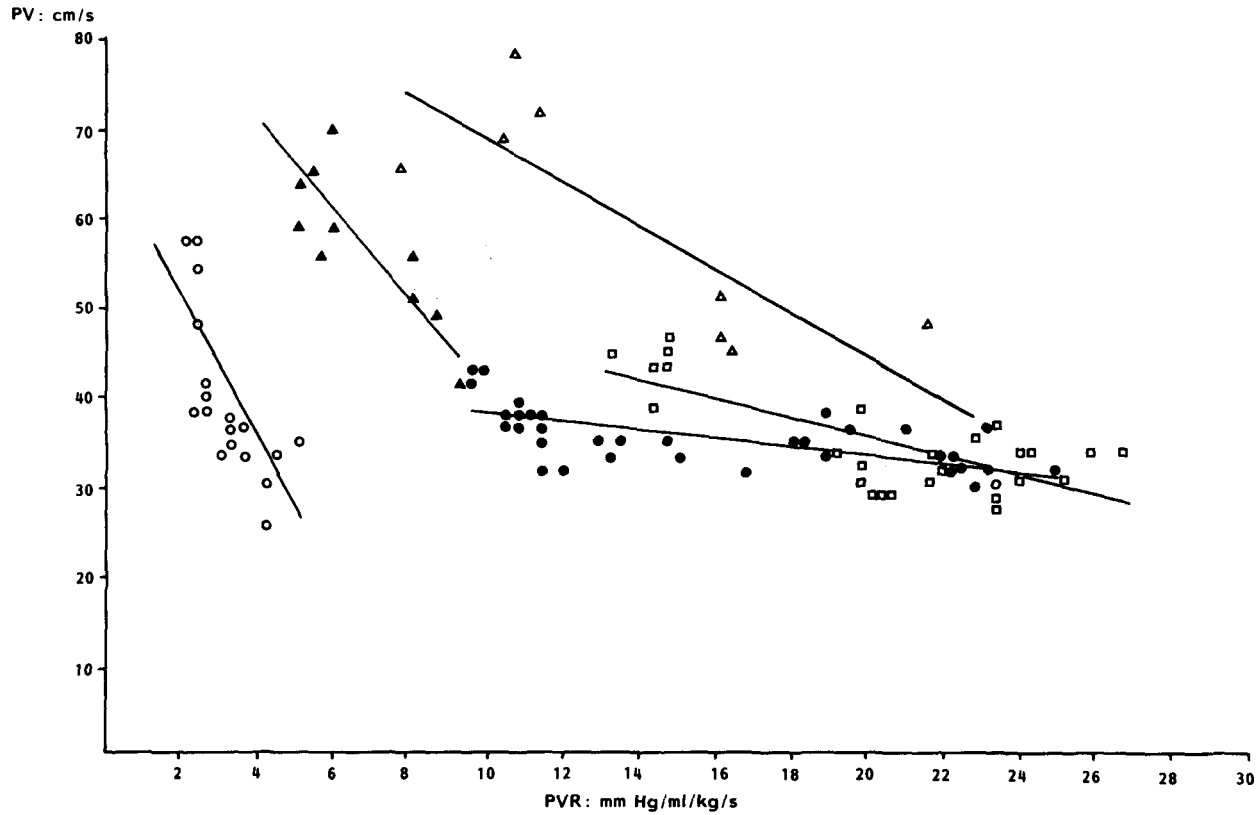


Fig. 1. PV vs. PVR; regression lines for individual lambs. △, lamb 1; ▲, lamb 2; ○, lamb 3; ●, lamb 4; □, lamb 5.

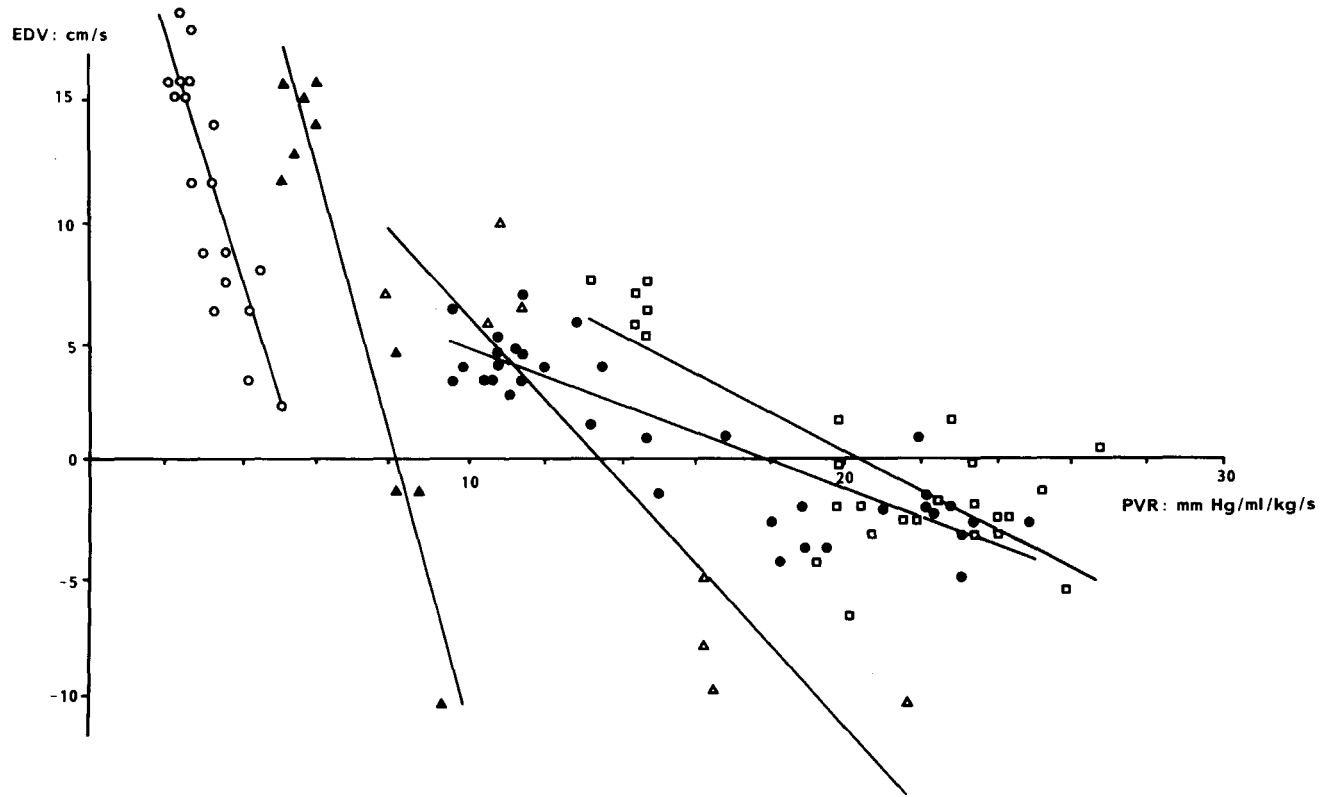


Fig. 2. EDV vs. PVR; regression lines for individual lambs. Δ , lamb 1; \blacktriangle , lamb 2; \circ , lamb 3; \bullet , lamb 4; \square , lamb 5.

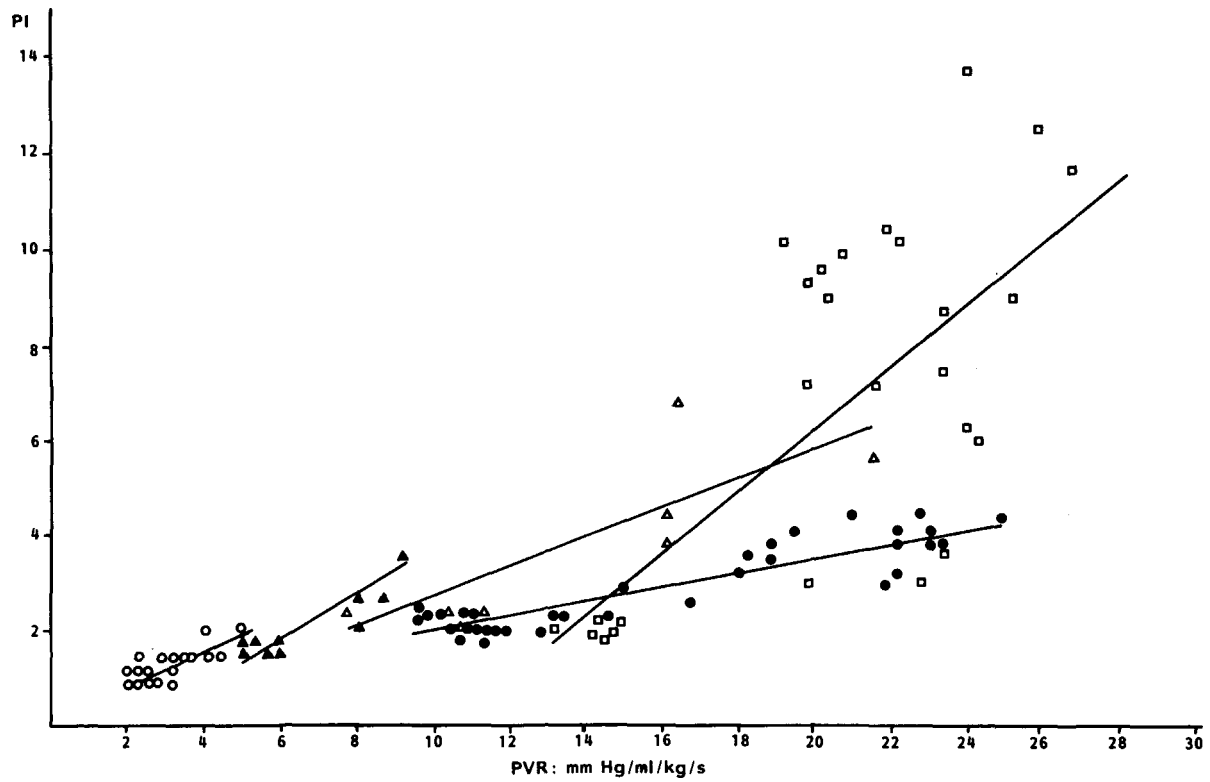


Fig. 3. PI vs. PVR; regression lines for individual lambs. Δ , lamb 1; \blacktriangle , lamb 2; \circ , lamb 3; \bullet , lamb 4; \square , lamb 5.

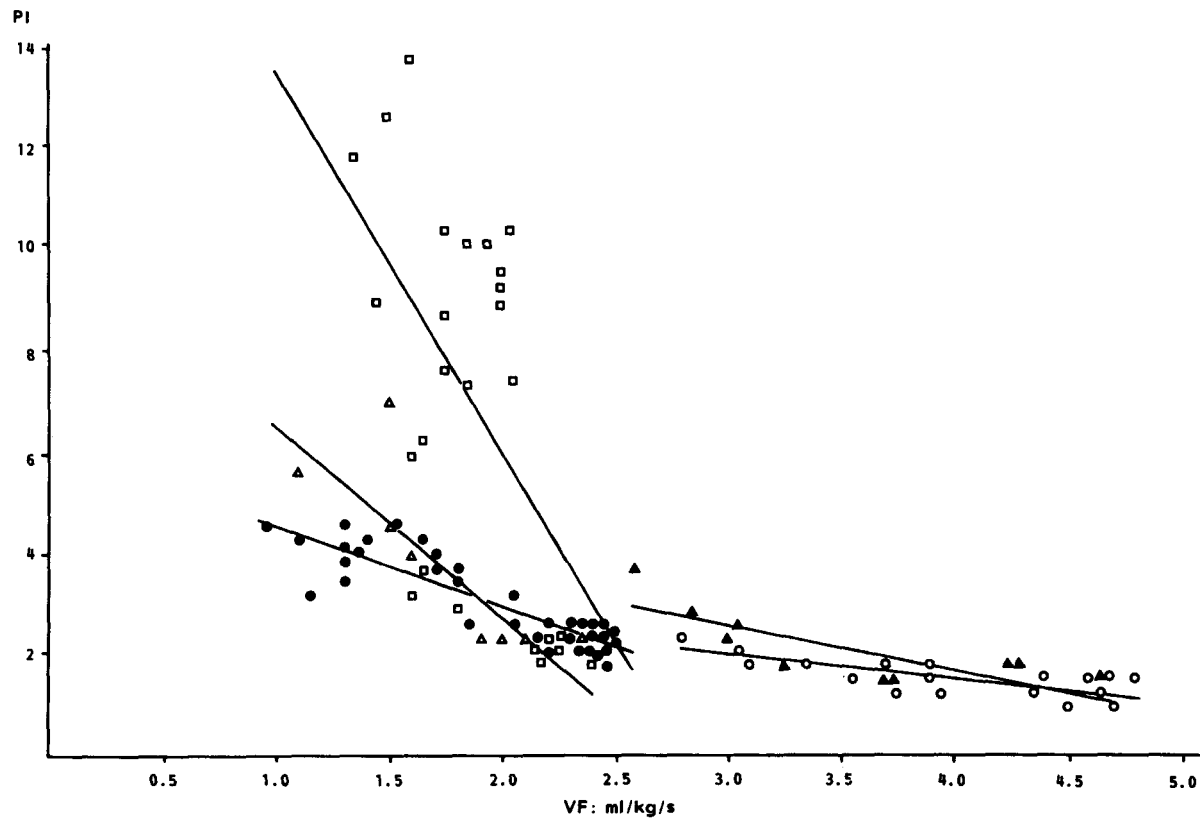


Fig. 4. PI vs. VF; regression lines for individual lambs. Δ , lamb 1; \blacktriangle , lamb 2; \circ , lamb 3; \bullet , lamb 4; \square , lamb 5.

lamb for all blood flow velocity parameters, perfusion pressure and flow and therefore PVR. Stepwise placental embolization resulted in a gradual increase in PVR, because perfusion pressure increased and aortic volume flow decreased. Of the flow velocity waveforms, PV, AV, and EDV showed gradual reductions, while PI increased. Figures 1–4 depict for each fetal lamb the actual data and calculated regression line for the correlation PV/PVR (Fig. 1); EDV/PVR (Fig. 2); PI/PVR (Fig. 3) and the correlation PI/volume flow (VF) (Fig. 4). In each fetal lamb PVR displays a negative correlation with PV ($P < 0.01$) and EDV ($P < 0.001$) and a positive correlation with PI ($P < 0.01$). A negative correlation ($P < 0.01$) was found between PI and VF.

Discussion

The need for verification and deeper understanding of non-invasive Doppler ultrasound measurements of human fetal volume flow and arterial flow velocity waveforms has led to a number of recent animal studies. In an acute experiment on exteriorized fetal lambs [7] cord occlusion was followed by a marked rise in aortic PI. It was demonstrated in a chronic fetal lamb experiment [10] that placental embolization over a period of 9 days resulted in an increase in the umbilical artery systolic/diastolic ratio of the velocity waveform. Resistance did not change significantly, which suggests that flow velocity waveform systolic/diastolic ratio measures peripheral wave reflection and outflow only. The shape of the aortic blood flow velocity waveform is thought to be mainly determined by the interaction of the forward pressure wave caused by cardiac systole and reflected waves from the peripheral arteriolar bed [4]. In the fetal descending aorta the indices of PVR are affected by the resistance in the visceral vascular bed, the lower extremities and the placenta. Forward flow during end-diastole has been documented by others, both in the human fetus [1,5,6,9] and in the fetal lamb [7,10]. The observed positive EDV (4–15 cm/s) prior to placental embolization in the present study reflects the continuous perfusion which results from low resistance. In the human fetus peak velocity levels below 50–55 cm/s and reverse end-diastolic flow in the lower thoracic part of the fetal descending aorta are generally associated with a poor fetal outcome [9]. In two of our fetuses (Nos. 4 and 5) control levels for peak velocity were below 50 cm/s. One might speculate that these two fetal lambs may already have been compromised to some degree at the onset of the study.

As expected, the PI in the fetal descending aorta was inversely related to the volume flow. Volume flow levels below 2.0–3.0 ml/kg/s fetal body weight in three fetuses were associated with a more pronounced rise in PI than was observed in the other two fetuses (Nos. 2 and 3) with higher volume flow levels and lower levels of PVR (Figs. 3 and 4). Although this may suggest that the PI rises more sharply at higher levels of vascular resistance, further studies are needed to substantiate this suggestion.

Our data demonstrate that increased PVR brought about by stepwise placental

embolization results in a reduction in peak and EDV and a rise in PI in the fetal descending aorta. This suggests that similar changes in the flow velocity waveform in the human fetal descending aorta in the presence of 'uteroplacental insufficiency' may indeed be determined by raised PVR.

Acknowledgements

Financial support for this study was obtained from the "Oranje Stichting", The Hague, The Netherlands.

References

- 1 Eik-nes, S.H., Brubakk, A.O. and Ulstein, M.K. (1980): Measurement of human fetal blood flow. *Br. Med. J.*, 1, 283-284.
- 2 Giles, W.B., Trudinger, B.J. and Baird, Ph.J. (1985): Fetal umbilical artery flow velocity waveforms and placental resistance: pathological correlation. *Br. J. Obstet. Gynaecol.*, 92, 31-38.
- 3 Gosling, R.G. and King, D.H. (1975): Ultrasound Angiology. In: *Arteries and Veins*, pp. 61-98. Editors: A.W. Marcus and L. Adamson. Churchill Livingstone, Edinburgh.
- 4 Gosling, R.G. (1976): Extraction of physiological information from spectrum analysed Doppler shifted Ultrasound signals obtained noninvasively from the arterial system. In: *Institute of Electrical Engineers Medical Electronics Monograph 21*, pp. 73-125. Peter Perogramis, Stevenage.
- 5 Griffin, D., Bilardo, K., Masini, L. et al. (1984): Doppler blood flow waveforms in the descending thoracic aorta of the human fetus. *Br. J. Obstet. Gynaecol.*, 91, 997-1006.
- 6 Jouppila, P. and Kirkinen, P. (1984): Increased vascular resistance in the descending aorta of the human fetus in hypoxia. *Br. J. Obstet. Gynaecol.*, 91, 853-860.
- 7 Lingman, G., Marsal, K., Rozen, K.G. and Kjellmer, I. (1986): Blood flow measurements in exteriorized lamb fetuses during asphyxia. In: *Doppler Techniques in Obstetrics, International Workshop Aachen, 1984*, pp. 36-40. Editors: H. Jung and H. Fendel. George Verlag, Stuttgart.
- 8 Stam, H. and De Jong, J.W. (1977): Sephadex-induced reduction of coronary flow in the isolated rat heart: a model for ischemic heart disease. *J. Mol. Cell. Cardiol.*, 9, 633-650.
- 9 Tonge, H.M., Wladimiroff, J.W., Noordam, M.J. and van Kooten, C. (1986): Blood flow velocity waveforms in the descending aorta of the human fetus in the third trimester of pregnancy: comparison between normal and growth-retarded fetuses. *Obstet. Gynaecol.*, 67, 851-855.
- 10 Trudinger, B.J. (1986): The effect of umbilical artery embolization on the flow velocity waveforms and resistance. In: *Abstractbook Satellite Symposium Fetal Physiology-Cellular and systems approaches. Vancouver Island, British Columbia, July 8-12.*