

## PDF hosted at the Radboud Repository of the Radboud University Nijmegen

The following full text is a publisher's version.

For additional information about this publication click this link.

<http://hdl.handle.net/2066/81671>

Please be advised that this information was generated on 2018-07-08 and may be subject to change.

## CASE REPORT

# RETRACTION OF AN INTRATHECAL BACLOFEN INFUSION CATHETER FOLLOWING SUPRAPUBIC CYSTOTOMY: A CASE REPORT

Frank M. J. Martens, MD<sup>1</sup>, Diederik M. Somford, MD<sup>1</sup>, Dirk H. J. M. van Kuppevelt, MD<sup>2</sup>,  
Monica J. M. van der Burg, MANP<sup>2</sup> and John P. F. A. Heesakkers, MD, PhD<sup>1</sup>

From the <sup>1</sup>Radboud University Nijmegen Medical Centre and <sup>2</sup>St. Maartenskliniek Nijmegen, Nijmegen, The Netherlands

**Introduction:** Intrathecal baclofen, administered via a Baclofen pump, is used for patients with spasticity. We report here a case of intrathecal catheter retraction following surgery.

**Case report:** A male patient with adrenoleukodystrophy and a baclofen pump implant was admitted to the urology department with bladder stones. A transurethral cystolithotripsy and a suprapubic cystotomy were performed. Following surgery there was no adequate spasm control. Plain abdominal X-ray showed complete retraction of the catheter out of the intrathecal space.

**Discussion:** Intrathecal catheter retraction after surgery has been reported in a few cases. The retraction in this case did not seem to be due to the suprapubic cystotomy itself, but was more likely due to the positioning of the patient for cystoscopy and surgery, combined with possible loosening of the anchoring of the catheter.

**Conclusion:** Specific attention should be paid to the positioning of patients before surgery in order to avoid intrathecal baclofen catheter withdrawal.

**Key words:** baclofen, intrathecal catheter, urinary bladder calculi, cystolithotripsy, operative surgical procedures.

J Rehabil Med 2009; 41: 90–91

*Correspondence address:* Frank M. J. Martens, Radboud University Nijmegen Medical Centre, Urology (659), PO Box 9101, NL-6500 HB Nijmegen, The Netherlands. E-mail: F.Martens@uro.umcn.nl

Submitted April 28, 2008; accepted September 2, 2008

## INTRODUCTION

Intrathecal baclofen can be used to treat disabling muscle spasms in neurogenic patients when oral spasmolytic agents are insufficient. Incomplete bladder emptying due to detrusor-external sphincter dyssynergy or a hypo-contractile bladder may require an indwelling catheter. However, this predisposes to bladder stones. For example, the 5-year cumulative incidence rate of an initial bladder stone from 1990 to 1996 in patients with spinal cord injury was reported to be 8% (1). We report here a patient with retraction of the intrathecal catheter of his baclofen device, probably caused by positioning of the patient for bladder stone surgery combined with loosening of the catheter anchoring.

## CASE REPORT

A 26-year-old male patient with adrenoleukodystrophy with bipyramidal syndrome who was a wheelchair user had had a suprapubic catheter for 4 years. A synchroMed Baclofen pump type II (Medtronic, Minneapolis, Minnesota, USA) was implanted because of severe muscle spasms without adequate response to oral medication. After initial implantation of the device the intrathecal catheter became disconnected. Revision of the system was performed. Afterwards the spasms were well controlled with a Baclofen dosage of 44 µg/day. Liquor leakage was diagnosed and treated twice using a blood patch.

One month later 2 urinary bladder stones were diagnosed on X-ray, which also showed correct positioning of the intrathecal catheter. The bladder stones were confirmed by cystoscopy and the patient was admitted for surgical cystolithotripsy. Transurethral removal of the stones was found to be impossible due to their size and hardness. Therefore, in the same session a suprapubic cystotomy was performed using a Pfannenstiel incision in the supine position. The Baclofen device in the lower right quadrant of the abdominal wall was carefully avoided. The bladder stones were removed successfully. Immediately after surgery spasticity was at the same level as before pump implantation. Because an increase in spasticity after surgery is normal the daily dose was raised several times. Three weeks after surgery the required intrathecal Baclofen dosage had been increased to 53 µg/day with no reduction in spasms. A failure of the device was suspected. Retraction of the intrathecal catheter was observed on X-ray, with the catheter coiled at the level of L2 (Fig. 1).

## DISCUSSION

Retraction of the intrathecal catheter for baclofen infusion is known to occur (2, 3). An online published case report presented a patient with vesical calculi, which were initially thought to elicit increased spasticity (3). However, the spasms did not decrease after stone removal. A new X-ray and revision of the preoperative X-ray showed a retracted and coiled catheter at level L4. Two cases of dislocation of the catheter after surgery have been reported to the manufacturer; one after hysterectomy and another after laparoscopic cholecystectomy.

The mechanism of retraction of an intrathecal catheter during surgery remains unknown. In our case, the intrathecal part of

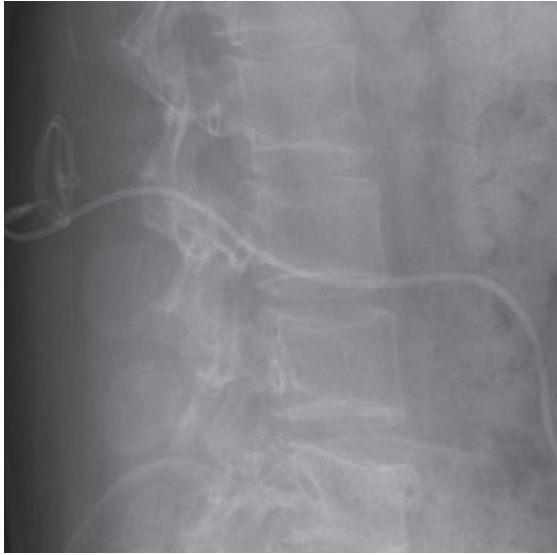


Fig. 1. X-ray following a suprapubic cystotomy, showing no disconnection. The intrathecal catheter is retracted and curled at the level of L2.

the system was retracted and curled at L2. Therefore, no direct traction to the abdominal part of the catheter device seems to have been involved. The normal body movements of the patient in his wheelchair may have predisposed to the retraction from the intrathecal space due to rubbing on bony structures. It is possible that the positioning of the anaesthetized patient during the cystoscopy and suprapubic cystotomy was causative. In particular, a reduction in lordosis of the spine might evoke catheter retraction. The patient has recently been operated on to reposition the intrathecal catheter. It was thought that the dislocation of the catheter was caused by loosening of the anchoring. A combination of positioning for surgery and anchoring weakness is also a possibility.

In order to prevent retraction of an intrathecal catheter, positioning of the patient for surgery should be carried out with care and unnecessary movements should be avoided. Avoiding

a reduction in lordosis of the lumbar spine might help to prevent a retraction. The decision to perform a suprapubic cystotomy should perhaps have been taken during cystoscopy in the outpatient clinic. In general, surgeons need to be well informed about the presence of an intrathecal catheter for Baclofen infusion and ensure careful handling of the patient.

Following surgery one needs to be alert for withdrawal syndrome as a symptom of intrathecal catheter retraction (4). Symptoms of withdrawal syndrome include severe spasticity, headache, disorientation, seizures, hallucination, itching and fever. Physicians should be aware that these symptoms could be due to a retraction or disconnection of the intrathecal catheter. X-ray control should be performed without reluctance if retraction or disconnection of the intrathecal catheter is suspected.

In conclusion, retraction of an intrathecal catheter due to positioning and surgery is an uncommon event, but is possible. Specific attention should be paid to the positioning of these patients. Avoiding a reduction in lordosis of the lumbar spine might help to prevent such a retraction. Physicians who observe increasing spasms after surgery in patients receiving intrathecal spasmolytic infusion should be aware of this possible complication.

#### REFERENCES

1. Chen Y, DeVivo MJ, Lloyd LK. Bladder stone incidence in persons with spinal cord injury: determinants and trends, 1973–1996. *Urology* 2001; 58: 665–670.
2. Albright AL. Intrathecal baclofen for childhood hypertonia. *Childs Nerv Syst* 2007; 23: 971–979.
3. Vaidyanathan S, Soni BM, Oo T, Hughes PL, Singh G, Watt JWH, et al. Bladder stones – red herring for resurgence of spasticity in a spinal cord injury patient with implantation of Medtronic Synchromed pump for intrathecal delivery of baclofen – a case report. *VMC Urology* 2003; 3:3. Epub 2003 Mar 25.
4. Coffey RJ, Edgar TS, Francisco GE, Graziani V, Meythaler JM, Ridgely PM, et al. Abrupt withdrawal from intrathecal baclofen: recognition and management of a potentially life-threatening syndrome. *Arch Phys Med Rehabil* 2002; 83: 735–741.