

## PDF hosted at the Radboud Repository of the Radboud University Nijmegen

The following full text is a publisher's version.

For additional information about this publication click this link.

<http://hdl.handle.net/2066/81151>

Please be advised that this information was generated on 2017-12-06 and may be subject to change.

## Three dimensional measurement of rhinoplasty results\*

Niels van Heerbeek<sup>1</sup>, Koen J.A.O. Ingels<sup>1</sup>, Bram van Loon<sup>2</sup>, Joanneke M. Plooij<sup>2</sup>, Stefaan J. Bergé<sup>2</sup>

<sup>1</sup> Department of Otorhinolaryngology, Head & Neck Surgery, Radboud University Nijmegen Medical Center, Nijmegen, the Netherlands

<sup>2</sup> Department of Oral and Maxillofacial Surgery, Radboud University Nijmegen Medical Center, Nijmegen, the Netherlands

### SUMMARY

**Background:** Pre- and postoperative imaging is important and essential for evaluation of the results of rhinoplasty surgery. Two-dimensional photographs are used routinely for this purpose, but have several disadvantages as opposed to three-dimensional imaging techniques, such as stereophotogrammetry. This study is the first to describe the measurement of rhinoplasty results using stereophotogrammetry. The aim of this study was to evaluate the ability of 3D imaging to measure and objectify rhinoplasty results.

**Methods:** During a 6-month period all consecutive hump reduction patients were included in this prospective study. Pre- and postoperative 3D photographs were taken and compared.

**Results:** Twelve patients were studied. In ten of these twelve patients a significant volume reduction in the area of the nasal dorsum was found with stereophotogrammetry. The maximum decrease (i.e. lowering) of the nasal dorsum ranged from 0.8 to 4.4 mm. In two patients no reduction of the nasal dorsum was found. In both patients this was due to additional changes made to the nose during surgery. These changes, increased tip rotation and dorsal augmentation respectively, were also documented with stereophotogrammetry.

**Conclusions:** Both pronounced as well as subtle postoperative changes of rhinoplasty surgery can be objectified and measured with stereophotogrammetry. This tool can be used to study whether surgical techniques have the desired effect on the nose, and to compare different techniques with each other.

**Key words:** rhinoplasty, hump reduction, nose, stereophotogrammetry, three dimensional, 3D, maxillofacial surgery

### INTRODUCTION

Pre- and postoperative standard and uniform (digital) colour photographs are important and essential for postoperative evaluation of the (long-term) results of rhinoplasty surgery. In addition, these photographs can be used for teaching and research purposes. Thus far, all studies describing objective changes after rhinoplasty are based on two-dimensional (2D) standardized photographs. This poses several potential problems. First, the pre- and postoperative pictures must be made in exactly the same way, i.e. from the same distance and with the head in an identical position to prevent over- or underestimation of absolute changes in for instance tip projection/rotation or width of the alar base. This problem may be overcome using relative measurements<sup>(1-3)</sup>, but these methods are more time-consuming and still liable to the second disadvantage of using normal pictures: the complex three-dimensional (3D) appearance of the nose is turned into 2D-pictures.

Recent advances in technology have generated several 3D-techniques to capture facial topography and overcome the deficiencies and problems encountered with conventional photographs<sup>(4,5)</sup>. One of these techniques is stereophotogrammetry<sup>(6,7)</sup>. Stereophotogrammetry is a technique that uses two or more cameras configured as pairs to capture multiple views of the face. These different views are used to form a 3D-photograph<sup>(8)</sup>. An early disadvantage of stereophotogrammetry has been its inaccuracy, but recently the technique has been improved resulting in high-quality, realistic 3D-photographs<sup>(8)</sup>. Nowadays pre- and postoperative 3D-photographs can be superimposed and the differences between the two surfaces can be compared to provide information about the results of surgery on facial appearance. This study is the first to describe the measurement of rhinoplasty effects using stereophotogrammetry. The aim of this study was to evaluate the ability of 3D-imaging to measure and objectify rhinoplasty results.

## METHODS

### *Surgical procedure*

Between September 2006 and April 2007 all rhinoplasty patients undergoing hump reduction were included in this prospective study. In all patients the operation was performed by one of the authors (KI or NvH). A detailed surgical report was kept to register if other surgical techniques (such as tip refining, septoplasty, et cetera) were used as well.

All rhinoplasty procedures were performed through an open approach. The open approach was chosen because both surgeons prefer this approach when more than just a hump reduction has to be performed, which was the case for all patients. The nasal dorsum was exposed immediately supraperichondrially and subperiostally. After the triangular cartilages had been detached from the nasal septum extramucosally and the nasal mucosa had been removed from the inner side of the nasal bones, a cartilaginous and/or bony hump reduction was done, followed by medial oblique osteotomies. Subsequently the lateral osteotomies were performed. Finally the nasal bones were infrafractured to close the open roof. The nasal dorsum was positioned in the midline and if necessary one or two spreader grafts were used to further align the nasal dorsum. After finishing the remainder of the procedure nasal packing and an adhesive thermoplastic nasal splint were applied.

### *3D-imaging (i.e. stereophotogrammetry)*

3D digital photographs were taken 1 day preoperatively and 6 months postoperatively in all patients. The 3D-photographs of the face were captured with a 3D stereophotogrammetrical camera setup and the Modular System v1.0 (3dMDface™ System, 3dMD Ltd, Atlanta, GA, USA) software program. The camera setup consists of two pods, each equipped with 3 digital cameras and a flash. Both pods acquire 2 sets of photos simultaneously: 2 photos with a pattern projected and a full-colour photo, resulting in a total of 6 facial pictures. The pattern is needed for the 3D surface reconstruction. As a result, a polygonal mesh with true colour texture information is obtained. Capture time was 2 milliseconds, which limited the risk of movement artefacts. Prior to its use, the camera was calibrated to define a 3D coordinate system for the 3D-photograph, which was referred to as the original 3D coordinate system. The obtained 6 facial pictures were reconstructed into one 3D stereophotogrammetrical photograph and automatically saved as a 'three-dimensional surface binary' file (.tsb file). The 3D-photographs were taken in natural head position with eyes open. Subsequently, the .tsb file was opened using the 3dMDpatient v2.0 (3DMDpatient™ Software Platform, 3dMD Ltd) software program and directly exported as a 'wavefront object' file (.obj file) to enable import of the 3D-object into Maxilim® version 2.0.1 (Medicim NV, Mechelen, Belgium). Without any editing the .obj file was saved as 'maxilim' file (.mxm file) for further use.

The surface based matching tool of the Maxilim® software was used to superimpose the pre- and postoperative 3D-pho-

Table 1. Step-by-step approach to matching the textured and untextured surfaces.

Step 1	Initial positioning of the 3D photographs by indicating landmarks on both images	Semi-automatic
Step 2	Excluding error regions	Manual
Step 3	Registration of the 3D photographs	Automatic
Step 4	Computation of distance map between superimposed 3D photographs	Automatic

tographs. A four step matching process was performed (Table 1). First, four easily reproducible, corresponding landmarks that were well spread over the facial surface were indicated on the pre- and postoperative 3D surfaces / 3D photographs. These landmarks were a base for surface matching and minimized the need for further initial translation and rotation of the surfaces. Second, the accuracy of the registration was improved by excluding regions that were obviously different, such as the nose itself, border of the hair, the neck, the eyes and eyelids and the mouth. Subsequently, rigid registration was used to register the pre- and postoperative skin surfaces with a 3D surface matching algorithm (Iterated Closest Point (ICP) algorithm). Finally, a distance map was calculated between both surfaces. This resulted in a colour-based image indicating unchanged (white areas), decreased (red discolouration) and increased (green discolouration) facial volumes. A higher intensity of discolouration corresponds with a larger change in facial volume. At the point of maximal reduction, indicated by the highest intensity of discolouration, the reduction of the nasal dorsum was calculated.

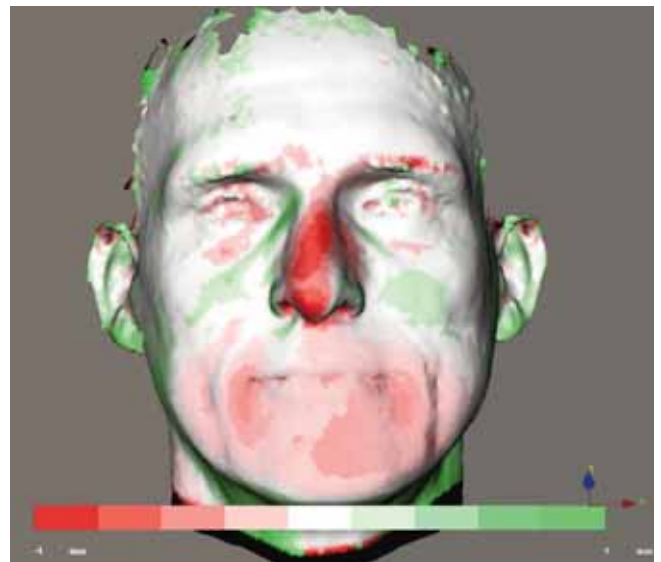


Figure 1. Example of colour based distance map that is the result of superimposing the pre- and postoperative photographs. In white areas with no difference between pre- and postoperative image are shown. Red discolouration indicates volume decrease and green discolouration indicates volume increase. Notice the distinct volume reduction in the area of nasal dorsum.

## RESULTS

Between September 2006 and April 2007 a hump reduction was performed in thirteen patients. One of these thirteen patients was lost to follow-up. The final study group consisted of five female and seven male patients with a mean age of 32.2 years (range 18.4 - 45.8). In all patients the hump reduction was combined with at least one other technique, e.g. placement of a strut or spreader graft, refinement of the tip or septoplasty. In ten out of our twelve patients a significant volume reduction in the area of the nasal dorsum was found after surgery. The decrease (i.e. lowering) of the nasal dorsum at the point of maximum reduction ranged from 0.8 to 4.4 mm with a median of 2.2 mm. Figure 1 shows an example of the colour-based image that is the result of the virtual subtraction of the preoperative photograph from the postoperative photograph. In white the areas are shown where no changes in volume had occurred. Red areas, such as the nasal dorsum, represent areas with reduced volumes 6 months after surgery. Green discolouration indicates an increase in volume. Green discolouration in the nasal area can be the result of additional techniques performed during rhinoplasty surgery, such as upward rotation of the tip. Discolouration, either green or red, in the remaining facial regions is considered to be the result of differences in facial posture at the moment of pre- and postoperative imaging. For instance, if a patient has even a slight difference in the position of the mandible pre- and postoperatively, this is immediately

detected as a change in volume in the region of the chin, neck and lips. The intensity, i.e. the degree, of redness and greenness corresponds with the amount of change in facial volume. The colour scale in Figure 1 displays these intensities together with the corresponding millimetres of increase or decrease.

In two patients no reduction of the nasal dorsum was found. In one patient with a saddle nose deformity a small bony hump was removed before a large cartilaginous dorsal onlay implant was placed. As expected and intended, a distinct increase in volume was found in the nasal dorsum region. This is shown as green discolouration of the nasal dorsum in Figure 2. The other patient without reduction of the nasal dorsum had a polly beak deformity prior to surgery. A very small cartilaginous pseudo hump was removed and subsequently the tip rotation was increased. In this patient no volume change was found in the dorsal region, probably due to the fact that the combination of these techniques led to straightening rather than lowering of the skin of the nasal dorsum. In addition, the increased rotation was shown as a volume increase in the supratip region and a volume decrease in the infratip region, shown in Figure 3.

## DISCUSSION

In aesthetic rhinoplasty patients indications can be roughly divided into: reduction rhinoplasty, in which the nose is made

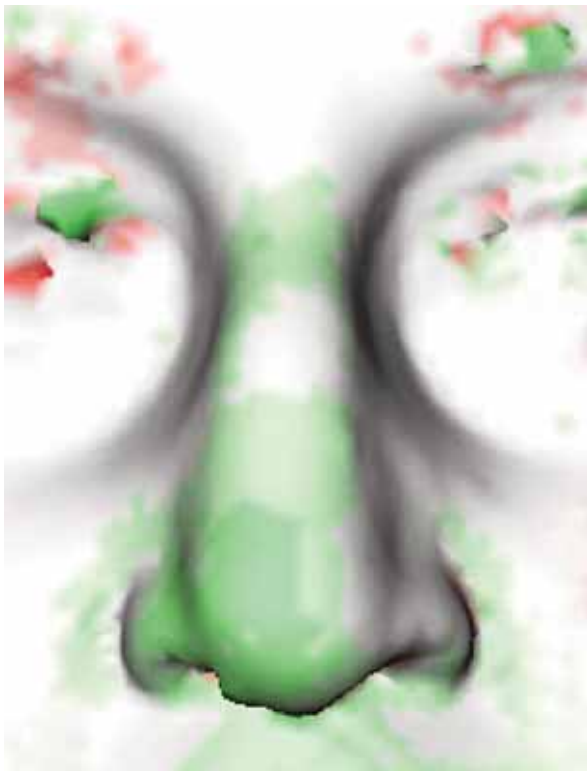

Figure 2. Patient with preoperative saddle nose deformity. Hump reduction was combined with dorsal onlay graft resulting in an increased nasal dorsal volume, shown as green discolouration of the nasal dorsum.

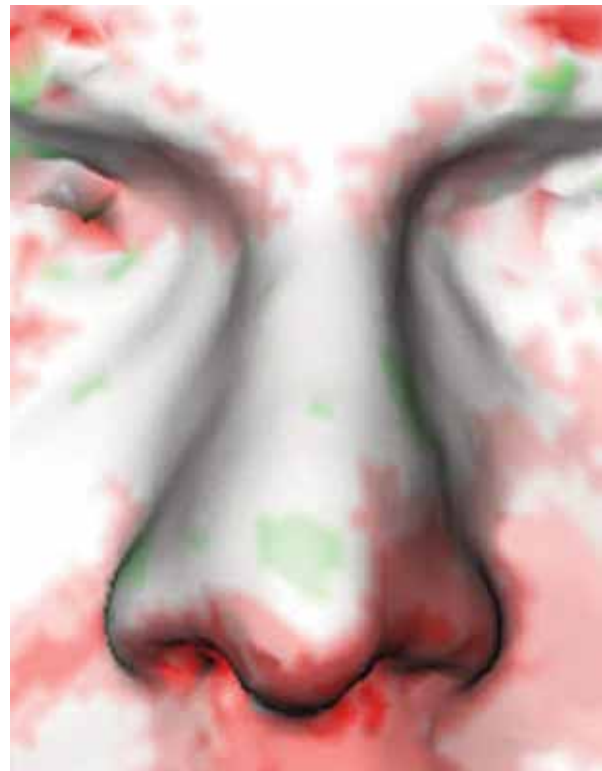

Figure 3. Patient with polly beak deformity and relative pseudo hump. The increased rotation of the tip is detected as a volume increase in the supratip region (green discolouration) and a volume decrease in the infratip region (red discolouration).

smaller, and augmentation rhinoplasty, in which the nose is enlarged. In addition, both reduction as well as augmentation techniques can be performed on the tip (e.g. removal of cephalic margin or suturing techniques and shield graft, respectively) and the nasal dorsum (e.g. hump reduction and dorsal onlay graft, respectively). As a general rule, changes made to the nasal dorsum are more distinct than changes made to the tip. Since the goal of this study was to determine whether rhinoplasty results can be measured with stereophotogrammetry, only patients with a more pronounced effect, i.e. patients with a hump reduction as part of their rhinoplasty procedure, were included in this study.

Rhinoplasty is one of the most challenging facial surgical procedures. A clear understanding of nasal anatomy is critical in order to provide an aesthetic result that does not compromise nasal function. Thorough analysis of the nose is vital for proper diagnosis and for determining the most appropriate treatment plan. This treatment plan often consists of numerous techniques. Each technique has a certain goal, e.g. placement of a strut to increase rotation or hump reduction to reduce the nasal dorsum. It is therefore very important to verify postoperatively whether a certain technique did as planned result in its matching result.

Several surgical techniques and their effects have been studied in the past<sup>(2,9-14)</sup>. Many of these studies have tried to establish objective methods to measure changes made to the nose. However, all these measurements were based on 2D-photographs. The nose is an outstanding example of a three-dimensional structure and changes made to the nose are hardly ever limited to two dimensions. These conclusions emphasize the need for a method of 3D-measurement of rhinoplasty results. With the development of stereophotogrammetry such a method has become available. In the present study stereophotogrammetry was used to capture 3D-photographs (3dMDface™ System) and a surface-based matching tool (Maxilim®) to analyze the nasal changes between pre- and postoperative 3D-photographs. Several studies have been reported describing the accuracy and reliability of 3D-imaging techniques to measure facial appearance<sup>(8,15-17)</sup>. They showed that the accuracy, reproducibility and reliability of the technique are high. The accuracy was found to be 0.5 mm. However, no study has yet been performed to determine the usefulness of 3D-imaging to measure and visualize rhinoplasty results.

This study describes that stereophotogrammetry is capable of, and useful for, measuring changes made to the nose by rhinoplasty surgery. In ten hump reduction patients a significant reduction of the nasal dorsal volume was found. The maximum reduction ranged from 0.8 to 4.4 mm. In two patients no reduction of the nasal dorsal volume was found. According to the surgical report both patients had undergone a hump reduc-

tion, but in one patient this concerned the reduction of a very small pseudo-hump combined with upward rotation of the tip and in the other patient a cartilaginous onlay graft was placed after the hump reduction. In addition to the distinct visualisation of the hump reduction in the other patients, these changes (i.e. rotation of the tip and augmentation of the nasal dorsum, respectively) were both also detected with stereophotogrammetry. This shows that the clinical postoperative findings can be objectified and measured with stereophotogrammetry and that the changes found correspond with the techniques performed. Even smaller changes made to the nose can be measured with stereophotogrammetry. Stereophotogrammetry can therefore be used to further objectify, measure and compare rhinoplasty results and to study whether certain surgical techniques indeed provide the desired effect on the appearance of the nose, especially in the long term. We are presently conducting a study to evaluate stereophotogrammetry for the comparison of the outcomes of different surgical techniques.

#### REFERENCES

1. Crumley RL, Lanser M. Quantitative analysis of nasal tip projection. *Laryngoscope* 1988; 98: 202-208.
2. Goode RL. A method of tip projection measurement. In: Powell N, Humphrey B, editors. *Proportions of the Aesthetic Face*. New York: Thieme-Stratton Inc; 1984. p. 15-39.
3. Erdem T, Ozturan O. Objective measurement of the deviated nose and a review of surgical techniques for correction. *Rhinology* 2008; 46: 56-61.
4. Hajeer MY, Millett DT, Ayoub AF, Siebert JP. Applications of 3D imaging in orthodontics: part I. *J Orthod* 2004; 31: 62-70.
5. Halazonetis DJ. Acquisition of 3-dimensional shapes from images. *Am J Orthod Dentofacial Orthop* 2001; 119: 556-560.
6. Beard LF, Burke PH. Evolution of a system of stereophotogrammetry for the study of facial morphology. *Med Biol Illus* 1967; 17: 20-25.
7. Burke PH, Beard FH. Stereophotogrammetry of the face. A preliminary investigation into the accuracy of a simplified system evolved for contour mapping by photography. *Am J Orthod* 1967; 53: 769-782.
8. Kau CH, Richmond S, Incrapera A, English J, Xia JJ. Three-dimensional surface acquisition systems for the study of facial morphology and their application to maxillofacial surgery. *Int J Med Robot* 2007; 3: 97-110.
9. Ingels K, Orhan KS. Measurement of preoperative and postoperative nasal tip projection and rotation. *Arch Facial Plast Surg* 2006; 8: 411-415.
10. Daudia A, Alkhaddour U, Sithole J, Mortimore S. A prospective objective study of the cosmetic sequelae of nasal septal surgery. *Acta Otolaryngol* 2006; 126: 1201-1205.
11. Okur E, Yildirim I, Aydogan B, Akif KM. Outcome of surgery for crooked nose: an objective method of evaluation. *Aesthetic Plast Surg* 2004; 28: 203-207.
12. Sharp HR, Rowe-Jones JM. Assessing outcome in aesthetic rhinoplasty. *Clin Otolaryngol Allied Sci* 2003; 28: 430-435.
13. Sporri S, Simmen D, Briner HR, Jones N. Objective assessment of tip projection and the nasolabial angle in rhinoplasty. *Arch Facial Plast Surg* 2004; 6: 295-298.
14. Ingels K, Orhan KS. Measuring nasal tip and lobule width; effect of transdomal and lateral crura suturing. *Rhinology* 2007; 45: 79-82.
15. Ayoub AF, Xiao Y, Khambay B, Siebert JP, Hadley D. Towards building a photo-realistic virtual human face for craniomaxillofacial diagnosis and treatment planning. *Int J Oral Maxillofac Surg* 2007; 36: 423-428.



16. Weinberg SM, Naidoo S, Govier DP, Martin RA, Kane AA, Marazita ML. Anthropometric precision and accuracy of digital three-dimensional photogrammetry: comparing the Genex and 3dMD imaging systems with one another and with direct anthropometry. *J Craniofac Surg* 2006; 17: 477-483.
17. Aldridge K, Boyadjiev SA, Capone GT, DeLeon VB, Richtsmeier JT. Precision and error of three-dimensional phenotypic measures acquired from 3dMD photogrammetric images. *Am J Med Genet A* 2005 15; 138: 247-253.

Niels van Heerbeek, MD, PhD  
Department of Otorhinolaryngology,  
Head & Neck Surgery  
University Medical Center St Radboud  
PO Box 9101  
6500 HB Nijmegen, The Netherlands

E-mail: [n.vanheerbeek@kno.umcn.nl](mailto:n.vanheerbeek@kno.umcn.nl)