

## PDF hosted at the Radboud Repository of the Radboud University Nijmegen

The following full text is a publisher's version.

For additional information about this publication click this link.

<http://hdl.handle.net/2066/80782>

Please be advised that this information was generated on 2017-12-06 and may be subject to change.

## Erythrosis Pigmentosa Mediofacialis: Familial Occurrence

H. Jorn Bovenschen and Marieke M. B. Seyger

Department of Dermatology, Radboud University Nijmegen Medical Center, René Descartes dreef 1, PO Box 9101, NL-6525 GL, Nijmegen, The Netherlands. E-mail: h.bovenschen@derma.umcn.nl

Accepted October 8, 2008.

Sir,

In 1999 Juhlin & Alkemade (1) described erythrosis pigmentosa mediofacialis (Brocq) and erythromelanosis follicularis faciei et colli (EFFC), occurring in the same patient. It was concluded that both entities may in fact be the same disease. Nine years later the younger half-sister of the original patient visited our outpatient clinic with the same symptoms.

### CASE REPORT

A 38-year-old woman was referred to our clinic with a 6-year history of dryness, scaling and an orange-brown to reddish discoloration of the middle of the face. Whereas it had started suddenly and progressively over the first 2 years, in subsequent years the skin lesions had stabilized. As shown in the pedigree (Fig. 1) three of her half-sisters had the same skin changes including the one reported by Juhlin & Alkemade (1). Sun exposure was beneficial as it provoked hyperpigmentation of the uninvolved skin of the cheeks, which resulted in camouflage. No treatment had been initiated. The patient was otherwise healthy and only used oral contraceptive medication.

Dermatological examination revealed sharply demarcated erythematous to orange macules with a dry and rough slightly hyperkeratotic surface on the forehead, the perinasal and perioral region and on the chin. Teleangiectasias were apparent (Fig. 2). Diascopy resulted in a less intense discoloration, leaving a slight yellowish pigmentation. There were no signs of keratosis pilaris, EFFC, granulosis rubra nasi or rosacea.

Histological examination showed slight orthokeratotic hyperkeratosis with a regular epidermis. There was no specific inflammatory epidermal reaction pattern. Some oedema was detected in the papillary dermis. Remarkably, multiple enlarged follicular openings were observed. These openings contained small horny plugs, often with demodex folliculorum. There were some teleangiectatic vessels and an apparent pigment incontinence in the dermis was noticed, consisting of melanin-containing macrophages. The reticular dermis did not show any abnormalities (Fig. 3).

General investigation of peripheral blood including anti-nuclear antibodies was normal.

The diagnosis: erythrosis pigmentosa mediofacialis (EPM) was established on clinicopathological correlation and the evident familial involvement led us to the earlier report of her sister (1). Whilst the histopathology of EPM remains rather

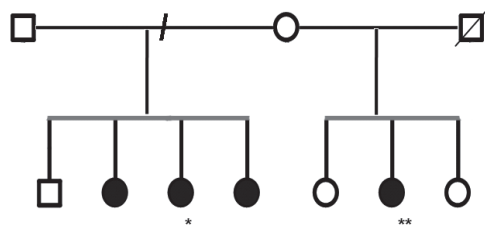


Fig. 1. Pedigree. \*Patient of Juhlin & Alkemade (1). \*\*The present index patient. /=Divorced.

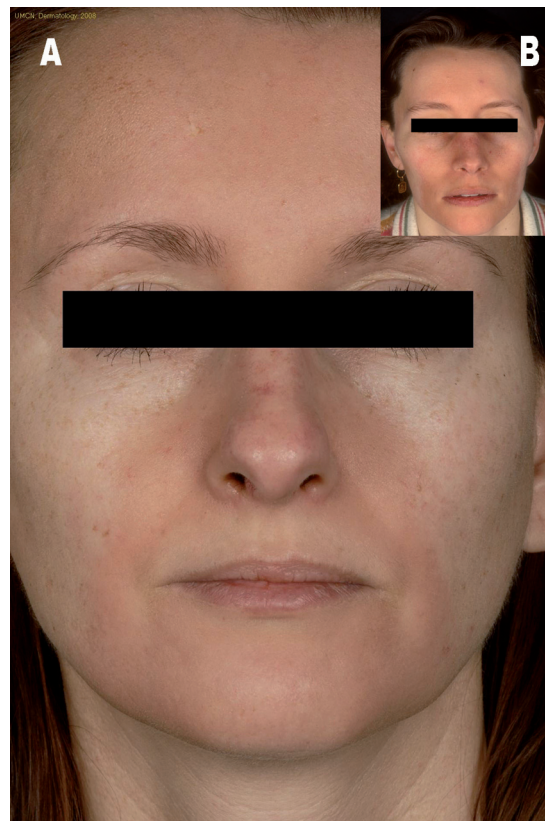

Fig. 2. (A) Clinical picture showing sharply demarcated hyperkeratotic erythematous to orange macules in the middle of the face. (B) Reminder: the half-sister of our patient, as described by Juhlin & Alkemade (1).

aspecific, there is a remarkable concordance between the clinical and histological presentation of the two half-sisters.

### DISCUSSION

In 1923, Brocq described patients with rough and dry, yellow-brown to erythematous lesions around the nose and on the chin (2, 3). Since then, around 30 female patients and 5 male patients with EPM have been described in literature. The nomenclature of the lesions has evolved from *erythroze pigmentaire faciale*, to *dermatose pigmentée médiofaciale*, to *erythrosis pigmentosa peribuccalis*, to *erythrosis pigmentata faciei*, to *erythromelanosis follicularis faciei* and *erythrosis pigmentosa faciei et colli*, which makes it difficult to cluster these from the literature (1).

This report emphasizes the familial occurrence of EPM in our patient. The pedigree in Fig. 1 shows that all affected family members are female and half-sisters.

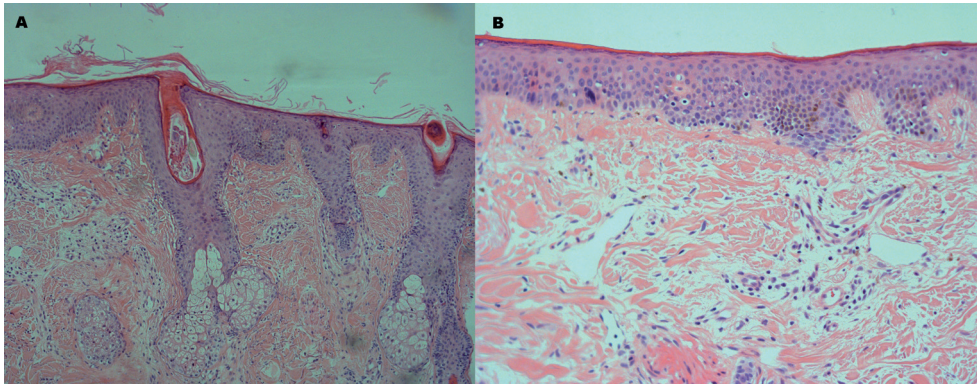


Fig. 3. Histopathological examination showed: (A) dilated follicular opening with orthokeratotic plugs, (B) dermal oedema, pigment incontinence and telangiectatic vessels. Magnification  $\times 100$ .

The parents did not have the skin disorder, neither did the grandparents. Two children of the affected patients (aged  $< 10$  years) did not (yet) have EPM. It is of note that the unaffected mother had 7 children, 4 with her first (Dutch) partner and 3 with a subsequent (Greek) partner. The children from both partners included affected daughters. None of the parents were consanguine.

Juhlin & Alkemade (1) postulated that EPM and EFFC may belong to the same spectrum of disease. Although our patient did not have EFFC, it is remotely possible that there are either genetic links or environmental factors that may induce these skin abnormalities. However, the pathogenesis of both remains largely unknown.

There is a small amount of evidence that the prevalent EFFC has an autosomal recessive mode of inheritance (4). On the contrary, EPM is an exceptionally rare skin disorder, for which no genetic factors have been described thus far. Given the current family it is highly unlikely that EPM has an autosomal recessive mode of inheritance, since the chance of the carrier (mother) meeting two carriers in a row (both fathers) is merely theoretical. Instead, the fact that only females are affected, with an unaffected mother, suggests an autosomal dominant pattern with incomplete penetrance, gonadal mosaicism or a mitochondrial defect. This would implicate that EPM is, in fact, a distinct clinical entity, in contrast to the suggestion by Juhlin & Alkemade (1) that EPM and EFFC may be part of the same spectrum. The fact that EFFC is more prevalent in men, whereas EPM is more often described in women also supports this theory.

It is widely accepted that ultraviolet (UV) radiation and fragrances are contributing factors in the pathogenesis of the more common EFFC. One report emphasizes the combination of genetic and environmental factors in EFFC, thereby referring to a chromosomal instability syndrome (6). *Demodex folliculorum* does not seem to be of aetiological relevance (1, 7). Indisputably, environmental factors such as exposure to UV and fragrance, or a combination of both, may also be factors involved in the pathogenesis of EPM (5).

No treatment options are available for EPM (5). Only one case series is reported on the beneficial effect of pulsed dye laser treatment for EFFC, which might belong to the same spectrum of disease (8). Our patient was instructed to minimize sun exposure and to stop the use of fragrance. Furthermore, she was treated with systemic metronidazole 500 mg thrice daily, which resulted in stomach-ache and was therefore ceased. Topical metronidazole cream 1%, topical adapalene gel 0.1% and urea cream 10%, all twice daily, did not result in any benefit.

In conclusion, EPM is a therapy-resistant skin disorder of the mid-face of unknown origin. Whereas UV radiation and fragrances may aggravate the disease, the familial occurrence of EPM in the present cases may point toward a role for genetic susceptibility in the pathogenesis of this skin disorder.

## REFERENCES

- Juhlin L, Alkemade H. Erythrosis pigmentosa mediofacialis (Brocq) and erythromelanos follicularis faciei et colli in the same patient. *Acta Derm Venereol* 1999; 79: 65–66.
- Brocq L. L'erythroze pigmentée peri-buccale. *Presse Med* 1923; 13: 728–729.
- Brocq L. Discussion. *Bull Soc Franc Derm Syph* 1927; 34: 339–340.
- Yañez S, Velasco JA, González MP. Familial erythromelanos follicularis faciei et colli – an autosomal recessive mode of inheritance. *Clin Exp Dermatol* 1993; 18: 283–285.
- Bleehan SS, Anstey AV. Disorders of skin colour. In: Burns T, Breathnach S, Cox N, Griffiths C, editors. *Rook's textbook of dermatology*. 7th edn. Oxford: Blackwell, 2004: p. 39.41–42.
- Tüzün Y, Wolf R, Tüzün B, Ozdemir M, Demirkesen C, Deviren A, et al. Familial erythromelanos follicularis and chromosomal instability. *J Eur Acad Dermatol Venereol* 2001; 15: 150–152.
- Ormsby OS, Ebert L. Erythroze peribuccale pigmentaire de Brocq. *Arch Dermatol Syphil* 1931; 23: 429–436.
- Kurita M, Momosawa A, Ozaki M, Ban I, Harii K. Long-pulsed dye laser for the treatment of erythromelanos follicularis faciei: report of two clinical cases. *Dermatol Surg* 2006; 32: 1414–1417.