

PDF hosted at the Radboud Repository of the Radboud University Nijmegen

The following full text is a publisher's version.

For additional information about this publication click this link.

<http://hdl.handle.net/2066/70993>

Please be advised that this information was generated on 2017-12-06 and may be subject to change.

Sister Mary Joseph Nodule as a First and Only Sign of Extraovarian Carcinoma

A Case Report and Review of the Literature

Eva Kolwijck, MD; Roy F. Kruitwagen, MD, PhD; Leon F. Massuger, MD, PhD

• Sister Mary Joseph nodule is one of the less well-known signs of intra-abdominal metastatic disease. The primary tumor site is nearly always detected because of specific morphologic and immunohistochemical features of the umbilical tumor. We describe a case of a 74-year-old woman with a Sister Mary Joseph nodule, which appeared most likely to be metastatic from a primary serous papillary ovarian carcinoma based on the histologic examination and the immunohistochemical analysis. Despite an extensive workup, no primary tumor could be detected and therefore we ultimately diagnosed the tumor as an extraovarian carcinoma with primary site at the umbilicus. After a literature search we concluded that a primary adenocarcinoma of the umbilicus is extremely rare and to our knowledge has never been described with both morphologic and immunohistochemical features of a serous ovarian carcinoma.

(*Arch Pathol Lab Med.* 2008;132:1943–1945)

Sister Mary Joseph nodule is a term introduced by Hamilton Bailey in 1960 for a malignant umbilical tumor. It was named after Sister Mary Joseph, a nurse who was the first person to observe umbilical nodules as one of the less well-known signs of intra-abdominal metastatic disease. It can be the first symptom of an underlying cancer or an indication of a recurrence in a patient with a previous intra-abdominal malignancy. Since then numerous case reports have described such a tumor localization, both in men and women, originating from different tumor types, mainly adenocarcinomas.^{1,2} Whereas in men these tumor nodules often are related to the gastrointestinal tract, in women the main primary tumor is located in the genital tract, especially the ovary.² We present a case of a patient in whom a Sister Mary Joseph nodule was identified, being the first and only sign of a (extraovarian) papillary serous adenocarcinoma.

REPORT OF A CASE

A 74-year-old woman was referred to a surgeon for excision of a chronically infected umbilicus because conservative treatment was unsuccessful. During this procedure, an umbilical hernia was also repaired. Histologic examination of the umbilical mass identified the presence of a papillary serous adenocarcinoma with multiple psammoma bodies and microcalcifications (Figure, A and B). Immunohistochemistry was performed on formalin-fixed, paraffin-embedded tissue of the tumor using the immunoperoxidase method. The epithelial lining stained immunopositive for CA 125 at the apical surface of the cytoplasm (Figure, C), for cytokeratin (CK) 7 in the cytoplasm (Figure, D), and for estrogen receptor in the nucleus (Figure, F). It was 30% positive for progesterone receptor in the nucleus and tested negative for CK20 (Figure, E) and carcinoembryonic antigen. Based on this morphology and immunohistochemical analysis the tumor appeared most likely to be related to a primary ovarian carcinoma. The patient was referred to our department at that point. At gynecologic examination, including transvaginal ultrasonography, no abnormalities were found. A radiologic workup was initiated (transvaginal ultrasonography, X-mammography, computed tomography of thorax and abdomen), which again showed no abnormalities. Serum CA 125, CA 15.3, and carcinoembryonic antigen levels were normal. Endometrial histology, obtained by dilatation and curettage, showed an atrophic endometrium. At laparoscopy no abnormalities were found and a bilateral salpingo-oophorectomy was performed. Despite ultrasonography, histologic examination revealed no primary tumor localization.

Finally it was decided to perform a complete staging laparotomy, composed of a hysterectomy, numerous peritoneal biopsies, a pelvic retroperitoneal lymph node sampling, and an infracolic omentectomy. Again, histologic examination revealed no primary tumor localizations and therefore no adjuvant chemotherapy was started. Seven months after excision of the umbilical tumor, the patient showed no evidence of disease.

COMMENT

So far, a Sister Mary Joseph nodule has been interpreted as the expression of metastatic disease of different intra-abdominal tumor types. Despite the fact that these tumor nodules sometimes can be the first symptom, during further workup the primary tumor site nearly always is identified, and in women often appears to be the ovary. This identification is relatively easy because most umbilical adenocarcinomas have specific histologic and immunohistochemical features that enable a fairly confident prediction of the probable site of the primary tumor.²

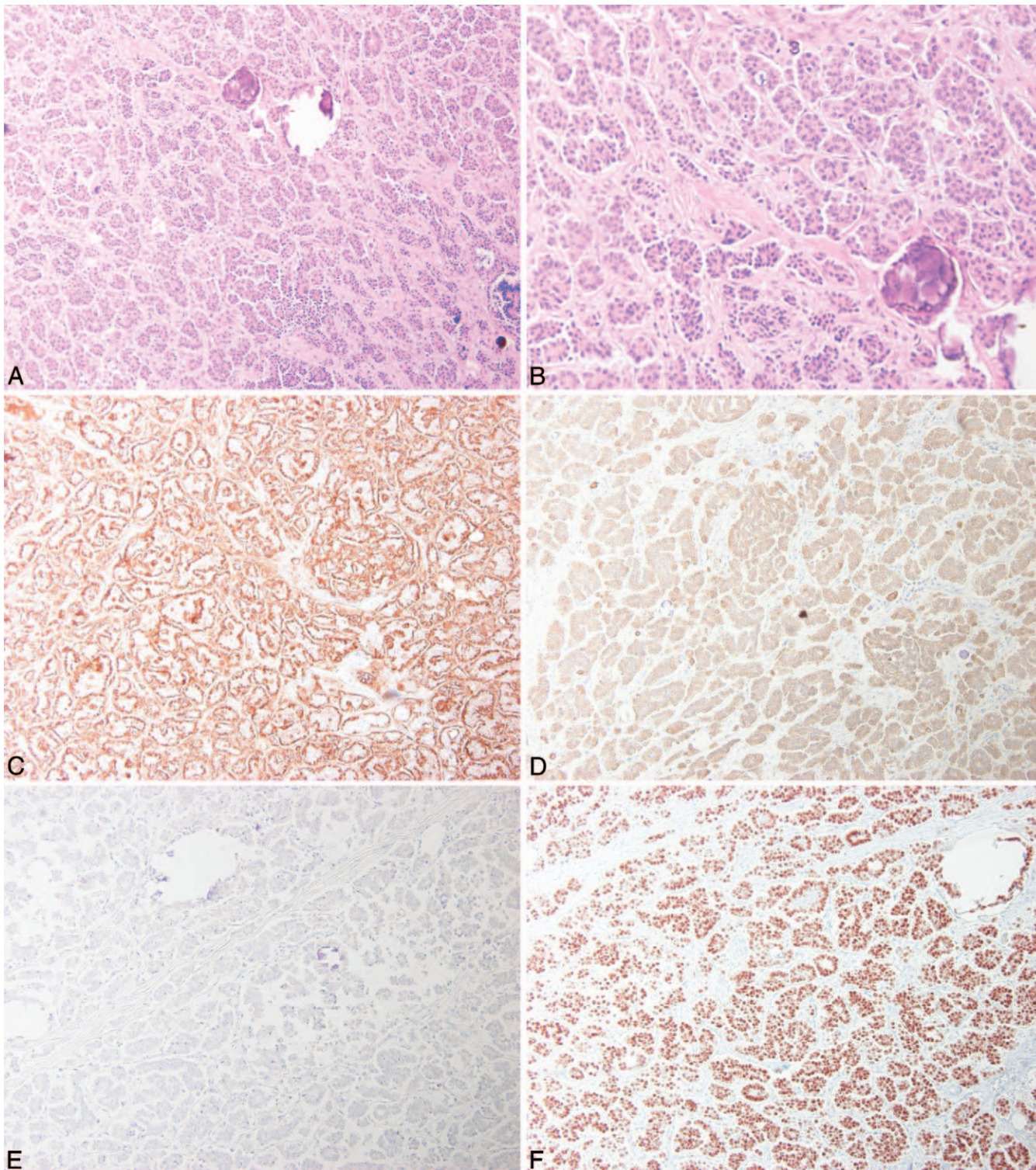
Most authors support the idea that these metastatic lesions in the umbilicus are the result of lymphatic and/or hematogenic spread, or by extension per continuitatem

Accepted for publication June 18, 2008.

From the Department of Obstetrics and Gynaecology, Radboud University Nijmegen Medical Center, Nijmegen, The Netherlands.

The authors have no relevant financial interest in the products or companies described in this article.

Reprints: Eva Kolwijck, MD, Radboud University Nijmegen Medical Center, Internal Postal Code 791, PO Box 9101, 6500 HB Nijmegen, The Netherlands (e-mail: E.Kolwijck@obgyn.umcn.nl).



Stained tissue sections of the adenocarcinoma of unknown primary origin. A and B, Hematoxylin-eosin-stained section shows a papillary pattern of malignant cells and psammoma calcifications (original magnifications $\times 100$ [A] and $\times 200$ [B]). Immunohistochemistry using immunoperoxidase method on the same tumor shows a positive staining for CA 125 (C), cytokeratin 7 (D), and estrogen receptor (F) and a negative staining for cytokeratin 20 (E) (original magnifications $\times 100$).

from the peritoneal surface.^{2,3} In addition, iatrogenic metastases after laparoscopy at the umbilical port site have been reported. Possible mechanisms for this phenomenon include direct or indirect seeding of tumor cells due to excessive manipulation, leakage of insufflation gas

through the port site (chimney effect), replacement of trocars, unprotected retraction of tumor tissue, and the CO₂ pneumoperitoneum that causes diffuse damage to the entire mesothelial layer.⁴

Primary malignant umbilical tumors are rare and most-

ly comprise melanomas and squamous and basal cell carcinomas. The diagnosis of primary umbilical adenocarcinoma can be suspected when an alternative primary cancer has been searched for but not found by complete examination.² In his 1966 review of the literature, Barrow³ found 29 cases of primary umbilical adenocarcinomas of which 24 were reported by Cullen in 1916 and were collected around the turn of the century or before. Steck and Helwig¹ declared that the reports of Cullen offered little proof that the umbilical lesion was primary or even cancer. Moreover, in their series of 48 malignant umbilical tumors they only found 1 possible primary adenocarcinoma. For this reason they concluded that proof of a diagnosis of primary adenocarcinoma in the umbilicus is extremely rare and very difficult to establish.

After a literature search we could only find 1 case report of a primary umbilical adenocarcinoma that was thought to be metastatic from an ovarian primary neoplasm.⁵ Histologic examination revealed a well-differentiated papillary adenocarcinoma with psammoma bodies. However, no immunohistochemical analysis was performed, which means that the type of histology described may be related to other intra-abdominal malignancies as well. After this case was reported in 1975, in which no primary (ovarian) tumor could be detected, no other extraovarian umbilical adenocarcinomas were reported until now.

It is suggested that primary umbilical adenocarcinoma arises from an embryologic remnant connected to the umbilicus, such as the omphalomesenteric (OM) duct or the urachus.^{1,5} The OM duct is a tubular structure that joins the gut of the early embryo to the yolk sac. Remnants of the duct may persist anywhere along its course and commonly contain gastrointestinal mucosa (primarily consisting of columnar and mucus-secreting goblet cells) and smooth muscle. Steck and Helwig⁶ studied 40 patients with cutaneous remnants of the OM duct but failed to detect any neoplasm. The only OM neoplasms described so far are of Meckel diverticulum, a remnant of the most proximal part of the OM duct. Rarely, malignant tumors arise in this site and almost always comprise carcinoids. The few cases of adenocarcinomas of Meckel diverticulum reported were of gastrointestinal type.⁷

The urachus runs downward in the extraperitoneal space from the umbilicus to the apex of the bladder. Primary urachal adenocarcinomas account for less than 1% of all urinary bladder cancers and theoretically might occur at any point up to the umbilicus. Malignant urachal tumors mostly are well-differentiated mucinous adenocarcinomas and are occasionally signet-ring cell carcinomas.⁸ Three cases of a primary urachal adenocarcinoma with

ovarian metastases that mimicked primary ovarian mucinous adenocarcinoma have been described.⁸⁻¹⁰ Arguments for these ovarian tumors being metastatic from the urachal tumor rather than primary ovarian carcinoma were the occurrence of the ovarian tumor localizations after occurrence of the urachal tumor and a characteristic morphology (mucinous adenocarcinoma) and immunohistochemical profile (CK20 receptor positive and CK7 receptor negative) being more consistent with metastatic rather than primary ovarian carcinoma.⁸

In our patient, the histology of the tumor nodule was in accordance with a papillary serous adenocarcinoma of the ovary, both morphologically (existence of psammoma bodies) as well as immunohistochemically (CK7, estrogen receptor, progesterone receptor, and CA 125 receptor positive). Despite an extensive workup to find the primary tumor localization, including a complete staging laparotomy as in primary (extra)ovarian cancer, no primary tumor was found. Therefore, a primary site in the umbilicus was accepted by default. However, it is questionable if the tumor arose within an ectopic remnant of the umbilicus because of the difference in histology and morphology compared with common malignancies of the OM duct and urachus. In addition, although unlikely, we could not completely rule out the existence of an occult primary serous carcinoma because the follow-up time was only 7 months.

In conclusion, to our knowledge, this report describes a unique case of a malignant umbilical tumor nodule with ovarian carcinoma-like appearance as the only sign of a malignancy supporting the idea of a primary extraovarian tumor site at the umbilicus.

References

1. Steck WD, Helwig EB. Tumors of the umbilicus. *Cancer*. 1965;18:907-915.
2. Dubreuil A, Domp Martin A, Barjot P, Louvet S, Leroy D. Umbilical metastasis or Sister Mary Joseph's nodule. *Int J Dermatol*. 1998;37(1):7-13.
3. Barrow MV. Metastatic tumors of the umbilicus. *J Chronic Dis*. 1966;19:1113-1117.
4. Martinez-Palones JM, Gil-Moreno A, Perez-Benavente MA, Garcia-Gimenez A, Xercavins J. Umbilical metastasis after laparoscopic retroperitoneal paraaortic lymphadenectomy for cervical cancer: a true port-site metastasis? *Gynecol Oncol*. 2005;97(1):292-295.
5. Ross JE, Hill RB Jr. Primary umbilical adenocarcinoma: a case report and review of literature. *Arch Pathol*. 1975;99:327-329.
6. Steck WD, Helwig EB. Cutaneous remnants of the omphalomesenteric duct. *Arch Dermatol*. 1964;90:463-470.
7. Lippe P, Berardi R, Latini L, Bracci R, Cellerino R. Severe prognosis of signet-ring cell adenocarcinoma occurring in Meckel's diverticulum. *Ann Oncol*. 2001;12(2):277.
8. Ohira S, Shiohara S, Itoh K, Ashida T, Fukushima M, Konishi I. Urachal adenocarcinoma metastatic to the ovaries: case report and literature review. *Int J Gynecol Pathol*. 2003;22(2):189-193.
9. Young RH. Urachal adenocarcinoma metastatic to the ovary simulating primary mucinous cystadenocarcinoma of the ovary: report of a case. *Virchows Arch*. 1995;426:529-532.
10. Trastour C, Desprez B, Delotte J, et al. Ovarian metastases from an urachal adenocarcinoma. *Eur J Obstet Gynecol Reprod Biol*. 2006;125(1):143-144.