

PDF hosted at the Radboud Repository of the Radboud University Nijmegen

The following full text is a publisher's version.

For additional information about this publication click this link.

<http://hdl.handle.net/2066/69638>

Please be advised that this information was generated on 2017-12-06 and may be subject to change.

Review

Intracavitary Radioimmunotherapy to Treat Solid Tumors

Frits Aarts,¹ Robert P. Bleichrodt,¹ Wim J.G. Oyen,² and Otto C. Boerman²

Departments of ¹Surgery and ²Nuclear Medicine, Radboud University Nijmegen Medical Centre, Nijmegen, The Netherlands

ABSTRACT

Radioimmunotherapy (RIT) potentially is an attractive treatment for radiosensitive early-stage solid tumors and as an adjuvant to cytoreductive surgery. Topical administration of RIT may improve the efficacy because higher local concentrations are achieved. We reviewed the results of locally applied radiolabeled monoclonal antibodies for the treatment of solid tumors. Intracavitary RIT in patients with ovarian cancer and glioma showed improved targeting after local administration, as compared to the intravenous administration. In addition, various studies showed the feasibility of locally applied RIT in these patients. In studies that included patients with small-volume disease, adjuvant RIT in ovarian cancer and glioma showed to be at least as effective as standard therapy. The information about RIT for peritoneal carcinomatosis of colorectal origin is scarce, while results from preclinical data are promising. RIT may be applied for other, relatively unexplored indications. Studies on the application of radiolabeled antibodies in early urothelial cell cancer have been performed, showing that intracavitary RIT may hold a promise. Moreover, in patients with malignant pleural mesothelioma or malignant pleural effusion, RIT may play a role in the palliative treatment. Intracavitary RIT limits toxicity and improves tumor targeting. RIT is more effective in patients with small-volume disease of solid cancers. RIT may have potential for palliation in patients with malignant pleural mesothelioma or malignant pleural effusion. The future of RIT may, therefore, not only be in the inclusion in contemporary multimodality treatment, but also in the expansion to palliative treatment.

Key words: radioimmunotherapy, intracavitary, ovarian cancer, glioma, colorectal cancer, urothelial cell cancer

*Address reprint requests to: Frits Aarts; Department of Surgery, Radboud University Nijmegen Medical Centre; P.O. Box 9101, 6500 HB Nijmegen, The Netherlands; Tel.: +31-24-3615333; Fax: +31-24-3540501
E-mail: F.Aarts@chir.umcn.nl*

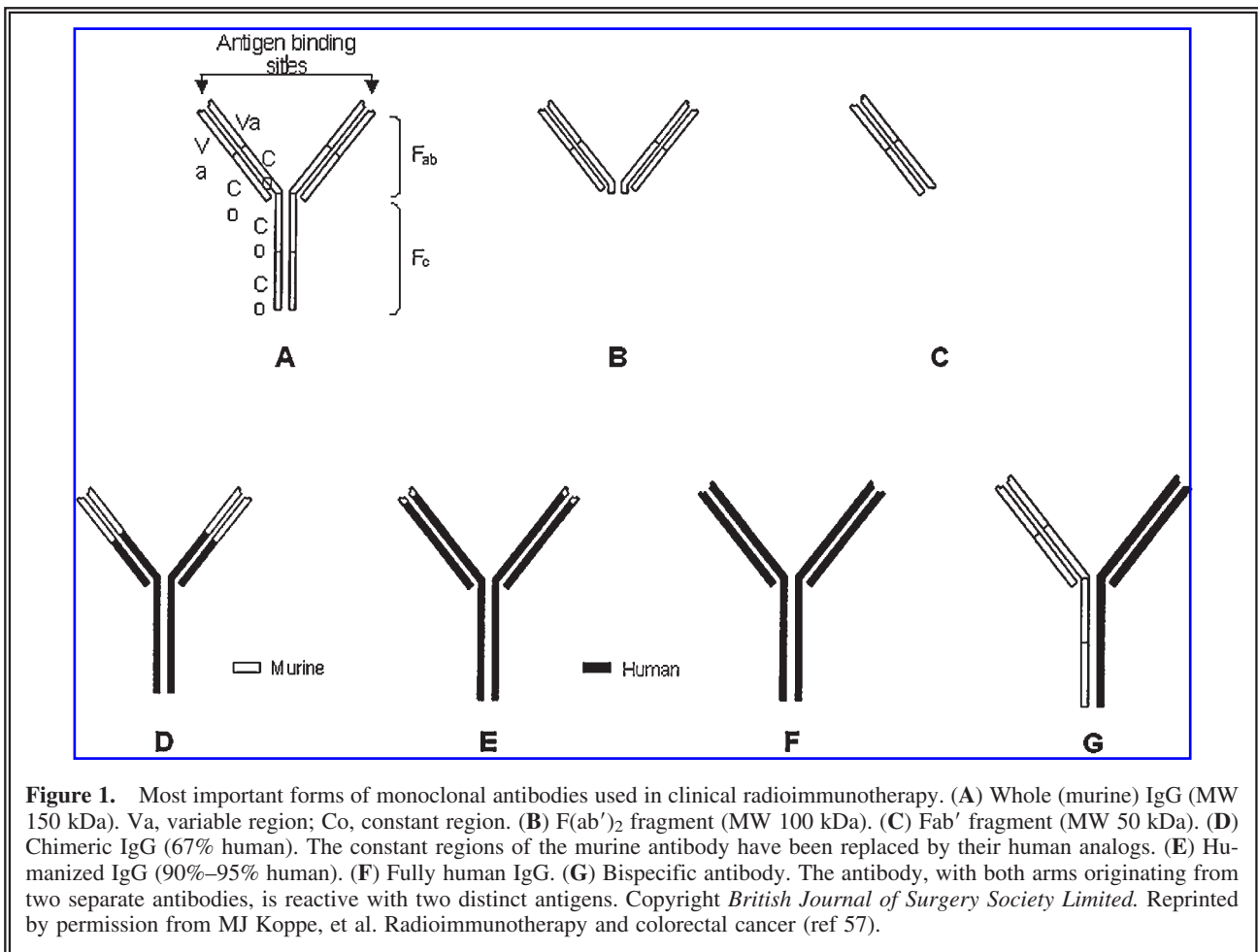
INTRODUCTION

Biologicals play an increasingly important role in the treatment of cancer. Monoclonal antibodies (mAbs) against CD20 are standard therapy in non-Hodgkin's lymphoma (NHL), anti-vas-

cular endothelial growth factor (VEGF) antibodies are used to treat colon and lung carcinoma and anti-HER2 antibodies play a role in breast cancer treatment. mAbs can also be used to direct anticancer drugs to tumor cells. Drugs, toxins, or radionuclides can be conjugated to mAbs for selective delivery of these agents to tumor tissues, thus sparing normal tissues in contrast to conventional systemic anticancer therapies^{1,2}

In radioimmunotherapy (RIT), mAbs are labeled with radionuclides to selectively irradiate tumor cells. RIT has proven to be effective in hematologic malignancies but is less effective in solid cancers.³⁻⁵ Large solid tumors have a limited blood supply, rendering these tumors less accessible for therapeutic agents being delivered via the blood. Impaired blood supply and concomitant ischemia make tumor cells less radiosensitive.^{6,7} In addition, solid tumors have a high interstitial fluid pressure that limits the uptake and

penetration of antibodies.⁸ As a result, in large tumors, the uptake of mAbs from the blood is relatively low and heterogeneous, thus limiting the efficacy of RIT. In small tumor lesions, the uptake of mAbs is higher and the heterogeneity of antibody uptake within the tumor can be overcome by the penetration range of the radiation. Therefore, RIT seems to be an attractive adjuvant therapy in small-volume disease or microscopic residual tumor deposits. RIT may also be administered topically in order to reduce systemic activity and enhance tumor targeting. In addition, there are conditions that are particularly suitable for RIT owing to tumor localization (i.e., the development of cancer within a natural cavity) and its concomitant pharmacologic advantages. In both preclinical and clinical studies, the mAb levels in intraperitoneally growing tumors were found to be higher during the first 24 hours after intraperitoneal administration, as compared to systemic administration, thus favoring this route



of administration.^{9,10} In this paper, we reviewed the results of locally applied radiolabeled mAbs for the treatment of solid tumors.

RADIOIMMUNOTHERAPY

Antibodies

Since the development of the hybridoma technology, it is possible to generate antibodies specifically directed against tumor-associated antigens.¹¹ Murine antibodies were the first clinically applied antibodies. A major disadvantage was the production of human antimouse antibodies (HAMAs) that could induce humoral immune responses. In order to reduce immunogenicity, recombinant DNA techniques were applied to produce chimeric and humanized mAbs.¹² In chimeric mAbs, the variable regions of heavy and light chains are of murine origin, and these are then fused with the constant regions of human origin (Fig. 1). In humanized mAbs, only the Complementarity Determining Regions (CDR) of the murine origin are grafted in a human antibody framework.^{13,14} To improve *in vivo* targeting properties, new antibody constructs have been produced, using recombinant DNA techniques (e.g., scFv, minibodies, diabodies, and so forth).

Radionuclides

The most commonly used radionuclides in RIT are beta-emitters. Beta-particles are electrons that are emitted from the nucleus of an unstable atom. In RIT, iodine-131 (¹³¹I) and yttrium (⁹⁰Y) are the most commonly used beta-emitters. More recently, rhenium-186 (¹⁸⁶Re), copper-67 (⁶⁷Cu), and lutetium-177 (¹⁷⁷Lu) have also been applied (see Table 1) The differences in physical half-life, the presence or absence of gamma rays, the energy, and consequently the range of the beta-particles in tissue are important with respect to the ra-

diation dose that can be delivered to the tumor. For example, ⁹⁰Y-labeled mAbs are theoretically not suitable for the treatment of minimal or residual disease with a diameter of only a few millimeters or less, since 70% of the radiation energy will be deposited outside small tumors (diameter <5 mm) owing to the high energy of the β -particles (mean, 0.9 MeV).¹⁵ For this application, the use of ¹⁷⁷Lu-labeled antibodies with medium-energy electron emissions is better suited.¹⁶ Internalization of the radiolabeled antibodies depends on various factors, including the antibody itself and the targeted antigen. All antibodies eventually are internalized by the target cell and subsequently catabolized.¹⁷ When internalized, the radiolabeled mAb is degraded in the lysosomes. In case of radioiodinated mAbs, the radiolabeled metabolites are excreted from the cell. Labeling of mAbs with radiometals, such as ⁹⁰Y, ¹⁷⁷Lu, and ⁶⁷Cu, is performed by first linking chemical moieties that can complex the metal ions to the antibody (chelators such as DTPA, DOTA, or TETA). When catabolized, the radioactive metabolites of mAbs labeled with radiometals are trapped in the lysosomes, increasing the retention of these radiolabels in the tumor.^{18,19}

INTRAPERITONEAL RIT

The abdominal cavity is lined with mesothelial cells that not only play a role in the sliding of the peritoneal surfaces, but also play an active role in the immunologic response, inflammation, and coagulation.²⁰ Peritoneal clearance is regulated via the peritoneum that behaves as a semipermeable membrane and the lymphatic lacunae underlying diaphragmatic stomata. This clearing process starts within minutes after contamination of the peritoneal cavity.

Antibodies administered into the peritoneal cavity cross the peritoneal lining mainly by diffusion. The rate of diffusion depends on the volume of the instilled agent and the concomitant increase in fluid pressure.^{21,22} Moreover, antibodies will be cleared via the diaphragmatic stomata. For RIT of intraperitoneal lesions, the intraperitoneal (i.p.) administration is advantageous, as compared to the systemic administration, because higher concentrations of the antibody can be reached in the tumor.²³ When mAbs are administered into the peritoneal cavity, their pharmacokinetics are similar to that of other large-serum proteins. Apart from specific binding to i.p. tumors, there is transportation to the

Table 1. Radionuclides

Radionuclide	Half-life	Beta energy (KeV)	Gamma energy (KeV)	Range (β)
¹³¹ I	8 days	192	362	3 mm
⁹⁰ Y	64 hours	935	—	12 mm
¹⁸⁸ Re	17 hours	795	155	27 mm
¹⁷⁷ Lu	7 days	149	208	3 mm
⁶⁷ Cu	62 hours	141	185	2 mm

Table 2. Ovarian Cancer

<i>Author</i>	<i>No. of patients</i>	<i>Median survival (months)</i>	<i>Tumor-associated antigen</i>	<i>Antibody</i>	<i>Stable disease</i>	<i>Remission</i>	<i>Partial remission</i>	<i>Nuclide</i>	<i>Dose</i>
Epenetos et al. ³⁴	24		MUC1	HMFG1-2, AUA1, H17E2	5/24	4/24		¹³¹ I	140 mCi
Nicholsson et al. ³⁵	25	n.r.	MUC1	HMFG1				⁹⁰ Y	18 mCi/m ²
Epenetos et al. ³⁶	52	>52	MUC1	HMFG1		21/54		⁹⁰ Y	
Verheijen et al. ³⁷	224		MUC1	HMFG1				⁹⁰ Y	18 mCi/m ²
Meredith et al. ⁴⁰	12		TAG-72	CC-49		3/12	1/12	¹⁷⁷ Lu	10–30 mCi/m ²
Rosenblum et al. ⁴¹	58		TAG-72	B72.3	30	2/52	2/57	⁹⁰ Y	1–25 mCi
Alvarez et al. ⁴²	27		TAG-72	CC-49	2	3/27		¹⁷⁷ Lu	10–50 mCi/m ²
Meredith et al. ⁴⁴	44		TAG-72	CC-49	4/44		4/44	¹⁷⁷ Lu	40–45 mCi/m ²
Alvarez et al. ^a	20		TAG-72	CC-49	5/20	11/20	2/20	⁹⁰ Y	
Crippa et al. ⁴⁶	16		GP38	MOv-18		5/16		¹³¹ I	100 mCi
Mahe et al. ⁴⁷	6		CA-125	OC-125	3			¹³¹ I	120 mCi
Grana et al. ^b	16		CEA/TAG-72/GP38	n.s.	5/16	1/16		⁹⁰ Y	
Riva et al. ^c	10		MUC1 TAG-72	HMFG1 HMFG2 H17E2 B72.3			3	¹³¹ I	92 mCi
Jacobs et al. ^d	17		PCCA				4/17	¹⁸⁸ Re	

n.r., not reported; n.s., not significant.

^aAlvarez RD, Huh WK, Khzaeli MB, et al. A Phase I study of combined modality (90)Yttrium-CC49 intraperitoneal radioimmunotherapy for ovarian cancer. *Clin Cancer Res* 2002;8:2806.

^bGrana C, Bartolomei M, Handkiewicz D, et al. Radioimmunotherapy in advanced ovarian cancer: Is there a role for pre-targeting with (90)Y-biotin? *Gynecol Oncol* 2004;93:691.

^cRiva P, Marangolo M, Lazzari S, et al. Locoregional immunotherapy of human ovarian cancer: Preliminary results. *Int J Rad Appl Instrum B* 1989;16:659.

^dJacobs AJ, Fer M, Su FM, et al. A phase I trial of a rhenium 186-labeled monoclonal antibody administered intraperitoneally in ovarian carcinoma: Toxicity and clinical response. *Obstet Gynecol* 1993;82:586.

circulation and subsequent uptake in normal tissues.^{24,25} However, in both preclinical and in clinical studies, the concentration of mAbs in the tumor lesions is higher during the first 24 hours after an i.p. administration while blood levels are lower, as compared to a systemic administration. In addition, not only the tumor uptake is increased, but also the tumor:nontumor ratio. This favors this route of administration for i.p. growing tumors.^{10,26}

Ovarian Cancer

Ovarian cancer mostly originates from the surface epithelium of the ovaries, and in most patients, metastases are confined to the peritoneal cavity without further distant metastases.²⁷ The overall survival rate is 35%. The majority of patients presents with advanced disease at the time of diagnosis. Radical debulking, in combination with platinum- or taxol-based chemotherapy, is

the standard treatment, resulting in 50% local recurrences and a median survival of 2 years.^{28,29}

Ovarian cancer seems to be well suited for i.p. administered adjuvant RIT.³⁰ The disease has been targeted by using antibodies directed against tumor-associated antigens as the mucin-1 (MUC1) antigen, CA-125, TAG-72, and gp38 (see Table 2).

As mentioned above, several preclinical and clinical studies demonstrated that an i.p. administration of RIT resulted in a higher uptake of radiolabeled antibodies in tumor, as compared to systemic route administration.^{10,26,31,32}

MUC-1

MUC-1 is expressed on glandular epithelium in the majority of adenocarcinomas, including breast, ovary, and pancreas, where it is both overexpressed as well as aberrantly glycosylated.³³ One of the first RIT trials in patients with ovarian cancer was carried out by Epenetos et al., treating 24 patients with stage III ovarian cancer in an adjuvant setting to cytoreductive surgery and platinum-based chemotherapy. In this study, ¹³¹I-labeled anti-MUC1 mAbs, HMFG1-2, AUA 1, and H17E2, were used.³⁴ The best response was found in the 16 patients with minimal or small-volume (<2 cm diameter) disease. No response was seen in the 8 patients with large-volume disease (>2 cm diameter) who all died of recurrent disease within 9 months. In another trial, the efficacy of adjuvant ⁹⁰Y-labeled HMFG1 following surgery and chemotherapy was compared to a historic control group that was treated with surgery and chemotherapy alone. Five (5)-year survival in the RIT group was 80%, as compared to 55% in the control group.³⁵ Later, these investigators reported that after 12 years of follow-up, the median survival of a group with complete remission following surgery, chemotherapy, and adjuvant ⁹⁰Y-HMFG1 had not yet been reached. These results were better than the results in a historic control group that had a median survival of 42% survival after 5 years of follow-up.³⁶ Based on the encouraging results of these phase I/II studies, a phase III open-label, randomized, multicenter phase III trial was undertaken. This study included patients to be treated with ⁹⁰Y-HMFG1 RIT (maximum dose, 25 mCi; *N* = 224) and compared them to conventionally treated patients (*N* = 223).³⁷ Patients were eligible after a complete clinical response to platinum-based chemotherapy following surgical cytoreduction. Intraperitoneally administered RIT was applied after a confirmed mac-

roscopically negative laparoscopy. This study failed to show a benefit in overall survival or a prolonged disease-free survival after RIT. Although peritoneal recurrence was significantly delayed in the RIT group, extraperitoneal metastases, mainly located in the para-aortic lymph nodes, were found more frequently than in the control group (49% versus 14%).³⁸

TAG-72

TAG-72 is a mucin-like antigen that is heterogeneously expressed in virtually all ovarian cancers. The pharmacology, metabolism, and tissue distribution of ⁹⁰Y-labeled anti-TAG-72 B72.3 was investigated in 9 patients with ovarian cancer.³⁹ Following this report, Meredith et al.⁴⁰ and Rosenblum et al.⁴¹ performed i.p. RIT studies in patients with chemotherapy-resistant or refractory ovarian cancer limited to the peritoneal cavity. Rosenblum et al. included 58 patients treated with ⁹⁰Y-labeled B72.3, 1–25 mCi, resulting in 2 complete remissions and 30 patients with stable disease with a median of 6 months (range, 4–24). In a study using ¹⁷⁷Lu-labeled CC49, a second-generation anti-TAG-72 antibody with a higher affinity for TAG-72 than the B72.3 antibody (dose, 10–50 mCi/m²), Alvarez et al. included 27 patients. Fourteen (14) of these patients with small (<1 cm) or microscopic disease were stable for 6–35 months, whereas in patients with measurable disease (>1 mm), only 1 patient showed a partial response. The other patients showed progression within 3 months.⁴² Meredith et al. published a report including 12 patients treated with ¹⁷⁷Lu-labeled CC49, 10–30 mCi/m².⁴⁰ This resulted in complete remission in 3 patients and stable disease in 1. Complete responses were only found in patients with microscopic disease. Following the report by Roselli et al.,⁴³ who showed that interferon (IFN) enhances the expression of TAG-72, Meredith et al. subsequently tested the feasibility and efficacy of a combination of subcutaneous (s.c.) injections of IFN, i.p. paclitaxel (100 mg/m²), and RIT consisting of 40–45 mCi/m² ¹⁷⁷Lu-labeled CC49. This study included 44 patients with ovarian cancer, 27 of whom had only microscopic disease or disease not measurable on computed tomography (CT).⁴⁴ Four (4) of 17 patients with macroscopic disease on CT showed a partial response (decrease of >50% diameter), whereas 4 of 27 patients with microscopic disease showed progression-free time intervals of more than 18 months. Subsequently, the same research group treated 20

patients with persistent or recurrent ovarian cancer after conventional cytoreductive surgery and chemotherapy, with a combination of RIT using ^{90}Y -labeled CC49 and a single i.p. administered dose of paclitaxel (100 mg/m^2) and IFN. In 3 of 11 patients with nonmeasurable disease, disease-free survival was more than 18 months. The researchers concluded that this combination of treatments was well tolerated and showed antitumor activity.

gp38

MOv18 is an antibody directed against the folate receptor gp38, which is expressed at high levels in 90% of serous ovarian carcinomas. The expression level on other epithelial tissues is low.⁴⁵ The murine MOv18 mAb is highly immunogenic, inducing human antimouse antibodies (HAMA) in most patients. MOv18 targeting of ovarian cancer was investigated by van Zanten-Przybysz et al.²⁶ by comparing the i.p. administration to the intravenous (i.v.) injection. *Ex vivo* measured tumor uptake after i.p. administration was 3.4%–12.3%, whereas this was 3.6%–5.4% after the i.v. administration.³² In addition, van Zanten-Przybysz et al. determined the pharmacokinetics and tumor accumulation of both i.v. and i.p. administered cMOv18 in the same patient in a dual-label $^{125}\text{I}/^{131}\text{I}$ -study in 15 patients. They showed a tumor uptake of 4.9% and 2.4% injected dose per kilogram (ID/kg) after the i.v. and i.p. administration after 2 days, respectively. After 6 days, there was no difference in tumor uptake between the routes of administration (3.8% and 3.9% ID/kg for i.v. and i.p.). Moreover, the mean AUC for the blood-activity versus time curve was 3.5 times higher after the i.v. injection at 2 days and 2.1 times higher at 6 days, as compared to the i.p. injection. The researchers, therefore, concluded that the i.p. route could be advantageous owing to the significantly lower bone marrow toxicity as a result of lower blood levels of the radiolabeled antibody when administered i.p.²⁶

Crippa et al. tested the efficacy of i.p. administered RIT, using ^{131}I -MOv18 (mean dose, 100 mCi) in 16 patients with minimal or small-volume ovarian cancer.⁴⁶ Clinical follow-up and/or third-look evaluation performed 90 days after the administration of RIT showed a complete response in 5, stable disease in 6, and progressive disease in 5 patients. Of the 5 patients that showed a complete response, 1 patient remained disease free after a follow-up of 34 months, whereas the remaining 4 patients relapsed after a mean period of 10.5 months.

CA-125

Mahe et al. performed a phase I study comprising of i.p. administered 120 mCi of the ^{131}I -labeled anti-CA-125 antibody OC125 to 6 patients with residual macroscopic ($<5\text{ mm}$) or microscopic disease, resulting in stable disease in 2 patients.⁴⁷ In addition, there was HAMA formation in all 6 patients. The reported lack of efficacy might be owing to the nature of CA-125, being an antigen that is shed from the cell membrane.^{48,49}

In conclusion, the data available on the use of adjuvant i.p. RIT in patients with ovarian cancer show improved targeting after the i.p. administration, as compared to the i.v. administration. Despite the lack of survival benefit, the phase III study with ^{90}Y -HMFG1 showed an improved local control of i.p. disease in patients treated with RIT.

Colorectal Cancer

Colorectal cancer (CRC) may spread intraperitoneally, causing peritoneal carcinomatosis (PC). In 25% of the patients with recurrent CRC, this is the only site of metastasis.⁵⁰ If untreated, patients suffering from PC have a median survival of only 6 months.⁵¹ Today's gold standard for the treatment of PC is cytoreductive surgery, followed by heated i.p. chemotherapy or HIPEC.⁵⁰ This highly specialized, extensive treatment is associated with a high morbidity (14%–55%) and high mortality (19%).⁵⁰ Although the results of this treatment are promising, the median survival is 13–34 months^{52,53} and the 5-year survival rate is 19%–27%.^{54,55} Owing to the high complication rates, there is a need for new treatment modalities.

RIT for CRC has been under clinical investigation since 1992, mainly with anti-carcinoembryonic antigen (CEA) antibodies.⁵⁶ The results of RIT in CRC were recently reviewed by our group.⁵⁷ So far, only one trial gave the results of i.p. administered RIT in patients with advanced CRC. Patients with local as well as regional and systemic spread were included.⁵⁸ Thirty-one (31) patients with large peritoneal metastases were treated. Patients received 5 cycles of i.p. administered ^{131}I -labeled anti-CEA/TAG-72/MUC-1. This was done either as monotherapy (one antibody) or in combination with multiple antibodies. The average activity dose per cycle was 98 mCi. The researchers reported a median survival of 41 months, complete remission lasting 23 months in 10 patients, stable disease that lasted

for 12 months in 8 patients, and a partial remission in 10 patients.

Preclinical studies in mice with colon cancer xenografts were performed by Keenan et al. as early as 1984, suggesting RIT might be successful for the treatment of colon cancer in humans.⁵⁹ The preclinical as well as the clinical investigations of this group focussed on the i.v. route of administration, despite a more efficient tumor targeting in patients with PC after a i.p. administration than after an i.v. administration, as shown in a dual-label study of concomitant i.v.- and i.p.-administered ¹³¹I-labeled B72.3.¹⁰

In nude mice with i.p. growing human colon carcinoma, the i.p. route of administration of radiolabeled MN14, an anti-CEA antibody, showed a higher tumor uptake during the first –48 hours ($58.5\% \pm 6.8\%$ ID/g for i.p. vs. $34.9\% \pm 4.7\%$ ID/g for i.v.) after administration. Thereafter, the uptake was similar.⁶⁰ In addition, an increased therapeutic efficacy of ¹⁷⁷Lu-(median survival, 136 days) and ¹³¹I-labeled MN14 (median, 100 days) was reported, when compared to equitoxic doses (8.33 MBq) of ⁹⁰Y-(median, 82 days) and ¹⁸⁶Re-labeled MN14 (median, 72 days) in this model.⁶¹ The feasibility of i.p. RIT in an adjuvant setting to cytoreductive surgery, leaving only microscopic disease, was also investigated by Koppe et al. The researchers used ¹⁷⁷Lu-labeled MG1, a radiolabeled anti-CC531 (rat colon carcinoma) antibody administered after cytoreductive surgery (CS). In this model, adjuvant RIT resulted in a significantly improved survival of rats treated with the combination of CS and RIT, as compared to either CS or RIT alone.⁶² Despite these favorable preclinical studies, there are no clinical trials investigating the efficacy of RIT as an adjuvant treatment to cytoreductive surgery for peritoneal carcinomatosis of colorectal origin.

In conclusion, RIT is an effective treatment for i.p. metastases and an effective adjuvant to cytoreductive surgery in preclinical studies. The limited experience in phase I clinical trials warrants clinical studies.

RIT IN BRAIN TUMORS

An estimated 41,000 cases of primary central nervous system (CNS) tumors occur annually in the United States, 42% of which are glial tumors that are, in most cases, malignant.⁶³ Glioblastoma multiforme, the most malignant form of CNS tumors, offers patients a very poor overall survival

of only 3.3% after 2 years, despite the combination of surgery, radiotherapy, and chemotherapy.⁶⁴ More than 90% of all recurrences are adjacent to the site of origin, indicating a failure of local tumor control. Conventional radiotherapy plays a primary role in brain cancer treatment. However, its lack of tumor specificity is a significant limitation of this form of therapy. Owing to its nonspecific nature, toxicity to normal brain limits the radiation dose that can be delivered to tumor cells and compromises the quality of life of the few longer term survivors. There are three factors responsible for treatment failure: (1) the delivery of therapeutic agents is limited by the blood-brain barrier (BBB), despite the fact that it is disrupted in regions of macroscopic tumor⁶⁵; (2) dysfunctional tumor vasculature, as is the case in most solid tumors, leads to local hypoxia and a reduced responsiveness to chemo- and radiotherapy in combination with an elevated intratumoral interstitial pressure^{66–68}; (3) inter- and intratumoral cellular and genetic heterogeneity, leading to heterogeneous antigen expression.^{69,70}

In general, adjuvant treatment consists of the use of local radiation by means of stereotactic radiotherapy or brachytherapy with implanted ¹²⁵I rods. However, these approaches did not show additional effects on survival.^{71,72} Recent applications of combinations of chemotherapy (temozolomide) with radiotherapy showed a survival benefit. The majority of patients, however, died within 1–2 years from progressive disease, underlining the need for new treatment strategies.⁷³

The BBB regulates the exchange of substances between the vasculature and the CNS. This physiologic barrier is composed of tight junctions between the capillary endothelial cells and is supported by a microenvironment of astrocytes, pericytes, and microglial cells.⁷⁴ This almost impenetrable barrier prohibits the delivery of potentially effective therapeutic agents, thereby limiting the treatment of CNS diseases. In the case of malignant disease, the deterioration of the BBB may occur, which may improve the delivery of therapeutic agents to the CNS. Brain tumors can cause a complete breakdown of the BBB, eventually leading to peritumoral, vasogenic edema.⁷⁴ Imaging of CNS malignancies, using radiolabeled antibodies, showed intratumoral accumulation following the i.v. administration, allowing for scintigraphic imaging. This indicates damage to the BBB. However, in general, there is insufficient targeting for therapeutic studies.⁷⁵

Table 3. Intra-Squamous Cell Carcinoma Radioimmunotherapy

Author	No. of patients	Indication	Tumor-associated antigen	Antibody	Median survival (months)	Stable disease	Remission	Partial remission	Nuclide	Dose
Bigner et al. ⁸¹	42	GB/AA/AO	TN	81C6					¹³¹ I	100 mCi
Cokgor et al. ⁸³	42	GB/AA/AO	TN	81C6	20 weeks	4/42			¹³¹ I	20–180 mCi
Reardon et al. ⁸⁴	33	GB/AA/AO	TN	81C6	79–85 weeks	0	n.r.	n.r.	¹³¹ I	120 mCi
Reardon et al. ⁸⁵	43	GB/AA/AO	TN	81C6	69 weeks	0	0	0	¹³¹ I	120 mCi
Reardon et al. ⁸⁶	47	GB/AA/AO	TN	ch81C6	89 weeks				¹³¹ I	≤80–100 mCi
Riva et al. ⁸⁸	10	GB	TN	BC-2/4		3/10	1/10	2/10		15 mCi
Riva et al. ⁹⁰	50	GB	TN	BC-2/4	20 months	11/50	3/50	6/50	¹³¹ I	
Riva et al. ⁹¹	111	GB/AA/AO	TN	BC-2/4	19 months	10	1	9	¹³¹ I	70 mCi
Riva et al. ^a	23	GB	TN	BC-2/4	16 months	5/23	3/23	3/23	¹³¹ I	15–57 mCi
Riva et al. ^b	20	GB/AA	TN	BC-4	n.r.	0	0	0	⁹⁰ Y	5–30 mCi
Mamelak et al. ^c	19	GB/AA	TN	TM-601	27 weeks				¹³¹ I	10 mCi
Riva et al. ^b	17	GB					3/17	3/17		
Pöpperl et al. ^d	24	GB/AA	TN		12–87		7/24		¹³¹ I/ ¹⁸⁸ Re	150–13 Mci
Goetz et al. ^e	37	GB/AA	TN		17	n.r.	n.r.	n.r.	¹³¹ I/ ⁹⁰ Y	
Paganelli et al. ⁹³	24	GB/AA	TN	BC-4	11/19	12/24		6/24	⁹⁰ Y	15–30 mCi
Papanastassiou et al. ^f	7	Glioma	NCAM	ERIC-1	n.r.	n.r.	n.r.	n.r.	¹³¹ I	

n.r., not reported.

^aRiva P, Arista A, Tison V, et al. Intralesional radioimmunotherapy of malignant gliomas: An effective treatment in recurrent tumors. *Cancer* 1994;73:1076.

^bRiva P, Franceschi G, Frattarelli M, et al. Loco-regional radioimmunotherapy of high-grade malignant gliomas using specific monoclonal antibodies labeled with ⁹⁰Y: A phase I study. *Clin Cancer Res* 1999;5:3275s.

^cMamelak AN, Rosenfeld S, Bucholz R, et al. Phase I single-dose study of intracavitary-administered iodine-131-TM-601 in adults with recurrent high-grade glioma. *J Clin Oncol* 2006;24:3644.

^dPöpperl G, Gotz C, Rachinger W, et al. Serial O-(2-[(18)F]fluoroethyl)-L- Tyrosine PET for monitoring the effects of intracavitary radioimmunotherapy in patients with malignant glioma. *Eur J Nucl Med Mol Imaging* 2006;33:792.

^eGoetz C, Rachinger W, Poepperl G, et al. Intralesional radioimmunotherapy in the treatment of malignant glioma: Clinical and experimental findings. *Acta Neurochir Suppl* 2003;88:69.

^fPapanastassiou V, Pizer BL, Coakham HB, et al. Treatment of recurrent and cystic malignant gliomas by a single intracavity injection of ¹³¹I monoclonal antibody: Feasibility, pharmacokinetics and dosimetry. *Br J Cancer* 1993;67:144.

To overcome the problem of limited penetration, the locoregional application of therapeutic agents in patients with malignant glioma has been investigated.⁷⁶ To investigate the application of RIT, candidates for therapy, or tumor-associated antigens (TAAs), needed to be identified.

Tenascin-c

In the majority of clinical RIT studies in glioma patients, antitenascin mAbs were used. m81C6, a murine IgG2b with affinity for tenascin-c (TN),

has been administrated through a s.c. implanted reservoir connected to an intracavitary-placed drain. TN is an extracellular matrix protein modulating cell-matrix interactions,⁷⁷ which is over-expressed in malignant glioma tissue, but not expressed in the normal brain. The distribution and intensity of TN expression correlates well with tumor neovasculature and shows evident expression in aggressive histotypes as well as in those tumors with high proliferation indices.^{78–80} This distribution of TN makes it a suitable target in RIT in glioma (see Table 3).

A series of phase I–III studies has been conducted at Duke University. In the first phase I study, 42 patients with recurrent glioma were included and the maximal tolerable dose (MTD) was assessed in a dose-escalation study after intracavitary (into the surgically created cavity; SCC) administration. This study showed that the MTD was 100 mCi for intracavitary-administered ^{131}I -labeled 81C6, with neurotoxicity being the dose-limiting factor.⁸¹ The results of this study suggested that there was a potential survival benefit, as compared to patients treated with stereotactic radiotherapy and high-dose brachytherapy (a median survival of 60 weeks in the present study, as compared to 41 and 46 weeks, respectively). In the second study, 42 patients with newly diagnosed glioma were included in order to investigate dosimetry and dose-response relationships.^{82,83} In these patients, the MTD was 120 mCi, with neurotoxicity being the dose-limiting factor. The median survival of these patients was 79 weeks, as compared to 46 weeks of historic controls, when patients were treated with surgery, chemotherapy, and radiotherapy. Based on these encouraging results, a phase II trial was performed in 33 patients with newly diagnosed, previously untreated patients. The median survival after treatment with 120 mCi of ^{131}I -labeled 81C6 in this study was 79–85 weeks, depending on the pathologic type of glioma (patients with astrocytic oligodendroglioma showed a better response than those with glioblastoma multiforme).⁸⁴ When 100 mCi of radiolabeled antibody was administered to 43 patients with recurrent glioma, survival was still 69 weeks.⁸⁵ The results of these trials warranted a phase III trial, which is currently ongoing.

Recently, a human/mouse chimeric mAb, originating from 81C6, has been developed, showing better tumor targeting in animal studies. The targeting capabilities of the antibody were subsequently tested in a phase I study that included 47 patients with recurrent disease.⁸⁶ This chimeric antibody showed a prolonged retention time within the SCC, as compared to the antibody of murine origin. Owing to the enhanced circulatory half-life of the chimeric antibody, a MTD of 80 mCi was found, as compared to 120 mCi found in previous studies with the murine antibody. In this phase I dose-escalation study, the median survival was 87 weeks for patients with newly diagnosed glioma and 65 weeks for those patients with recurrent disease.

Riva et al. used another anti-tenascin antibody labeled with ^{131}I , BC-2/4, initially injected directly

into the tumor.⁸⁷ Thereafter, the antibody was, in some patients repeatedly, administered into the SCC in 23 patients with recurrent glioblastoma. In their first report, no toxicity and an objective response in 11 patients, in whom were 3 complete remissions and a median survival of 16 months, were reported.⁸⁸ The follow-up study compared the results of antibody administration in recurrent and newly diagnosed patients.⁸⁹ The reported total median survival was 20 months. When bulky (median, 17 months) versus minimal disease (median, 26 months) were compared, the results supported the concept that RIT is most suitable in patients with small-volume disease. Later, combined data of 111 patients that were included in phase I and II studies showed a median survival of 20 months.⁹⁰ The researchers concluded that the application of RIT is most suitable in small-volume disease. In a following phase I study,⁹¹ the researchers switched to the application of another radionuclide, ^{90}Y , in 20 patients and determined the MTD to be 25 mCi with neurotoxicity as the dose-limiting toxicity. No diffusion of the radiolabeled antibody to normal tissue was reported. However, this study failed to show clinical responses, presumably owing to the inclusion of patients with advanced disease.

Paganelli et al.^{92,93} investigated the use of the pretargeting technique consisting of the biotinylated antitenascin MAb BC4, avidin and ^{90}Y -biotin, both i.v. administered as well as directly into the SCC, following surgical debulking. In this pretargeting approach, the large IgG-avidin conjugate was administered first, followed by a ^{90}Y -labeled biotin injection. These studies showed no hematologic toxicity following the RIT when applied into the SCC, as compared to almost all the other studies that used mAbs, including the study where pretargeting was used and administered i.v. This latter study supports the local administration technique by showing a total body distribution of the biotinylated mAb and fast blood clearance within hours after the i.v. administration.

To summarize, the phase I–II studies from Duke University on the use of adjuvant RIT after debulking surgery in patients with malignant glioma indicate an improved survival, as compared to historic control groups. In addition, there was a reduction in treatment-related toxicity, compared to stereotactic radiotherapy or brachytherapy. This resulted in a phase III trial that is currently ongoing. The results from Riva et al., despite the more heterogeneous group of patients, support this conclusion.

Table 4. Intravesical Radioimmunoscintigraphy

<i>Author</i>	<i>No. of patients</i>	<i>Indication</i>	<i>Tumor-associated antigen</i>	<i>Antibody</i>	<i>Nuclide</i>	<i>Targeting</i>
Bamias et al. ⁹⁸	21	SUC	MUC1	HMFG2	¹¹¹ In	+
Simms et al. ^a	21	SUC-T2-metastatic invasive bladder cancer	MUC1	C595	^{99m} Tc	16/20
Murray et al. ⁹⁹	5	TCC	MUC1	C595	¹⁸⁸ Re	4/5
Hughes et al. ¹⁰⁰	16	SUC-T2	MUC1	C595	⁶⁷ Cu	12/16
Malamitsi et al. ¹⁰¹	15	SUC	MUC1	HMFG1	^{99m} Tc/ ¹³¹ I	±
Chinol et al. ^b	12	TCC	n.r.	Avidin	^{99m} Tc	10/12
Syrigos ^c	6	SUC	MUC1	HMFG1	¹³¹ I	4/6
Kunkler et al. ^d	12	SUC	MUC1	NCRC48	¹¹¹ In	+

n.r., not reported.

^aSimms MS, Perkins AC, Price MR, et al. ^{99m}Technetium-C595 radioimmunoscintigraphy: A potential staging tool for bladder cancer. *BJU Int* 2001;88:686.

^bChinol M, De CO, Trifiro G, et al. Localization of avidin in superficial bladder cancer: A potentially new approach for radionuclide therapy. *Eur Urol* 2003;44:556.

^cSyrigos KN, Khawaja M, Krausz T, et al. Intravesical administration of radiolabelled tumour-associated monoclonal antibody in bladder cancer. *Acta Oncol* 1999;38:379.

^dKunkler RB, Bishop MC, Green DJ, et al. Targeting of bladder cancer with monoclonal antibody NCRC48—a possible approach for intravesical therapy. *Br J Urol* 1995;76:81.

INTRAVESICAL RIT

Bladder cancer is the second most common cancer of the genito-urinary system, mainly occurring in men. Two distinct types of urothelial cancer exist, the majority of which are superficial and noninvasive. However, the remaining 20% are solid, highly aggressive bladder cancers that are invasive and metastasize in an early phase of the disease.⁹⁴ Cystectomy is the treatment of choice for a tumor stage of T2–T4 (muscle invasive), leaving local resection to CIS and T1 disease. In T1 urothelial carcinoma recurrence rates are as high as 80% after resection.⁹⁵ When intravesical chemotherapy is added to surgery, recurrence rates are reduced by 50% at 2 years. Part of the contemporary bladder-sparing treatment is the use of immunotherapy by means of an intravesical Bacille Calmette-Guérin (BCG) instillation, the results of which are comparable to those achieved with chemotherapy.⁹⁶ Since the standard therapy in invasive bladder cancer is radical cystectomy, the role of RIT is limited to CIS and T1 disease.

Despite several preclinical experiments, reports on the clinical use of radiolabeled antibodies in patients with bladder cancer are limited to investigations on radioimmunoscintigraphy studies rather

than RIT (see Table 4). In these studies, antibodies directed against the target antigen MUC-1 are used. MUC-1 mucin is a high-molecular-weight cell-surface glycoprotein that is found on normal urothelium and that is both unregulated as well as abnormally glycosylated in bladder cancer.⁹⁷ One of the first studies in 20 patients was performed by Bamias et al., who intravesically administered the ¹¹¹In-labeled anti-MUC-1 antibody HMFG2.⁹⁸ Autoradiography of the resected specimen showed selective tumor targeting. Murray et al. used an intravesically administered ¹⁸⁸Re-labeled C595 antibody in 3 patients with transitional cell carcinoma.⁹⁹ In addition, this group investigated the intravesical administration of ⁶⁷Cu-labeled C595 in 16 patients with bladder cancer and studied the systemic absorption of the radiolabeled antibody.¹⁰⁰ The results of this study showed no detectable activity above the background, meaning there was no systemic radiolabel present after the local application, while 80% of the tumors were successfully visualized.

Malamitsi et al. investigated the intravesical application of ^{99m}Tc-labeled MUC-1 antibody HMFG1 in 14 patients and concluded that, despite the excellent imaging of tumors, future attempts to administer RIT using HMFG1 should not be undertaken owing to a low and heteroge-

neous uptake in the 6 patients with positive imaging (0%–9% injected dose) caused by heterogeneous antigen expression.¹⁰¹

In conclusion, intravesically administered RIS in bladder cancer may hold a promise for RIT, using anti-MUC1 antibodies, in early urothelial cell cancer owing to selective targeting and low systemic concentrations of the targeting agent.

INTRATHORACIC RIT

The prognosis of patients with malignant pleural mesothelioma (MPM) is poor. In general, median survival is 6–16 months. The malignant form can be classified in two categories: diffuse or localized. Both are essentially insensitive to any treatment.¹⁰² Different agents for intracavitary chemotherapy to treat mesothelioma have been utilized. The response rate varied between 15% and 37%, without effect on survival, even when used in combination with paclitaxel and docetaxel. The clinical data regarding studies that used intrathoracic chemotherapy adjuvant to surgical debulking were disappointing.^{103,104} Therefore, the intrathoracic application of chemotherapeutic agents is mainly used to treat malignant pleural effusion.^{105,106} Another obstacle for RIT of mesothelioma is the low tumor antigen (mesothelin, tenascin-c) expression.¹⁰⁷ Enhancing antigen expression with proinflammatory cytokines, however, do not improve survival after immunotherapy.¹⁰⁸

Mesothelin is a 40-kD cell-surface glycosylated phosphatidylinositol (GPI)-anchored glycoprotein, with functions in cell-to-cell adhesion expressed by normal mesothelial cells. It is highly overexpressed in cancers as malignant mesothelioma, pancreatic or ovarian carcinoma sarcomas, and in some gastrointestinal or pulmonary carcinomas.¹⁰⁹ In preclinical studies, Hassan et al. and Fan et al. have used antimethelin antibodies and antibody fragments linked to exotoxins to treat mesothelin-expressing tumors in nude mice. The development of experimental metastases was inhibited, and even a complete regression of the tumor was observed in some cases.^{110,111}

In conclusion, this antigen may be an attractive target for the intrathoracic application of RIT, but no clinical RIT studies have been performed. Currently, a clinical trial is being conducted, using a chimeric mAb (MORAb-009) directed against a cell-surface glycoprotein, GP-9, that is overexpressed in epithelial type cancers as mesothelioma,

ovarian, and pancreatic cancer.* GP-9 may, therefore, be a potentially suitable target for radiolabeled MORAb-009 in future RIT of MPM.

Malignant pleural effusion (MPE)

MPE is thought to arise from tumor emboli detaching from visceral tumor nodules and concomitant attachment to the parietal pleura. Also, direct tumor invasion (in lung cancers, chest wall neoplasms, and breast carcinoma), hematogenous spread to the parietal pleura, and lymphatic involvement may be a mechanism for development of MPE. The effusion is composed of extracellular matrix proteins, cytokines, and growth factors, thereby promoting cell proliferation and invasion.¹¹² In women, the most common causes of these effusions are breast and ovarian cancer, whereas in men, these are lung cancer and malignant pleural mesothelioma. Treatment of this specific entity can be done by either therapeutical pleur aspiration (in case of a very short life expectancy), talc pleurodesis, or indwelling catheters. MPM with MPE is also an indication for intrapleural therapy, as is the case with MPE arising from ovarian cancer. Schmidt et al. described the successful intrapleural application of rituximab, an anti-CD20 mAb, in a patient with NHL who was free of symptoms for 8 months after this treatment.¹¹³ The researchers described a case report regarding treatment failure of repeated percutaneous drainage and bilateral continuous chest tube drainage. This result may be promising, in particular when considering the possibilities of the effects of the application of radiolabeled antibodies. This is the case with ⁹⁰Y-labeled ibritumomab tiuxetan for the treatment of NHL, where the RIC produces significantly better responses than the mAb alone.¹¹⁴

Awaiting the results of the trial using MORAb-009 in the case of MPM and the future development of TAAs directed against MPM, there may be a role for RIT in the treatment of MPM. In addition, RIT may play a role in the palliative treatment in patients with MPE, regardless of the origin of the primary tumor.

DISCUSSION

The intracavitary application of radiolabeled antibodies combines the advantage of high tumor

*Source: Trial number: NCT00325494. www.clinicaltrials.gov Accessed January 28, 2008.

doses and low systemic toxicity. Therefore, higher doses of RIT can be applied than with systemic administration.

Currently, RIT with radiolabeled anti-CD20 antibodies is an accepted treatment for patients with NHL. For other indications, only a limited number of clinical phase I/II and one phase III RIT trials have been performed, using different antibodies and radionuclides in patients with different types of cancer. The results various studies on the therapeutic efficacy and toxicity of RIT in patients with ovarian cancer (^{90}Y -HMFG-1, ^{177}Lu -B72.3) and malignant glioma (^{131}I -81C6) indicate that the adjuvant application of RIT within a confined area limits toxicity and improves tumor targeting. In addition, RIT should be applied as a treatment of patients with minimal residual or microscopic disease of solid cancers in order to gain from its maximal potential.

For the treatment of ovarian cancer, the application of RIT was studied in a randomized, phase III trial. Unfortunately, the results of the latter study showed no survival benefit. The lack of efficacy of adjuvant RIT in this trial could be owing to several factors. First, the selection of the high-energy beta-emitter ^{90}Y , with a maximum tissue penetration of 12 mm, is not appropriate, since most of the energy will be deposited outside small tumor deposits in small-volume or microscopic disease. Second, the protein dose was augmented with 20 mg of unlabeled antibody to a total of 25 mg ^{90}Y -HMFG1, with the intent to provoke a human antimouse antibody response. This high antibody dose might have had a negative effect on the uptake of the radiolabel in the tumor lesions owing to the saturation of MUC-1 epitopes on the tumor cells.¹¹⁵ In the future, however, optimizing this treatment, using nuclides such as ^{177}Lu that are more suitable for minimal residual disease than ^{90}Y in order to enhance the antitumor effect, may result in survival benefit. The same can be true for the treatment of peritoneal carcinomatosis of colorectal origin when trials will be undertaken to treat this entity. Progress has been made in the treatment of recurrent glioma by the application of RIT and this treatment may, therefore, become an additional adjuvant treatment modality in neuro-oncology.

CONCLUSIONS

In the case of superficial bladder cancer, promising results of preclinical and radioimmuno-

scintigraphy studies may precede phase I and II trials. When therapeutic options are no longer available, RIT may offer patients a chance of minimally invasive palliation in patients with MPM or MPE. The future of RIT may, therefore, not only be in the inclusion in contemporary multimodality treatment, but also in the expansion of its indication to palliative treatment as a supplement or even a substitution for present-day treatments.

ACKNOWLEDGMENTS

The authors wish to thank Professor Dr. André Grotenhuis (Department of Neurosurgery, Radboud University Nijmegen Medical Center Nijmegen, The Netherlands) for his valuable comments on earlier versions of this manuscript.

REFERENCES

1. Goyle S, Maraveyas A. Chemotherapy for colorectal cancer. *Dig Surg* 2005;22:401.
2. Yan T, Welch L, Black D, et al. A systematic review on the efficacy of cytoreductive surgery combined with perioperative intraperitoneal chemotherapy for diffuse malignancy peritoneal mesothelioma. *Ann Oncol* 2007;18:827.
3. Fisher RI, Kaminski MS, Wahl RL, et al. Tositumomab and iodine-131 tositumomab produces durable complete remissions in a subset of heavily pretreated patients with low-grade and transformed non-Hodgkin's lymphomas. *J Clin Oncol* 2005;23:7565.
4. Davis TA, Kaminski MS, Leonard JP, et al. The radioisotope contributes significantly to the activity of radioimmunotherapy. *Clin Cancer Res* 2004;10:7792.
5. Gordon LI, Molina A, Witzig T, et al. Durable responses after ibritumomab tiuxetan radioimmunotherapy for CD20⁺ B-cell lymphoma: Long-term follow-up of a phase 1/2 study. *Blood* 2004;103:4429.
6. Kaanders JH, Bussink J, van der Kogel AJ. ARCON: A novel biology-based approach in radiotherapy. *Lancet Oncol* 2002;3:728.
7. Kaanders JH, Bussink J, van der Kogel AJ. Clinical studies of hypoxia modification in radiotherapy. *Semin Radiat Oncol* 2004;14:233.
8. Heldin CH. High interstitial fluid pressure—an obstacle in cancer therapy. *Nat Rev Cancer* 2004;4:806.
9. Koppe MJ, Soede AC, Pels W, et al. Experimental radioimmunotherapy of small peritoneal metastases of colorectal origin. *Int J Cancer* 2003;106:965.
10. Colcher D, Esteban J, Carrasquillo JA, et al. Complementation of intracavitary and intravenous administration of a monoclonal antibody (B72.3) in patients with carcinoma. *Cancer Res* 1987;47:4218.

11. Kohler G, Milstein C. Continuous cultures of fused cells secreting antibody of predefined specificity. *Nature* 1975;256:495.
12. Goldenberg DM, Sharkey RM. Advances in cancer therapy with radiolabeled monoclonal antibodies. *Q J Nucl Med Mol Imaging* 2006;50:248.
13. Harris M. Monoclonal antibodies as therapeutic agents for cancer. *Lancet Oncol* 2004;5:292.
14. Lin MZ, Teitell MA, Schiller GJ. The evolution of antibodies into versatile tumor-targeting agents. *Clin Cancer Res* 2005;11:129.
15. Sharkey RM, Blumenthal RD, Behr TM, et al. Selection of radioimmunconjugates for the therapy of well-established or micrometastatic colon carcinoma. *Int J Cancer* 1997;72:477.
16. Uusijarvi H, Bernhardt P, Rosch F, et al. Electron- and positron-emitting radiolanthanides for therapy: Aspects of dosimetry and production. *J Nucl Med* 2006;47:807.
17. Shih LB, Thorpe SR, Griffiths GL, et al. The processing and fate of antibodies and their radiolabels bound to the surface of tumor cells *in vitro*: A comparison of nine radiolabels. *J Nucl Med* 1994;35:899.
18. Koppe MJ, Bleichrodt RP, Soede AC, et al. Biodistribution and therapeutic efficacy of (125/131)I-, (186)Re-, (88/90)Y-, or (177)Lu-labeled monoclonal antibody MN-14 to carcinoembryonic antigen in mice with small peritoneal metastases of colorectal origin. *J Nucl Med* 2004;45:1224.
19. Novak-Hofer I, Schubiger PA. Copper-67 as a therapeutic nuclide for radioimmunotherapy. *Eur J Nucl Med Mol Imaging* 2002;29:821.
20. Yao V, Platell C, Hall JC. Role of peritoneal mesothelial cells in peritonitis. *Br J Surg* 2003;90:1187.
21. Dedrick RL, Flessner MF. Pharmacokinetic considerations on monoclonal antibodies. *Prog Clin Biol Res* 1989;288:429.
22. Flessner MF, Dedrick RL. Monoclonal antibody delivery to intraperitoneal tumors in rats: Effects of route of administration and intraperitoneal solution osmolality. *Cancer Res* 1994;54:4376.
23. van Ruth S, Verwaal VJ, Zoetmulder FA. Pharmacokinetics of intraperitoneal mitomycin C. *Surg Oncol Clin N Am* 2003;12:771.
24. Koppe MJ, Bleichrodt RP, Soede AC, et al. Biodistribution and therapeutic efficacy of (125/131)I-, (186)Re-, (88/90)Y-, or (177)Lu-labeled monoclonal antibody MN-14 to carcinoembryonic antigen in mice with small peritoneal metastases of colorectal origin. *J Nucl Med* 2004;45:1224.
25. Koppe MJ, Soede AC, Pels W, et al. Experimental radioimmunotherapy of small peritoneal metastases of colorectal origin. *Int J Cancer* 2003;106:965.
26. van Zanten-Przybyls I, Molthoff CF, Roos JC, et al. Influence of the route of administration on targeting of ovarian cancer with the chimeric monoclonal antibody MOv18: i.v. vs. i.p. *Int J Cancer* 2001;92:106.
27. Dubeau L. The cell of origin of ovarian epithelial tumors and the ovarian surface epithelium dogma: Does the emperor have no clothes? *Gynecol Oncol* 1999;72:437.
28. Bhoola S, Hoskins WJ. Diagnosis and management of epithelial ovarian cancer. *Obstet Gynecol* 2006;107:1399.
29. Ozols RF. Systemic therapy for ovarian cancer: Current status and new treatments. *Semin Oncol* 2006;33:S3.
30. Rubin SC. Monoclonal antibodies in the management of ovarian cancer. A clinical perspective. *Cancer* 1993;71:1602.
31. Haisma HJ, Moseley KR, Battaile AI, et al. Biodistribution, pharmacokinetics, and imaging of ¹³¹I-labelled OC125 in ovarian cancer. *Int J Cancer Suppl* 1988;2:109.
32. Buijs WC, Tibben JG, Boerman OC, et al. Dosimetric analysis of chimeric monoclonal antibody cMOv18 IgG in ovarian carcinoma patients after intraperitoneal and intravenous administration. *Eur J Nucl Med* 1998;25:1552.
33. Kalofonos HP, Karamouzis MV, Epenetos AA. Radioimmunoscinigraphy in patients with ovarian cancer. *Acta Oncol* 2001;40:549.
34. Epenetos AA, Munro AJ, Stewart S, et al. Antibody-guided irradiation of advanced ovarian cancer with intraperitoneally administered radiolabeled monoclonal antibodies. *J Clin Oncol* 1987;5:1890.
35. Nicholson S, Gooden CS, Hird V, et al. Radioimmunotherapy after chemotherapy compared to chemotherapy alone in the treatment of advanced ovarian cancer: A matched analysis. *Oncol Rep* 1998;5:223.
36. Epenetos AA, Hird V, Lambert H, et al. Long-term survival of patients with advanced ovarian cancer treated with intraperitoneal radioimmunotherapy. *Int J Gynecol Cancer* 2000;10:44.
37. Verheijen RH, Massuger LF, Benigno BB, et al. Phase III trial of intraperitoneal therapy with yttrium-90-labeled HMFG1 murine monoclonal antibody in patients with epithelial ovarian cancer after a surgically defined complete remission. *J Clin Oncol* 2006;24:571.
38. Massuger LF, Verheijen RH, Seiden MV. Intraperitoneal disease control after i.p. consolidation treatment with yttrium-90-labeled HMFG1 monoclonal antibody in patients with epithelial ovarian cancer. Annual Meeting on Women's Cancer of the Society of Gynecologic Oncologists, Miami Beach, FL, March 19–23, 2005.
39. Rosenblum MG, Kavanagh JJ, Burke TW, et al. Clinical pharmacology, metabolism, and tissue distribution of ⁹⁰Y-labeled monoclonal antibody B72.3 after intraperitoneal administration. *J Natl Cancer Inst* 1991;83:1629.
40. Meredith RF, Partridge EE, Alvarez RD, et al. Intraperitoneal radioimmunotherapy of ovarian cancer with lutetium-177-CC49. *J Nucl Med* 1996;37:1491.
41. Rosenblum MG, Verschraegen CF, Murray JL, et al. Phase I study of ⁹⁰Y-labeled B72.3 intraperitoneal administration in patients with ovarian cancer: Effect of dose and EDTA coadministration on pharmacokinetics and toxicity. *Clin Cancer Res* 1999;5:953.

42. Alvarez RD, Partridge EE, Khazaeli MB, et al. Intraperitoneal radioimmunotherapy of ovarian cancer with ¹⁷⁷Lu-CC49: A phase I/II study. *Gynecol Oncol* 1997;65:94.
43. Roselli M, Guadagni F, Buonomo O, et al. Systemic administration of recombinant interferon alfa in carcinoma patients upregulates the expression of the carcinoma-associated antigens tumor-associated glycoprotein-72 and carcinoembryonic antigen. *J Clin Oncol* 1996;14:2031.
44. Meredith RF, Alvarez RD, Partridge EE, et al. Intraperitoneal radioimmunochemotherapy of ovarian cancer: A phase I study. *Cancer Biother Radiopharm* 2001;16:305.
45. Miotti S, Facheris P, Tomassetti A, et al. Growth of ovarian-carcinoma cell lines at physiological folate concentration: Effect on folate-binding protein expression *in vitro* and *in vivo*. *Int J Cancer* 1995;63:395.
46. Crippa F, Bolis G, Seregini E, et al. Single-dose intraperitoneal radioimmunotherapy with the murine monoclonal antibody I-131 MOv18: Clinical results in patients with minimal residual disease of ovarian cancer. *Eur J Cancer* 1995;31A:686.
47. Mahe MA, Fumoleau P, Fabbro M, et al. A phase II study of intraperitoneal radioimmunotherapy with iodine-131-labeled monoclonal antibody OC-125 in patients with residual ovarian carcinoma. *Clin Cancer Res* 1999;5:3249s.
48. O'Brien TJ, Tanimoto H, Konishi I, et al. More than 15 years of CA 125: What is known about the antigen, its structure, and its function. *Int J Biol Markers* 1998;13:188.
49. Haisma HJ, Battaile A, Stradtman EW, et al. Antibody-antigen complex formation following injection of OC125 monoclonal antibody in patients with ovarian cancer. *Int J Cancer* 1987;40:758.
50. Koppe MJ, Boerman OC, Oyen WJ, et al. Peritoneal carcinomatosis of colorectal origin: Incidence and current treatment strategies. *Ann Surg* 2006;243:212.
51. Jayne DG, Fook S, Loi C, et al. Peritoneal carcinomatosis from colorectal cancer. *Br J Surg* 2002;89:1545.
52. Glehen O, Cotte E, Schreiber V, et al. Intraperitoneal chemohyperthermia and attempted cytoreductive surgery in patients with peritoneal carcinomatosis of colorectal origin. *Br J Surg* 2004;91:747.
53. Culliford AT, Brooks AD, Sharma S, et al. Surgical debulking and intraperitoneal chemotherapy for established peritoneal metastases from colon and appendix cancer. *Ann Surg Oncol* 2001;8:787.
54. Glehen O, Kwiatkowski F, Sugarbaker PH, et al. Cytoreductive surgery combined with perioperative intraperitoneal chemotherapy for the management of peritoneal carcinomatosis from colorectal cancer: A multi-institutional study. *J Clin Oncol* 2004;22:3284.
55. Elias D, Blot F, El OA, et al. Curative treatment of peritoneal carcinomatosis arising from colorectal cancer by complete resection and intraperitoneal chemotherapy. *Cancer* 2001;92:71.
56. Meredith RF, Khazaeli MB, Liu T, et al. Dose fractionation of radiolabeled antibodies in patients with metastatic colon cancer. *J Nucl Med* 1992;33:1648.
57. Koppe MJ, Bleichrodt RP, Oyen WJ, et al. Radioimmunotherapy and colorectal cancer. *Br J Surg* 2005;92:264.
58. Riva P, Tison V, Arista A, et al. Radioimmunotherapy of gastrointestinal cancer and glioblastomas. *Int J Biol Markers* 1993;8:192.
59. Keenan AM, Colcher D, Larson SM, et al. Radioimmunoscintigraphy of human colon cancer xenografts in mice with radioiodinated monoclonal antibody B72.3. *J Nucl Med* 1984;25:1197.
60. Koppe MJ, Soede AC, Pels W, et al. Experimental radioimmunotherapy of small peritoneal metastases of colorectal origin. *Int J Cancer* 2003;106:965.
61. Koppe MJ, Bleichrodt RP, Soede AC, et al. Biodistribution and therapeutic efficacy of (125/131)I-, (186)Re-, (88/90)Y-, or (177)Lu-labeled monoclonal antibody MN-14 to carcinoembryonic antigen in mice with small peritoneal metastases of colorectal origin. *J Nucl Med* 2004;45:1224.
62. Koppe MJ, Hendriks T, Boerman OC, et al. Radioimmunotherapy is an effective adjuvant treatment modality after cytoreductive surgery of peritoneal carcinomatosis of colonic origin. *J Nucl Med* 2006;47:1867.
63. Reardon DA, Rich JN, Friedman HS, et al. Recent advances in the treatment of malignant astrocytoma. *J Clin Oncol* 2006;24:1253.
64. Ohgaki H, Dessen P, Jourde B, et al. Genetic pathways to glioblastoma: A population-based study. *Cancer Res* 2004;64:6892.
65. Brooks DJ, Beany RP, Lammertsma AA, et al. Quantitative measurement of blood-brain barrier permeability using rubidium-82 and positron emission tomography. *J Cereb Blood Flow Metab* 1984;4:535.
66. Vajkoczy P, Menger MD. Vascular microenvironment in gliomas. *Cancer Treat Res* 2004;117:249.
67. Evans SM, Judy KD, Dunphy I, et al. Hypoxia is important in the biology and aggression of human glial brain tumors. *Clin Cancer Res* 2004;10:8177.
68. Jain RK. Delivery of molecular medicine to solid tumors: Lessons from *in vivo* imaging of gene expression and function. *J Contr Rel* 2001;74:7.
69. Burger PC, Vogel FS, Green SB, et al. Glioblastoma multiforme and anaplastic astrocytoma. Pathologic criteria and prognostic implications. *Cancer* 1985;56:1106.
70. Kleihues P, Sobin LH. World Health Organization classification of tumors. *Cancer* 2000;88:2887.
71. Souhami L, Seiferheld W, Brachman D, et al. Randomized comparison of stereotactic radiosurgery followed by conventional radiotherapy with carmustine to conventional radiotherapy with carmustine for patients with glioblastoma multiforme: report of Radiation Therapy Oncology Group 93-05 protocol. *Int J Radiat Oncol Biol Phys* 2004;60:853.
72. Selker RG, Shapiro WR, Burger P, et al. The Brain Tumor Cooperative Group NIH Trial 87-01: A ran-

- domized comparison of surgery, external radiotherapy, and carmustine versus surgery, interstitial radiotherapy boost, external radiation therapy, and carmustine. *Neurosurgery* 2002;51:343.
73. Stupp R, Mason WP, van den Bent MJ, et al. Radiotherapy plus concomitant and adjuvant temozolomide for glioblastoma. *N Engl J Med* 2005;352:987.
 74. Arismendi-Morillo G, Castellano A. Tumoral micro-blood vessels and vascular microenvironment in human astrocytic tumors. A transmission electron microscopy study. *J Neurooncol* 2005;73:211.
 75. Schold SC, Jr, Zalutsky MR, Coleman RE, et al. Distribution and dosimetry of I-123-labeled monoclonal antibody 81C6 in patients with anaplastic glioma. *Invest Radiol* 1993;28:488.
 76. Guerin C, Olivi A, Weingart JD, et al. Recent advances in brain tumor therapy: Local intracerebral drug delivery by polymers. *Invest New Drugs* 2004;22:27.
 77. Hsia HC, Schwarzbauer JE. Meet the tenascins: Multifunctional and mysterious. *J Biol Chem* 2005;280:26641.
 78. Zagzag D, Friedlander DR, Dosik J, et al. Tenascin-C expression by angiogenic vessels in human astrocytomas and by human brain endothelial cells *in vitro*. *Cancer Res* 1996;56:182.
 79. McLendon RE, Wikstrand CJ, Matthews MR, et al. Glioma-associated antigen expression in oligodendroglial neoplasms. Tenascin and epidermal growth factor receptor. *J Histochem Cytochem* 2000;48:1103.
 80. Kim CH, Bak KH, Kim YS, et al. Expression of tenascin-C in astrocytic tumors: Its relevance to proliferation and angiogenesis. *Surg Neurol* 2000;54:235.
 81. Bigner DD, Brown MT, Friedman AH, et al. Iodine-131-labeled antitenascin monoclonal antibody 81C6 treatment of patients with recurrent malignant gliomas: Phase I trial results. *J Clin Oncol* 1998;16:2202.
 82. Akabani G, Cokgor I, Coleman RE, et al. Dosimetry and dose-response relationships in newly diagnosed patients with malignant gliomas treated with iodine-131-labeled anti-tenascin monoclonal antibody 81C6 therapy. *Int J Radiat Oncol Biol Phys* 2000;46:947.
 83. Cokgor I, Akabani G, Kuan CT, et al. Phase I trial results of iodine-131-labeled antitenascin monoclonal antibody 81C6 treatment of patients with newly diagnosed malignant gliomas. *J Clin Oncol* 2000;18:3862.
 84. Reardon DA, Akabani G, Coleman RE, et al. Phase II trial of murine (131)I-labeled antitenascin monoclonal antibody 81C6 administered into surgically created resection cavities of patients with newly diagnosed malignant gliomas. *J Clin Oncol* 2002;20:1389.
 85. Reardon DA, Akabani G, Coleman RE, et al. Salvage radioimmunotherapy with murine iodine-131-labeled antitenascin monoclonal antibody 81C6 for patients with recurrent primary and metastatic malignant brain tumors: Phase II study results. *J Clin Oncol* 2006;24:115.
 86. Reardon DA, Quinn JA, Akabani G, et al. Novel human IgG2b/murine chimeric antitenascin monoclonal antibody construct radiolabeled with ¹³¹I and administered into the surgically created resection cavity of patients with malignant glioma: Phase I trial results. *J Nucl Med* 2006;47:912.
 87. Riva P, Arista A, Sturiale C, et al. Treatment of intracranial human glioblastoma by direct intratumoral administration of ¹³¹I-labeled anti-tenascin monoclonal antibody BC-2. *Int J Cancer* 1992;51:7.
 88. Riva P, Arista A, Tison V, et al. Intralesional radioimmunotherapy of malignant gliomas. An effective treatment in recurrent tumors. *Cancer* 1994;73:1076.
 89. Riva P, Arista A, Franceschi G, et al. Local treatment of malignant gliomas by direct infusion of specific monoclonal antibodies labeled with ¹³¹I: Comparison of the results obtained in recurrent and newly diagnosed tumors. *Cancer Res* 1995;55:5952s.
 90. Riva P, Franceschi G, Frattarelli M, et al. ¹³¹I radio-conjugated antibodies for the locoregional radioimmunotherapy of high-grade malignant glioma—phase I and II study. *Acta Oncol* 1999;38:351.
 91. Riva P, Franceschi G, Frattarelli M, et al. Locoregional radioimmunotherapy of high-grade malignant gliomas using specific monoclonal antibodies labeled with ⁹⁰Y: A phase I study. *Clin Cancer Res* 1999;5:3275s.
 92. Paganelli G, Bartolomei M, Ferrari M, et al. Pretargeted locoregional radioimmunotherapy with ⁹⁰Y-biotin in glioma patients: Phase I study and preliminary therapeutic results. *Cancer Biother Radiopharm* 2001;16:227.
 93. Paganelli G, Grana C, Chinol M, et al. Antibody-guided three-step therapy for high grade glioma with yttrium-90 biotin. *Eur J Nucl Med* 1999;26:348.
 94. Dinney CP. Therapy of invasive bladder cancer. *Urology* 2006;67:56.
 95. Nieder AM, Brausi M, Lamm D, et al. Management of stage T1 tumors of the bladder: International Consensus Panel. *Urology* 2005;66:108.
 96. Shelley MD, Court JB, Kynaston H, et al. Intravesical Bacillus Calmette-Guerin versus Mitomycin C for Ta and T1 Bladder Cancer. *Cochrane Database Syst Rev* 2003;3:CD003231
 97. Walsh MD, Hohn BG, Thong W, et al. Mucin expression by transitional cell carcinomas of the bladder. *Br J Urol* 1994;73:256.
 98. Bamias A, Bowles MJ, Krausz T, et al. Intravesical administration of indium-111-labelled HMFG2 monoclonal antibody in superficial bladder carcinomas. *Int J Cancer* 1993;54:899.
 99. Murray A, Simms MS, Scholfield DP, et al. Production and characterization of 188Re-C595 antibody for radioimmunotherapy of transitional cell bladder cancer. *J Nucl Med* 2001;42:726.
 100. Hughes OD, Bishop MC, Perkins AC, et al. Targeting superficial bladder cancer by the intravesical administration of copper-67-labeled anti-MUC1 mucin monoclonal antibody C595. *J Clin Oncol* 2000;18:363.
 101. Malamitsi J, Zorzos J, Varvarigou AD, et al. Immunolocalization of transitional cell carcinoma of the bladder with intravesically administered technetium-99m labelled HMFG1 monoclonal antibody. *Eur J Nucl Med* 1995;22:25.

102. Sterman DH, Kaiser LR, Albelda SM. Advances in the treatment of malignant pleural mesothelioma. *Chest* 1999;116:504.
103. van Ruth S, Baas P, Haas RL, et al. Cytoreductive surgery combined with intraoperative hyperthermic intrathoracic chemotherapy for stage I malignant pleural mesothelioma. *Ann Surg Oncol* 2003;10:176.
104. van Ruth S, van TO, Korse CM, et al. Pharmacokinetics of doxorubicin and cisplatin used in intraoperative hyperthermic intrathoracic chemotherapy after cytoreductive surgery for malignant pleural mesothelioma and pleural thymoma. *Anticancer Drugs* 2003;14:57.
105. Kasahara K, Shibata K, Shintani H, et al. Randomized, phase II trial of OK-432 in patients with malignant pleural effusion due to non-small-cell lung cancer. *Anticancer Res* 2006;26:1495.
106. Eitan R, Levine DA, bu-Rustum N, et al. The clinical significance of malignant pleural effusions in patients with optimally debulked ovarian carcinoma. *Cancer* 2005;103:1397.
107. Fitzpatrick DR, Peroni DJ, Bielefeldt-Ohmann H. The role of growth factors and cytokines in the tumorigenesis and immunobiology of malignant mesothelioma. *Am J Respir Cell Mol Biol* 1995;12:455.
108. Robinson BW, Lake RA. Advances in malignant mesothelioma. *N Engl J Med* 2005;353:1591.
109. Scherpereel A, Grigoriu B, Conti M, et al. Soluble mesothelin-related peptides in the diagnosis of malignant pleural mesothelioma. *Am J Respir Crit Care Med* 2006;173:1155.
110. Hassan R, Viner JL, Wang QC, et al. Anti-tumor activity of K1-LysPE38QQR, an immunotoxin targeting mesothelin, a cell-surface antigen overexpressed in ovarian cancer and malignant mesothelioma. *J Immunother* 2000;23:473.
111. Fan D, Yano S, Shinohara H, et al. Targeted therapy against human lung cancer in nude mice by high-affinity recombinant antimesothelin single-chain Fv immunotoxin. *Mol Cancer Ther* 2002;1:595.
112. Lynch CC, Matrisian LM. Matrix metalloproteinases in tumor-host cell communication. *Differentiation* 2002;70:561.
113. Schmidt HH, Renner H, Linkesch W. Intrapleural instillation of rituximab for the treatment of malignant pleural effusions in NHL. *Haematologica* 2004;89: ECR39.
114. Witzig TE, Gordon LI, Cabanillas F, et al. Randomized, controlled trial of yttrium-90-labeled ibritumomab tiuxetan radioimmunotherapy versus rituximab immunotherapy for patients with relapsed or refractory low-grade, follicular, or transformed B-cell non-Hodgkin's lymphoma. *J Clin Oncol* 2002;20:2453.
115. Kranenborg MH, Boerman OC, de Weijert MC, et al. The effect of antibody protein dose of anti-renal cell carcinoma monoclonal antibodies in nude mice with renal cell carcinoma xenografts. *Cancer* 1997;80:2390.

This article has been cited by:

1. Csilla Hasovits, Stephen Clarke. 2012. Pharmacokinetics and Pharmacodynamics of Intraperitoneal Cancer Chemotherapeutics. *Clinical Pharmacokinetics* **51**:4, 203-224. [[CrossRef](#)]
2. Robert M Sharkey, David M Goldenberg. 2011. Cancer radioimmunotherapy. *Immunotherapy* **3**:3, 349-370. [[CrossRef](#)]
3. Nobuyuki Kosaka, Mikako Ogawa, David S. Paik, Chang H. Paik, Peter L. Choyke, Hisataka Kobayashi. 2010. Semiquantitative assessment of the microdistribution of fluorescence-labeled monoclonal antibody in small peritoneal disseminations of ovarian cancer. *Cancer Science* **101**:3, 820-825. [[CrossRef](#)]