



Intraocular cytokine profile and autoimmune reactions in retinitis pigmentosa, age-related macular degeneration, glaucoma and cataract

Josianne C. ten Berge,¹  Zainab Fazil,¹ Ingeborgh van den Born,² Roger C. W. Wolfs,¹ Marco W. J. Schreurs,³ Wim A. Dik^{3,†} and Aniki Rothova^{1,†} 

¹Department of Ophthalmology, Erasmus Medical Center, Rotterdam, the Netherlands

²The Rotterdam Eye Hospital, Rotterdam, the Netherlands

³Department of Immunology, Laboratory Medical Immunology, Erasmus Medical Center, Rotterdam, the Netherlands

ABSTRACT.

Purpose: To analyse intraocular cytokine levels and prevalence of intraocular antiretinal antibodies (ARAs) in patients with retinitis pigmentosa (RP), age-related macular degeneration (AMD), glaucoma and cataract, and correlate the results to clinical manifestations.

Methods: We collected intraocular fluid samples from patients with RP ($n = 25$), AMD ($n = 12$), glaucoma ($n = 28$) and cataract ($n = 22$), and serum samples paired with the intraocular fluids from patients with RP ($N = 7$) and cataract ($n = 10$). Interleukin (IL)-1 β , IL-1 α , IL-2, IL-6, IL-6 α , IL-7, IL-8, IL-10, IL-17A, IL-23, thymus- and activation-regulated chemokine (TARC), monocyte chemoattractant protein-1 (MCP-1), tumour necrosis factor- α (TNF- α), placental growth factor (PIGF) and vascular endothelial growth factor (VEGF) were measured using a multiplex assay. Antiretinal antibodies (ARA) detection was performed by indirect immunofluorescence.

Results: Increasing age was associated with increasing levels of IL-6, IL-8, TNF- α and VEGF. All patient groups exhibited distinct profiles of intraocular cytokines. Intraocular levels of IL-8 were highest in patients with AMD and glaucoma. Cataract patients exhibited high intraocular levels of IL-23. Intraocular levels of IL-2, IL-6, MCP-1 and PIGF in RP patients exceeded the levels of serum, indicating intraocular production. Intraocular ARAs were found in only one patient with AMD.

Conclusion: Increased levels of inflammatory cytokines in intraocular fluid of patients with originally noninflammatory ocular diseases show that intraocular inflammation is involved in their pathogenesis of these entities. Moreover, we show that increasing age is associated with increasing levels of intraocular cytokines and conclude that future studies on intraocular mediators should be corrected for age of patients.

Key words: age-related macular degeneration – antiretinal antibodies – cytokines – glaucoma – indirect immunofluorescence – intraocular fluid – multiplex bead immunoassay – retinitis pigmentosa

[†]These authors contributed equally as last authors.

Acta Ophthalmol.

© 2018 Acta Ophthalmologica Scandinavica Foundation. Published by John Wiley & Sons Ltd

doi: 10.1111/aos.13899

Introduction

The pathogenesis of retinitis pigmentosa (RP), age-related macular degeneration (AMD) and glaucoma is not fully clarified, but a growing body of evidence documents the involvement of the immune system. Further insights into the role of immune activation could lead to potential new therapeutic modalities for these blinding diseases.

Recent studies identified autoantibodies directed against retinal tissue in serum of patients with RP, AMD and glaucoma. (Bell et al. 2013; Nussenblatt et al. 2013) An association between antiretinal antibodies (ARAs) in serum and macular oedema has been observed in RP. (Heckenlively et al. 1999) Decrease in serum ARA levels was reported after intravitreal anti-vascular endothelial growth factor (VEGF) therapy in AMD. (Kubicka-Trzaska et al. 2016) Also, a variant of the complement factor H (CFH) gene, which causes uncontrolled complement activation, has been linked to AMD. (Nussenblatt et al. 2013) The presence of ARAs in aqueous humour and serum has been observed in patients with glaucoma and in neurodegenerative damage of the optic nerve. (Joachim et al. 2007) Further, the elevated levels of different chemokines, including monocyte chemoattractant protein 1 (MCP-1) and interleukin (IL)-8, as well as the pro-inflammatory cytokine IL-6, have been described in aqueous humour of RP, AMD and

glaucoma.(Chiu et al. 2010; Jonas et al. 2012; Freedman & Iserovich 2013; Yoshida et al. 2013; Chalam et al. 2014; Rezar-Dreindl et al. 2016).

Autoimmune reactions against retina, choroid and/or retinal pigment epithelium (RPE) might contribute to continuation and/or aggravation of some of these initially noninflammatory ocular diseases.(Nussenblatt et al. 2013; Kauppinen et al. 2016; Feng et al. 2017; Rezar-Dreindl et al. 2017; Shiraya et al. 2017) However, the role of autoimmune reactions within the eye and comparison of inflammatory reactions between different degenerative ocular diseases have been scarcely addressed.

Herein, we investigate specific cytokine, chemokine and growth factor levels and the presence of ARAs in intraocular fluid samples in patients with RP, AMD, glaucoma and cataract and relate the laboratory outcomes to clinical manifestations.

Patients and Methods

Sample collection

In this cross-sectional study, we obtained intraocular fluid samples from 87 patients with RP, AMD, glaucoma and cataract (controls) from the biobank at the Erasmus University Medical Center and the biobank of the Rotterdam Eye Hospital. Ocular fluids within the biobank were collected during the beginning of a cataract extraction. The study was approved by the local ethics committee from the Erasmus University Medical Center (Medical Ethics Committee Erasmus MC) and the ethics committee from the institutional research board from the Rotterdam Eye Hospital and adhered to the tenets of the Declaration of Helsinki. All intraocular fluid samples were stored at -80°C . Serum samples paired with intraocular fluids of seven patients with RP and 10 patients with age-related cataract were also obtained from the biobank.

Patient and data collection

The diagnosis of RP was based on clinical characteristics such as night blindness, visual field constriction, retinal abnormalities observed through funduscopy and/or electroretinographic changes confirming the

presence of RP-related photoreceptor damage. The diagnosis of AMD was carried out through clinical examination and optical coherence tomography. The diagnosis of glaucoma was based on the clinical presentation with high intraocular pressure, optic nerve damage and/or on characteristic visual field loss. Participants suffering from ocular comorbidity or from a combination of included ocular diseases were excluded.

Clinical characteristics of all patients were collected. For RP patients, the presence of cystoid maculopathy (CM) was assessed as follows: (1) no CM, (2) any prior CM and/or (3) current CM (<4 weeks prior to sample collection). For patients with AMD, differentiation between exudative and dry AMD was made and treatment with anti-VEGF was noted: (1) no anti-VEGF medication, (2) any prior use of anti-VEGF medication and/or (3) current use of anti-VEGF medication (<4 weeks prior to sample collection). Patients with glaucoma were classified by the type of their glaucoma. Prescription of anti-hypertensive eye drops and filtering surgery prior to sample collection were registered.

Cytokine analysis

Measurement of interleukins (IL-1 β , IL-1ra, IL-2, IL-6, IL-6 α , IL-7, IL-8, IL-10, IL-17A, IL-23), thymus- and activation-regulated chemokine (TARC), MCP-1, tumour necrosis factor-alpha (TNF- α), placental growth factor (PIGF) and VEGF was performed with a Luminex multiplex bead immunoassay system (R&D Systems Europe, Ltd; UK). The selection of the cytokine panel was based on potential relevance according to previous reports and/or possible targets for treatment options.(Yoshida et al. 2013; Chalam et al. 2014; Huang et al. 2014; Du et al. 2016; Rezar-Dreindl et al. 2016) The assays were performed according to the manufacturer's instructions with exception of one additional dilution step within the standards (in total 7 standard dilutions). Fifty microlitres of undiluted intraocular fluid samples was transferred to the plate, with the exception of intraocular fluid samples with insufficient amount of material ($n = 16$), which were diluted to a total volume of 50 μl . Serum samples were diluted twofold according to the

manufacturer's standard protocol. Measurements were performed on a Bio-Plex MAGPIX machine, and data were analysed using Bio-Plex Manager MP software.

Antiretinal antibody analysis

The presence of ARAs was assessed by indirect immunofluorescence (IIF) using primate retinal tissue (Euroimmun) and evaluated as described before in ten Berge et al.(Ten Berge et al. 2016) IIF was conducted with intraocular fluids samples with sufficient volume available and on all serum samples. Samples that displayed nuclear staining on retinal tissue were also analysed in a routine IIF antinuclear antibody (ANA) screening test using HEp-2 cells (Inova), to exclude nonspecific retinal staining due to ANA positivity, as described previously. (Ten Berge et al. 2016).

Statistical analysis

Data from the Luminex immunoassay were analysed both as continuous data and as categorical data. For the continuous analyses, values below the lower limit of detection were replaced by the lowest value of the reference curve. For categorical analyses, we used the lowest value of the reference curve as cut-off point. Continuous variables were summarized using medians and ranges, and categorical variables were summarized using percentages. Logistic regression for categorical data and linear regressions for continuous data were assessed to compare laboratory outcomes between diagnosis groups. Age, gender and diagnosis were included in the regression model, to correct for confounders and analyse the effect of each of these variables. Statistical analyses were performed using IBM SPSS Statistics, version 21, and a p-value of <0.05 was considered as statistically significant.

Results

Patient characteristics

Aqueous humour samples were obtained from a total of 87 patients: RP ($n = 25$), AMD ($n = 12$), glaucoma ($n = 28$) and cataract ($n = 22$). Serum samples obtained simultaneously with intraocular fluids samples were

available from 17 patients: RP ($n = 7$) and cataract patients ($n = 10$). Gender distribution did not differ between groups, but age differed significantly ($p < 0.001$); specifically, patients with AMD were older and patients with RP were younger (Table 1). The AMD group consisted of 10 patients with dry and two patients with exudative AMD. The classification of glaucoma included primary open-angle glaucoma (POAG, $n = 22$), narrow-angle glaucoma ($n = 4$), normal tension glaucoma ($n = 1$) and glaucoma secondary to pigment dispersion syndrome ($n = 1$).

Prevalence of intraocular cytokines

The prevalence of cytokines, chemokines and growth factors in intraocular fluid is summarized in the Table S1. Gender did not influence the prevalence of cytokines. After correction for diagnosis, the prevalence of intraocular IL-6 and TNF- α increased with age ($p = 0.012$ and $p = 0.002$, respectively). Interleukin (IL)-2 and MCP-1 were present in all intraocular fluid samples, while IL-1 β and IL-17A were undetectable in all intraocular fluid samples. Thymus- and activation-regulated chemokine (TARC) was detected in intraocular fluid of patients with RP, AMD and glaucoma, but not in cataract patients. Differences in the presence of cytokines in intraocular fluids between ocular diseases were, however, not significant. No associations were found between clinical characteristics (such as duration of disease, clinical manifestations, use of systemic and topical medications, previous intraocular surgeries and others) and the mere presence of cytokines, chemokines or growth factors in intraocular fluid.

Prevalence of cytokines in paired intraocular and serum samples

A similar cytokine profile was found in serum and intraocular fluid in RP

patients, except for IL-2 and IL-6, which were more often present in the intraocular fluid samples, and IL-1ra and TARC, which were more frequently observed in serum. The presence of serum cytokines was not different between RP patients and cataract patients.

Levels of intraocular cytokines

Linear regressions using specific diagnosis, age and gender in the model showed that intraocular levels of IL-6, TNF- α and VEGF correlated positively with age ($p = 0.009$, $p = 0.019$ and $p < 0.001$, respectively; borderline association was observed also for IL 8; $p = 0.049$, Fig. 1). Gender showed no association with intraocular cytokine levels. Different cytokine profiles were observed for RP, AMD, glaucoma and cataract; specifically, intraocular levels of IL-6r α ($p = 0.019$), IL-8 ($p = 0.032$), and IL-23 ($p < 0.004$) differed between the studied ocular diseases (Fig. 2). Retinitis pigmentosa (RP) patients were characterized by low levels of intraocular IL-8 and IL-23. Intraocular IL-8 levels were highest in patients with AMD and glaucoma. Cataract patients had high levels of IL-23. Intraocular levels of IL-6r α were higher in patients with RP or glaucoma than in patients with AMD or cataract. Vascular endothelial growth factor (VEGF) levels were highest in intraocular fluids of AMD patients and lowest in RP, although the differences did not reach significance after correction for age (Table 2).

Retinitis pigmentosa (RP) patients who ever had CM during their disease course exhibited lower intraocular IL-2 levels than RP patients without CM ($p = 0.042$). Glaucoma patients treated with antihypertensive eye drops displayed lower intraocular IL-6 levels compared to glaucoma without this treatment modality ($p < 0.001$). Glaucoma patients who previously underwent surgical treatment (11/28, 39%; consisting of selective laser therapy,

trabeculectomy or occasional glaucoma implants) exhibited higher intraocular IL-8 levels ($p = 0.035$). No other associations were found between clinical characteristics (such as duration of disease, use of systemic or topical medications) and the levels of cytokines, chemokines or growth factors in intraocular fluid.

Levels of cytokines in paired intraocular and serum samples

Interleukin (IL)-2, IL-6, MCP-1 and PlGF levels were higher in intraocular fluid than in serum in both RP ($p < 0.001$, $p = 0.001$, $p < 0.001$ and $p = 0.006$) and cataract ($p < 0.001$, $p = 0.047$, $p < 0.001$ and $p < 0.001$). Moreover, cataract patients had higher levels of IL-23 in intraocular fluid than serum ($p = 0.043$). In contrast, intraocular IL-23 levels in RP were lower than the serum levels ($p < 0.001$). Intraocular levels of all other cytokines, chemokines and growth factors in intraocular fluid did not exceed serum levels. Levels of serum cytokines were not different between RP patients and cataract patients.

Prevalence of antiretinal antibodies

Antiretinal antibodies (ARAs) were not detected in intraocular fluid samples from RP ($n = 21$), glaucoma ($n = 18$) and cataract ($n = 16$). In one patient with AMD (1/8, 13%), intraocular ARA were detected. Serum ARA levels were detected in five of seven (71%) patients with RP and six of 10 (60%) patients with cataract. All samples with nuclear staining on retinal tissue ($n = 7$) were negative for ANA.

Discussion

Our study describes different pro-inflammatory intraocular cytokine profiles in RP, AMD, glaucoma and cataract and reveals a positive correlation between intraocular cytokine levels and increasing age,

Table 1. Patient characteristics.

	Retinitis pigmentosa	Age-related macular degeneration	Glaucoma	Cataract	p-value
Total number of patients	$N = 25$	$N = 12$	$N = 28$	$N = 22$	
Median age in years (range)	51 (25-86)	84 (68-94)	73 (50-88)	66 (17-80)	< 0.001
Gender (male)	12/25 (48%)	3/12 (25%)	13/28 (46%)	8/22 (36%)	n.s.

n.s. = not statistically significant ($p > 0.05$).

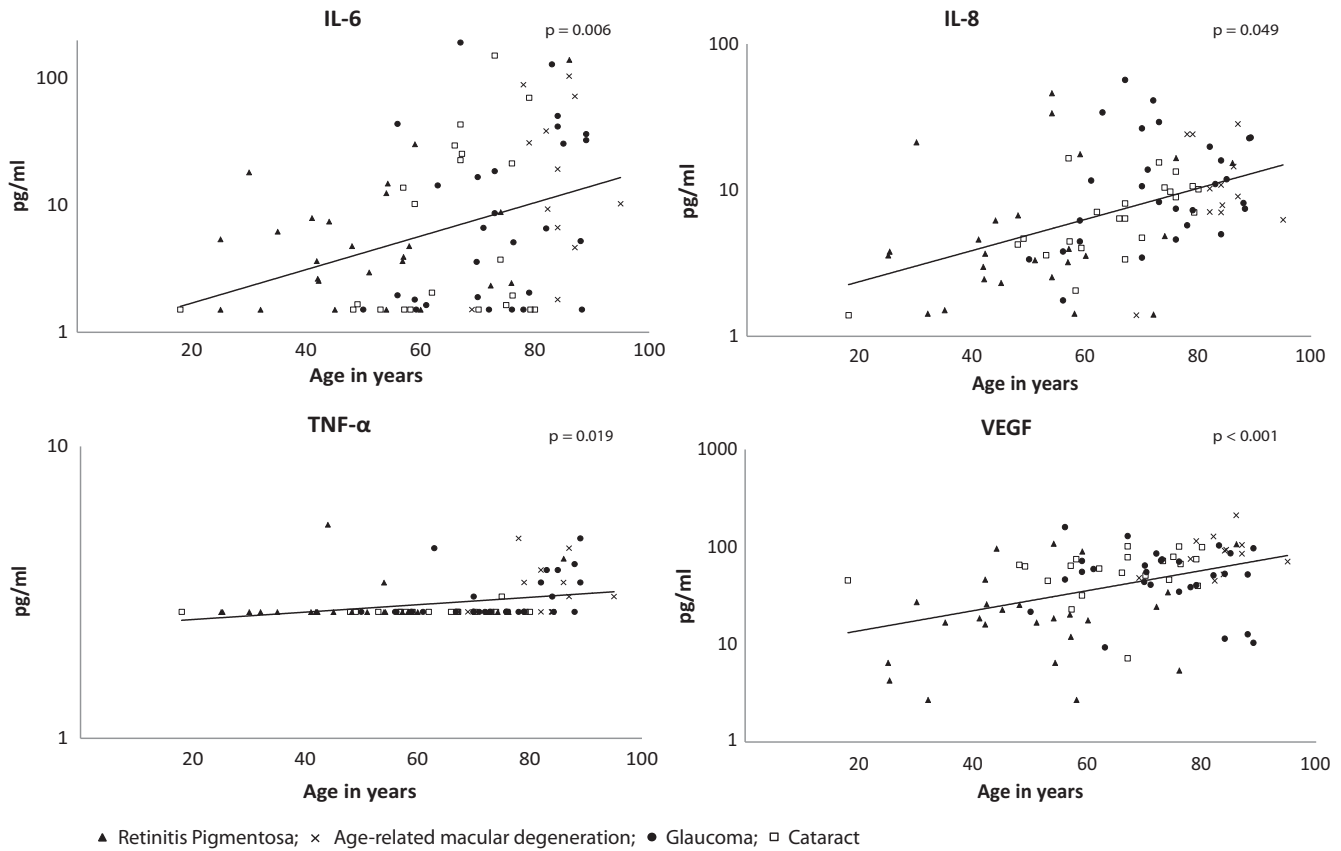


Fig. 1. Levels of intraocular cytokines in relation to age. p-values for comparison of intraocular cytokine levels and age were determined by linear regression with adjustment for diagnosis and gender.

independently of diagnosis. Interestingly, intraocular fluid samples from cataract patients displayed the highest levels of IL-23. Although intraocular levels of VEGF were highest in AMD patients, after age correction, no significant differences were found between the various diagnostic groups. Comparison of paired serum and intraocular fluid samples of RP patients showed that intraocular levels of IL-2, IL-6, MCP-1 and PIGF exceeded the serum levels, suggesting a local production. Intraocular ARAs were absent in nearly all samples.

Although a genetic mutation is the cause of RP, inflammation was suggested to have a (secondary) role in the disease pathogenesis.(Chant et al. 1985; Nussenblatt et al. 2013; Hettinga et al. 2016). It has been previously reported that RP patients with CM exhibited more often ARAs in their peripheral blood, the finding which was also noted in present series. (Heckenlively et al. 1999). In contrast to serum findings, ARAs were not detected in intraocular fluids samples of patients with RP.

Previous reports on intraocular cytokines in RP show higher levels of IL-6, IL-8, MCP-1 and TARC in RP compared to cataract.(Salom et al. 2008; Yoshida et al. 2013) We also observed intraocular presence of these mediators in RP patients, but their levels were not elevated compared to other groups. This discrepancy may be explained by the low number of included patients in our study or possible differences in disease stage and/or extent of degeneration. Yet RP patients, like glaucoma patients, had higher intraocular levels of soluble IL-6 α (sIL-6R α) compared to cataract. Soluble IL-6 α (sIL-6R α) interacts with IL-6, forming the IL-6/sIL-6R α complex, which subsequently induces IL-6 trans-signalling by binding cell membrane expressed gp130.(Rose-John 2012) IL-6 trans-signalling is recognized to enhance IL-6 activity under inflammatory conditions and moreover to inhibit intraocular T-cell apoptosis in uveitis, which likely exacerbates or prolongs the disease process. (Nowell et al. 2003; Curnow et al. 2004;

Barkhausen et al. 2011) Further, we observed a significant association between lower levels of intraocular IL-2 (a growth factor for regulatory T cells) in RP patients who had CM. This may indicate a deregulated immune function, such as loss of tolerance, affecting the clinical manifestation of the disease and the formation of serum ARAs as observed in this and other studies.(Nelson 2004) Intraocular VEGF levels were lowest in the RP group, which is in line with the rare presence of retinal neovascularization in RP.

Inflammation was implicated in the development and progression of AMD.(Adamus 2017) So far, most previous studies investigated intraocular fluids of exudative AMD, demonstrating high levels of inflammatory mediators, including IL-6, IL-8, MCP-1 and VEGF.(Jonas et al. 2012; Knickelbein et al. 2015) However, it is still unknown whether these cytokines play a role in the primary pathogenesis of AMD or represent a secondary result of the disease process. We

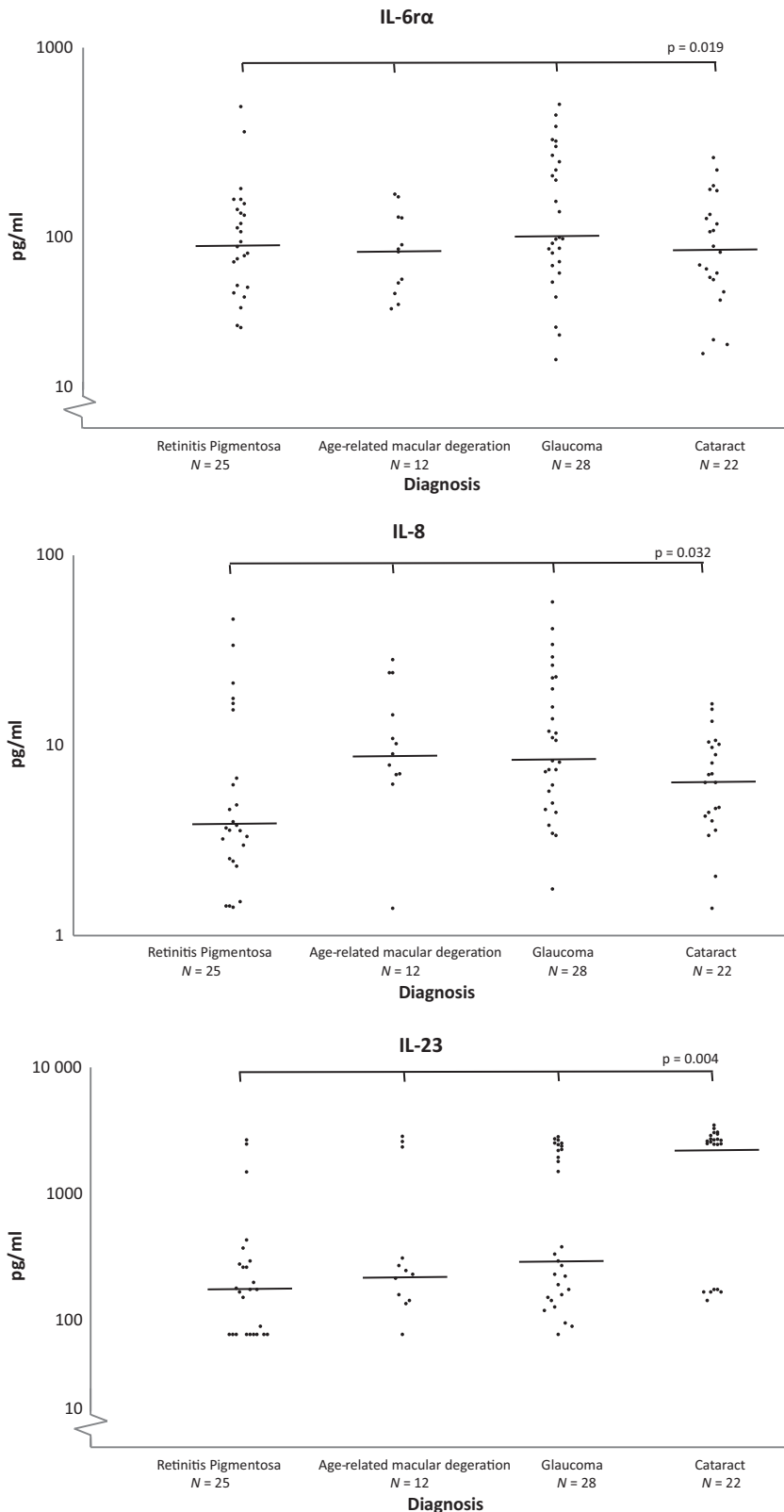


Fig. 2. Levels of intraocular cytokines in relation to ocular diagnosis. p-values for comparisons of intraocular cytokine levels within retinitis pigmentosa, age-related macular degeneration, glaucoma and cataract were determined by linear regression with adjustment for age and gender.

investigated patients with mainly dry AMD and observed higher intraocular IL-8 compared to cataract and RP.

Previous studies revealed that elevated (intraocular) levels of IL-8 and IL-8 gene polymorphisms were associated

with angiogenesis.(Ghasemi et al. 2011; Forooghian et al. 2016) IL-6 and VEGF reached highest levels in the AMD group, though not significantly different compared to other diagnosis groups. According to previous studies, these mediators have been implicated in angiogenesis and decrease during treatment with anti-VEGF agents. (Agawa et al. 2014; Chalam et al. 2014) Retinal neuroprotective effects of VEGF have also been described, yet data on this matter are inconclusive and may be dependent on the VEGF variant, disease (stage) or experimental model used.(Nishijima et al. 2007; Saint-Geniez et al. 2008).

In glaucoma, the role of immune reactions is not known and could be either pathogenic or neuroprotective. In our study, patients with glaucoma, who consisted mainly of POAG, were characterized by high intraocular levels of IL-8, consistent with previous findings.(Kuchtey et al. 2010; Takai et al. 2012; Khalef et al. 2017; Kokubun et al. 2017) IL-8 is a main chemoattractant for neutrophils which have been found to accumulate in the trabecular meshwork in POAG.(Taurone et al. 2015) The highest levels of IL-8 were found in glaucoma patients who underwent surgical treatment prior to the surgical procedure during intraocular sample collection. This suggests that the higher levels of IL-8 might be explained by immune activation in response to (surgically inflicted) tissue damage.

Increased TNF-α levels have been reported in intraocular fluid, the trabecular meshwork, optic head and the retina of glaucoma patients; however, in our study, intraocular TNF-α appeared undetectable in most cases. (Yuan & Neufeld 2000; Tezel et al. 2001; Sawada et al. 2010; Balaiya et al. 2011; Taurone et al. 2015; Khalef et al. 2017) This discrepancy may have resulted from differences in laboratory techniques and specific patient groups. So far, to our knowledge, only sporadic studies are available on the effect of anti-TNF medication in glaucoma, which shows an increase in fibrosis after surgical treatment.(Nikita et al. 2017).

In our study, cataract was generally characterized by lower levels of pro-inflammatory mediators compared to other studied diseases, with the exception of IL-23. IL-23, produced by

Table 2. Levels of cytokines in different ocular disease.

Cytokines (median, ranges)	Retinitis pigmentosa			Age-related macular degeneration			Cataract			p-value (comparison of IOF)
	IOF	Serum	p-value	IOF	Serum	p-value	IOF	Serum	p-value	
Cytokines										
IL-1 β	5 (5-5)	5 (5-5)	n.s.	5 (5-5)	5 (5-5)		5 (5-5)	5 (5-5)		n.s.
IL-1ra	33 (9-3673)	576 (426-2436)	n.s.	121 (9-1169)	65 (9-876)		124 (9-2357)	608 (328-1043)		n.s.
IL-2	292 (142-899)	33 (33-93)	<0.001	282 (205-1727)	271 (151-1371)		275 (212-1101)	136 (15-262)		<0.001
IL-6rx	95 (33-489)	41505 (39074-50271)	<0.001	85 (42-169)	99 (22-502)		87 (24-263)	44327 (34714-58859)		<0.001
IL-6	4 (1-140)	1 (1-1)	0.001	14 (1-104)	5 (1-192)		2 (1-151)	1 (1-3)		0.047
IL-7	3 (1-6)	4 (1-7)	n.s.	2 (1-7)	3 (1-12)		1 (1-9)	5 (2-7)		0.004
IL-10	3 (3-5)	3 (3-3)	n.s.	3 (3-8)	3 (3-7)		3 (3-8)	5 (3-24)		n.s.
IL-17A	8 (8-8)	8 (8-8)	n.s.	8 (8-8)	8 (8-8)		8 (8-8)	10 (8-25)		n.s.
IL-23	176 (77-3611)	812 (539-919)	0.001	240 (77-2844)	315 (77-2828)		2592 (144-3493)	750 (510-945)		0.043
TNF- α	2 (2-5)	2 (2-3)	n.s.	3 (2-4)	2 (2-4)		2 (2-3)	2 (2-4)		n.s.
IL-8	3 (1-46)	6 (2-21)	n.s.	9 (1-28)	9 (1-56)		6 (1-16)	7 (1-12)		n.s.
TARC	28 (28-57)	180 (101-681)	<0.001	28 (28-37)	28 (28-57)		28 (28-28)	262 (62-470)		<0.001
MCP-1	891 (339-1805)	256 (201-451)	<0.001	638 (256-1035)	731 (264-3495)		618 (249-1920)	320 (120-478)		<0.001
PIGF	6 (0-26)	1 (0-1)	0.006	6 (0-13)	5 (0-13)		5 (2-12)	1 (0-2)		<0.001
VEGF	18 (2-108)	52 (18-107)	0.020	88 (45-210)	54 (9-159)		63 (7-101)	73 (18-126)		n.s.

IOF = intraocular fluid, IL = Interleukin, MCP-1 = monocyte chemoattractant protein 1, n.s. = not statistically significant ($p \geq 0.05$), PIGF = placental growth factor, TARC = thymus- and activation-regulated chemokine, TNF- α = tumour necrosis factor-alpha, VEGF = vascular endothelial growth factor.

dendritic cells/myeloid cells, is well known for its key role in several autoimmune diseases via the IL-23/IL-17 axis and associated pathological Th17 development.(D’Elios et al. 2010; Lubberts 2015) Despite the presence of IL-23 in most intraocular fluids analysed in our study, IL-17A was never detected. Interestingly, some studies report immunosuppressive effects of IL-23 within tumour microenvironments by suppressing lymphocyte effector function and enhanced production of immune regulatory cytokines.(Langowski et al. 2006; Teng et al. 2010; Nie et al. 2017) Also in a model of experimental autoimmune uveitis, it was found that IL-23 receptor expressing $\gamma\delta$ T cells can exert immunosuppressive effects due to their ability to bind IL-23.(Liang et al. 2013) Although the mechanism by which IL-23 can mediate immune-suppressive effects clearly requires further study, it is tempting to speculate that the low intraocular IL-23 levels observed in patients with RP, AMD and glaucoma may reflect diminished immune protection of the eye. Intraocular IL-23 levels revealed no association with serum levels nor with age of patients.

Ageing is associated with the development of a chronic state of low-grade tissue inflammation that also involves the retina and is associated with increased susceptibility to multiple diseases, including glaucoma and AMD.(Leske et al. 2008; Xu et al. 2009; Chakravarthy et al. 2010; Castelo-Branco & Soveral 2014) In support of this, we observed a gradual increase in the intraocular levels of IL-6, IL-8, TNF- α and VEGF with increasing age. A positive correlation between intraocular cytokine levels and age has been reported in two previous studies.(Takai et al. 2012; Kokubun et al. 2017) As a consequence of this correlation, all of our results are adjusted for the age of patients. However, systematic corrections for age have not been performed in previous studies, which may have affected the interpretation of these findings. It should thus be kept in mind that studies on intraocular cytokine profiling without age adjustment (and without age matched control groups) may show age-related bias rather than disease-associated differences.

Intraocular levels of IL-2, IL-6, MCP-1 and PIGF were higher than the serum levels of patients with RP

and cataract. The higher intraocular levels of inflammatory components may suggest local production, possibly by infiltrated immune cells or resident cells, such as retinal pigment epithelial cells. (Elner et al. 1992; Holtkamp et al. 1998) These findings may contribute to the understanding of the pathogenesis of RP and development of new treatment possibilities. In contrast, the low occurrence of intraocular ARAs suggests a negligible role of such antibodies in disease pathogenesis of RP. Antiretinal antibodies (ARAs) detected in serum from RP and cataract patients may represent a reflection of altered blood retinal barrier properties and most probably represent an innocent epiphenomena.

In this study, we investigated a variety of patients with different ocular disorders that are classically considered as being noninflammatory. Even with the limited number of diverse patients, we were able to conclude that autoimmune reactions are prevalent in originally noninflammatory ocular diseases. To our knowledge, our study is the only study so far assessing and comparing the role of inflammatory responses in different noninflammatory ocular diseases. The replacement of values of cytokine levels below the lowest standard by the lowest detection limit by the lowest value of the reference curve might have influenced our outcomes. However, omitting data below the lower limit of detection might cause selection bias.

In conclusion, the expression of inflammatory cytokines within the eye was strongly influenced by the age of patients, which shows that the correction for age is necessary in future studies on intraocular mediators. Differences in intraocular cytokine profiles were observed between originally non-inflammatory ocular diseases, suggesting involvement of inflammation; however, complex pathways with multiple signalling functions make a diagnostic role rather impossible. The role of immune reactions in basically non-inflammatory ocular diseases might influence the clinical manifestations and severity of ocular changes.

References

- Adamus G (2017): Can innate and autoimmune reactivity forecast early and advance stages of age-related macular degeneration? *Autoimmun Rev* **16**: 231–236.
- Agawa T, Usui Y, Wakabayashi Y et al. (2014): Profile of intraocular immune mediators in patients with age-related macular degeneration and the effect of intravitreal bevacizumab injection. *Retina* **34**: 1811–1818.
- Balaiya S, Edwards J, Tillis T, Khetpal V & Chalam KV (2011): Tumor necrosis factor- α (TNF- α) levels in aqueous humor of primary open angle glaucoma. *Clin Ophthalmol* **5**: 553–556.
- Barkhausen T, Tschernig T, Rosenstiel P et al. (2011): Selective blockade of interleukin-6 trans-signaling improves survival in a murine polymicrobial sepsis model. *Crit Care Med* **39**: 1407–1413.
- Bell K, Gramlich OW, Von Thun Und Hohenstein-Blaul N, Beck S, Funke S, Wilding C, Pfeiffer N & Grus FH (2013): Does autoimmunity play a part in the pathogenesis of glaucoma? *Prog Retin Eye Res* **36**: 199–216.
- Castelo-Branco C & Soveral I (2014): The immune system and aging: a review. *Gynecol Endocrinol* **30**: 16–22.
- Chakravarthy U, Wong TY, Fletcher A et al. (2010): Clinical risk factors for age-related macular degeneration: a systematic review and meta-analysis. *BMC Ophthalmol* **10**: 31.
- Chalam KV, Grover S, Sambhav K, Balaiya S & Murthy RK (2014): Aqueous interleukin-6 levels are superior to vascular endothelial growth factor in predicting therapeutic response to bevacizumab in age-related macular degeneration. *J Ophthalmol* **2014**: 502174.
- Chant SM, Heckenlively J & Meyers-Elliott RH (1985): Autoimmunity in hereditary retinal degeneration. I. Basic Studies. *Br J Ophthalmol* **69**: 19–24.
- Chiu K, Yeung SC, So KF & Chang RC (2010): Modulation of morphological changes of microglia and neuroprotection by monocyte chemoattractant protein-1 in experimental glaucoma. *Cell Mol Immunol* **7**: 61–68.
- Curnow SJ, Scheel-Toellner D, Jenkinson W et al. (2004): Inhibition of T cell apoptosis in the aqueous humor of patients with uveitis by IL-6/soluble IL-6 receptor trans-signaling. *J Immunol* **173**: 5290–5297.
- D'Elios MM, Del Prete G & Amedei A (2010): Targeting IL-23 in human diseases. *Expert Opin Ther Targets* **14**: 759–774.
- Du S, Huang W, Zhang X, Wang J, Wang W & Lam DS (2016): Multiplex cytokine levels of aqueous humor in acute primary angle-closure patients: fellow eye comparison. *BMC Ophthalmol* **16**: 6.
- Elner VM, Scales W, Elner SG, Danforth J, Kunkel SL & Strieter RM (1992): Interleukin-6 (IL-6) gene expression and secretion by cytokine-stimulated human retinal pigment epithelial cells. *Exp Eye Res* **54**: 361–368.
- Feng J, Zheng X, Li B & Jiang Y (2017): Differences in aqueous concentrations of cytokines in paediatric and adult patients with Coats' disease. *Acta Ophthalmol* **95**: 608–612.
- Forooghian F, Kertes PJ, Eng KT, Agrón E & Chew EY (2016): Alterations in intraocular cytokine levels following intravitreal ranibizumab. *Can J Ophthalmol* **51**: 87–90.
- Freedman J & Iserovich P (2013): Pro-inflammatory cytokines in glaucomatous aqueous and encysted Molteno implant blebs and their relationship to pressure. *Invest Ophthalmol Vis Sci* **54**: 4851–4855.
- Ghasemi H, Ghazanfari T, Yaraee R, Faghizadeh S & Hassan ZM (2011): Roles of IL-8 in ocular inflammations: a review. *Ocul Immunol Inflamm* **19**: 401–412.
- Heckenlively JR, Jordan BL & Aptsiauri N (1999): Association of antiretinal antibodies and cystoid macular edema in patients with retinitis pigmentosa. *Am J Ophthalmol* **127**: 565–573.
- Hettinga YM, Van Genderen MM, Wieringa W, Ossewaarde-van Norel J & de Boer JH (2016): Retinal dystrophy in 6 young patients who presented with intermediate uveitis. *Ophthalmology* **123**: 2043–2046.
- Holtkamp GM, Van Rossem M, de Vos AF, Willekens B, Peek R & Kijlstra A (1998): Polarized secretion of IL-6 and IL-8 by human retinal pigment epithelial cells. *Clin Exp Immunol* **112**: 34–43.
- Huang W, Chen S, Gao X et al. (2014): Inflammation-related cytokines of aqueous humor in acute primary angle-closure eyes. *Invest Ophthalmol Vis Sci* **55**: 1088–1094.
- Joachim SC, Bruns K, Lackner KJ, Pfeiffer N & Grus FH (2007): Antibodies to alpha B-crystallin, vimentin, and heat shock protein 70 in aqueous humor of patients with normal tension glaucoma and IgG antibody patterns against retinal antigen in aqueous humor. *Curr Eye Res* **32**: 501–509.
- Jonas JB, Tao Y, Neumaier M & Findeisen P (2012): Cytokine concentration in aqueous humour of eyes with exudative age-related macular degeneration. *Acta Ophthalmol* **90**: e381–e388.
- Kauppinen A, Paterno JJ, Blasiak J, Salminen A & Kaarniranta K (2016): Inflammation and its role in age-related macular degeneration. *Cell Mol Life Sci* **73**: 1765–1786.
- Khalef N, Labib H, Helmy H, El Hamid MA, Moemen L & Fahmy I (2017): Levels of cytokines in the aqueous humor of eyes with primary open angle glaucoma, pseudoexfoliation glaucoma and cataract. *Electron Physician* **9**: 3833–3837.
- Knickerbein JE, Chan CC, Sen HN, Ferris FL & Nussenblatt RB (2015): Inflammatory mechanisms of age-related macular degeneration. *Int Ophthalmol Clin* **55**: 63–78.
- Kokubun T, Tsuda S, Kunikata H, Yasuda M, Himori N, Kunimatsu-Sanuki S, Maruyama K & Nakazawa T (2017): Characteristic profiles of inflammatory cytokines in the aqueous humor of glaucomatous eyes. *Ocul Immunol Inflamm* 1–12. [Epub ahead of print]
- Kubicka-Trzaska A, Wilanska J, Romanowska-Dixon B & Sanak M (2016): Serum

- anti-endothelial cell antibodies in patients with age-related macular degeneration treated with intravitreal bevacizumab. *Acta Ophthalmol* **94**: e617–e623.
- Kuchtey J, Rezaei KA, Jaru-Ampornpan P, Sternberg Jr P, & Kuchtey RW (2010): Multiplex cytokine analysis reveals elevated concentration of interleukin-8 in glaucomatous aqueous humor. *Invest Ophthalmol Vis Sci* **51**: 6441–6447.
- Langowski JL, Zhang X, Wu L et al. (2006): IL-23 promotes tumour incidence and growth. *Nature* **442**: 461–465.
- Leske MC, Wu SY, Hennis A, Honkanen R, Nemesure B & Group BES (2008): Risk factors for incident open-angle glaucoma: the Barbados Eye Studies. *Ophthalmology* **115**: 85–93.
- Liang D, Zuo A, Shao H, Born WK, O'Brien RL, Kaplan HJ & Sun D (2013): IL-23 receptor expression on gammadelta T cells correlates with their enhancing or suppressive effects on autoreactive T cells in experimental autoimmune uveitis. *J Immunol* **191**: 1118–1125.
- Lubbets E (2015): The IL-23-IL-17 axis in inflammatory arthritis. *Nat Rev Rheumatol* **11**: 415–429.
- Nelson BH (2004): IL-2, regulatory T cells, and tolerance. *J Immunol* **172**: 3983–3988.
- Nie W, Yu T, Sang Y & Gao X (2017): Tumor-promoting effect of IL-23 in mammary cancer mediated by infiltration of M2 macrophages and neutrophils in tumor microenvironment. *Biochem Biophys Res Commun* **482**: 1400–1406.
- Nikita E, Moulin A, Vergados I, Brouzas D & Theodossiadis PG (2017): A pilot study on ocular safety and efficacy of infliximab as an antifibrotic agent after experimental glaucoma filtration surgery. *Ophthalmol Ther* **6**: 323–334.
- Nishijima K, Ng YS, Zhong L et al. (2007): Vascular endothelial growth factor-A is a survival factor for retinal neurons and a critical neuroprotectant during the adaptive response to ischemic injury. *Am J Pathol* **171**: 53–67.
- Nowell MA, Richards PJ, Horiuchi S, Yamamoto N, Rose-John S, Topley N, Williams AS & Jones SA (2003): Soluble IL-6 receptor governs IL-6 activity in experimental arthritis: blockade of arthritis severity by soluble glycoprotein 130. *J Immunol* **171**: 3202–3209.
- Nussenblatt RB, Liu B, Wei L & Sen HN (2013): The immunological basis of degenerative diseases of the eye. *Int Rev Immunol* **32**: 97–112.
- Rezar-Dreindl S, Sacu S, Eibenberger K et al. (2016): The intraocular cytokine profile and therapeutic response in persistent neovascular age-related macular degeneration. *Invest Ophthalmol Vis Sci* **57**: 4144–4150.
- Rezar-Dreindl S, Eibenberger K, Pollreis A et al. (2017): Effect of intravitreal dexamethasone implant on intra-ocular cytokines and chemokines in eyes with retinal vein occlusion. *Acta Ophthalmol* **95**: e119–e127.
- Rose-John S (2012): IL-6 trans-signaling via the soluble IL-6 receptor: importance for the pro-inflammatory activities of IL-6. *Int J Biol Sci* **8**: 1237–1247.
- Saint-Geniez M, Maharaj AS, Walshe TE et al. (2008): Endogenous VEGF is required for visual function: evidence for a survival role on muller cells and photoreceptors. *PLoS ONE* **3**: e3554.
- Salom D, Diaz-Llopis M, Garcia-Delpech S, Udaondo P, Sancho-Tello M & Romero FJ (2008): Aqueous humor levels of vascular endothelial growth factor in retinitis pigmentosa. *Invest Ophthalmol Vis Sci* **49**: 3499–3502.
- Sawada H, Fukuchi T, Tanaka T & Abe H (2010): Tumor necrosis factor-alpha concentrations in the aqueous humor of patients with glaucoma. *Invest Ophthalmol Vis Sci* **51**: 903–906.
- Shiraya T, Kato S, Araki F & Ueta T (2017): Effect of intravitreal ranibizumab injection on aqueous humour cytokine levels in patients with diabetic macular oedema. *Acta Ophthalmol* **95**: e340–e341.
- Takai Y, Tanito M & Ohira A (2012): Multiplex cytokine analysis of aqueous humor in eyes with primary open-angle glaucoma, exfoliation glaucoma, and cataract. *Invest Ophthalmol Vis Sci* **53**: 241–247.
- Taurone S, Ripandelli G, Pacella E et al. (2015): Potential regulatory molecules in the human trabecular meshwork of patients with glaucoma: immunohistochemical profile of a number of inflammatory cytokines. *Mol Med Rep* **11**: 1384–1390.
- Ten Berge JC, Schreurs MW, Vermeer J, Meester-Smoor MA & Rothova A (2016): Prevalence and clinical impact of antiretinal antibodies in uveitis. *Acta Ophthalmol* **94**: 282–288.
- Teng MW, Andrews DM, McLaughlin N et al. (2010): IL-23 suppresses innate immune response independently of IL-17A during carcinogenesis and metastasis. *Proc Natl Acad Sci U S A* **107**: 8328–8333.
- Tezel G, Li LY, Patil RV & Wax MB (2001): TNF-alpha and TNF-alpha receptor-1 in the retina of normal and glaucomatous eyes. *Invest Ophthalmol Vis Sci* **42**: 1787–1794.
- Xu H, Chen M & Forrester JV (2009): Para-inflammation in the aging retina. *Prog Retin Eye Res* **28**: 348–368.
- Yoshida N, Ikeda Y, Notomi S, Ishikawa K, Murakami Y, Hisatomi T, Enaida H & Ishibashi T (2013): Clinical evidence of sustained chronic inflammatory reaction in retinitis pigmentosa. *Ophthalmology* **120**: 100–105.
- Yuan L & Neufeld AH (2000): Tumor necrosis factor-alpha: a potentially neurodestructive cytokine produced by glia in the human glaucomatous optic nerve head. *Glia* **32**: 42–50.

Received on December 20th, 2017.
Accepted on July 21st, 2018.

Correspondence:

Josianne C. ten Berge
Department of Ophthalmology
Erasmus Medical Center Rotterdam
's-Gravendijkwal 230
3015 CE Rotterdam
the Netherlands
Tel: +31-10-7040135
Fax: +31-10-7033692
Email: j.tenberge@erasmusmc.nl

This research was supported by Stichting Lijf en Leven. This funding organization had no role in the design or conduct of this research.

Supporting Information

Additional supporting information may be found online in the Supporting Information section at the end of the article:

Table S1. Presence of cytokines in different ocular disease.