

RVC OPEN ACCESS REPOSITORY – COPYRIGHT NOTICE

This author's accepted manuscript may be used for non-commercial purposes in accordance with [Wiley Terms and Conditions for Self-Archiving](#).

The full details of the published version of the article are as follows:

TITLE: Bursting strength of surgeon's and self-locking knots for closure of ventral midline celiotomy in horses

AUTHORS: McGlinchey, L; Hanson, R R; Boone, L H; Rosanowski, S M; Coleridge, M; Souza, C; Munsterman, A S

JOURNAL: Veterinary Surgery

PUBLISHER: Wiley

PUBLICATION DATE: 1 October 2018 (online)

DOI: <https://doi.org/10.1111/vsu.12957>

Ex vivo comparison of the bursting strength of surgeon's knot compared to self-locking knots for closure of ventral midline celiotomy in horses.

Leah McGlinchey MVB¹, R. Reid Hanson DVM MS DACVS DACVECC¹, Lindsey H, Boone DVM PhD DACVS-LA¹, Sarah M. Rosanowski PhD PGDipVCS BSc², Matthew Coleridge BVMS¹, Amelia S. Munsterman DVM MS DACVS DACVECC³

¹Department of Clinical Sciences, Auburn University College of Veterinary Medicine, Auburn, AL

²Veterinary Epidemiology, Economics and Public Health Group, Department of Pathobiology and Population Sciences, Royal Veterinary College, Hatfield, UK

³Department of Surgical Sciences, School of Veterinary Medicine, University of Wisconsin-Madison, Madison, WI

Abstract

Objective: To compare the bursting strength and failure mode of ventral midline celiotomy closure using a simple continuous suture pattern with one of two knot combinations, a novel self-locking knot combination of forwarder start with an Aberdeen end knot (F-A) and a traditional knot combination of a surgeon's start with a surgeon's end knot (S-S).

Study Design: Ex vivo experimental.

Sample Population: Equine cadavers (n=14)

Methods: A 20-cm ventral midline celiotomy was created in 14 equine cadavers. Horses were assigned to celiotomy closure with a F-A or S-S knot combination. Prior to closure, a 200L inflatable bladder was placed in the abdomen, then insufflated until failure of the

celiotomy closure. The horses' signalment, weight, breed, age, knot combination type, mode of failure, closure time (minutes) and bursting strength (mmHg) were recorded.

Results: The median bursting strength of closure with F-A knot combination (388 mmHg) was significantly greater than the median bursting strength of closure with the S-S knot combination (290 mmHg) ($P=0.035$). The majority of F-A combinations failed along the fascia, in contrast to the majority of S-S combinations that failed at the knot. There were no significant differences in closure times ($P=0.48$).

Conclusion: The self-locking F-A knot combination had a significantly higher bursting strength compared to the traditional S-S knot. Our results indicate that closure of a ventral midline celiotomy with a F-A knot combination may offer a more secure closure than that of a traditional S-S knot combination, increasing bursting strength by an average of 25%.

Introduction

Complications involving the incision following ventral midline celiotomy in horses include incisional infection, herniation, acute incisional dehiscence, suture sinus formation, swelling, incisional drainage and abscess formation.¹⁻⁵ Incisional herniation occurs frequently, affecting 16% of horses undergoing celiotomy, resulting in significant patient morbidity.^{2,5-7} Incisional herniation is suggested to occur due to complications of the celiotomy closure such as protrusion of the omentum between sutures, partial tearing of the suture material through the tissue, suture breakage, knot slippage, and incisional infection.^{2,5,8-11} These complications of the closure can also contribute to acute incisional dehiscence post-celiotomy, which occurs with less frequency (0.3-2.9%), but causes significant patient morbidity and mortality.^{5,6} Given the significant morbidity and/or mortality following ventral midline celiotomy due to incisional complications, further investigation into improvement in ventral midline celiotomy closure is warranted.

Numerous equine in vitro and ex vivo studies have investigated the role of suture placement, pattern, and material on closure strength, but to date there are no studies that have evaluated the effect of knot construction on closure strength.¹²⁻¹⁶ However, failure at the knot is the most commonly reported mode of closure failure when the surgeon's knot is used as both the start and end knot in a simple continuous pattern for closure of the equine linea alba.^{12,13}

Previous in vitro tests have demonstrated that tied large gauge suture loops break at or adjacent to the knot 90-100% of the time.^{14,15,17-19} This is suggested to occur because a load applied to the suture has deformed the material's original structure creating a point of stress accumulation at the interface between the loop and the first throw of the knot.²⁰ It has also been shown that the addition of a knot to a suture line decreases the tensile strength of that suture by 30-35%.²¹

The optimum knot for use in surgery would be small in volume and constructed with a minimum number of throws, while providing sufficient security to maintain apposition under tension.²² Self-locking knots are commonly used in human surgery and are gaining popularity in veterinary medicine.²³⁻²⁶ The Aberdeen knot is a self-locking knot used to complete the end of a continuous suture line and has previously been investigated in vitro using small and large gauge suture.^{17,18,25,26} The forwarder knot is another self-locking knot used to start a continuous suture line. Its use has been reported in human laparoscopic and bariatric surgery, however, its use in veterinary medicine has only recently been investigated in vitro using large gauge suture.^{19,23} Both of these self-locking knots have superior mechanical properties compared to a surgeon's knot, exhibiting a greater knot holding capacity (KHC) and a greater relative knot strength (RKS), while requiring less suture material.^{17-19,21,27} A knot combination with a higher breaking strength and a smaller volume may help reduce suture related incisional complications post ventral midline celiotomy.

To date, there have been no ex vivo studies investigating different knot combinations in order to strengthen equine celiotomy closure. The objective of this study was to compare the bursting strength and failure mode of ventral midline celiotomy closure using a simple continuous suture pattern with one of two knot combinations, a novel self-locking knot combination of a forwarder start with an Aberdeen end knot (F-A) and a traditional knot combination of a surgeon's start with a surgeon's end knot (S-S). We chose to assess USP 3 polyglactin 910, a braided 0.6mm diameter absorbable suture as it is the largest suture available in the United States for closure of equine celiotomies and commonly used for closure of ventral midline celiotomy in the horse. We hypothesized that 1) ventral midline celiotomy bursting strength would be significantly higher following closure with the self-locking F-A knot combination compared to closure with the traditional S-S knot combination, 2) failure of the closure would occur most commonly along the suture line and most commonly at the knot regardless of knot combination used for closure and 3) that the F-A closure time would be significantly longer than that of the S-S knot combination.

Methods and materials:

Horses

Fourteen healthy horses were selected for this study. Selection criteria included age > 2 years, weight > 300kg and < 650kg. All horses were free of gross abdominal wall abnormalities as assessed by visual examination and digital palpation. Using a random numbers generator, horses were assigned to one of two knot combination groups; (S-S) or (F-A). Sex, age, weight and breed were recorded. All cadaver horses obtained were euthanized for a separate, unrelated study that was evaluated and approved by the University Institutional Animal Care and Use Committee.

Surgical Procedure

Immediately following euthanasia, cadavers were placed in dorsal recumbency. Using a #10 scalpel blade, a 30-cm skin incision was made extending cranially from the umbilicus, taking care not to score the linea alba over the intended site of a ventral midline celiotomy. The subcutaneous tissues and skin were sharply dissected laterally approximately 5 cm from the linea alba to facilitate observation of the suture line and adjacent fascia during testing. The abdomen was entered by sharp incision beginning at the umbilicus and extending 20 cm cranially through the linea alba. The peritoneum was entered bluntly using the index finger and the defect enlarged. Bilateral stab incisions were made between the 14th and 15th rib, in the ventral one third of each intercostal space, to provide access for ingress and egress tubing. A custom made, 200 L, polyurethane bladder (New World Mfg., Inc., Cloverdale, CA) was inserted into the abdominal cavity. The ingress tubing was exteriorized through the right stab incision and attached to an air compressor (8 gal. 2HP 125 PSI Oil Lube Air Compressor, Central Pneumatic, Harbor Freight, Calabasas, CA) with digital airflow regulator (RMA-24 Dwyer Instruments, Inc., Corporate HQ, Michigan City, IN), while the egress tubing was exteriorized through the left stab incision and connected to a pressure transducer (General Purpose Pressure Transducer PX209, Omega Engineering, Inc., Norwalk, CT), which was connected to a digital display unit (Strain Meter Controller DP25B-S, Omega Engineering, INC, Norwalk, CT). Prior to suture placement, the linea alba was measured and marked with a tissue marker to ensure suture placement 15mm from the linea alba with the suture bites spaced 15mm apart.

All celiotomies were closed using one strand of 3 USP polyglactin 910 (Ethicon US, LLC, Somerville, NJ) in a simple continuous pattern utilizing one of the two different knot combinations. The surgeon's start knot was tied with 5 throws and the surgeon's end knot was tied with 6 throws. The forwarder start knot was tied with 4 throws and the Aberdeen

end knot was tied with 3 throws and 1 turn.^{17,19} These throw combinations were extrapolated from data previously published by our laboratory that determined that these throw combinations displayed the highest knot holding capacity with the smallest knot size.¹⁷⁻¹⁹ The surgeon's and forwarder knots were tied using 8" Mayo-Hegar needle drivers, whereas the Aberdeen knots were tied by hand. All celiotomy closures were timed using a stopwatch (Apple iPhone 6, Apple Inc., Cupertino, CA). All celiotomies were created and closed by 1 surgeon (LM). The skin was left unopposed to allow observation of the suture and body wall during testing. After celiotomy closure, a 5 cm wide nylon ratchet strap was placed caudal to the celiotomy, just cranial to the pelvis, and tightened to prevent herniation of the abdominal organs through the inguinal fascia, as previously described.^{12,13}

Biomechanical testing

All celiotomy constructs were tested within 2 hours of euthanasia (room temperature 65° Fahrenheit, humidity 50%). Bursting strength and failure mode were evaluated by inflating the intra-abdominal bladder with compressed room air at 40 L/min until failure. Bursting strength was defined as the maximum bursting strength (mmHg) recorded before a sudden decrease in the pressure noted by a video recording (Apple iPhone 6, Apple Inc, Cupertino, CA). The mode of failure and digital pressure reading was recorded by a high-speed camera recording at 240 frames per second (Cannon Power Shot SX40 HS, Tokyo, Japan). Mode of failure was defined as either failure of the suture or failure of the abdominal wall. When failure occurred due to the suture, the location of failure (start knot, end knot, mid-suture line) was recorded. All abdominal cavities were thoroughly examined following failure to ensure there was no damage to internal organs.

Statistics

The age, sex, breed and weight of the cadavers were described as stratified by closure type. Continuous variables were described as medians, with ranges. The association between the

closure time and breaking pressure and closure type were assessed using the Wilcoxon Rank Sum test. Significance was set at $P < 0.05$. Descriptive statistics and analyses were conducted using Stata 13.1 (Stata Corp 2013, College Station, TX, USA).

Results:

Study population

Fourteen horses were included in the study population, Horses had a median age of 14.5 years (range 6-27 years), and a median weight of 454kg (363- 597kg). Five horses were mares and nine were geldings. Five horses were American Quarter horses, two were Paint horses, two were Tennessee Walking horses and there was one each of Arabian, Hanoverian, Morgan, Thoroughbred and Welsh Cob breeds. The median weight of S-S horses was 498 kg (range 363-597kg). The median weight of F-A horses was 431 kg (382- 597kg). The median age of S-S horses was 18 years (13- 27kg) and the median for F-A horses was 13 years (6- 25kg). There were significant differences between the age ($P=0.03$) and weights ($P=0.03$) of the groups, with the S-S horses being older and heavier. There were five and four males in the S-S and F-A groups, respectively.

Bursting Strength

The median bursting strength of closure with F-A knot combination (388 mmHg; range 276- 480mmHg) was significantly greater than the median bursting strength of closure with the S-S knot combination (290 mmHg; range 214- 390 mmHg) ($P=0.035$) (Figure 1). There was no significant correlation between horse's age or weight and the bursting strength of the closure ($P=0.10$ and $P=0.47$, respectively).

Failure Mode

The majority of F-A closures failed at the fascia adjacent to the incision ($n=6$). In one cadaver closed with the self-locking knots, the failure occurred mid-suture. In contrast, failure occurred

most commonly at the knot in S-S closures (n=6). In these S-S closures the start knot failed in 4 horses and the end knot failed in two horses. Failure occurred along the fascia adjacent to the incision in only one S-S horse.

Closure Time

There was no significant time difference between closure with the F-A knot combination or closure with the S-S knot combination (P=0.48). The median closure time was 12.26 minutes (8.27-14.00 min.) for F-A closures and 10.15 minutes (9.40-13.27 min.) for S-S knot combinations, respectively (Figure 2). There was no significant correlation between horse age or weight and the closure time (age: P=0.72; weight: P=0.57).

Discussion:

Ex vivo evaluation of a simple continuous suture pattern with a combination of the forwarder start and an Aberdeen end knot (F-A) compared to a traditional surgeon's start and surgeon's end knot (S-S) for ventral midline closure found that a F-A knot combination offers a more secure closure than that of a traditional S-S knot combination. The use of the self-locking knot combination increased incisional bursting strength by an average of 25%. In addition, the use of the F-A knot combination would not prolong surgical time as we found no significant differences in closure times between F-A closure and S-S closure.

We elected to use USP 3 polyglactin 910 for our testing as it is the largest gauge suture available in the United States for closure of equine ventral midline celiotomies and has a good size-to-strength ratio demonstrating greater initial breaking strength and stiffness than polydioxanone.²⁸ To the best of our knowledge, no other authors have specifically examined the effect of different knots on closure of the equine linea alba. Utilizing a surgeon's knot combination, Anderson et. al. demonstrated that closure with USP 7 polydioxanone offered a

stronger closure than that with USP 3 polyglactin 910. However, this large gauge suture is not available in many parts of the world, and the increased size of this suture would seem to neglect the basic surgical principle that recommends against placing more foreign material in an incision line.²⁸

We found no significant correlation in this study between horse age or weight and the bursting strength of closure. However, others have found that increasing age may have a significant negative impact on the celiotomies closed with USP 7 polydioxanone.¹² This report, using a similar experimental model, found a 10.2 mmHg decrease in bursting strength for every year increase in age, suggesting that the strength of the abdominal wall decreases in older horses.¹² These findings are in direct contrast to those reported in our experimental model as well as those by Magee et. al, who also reported no significant effect of age on bursting strength using the same research model as our laboratory.¹³ Further research is warranted to determine the effect of age and/or co-morbidities associated with aged horses have on bursting strength of the ventral abdominal wall.

Several different models have been used to test the strength of different variables in closure of the equine linea alba.^{12-16,29} The intact cadaver model used in this study was originally described by Magee et. al, and has been reported to more accurately simulate in vivo conditions.^{13,30,31} It is thought that the highest intra-abdominal pressures experienced post ventral midline celiotomy are during recovery from general anesthesia, however a direct measurement of this pressure has not been performed. The direct intra-abdominal pressures measured in a normal horse are typically sub-atmospheric at approximately -1.80 cmH₂O.³² Although the supraphysiological pressures experienced in our study would not normally be

encountered in vivo, this model allowed an even stress to be applied to the closure that would mimic potential sudden post-operative conditions.^{12,13,31}

Rapid completion of surgery is an important aspect of proper surgical technique for small and large intestinal lesions, as increased surgical time of exploratory celiotomy results in reduced survival rates and increased incisional complications.³³⁻³⁷ There was no significant difference in the closure time between the F-A and S-S knot combinations, indicating that these novel knots will likely not alter closure times for ventral midline celiotomies. However, if more than one strand of suture is required, multiple knots may be used which could therefore increase surgical time for both knot combinations. A closure utilizing the F-A knot combination could be performed by ending the first continuous line with an Aberdeen knot and starting a second continuous line with a forwarder knot as often performed with a surgeon's knot by some surgeons. This may provide increased security in comparison to current methods, and further studies are warranted to investigate additional applications of the F-A knot combination.

Basic surgical principles state that suture should be as strong as the tissue through which it is placed.²⁸ The celiotomies that were closed with the F-A knot combination most commonly failed at the fascia adjacent to the incision. This suggests that when the F-A combination is utilized, the suture/celiotomy construct is as strong or stronger than the surrounding tissue. This is in comparison to the majority of our S-S constructs (n=6, 86%) that failed at the knot. Magee et. al found similar results, with 71% of their constructs completed with a surgeon's knot using a simple continuous suture pattern failing at the knot.¹³ It has been suggested that it takes approximately 8 weeks for a linea alba incision to be comparable in strength and collagen formation to that of a control linea alba following ventral midline celiotomy.³⁸ In

that study significant increases in tensile strength were observed between 2 and 4 week specimens, emphasizing the importance of a strong and secure closure in the interim period.³⁸ During this acute healing phase, when the celiotomy closure is relying heavily on the suture line and knots, the F-A knot combination may provide an advantage over the use of a traditional S-S knot combination, as our results show it to be as strong as the surrounding tissue.

In the study by Magee et al, four knots were used to complete the celiotomy closure, but the knot which failed was not specified.¹³ Fifty-seven percent of our S-S knot combinations failed at the start knot. Our surgeon's start knot was secured with 5 throws and our surgeon's end knot was placed with 6 throws. These throw combinations were based on previous in vitro studies from our laboratory that showed these displayed the highest KHC and the smallest knot volume.¹⁷⁻¹⁹ The start knot may have failed more frequently due to the variation between in vitro and ex vivo testing, however the numbers were too low for statistical analysis. In addition to Magee et. al, many other studies that used a traditional surgeon's knot combination found that the majority of constructs failed at the suture and more specifically adjacent to the knot.^{14,15} One explanation for this finding is that the load applied to the surgeon's knot results in a stress accumulation between the interface of the loop and the first throw, causing failure at the knot. In contrast, when a load is applied to the self-locking knots, the intrinsic properties of these knots allow the suture to slide within the knot dissipating the tension and reducing the coefficient of friction at the knot-suture interface.^{18,19,26,27} This property allows the self-locking knot to be more secure and stronger in comparison to traditional surgeon's knot offering a more secure closure.

In contrast to celiotomy/suture constructs failing at the knot or along the suture, they may also fail along the body wall adjacent to the suture line or remote to the suture line.^{12,13,16}

There are a few studies where the majority of failures occurred along the fascia, demonstrating that their construct is as strong as the surrounding tissues, however, they have their limitations. One study investigated the optimum tissue bite interval for celiotomy closure.¹⁶ This model used a double stranded loop suture of USP 2 braided lactomer 9-1 and closed the incisions with two strands of suture starting mid incision, involving a knot at either end. Although the bursting pressures experienced were higher than our study (420.0-479.4 mmHg) and the closures contained the same total number of knots per incision, the disadvantage of this method is placement of a four-stranded knot along with the use of 2 strands along the continuous suture line. This results in a larger volume of suture material for closure than one-stranded continuous sutured lines.

We created a relatively small celiotomy incision of 20 cm, to facilitate closure with a single strand of suture material. Often a ventral midline celiotomy incision may be extended past 20 cm, particularly if large colon manipulation is required. Polyglactin 910 suture size USP 3 is only available in a length of 70 cm, and closure with only one suture strand would be difficult, if not impossible, if extended beyond 20 cm. Further studies may need to evaluate the use of size USP 2 Polyglactin 910, due to the availability of a longer suture strand (135cm) which would allow for fewer knots to close longer incision lines.

An additional complication of the use of both the forwarder and Aberdeen knot is that they are both sliding, self-locking knots. Therefore, it is possible that some level of suture translation may occur within the knot resulting in constriction of the knot around the linea alba tissues, to the detriment of wound healing. Although we did not specifically examine this

in our study, the unbroken knot loops were measured post-failure in an attempt to quantify the degree of tissue constriction. Many of the S-S knots were destroyed in the testing, and as a result there were too few knots to statistically compare. It must be recognized that the tension of knot constriction would be opposed by the intrinsic tension of the tissue and also the tension throughout the length of the suture line. To the author's knowledge, there are no published studies that examine either the effect of constriction of the forwarder or Aberdeen self-locking knots, and also surgeon's knots. Studies are warranted to specifically assess the constriction of these knots in vivo, and their effect on tissue healing.

The results of this study demonstrate that ventral midline celiotomy closure with USP 3 polyglactin 910 using a self-locking knot combination of a F-A obtained greater bursting strength than closure with S-S knot. Most of the constructs closed with F-A knots failed along the abdominal wall, suggesting that this suture and knot combination is as strong or stronger than the tissue in which it is placed.²⁸ In addition, surgical closure times are not significantly increased with the F-A knot combination. As the forwarder and Aberdeen knots have a smaller weight and volume compared to the surgeon's knot, this combination may reduce the volume of foreign material within the closure of the linea alba.¹⁷⁻¹⁹ Based on this data, the F-A knot combination appear to be a viable option for improving the bursting strength of ventral midline celiotomy closure in horses. Further investigations will be necessary to validate this technique for recommendation in clinical cases.

Funding:

The research project was funded in part by the Birmingham Racing Commission.

Disclosure:

The authors report no financial or other conflicts related to this report.

Abstract:

The paper was accepted for presentation in the resident's forum at the 2017 ACVS surgery summit in Indianapolis.

References:

1. Anderson SL, Devick I, Bracamonte JL, et al. Occurrence of Incisional Complications After Closure of Equine Celiotomies With USP 7 Polydioxanone. *Vet Surg.* 2015;44:521-526.
2. Gibson KT, Curtis CR, Turner AS, et al. Incisional hernias in the horse. Incidence and predisposing factors. *Vet Surg.* 1989;18:360-366.
3. Freeman DE. Management of ventral incisional hernias in large horses: a surgical challenge. *Equine Veterinary Education.* 2010;17:247-251.
4. Mair TS, Smith LJ. Survival and complication rates in 300 horses undergoing surgical treatment of colic. Part 2: Short-term complications. *Equine Vet J.* 2005;37:303-309.
5. Kobluk CN, Ducharme NG, Lumsden JH, et al. Factors affecting incisional complication rates associated with colic surgery in horses: 78 cases (1983-1985). *J Am Vet Med Assoc.* 1989;195:639-642.
6. Wilson DA, Baker GJ, Boero MJ. Complications of celiotomy incisions in horses. *Vet Surg.* 1995;24:506-514.
7. Ingle-Fehr JE, Baxter GM, Howard RD, et al. Bacterial culturing of ventral median celiotomies for prediction of postoperative incisional complications in horses. *Vet Surg.* 1997;26:7-13.
8. Jenkins TP. The burst abdominal wound: a mechanical approach. *Br J Surg.* 1976;63:873-876.

9. French NP, Smith J, Edwards GB, et al. Equine surgical colic: risk factors for postoperative complications. *Equine Vet J.* 2002;34:444-449.
10. Mair TS, Smith LJ. Survival and complication rates in 300 horses undergoing surgical treatment of colic. Part 1: Short-term survival following a single laparotomy. *Equine Veterinary Journal.* 2005;37:296-302.
11. Mair TS, Smith LJ, Sherlock CE. Evidence-based gastrointestinal surgery in horses. *Vet Clin North Am Equine Pract.* 2007;23:267-292.
12. Anderson SL, Bracamonte JL, Hendrick S, et al. Ex vivo comparison of 7 polydioxanone, 2 polyglactin 910 for closure of ventral median celiotomy in horses. *Vet Surg.* 2013;42:463-467.
13. Magee AA, Galuppo LD. Comparison of incisional bursting strength of simple continuous and inverted cruciate suture patterns in the equine linea alba. *Vet Surg.* 1999;28:442-447.
14. Fierheller EE, Wilson DG. An in vitro biomechanical comparison of the breaking strength and stiffness of polydioxanone (sizes 2, 7) and polyglactin 910 (sizes 3, 6) in the equine linea alba. *Vet Surg.* 2005;34:18-23.
15. Trostle SS, Wilson DG, Stone WC, et al. A study of the biomechanical properties of the adult equine linea alba: relationship of tissue bite size and suture material to breaking strength. *Vet Surg.* 1994;23:435-441.
16. Hassan KA, Galuppo LD, van Hoogmoed LM. An in vitro comparison of two suture intervals using braided absorbable loop suture in the equine linea alba. *Vet Surg.* 2006;35:310-314.
17. Coleridge M, Gillen AM, Farag R, et al. Effect of fluid media on the mechanical properties of continuous pattern-ending surgeon's, square, and Aberdeen knots in vitro. *Vet Surg.* 2017;46:306-315.

18. Gillen AM, Munsterman AS, Farag R, et al. In Vitro Evaluation of the Aberdeen Knot for Continuous Suture Patterns with Large Gauge Suture. *Vet Surg.* 2016;45:955-961.
19. Gillen AM, Munsterman AS, Hanson RR. In Vitro Evaluation of the Size, Knot Holding Capacity, and Knot Security of the Forwarder Knot Compared to Square and Surgeon's Knots Using Large Gauge Suture. *Vet Surg.* 2016;45:1034-1040.
20. Tera H, Aberg C. The strength of suture knots after one week in vivo. *Acta Chir Scand.* 1976;142:301-307.
21. Bourne RB, Bitar H, Andreae PR, et al. In-vivo comparison of four absorbable sutures: Vicryl, Dexon Plus, Maxon and PDS. *Can J Surg.* 1988;31:43-45.
22. Mulon PY, Zhim F, Yahia L, et al. The effect of six knotting methods on the biomechanical properties of three large diameter absorbable suture materials. *Vet Surg.* 2010;39:561-565.
23. Daes J. Self-locking first stitch in suture reinforcement of the laparoscopic gastric sleeve. *Obes Surg.* 2013;23:794-795.
24. Serra C, Perez N, Bou R, et al. Sliding self-locking first stitch and Aberdeen knot in suture reinforcement with omentoplasty of the laparoscopic gastric sleeve staple line. *Obes Surg.* 2014;24:1739-1740.
25. Schaaf O, Glyde M, Day RE. A secure Aberdeen knot: in vitro assessment of knot security in plasma and fat. *J Small Anim Pract.* 2009;50:415-421.
26. Schaaf O, Glyde M, Day RE. In vitro comparison of secure Aberdeen and square knots with plasma- and fat-coated polydioxanone. *Vet Surg.* 2010;39:553-560.
27. Israelsson LA, Jonsson T. Physical properties of self locking and conventional surgical knots. *Eur J Surg.* 1994;160:323-327.
28. Kümmerle JM. Chapter 16 -Suture Materials and Patterns. In: Auer JA, Stick JA eds: *Equine Surgery* (4th ed). Saint Louis, MO, Saunders, 2012, 181-202.

29. Boone LH, Epstein K, Cremer J, et al. Comparison of tensile strength and early healing of acute repeat celiotomy through a ventral median or a right ventral paramedian approach. *Vet Surg.* 2014;43:741-749.
30. Poole GV, Jr. Mechanical factors in abdominal wound closure: the prevention of fascial dehiscence. *Surgery.* 1985;97:631-640.
31. Poole GV, Jr., Meredith JW, Kon ND, et al. Suture technique and wound-bursting strength. *Am Surg.* 1984;50:569-572.
32. Munsterman AS, Hanson RR. Comparison of direct and indirect methods of intra-abdominal pressure measurement in normal horses. *J Vet Emerg Crit Care (San Antonio).* 2009;19:545-553.
33. Morton AJ, Blikslager AT. Surgical and postoperative factors influencing short-term survival of horses following small intestinal resection: 92 cases (1994-2001). *Equine Veterinary Journal.* 2010;34:450-454.
34. Proudman CJ, Smith JE, Edwards GB, et al. Long-term survival of equine surgical colic cases. Part 2: Modelling postoperative survival. *Equine Veterinary Journal.* 2010;34:438-443.
35. Dukti S, White N. Surgical complications of colic surgery. *Vet Clin North Am Equine Pract.* 2008;24:515-534, vii-viii.
36. Freeman DE. Chapter 36 -Small Intestine. In: Auer JA, Stick JA eds: *Equine Surgery* 4th ed. Saint Louis, MO, Saunders, 2012, 416-453.
37. Rakestraw PE, Hardy J. Chapter 37 -Large Intestine. In: Auer JA, Stick JA eds: *Equine Surgery* 4th ed. Saint Louis, MO, Saunders, 2012, 454-494.
38. Chism PN, Latimer FG, Patton CS, et al. Tissue strength and wound morphology of the equine linea alba after ventral median celiotomy. *Vet Surg.* 2000;29:145-151.

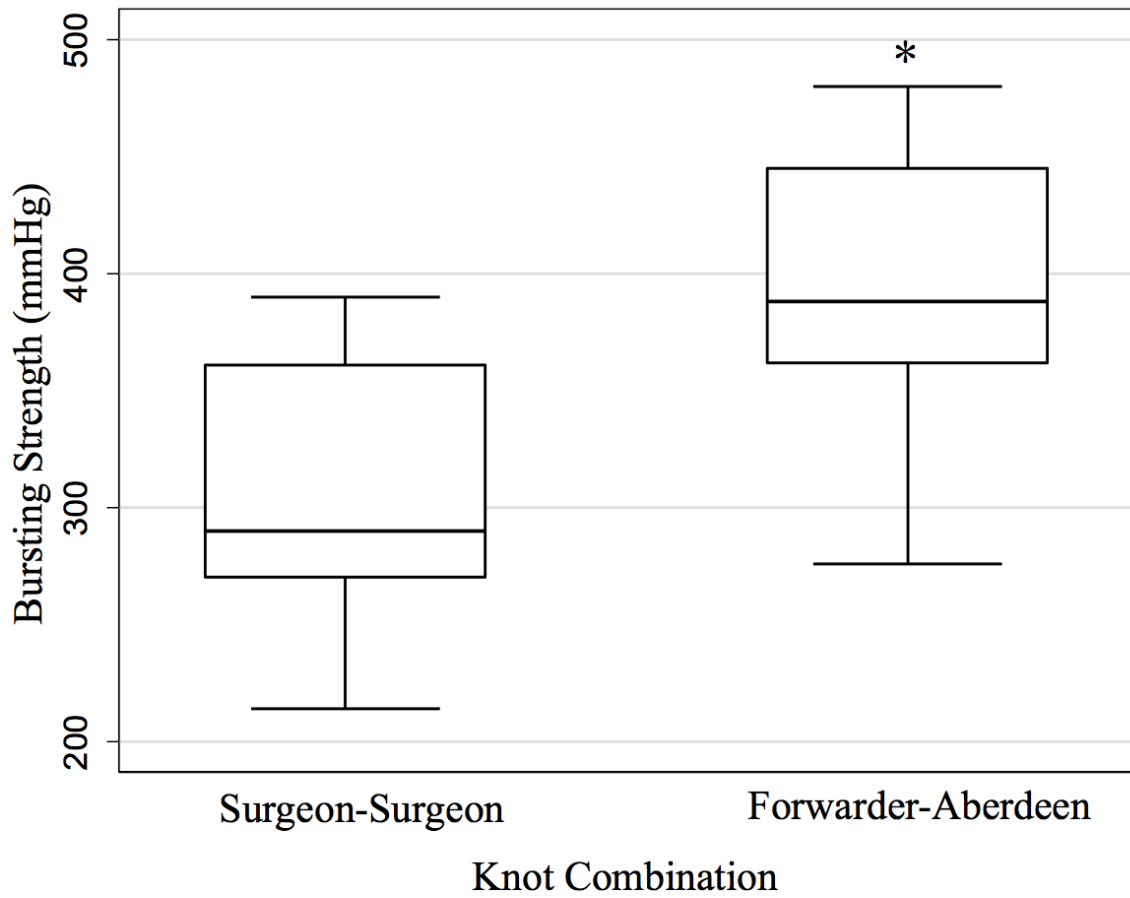


Figure 1. Box plots (median, 25% and 75% quartiles, and range) showing the difference in bursting strength of a Surgeon-Surgeon (S-S) and Forwarder-Aberdeen (F-A) knot combinations. The F-A knot combinations demonstrated significantly higher median bursting strength than the S-S combination ($P=0.035$) as identified by the *

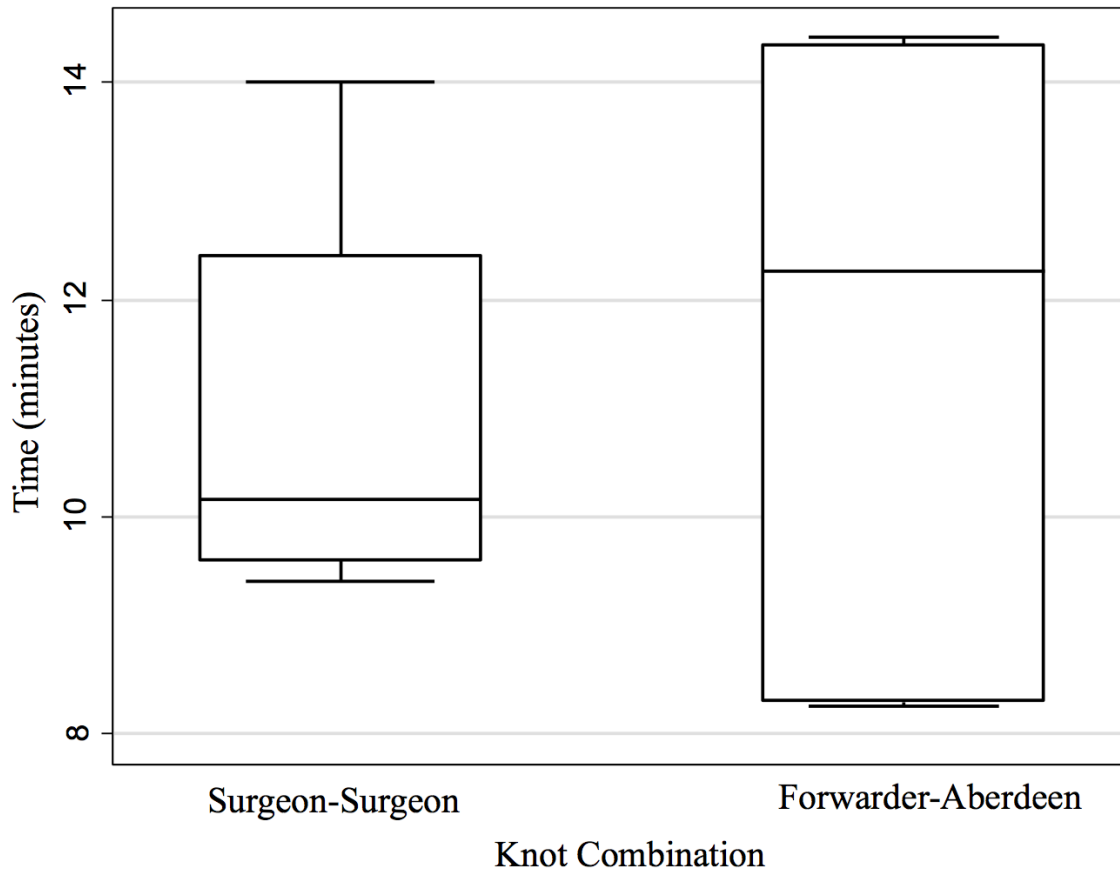


Figure 2. Box plots (median, 25% and 75% quartiles, and range) showing the difference in closure times of a Surgeon-Surgeon (S-S) and Forwarder-Aberdeen (F-A) Knot Combinations. No significant differences in closure times were observed between the two knot combinations (P=0.48).