




Available online at
ScienceDirect
www.sciencedirect.com

Elsevier Masson France
EM|consulte
www.em-consulte.com/en



MINI REVIEW

Hepatitis C virus and atherosclerosis: A legacy after virologic cure?



M.F. Bassendine^{a,b,*}, S.U. Nielsen^a, S.H. Bridge^{a,c},
D.J. Felmlee^{a,d}, D.A. Sheridan^{a,d}, C.J. Packard^e, R.D. Neely^f

^a Institute of Cellular Medicine, Newcastle University, United Kingdom

^b Department of Hepatology & Gastroenterology, Imperial College London, United Kingdom

^c Health and Life Sciences, Northumbria University, Newcastle upon Tyne, United Kingdom

^d Institute of Translational and Stratified Medicine, Peninsula Schools of Medicine & Dentistry, Plymouth University, United Kingdom

^e Institute of Cardiovascular and Medical Sciences, Floor 2, McGregor Building, University of Glasgow, United Kingdom

^f Department of Clinical Biochemistry, Newcastle upon Tyne Hospitals NHS Foundation Trust, United Kingdom

Available online 11 November 2016

Summary Hepatitis C virus (HCV) is a major pathogen with approximately 3% of the world's population (over 170 million) infected. Epidemiological studies have shown HCV is associated with an increased risk of cardiovascular and cerebrovascular mortality as well as peripheral arterial disease. This is despite HCV inducing an ostensibly favourable lipid profile with accompanying low classical risk score for atherosclerosis (AS). We discuss possible factors involved in the aetiopathogenesis of atherosclerosis in chronic HCV and hypothesise that an important mechanism underlying the development of AS is the presence of circulating low-density immune complexes that induce an inflammatory response. We suggest that HCV particles may be inducing an antibody response to lipoproteins present in the lipoviral particles and sub-viral particles – a concept similar to the more general 'autoantibody' response to modified LDL. After virologic cure some AS risk factors will recede but an increase in serum cholesterol could result in progression of early atherosclerotic lesions, leaving a legacy from persistent HCV infection that has clinical and therapeutic implications.

© 2016 Elsevier Masson SAS. All rights reserved.

* Corresponding author at: Department of Medicine, 10th Floor QEQM Wing, St. Mary's Hospital Campus, Imperial College London, South Wharf Street, London W2 1NY, United Kingdom.

E-mail address: m.bassendine@imperial.ac.uk (M.F. Bassendine).

Introduction

Atherosclerosis (AS) is the underlying cause of heart attack, ischaemic stroke and peripheral vascular disease and hence is a leading cause of morbidity and mortality. Traditional risk factor assessment has focused on parameters identified in epidemiological studies such as the Framingham Heart Study (FHS) (age, hypertension, cholesterol, family history, and cigarette smoking). However, a sizeable minority of patients suffering from atherosclerosis do not harbour the classical risk factors. Other predisposing factors appear to contribute to the disease process including chronic viral infections [1–3].

Lifelong exposure to raised concentrations of low-density lipoprotein cholesterol (LDL-C) increases cardiovascular event rates and the use of statin therapy as an adjunct to diet, exercise, and smoking cessation has proven highly effective in reducing the population burden of disease associated with hyperlipidaemia [4]. Conversely, rare inherited conditions such as hypobetalipoproteinemia and PCSK9 loss-of-function mutations have shown that very low LDL levels are associated with reduced risk of cardiovascular disease [5].

The human hepatitis C virus, hepatitis C virus (HCV) is a major pathogen with approximately 3% of the world's population (over 170 million) infected. 70% of those infected fail to clear the virus and are at risk of developing liver complications, mainly cirrhosis and liver cancer.

HCV affects cholesterol homeostasis and chronic infection is associated with a decrease in serum concentrations of total cholesterol, LDL-C and apolipoprotein B (apoB – the main protein constituent of LDL and very-low-density lipoprotein (VLDL)). These changes are more marked in HCV genotype 3 infection and effective anti-viral treatment results in their reversal (reviewed in [6,7]). Despite this apparently favourable lipid profile, HCV infection is

associated with an increased risk of atherosclerosis and its clinical manifestations [8].

HCV and atherosclerosis

It became apparent over a decade ago that HCV might be considered as a risk factor for the development of coronary artery disease (CAD) [9]. In 2012, a systematic review of the literature suggested an increased risk of CAD in HCV-infected individuals [10]. Subsequently myocardial perfusion defects have been found in 87% of the patients with chronic hepatitis C, which improved with viral eradication [11].

Carotid intima-media thickness (IMT) has been used as a surrogate of sub-clinical atherosclerosis and studies have shown that, after adjustment for classical cardiovascular risk factors, those with chronic HCV infection have raised IMT [12] and this occurs at an earlier age [13]. HCV RNA has been found in carotid plaques [14]. Recent meta-analyses have shown that HCV infection increases the risk of developing carotid intima media thickening by approximately 4-fold [15]; other studies found an increased risk of carotid atherosclerosis and of stroke (pooled OR of 1.76 & 1.97 respectively) [16,17].

Although some of the earlier studies did not identify an association between HCV and cardiovascular morbidity (reviewed in [18]), an increasing number of large epidemiological studies do confirm an association of HCV infection with atherosclerosis [19–22] (Table 1). One recent retrospective cohort study found that both HCV antibody positivity ($n = 8251$ individuals) and HCV RNA positivity (1434 individuals) were independent risk factors for coronary heart disease events (OR 1.32 and 1.59 respectively), when compared to 14,799 HCV negative patients [23]. This study concluded that lipid profile did not appear to be a good cardiovascular disease risk stratification tool in patients with HCV infection. Another recent study has also concluded that

Table 1 Some observational studies in HCV exposed individuals identifying risk of AS.

Reference	No. of participants	Atherosclerosis risk
Guiltinan AM et al., 2008 [19]	10,259 HCV antibody-positive (HCV+) vs 10,259 HCV antibody-negative (HCV-) blood donors	Increase in cardiovascular mortality (HR = 2.21 , 95% CI: 1.41–3.46)
Butt AA et al., 2009 [20]	82,083 HCV-infected vs 89,582 HCV-uninfected subjects	Higher risk of CAD (HR = 1.25 , 95% CI: 1.20–1.30).
Freiberg MS et al., 2011 [21]	8579 participants (9% HIV+HCV+ vs 28% HIV+ HCV-)	HIV+HCV+ had higher risk of CHD (HR = 2.03 , 95% CI: 1.28–3.21)
Lin MS et al., 2014 [22]	5015 eligible Taiwanese residents, age >40 years	HCV+ had 1.76 -fold risk of ischaemic ECG when compared with non-HCV
Pothineni NV et al., 2014 [23]	8251 HCV antibody positive, 1434 HCV RNA positive, vs 14,799 HCV negative patients	Increased risk of incident CHD events in HCV antibody-positive (OR = 1.32 , 95% CI: 1.09–1.60, $P < 0.001$) and HCV RNA positive (OR = 1.59 , 95% CI: 1.13–2.26, $P < 0.001$)
Lee MH et al. 2010 [25]	23,665 residents (aged 30–65 years), 255 cerebrovascular deaths during 382,011 person-years of follow-up	Increase in cerebrovascular death (HR = 2.18 , 95% CI: 1.50–3.16) for HCV-antibody positive
Hsu YH et al., 2015 [26]	7641 HCV-infected patients and 30,564 matched controls	Increase in peripheral arterial disease in HCV-infected patients (HR = 1.43 , 95% CI: 1.23–1.67) compared with non-HCV patients

Bold: significant increased risk of AS.

the Framingham Risk Score (FRS) may underestimate coronary heart disease (CHD) risk in both HCV mono-infected and HIV/HCV co-infected persons [24].

In a community based prospective cohort study of 23,665 Taiwanese residents (aged 30–65 years) the hazard ratio of cerebrovascular death was 2.18 (95% CI: 1.50–3.16) for anti-HCV seropositive individuals after adjustment for conventional risk factors of cerebrovascular disease. Compared with participants seronegative for anti-HCV as the referent, the multivariate-adjusted hazard ratio was 1.40, 2.36 and 2.82, respectively, for anti-HCV-seropositive participants with undetectable, low, and high serum levels of HCV RNA ($P < 0.001$ for trend) [25].

Another manifestation of atherosclerosis is peripheral vascular disease and, again, a population based study in Taiwan of 7641 HCV-infected patients compared to 30,564 matched controls has found a higher adjusted risk of peripheral arterial disease in the HCV-infected group of 1.43 which increased with age to 11.7 in those aged 65 years and above [26].

Aetiopathogenesis of HCV-associated atherosclerosis

As elevated LDL-C does not play a role during persistent HCV infection and FRS underestimates AS risk in these patients, it is important to examine other factors that may be playing a role. HCV infection may represent a new paradigm and reveal mechanism(s) that are relevant in up to 20% of patients with coronary heart disease who do not have conventional risk factors [27].

It is likely that the aetiopathogenesis of AS in HCV infection is multifactorial and pathogenic mechanism(s) may include:

- Endothelial dysfunction: in the last decades the endothelium has emerged as the key regulator of vascular homeostasis. Endothelial dysfunction and inflammation are linked to the pathogenesis of atherosclerotic disease. Increased risk for CV events is associated with increased levels of cytokines, cell-adhesion molecules, P-selectin and E-selectin and acute phase reactants, such a high-sensitivity C-reactive protein (CRP). Platelet-endothelial interactions occur in early atherosclerosis. Soluble P-selectin, a marker of *in vivo* platelet activation, is a cellular adhesion molecule that has been shown to be crucial in development of CHD. A positive linear association between P-selectin levels and rate of incident CHD after adjustment for traditional risk factors has been observed [28].
HCV infection of endothelial cells [29] may promote endothelial dysfunction and early atherogenesis. Patients with chronic hepatitis C infection have increased levels of several inflammatory markers including high-sensitivity CRP, soluble intercellular adhesion molecule-1, soluble vascular cell adhesion molecule-1, soluble E-selectin and P-selectin [30,31].
- Lipid disturbances: HCV causes profound changes in lipid metabolism including a raised Cholesteryl Ester Transfer Protein (CETP) [32]. CETP promotes the transfer of cholesteryl esters from HDL to very-low-density lipoprotein and LDL. Human genetic studies and human cohort studies have concluded that CETP gene polymorphisms associated with decreased CETP activity are accompanied by a significantly lower risk of atherosclerotic cardiovascular disease.
CETP inhibition raises HDL-C levels, long touted as the “good cholesterol”, and is being evaluated for treatment of atherosclerosis [33]. CETP inhibitors, as monotherapy or with statins, significantly reduce the concentrations of atherogenic apoB-containing lipoproteins, including Lp(a) [34]. However recent phase 3 outcome trials have shown limited benefit of CETP inhibitors on cardiovascular outcomes when combined with the current standard of care [35]. Hence no one CETP inhibitor is currently available in the clinic. Future trials should possibly focus on individuals with both AS and raised CETP such as those with chronic HCV infection.
- Metabolic disturbances: positive associations have been observed between CVD and type 2 diabetes mellitus (DM), but their causal relationship has not been clarified. Epidemiological data indicate a risk for development of insulin resistance (IR) particularly in patients with hepatitis C virus (HCV) genotype 1 infection and, ultimately, overt DM [36], although a recent large population-based study has not confirmed an appreciable excess risk of DM [37]. However, in a meta-analysis of 22 observational studies, the effect of HCV on CVD mortality was stronger in populations with a higher prevalence of diabetes (>10%) or hypertension (>20%) (OR, 1.71; 95% CI: 1.32–2.23; $P < .001$ for both) [38]. Eradication of HCV improves IR and insulin hypersecretion, as well as high baseline insulin resistance (HOMA-IR > 2.5) [39], so this risk factor should resolve after virologic cure.
- MicroRNAs (miRNAs) are small noncoding RNAs involved in intercellular communication; they have been shown to circulate in the bloodstream in stable forms. In the past years specific miRNA expression patterns have been linked to the development of atherosclerosis [40]. HCV infection alters the expression of host miRNAs and, in turn, miRNAs are able to regulate HCV replication [41]. It has been proposed that miR-122, the most abundant liver miRNA which plays a central role in the maintenance of lipid homeostasis, may constitute a novel biomarker for cardiovascular disease [42].
MiR-122 has been shown to modulate hepatic production of apoB-containing low density lipoprotein [43] and is a sensitive serum marker to distinguish chronic hepatitis C patients from healthy controls [44]. Administration of miravirsen, an anti-miR-122 oligonucleotide, has been shown to result in a dose dependent and prolonged decrease in HCV RNA levels in chronic hepatitis C patients [45]. The role of the deranged miRNAs induced by HCV in the aetiopathogenesis of HCV-associated AS is unclear.
- Autoimmunity: (auto)immune reactivity to a range of autoantigens, but most prominently modified LDL (mLDL), is a marker of human cardiovascular disease and in experimental models plays a significant role in promoting atherosclerotic plaque progression. Both pathogenic and protective immunity to apoB have been identified [46] but it appears that, in humans, the humoral immune response to mLDL is pathogenic rather than protective [reviewed in

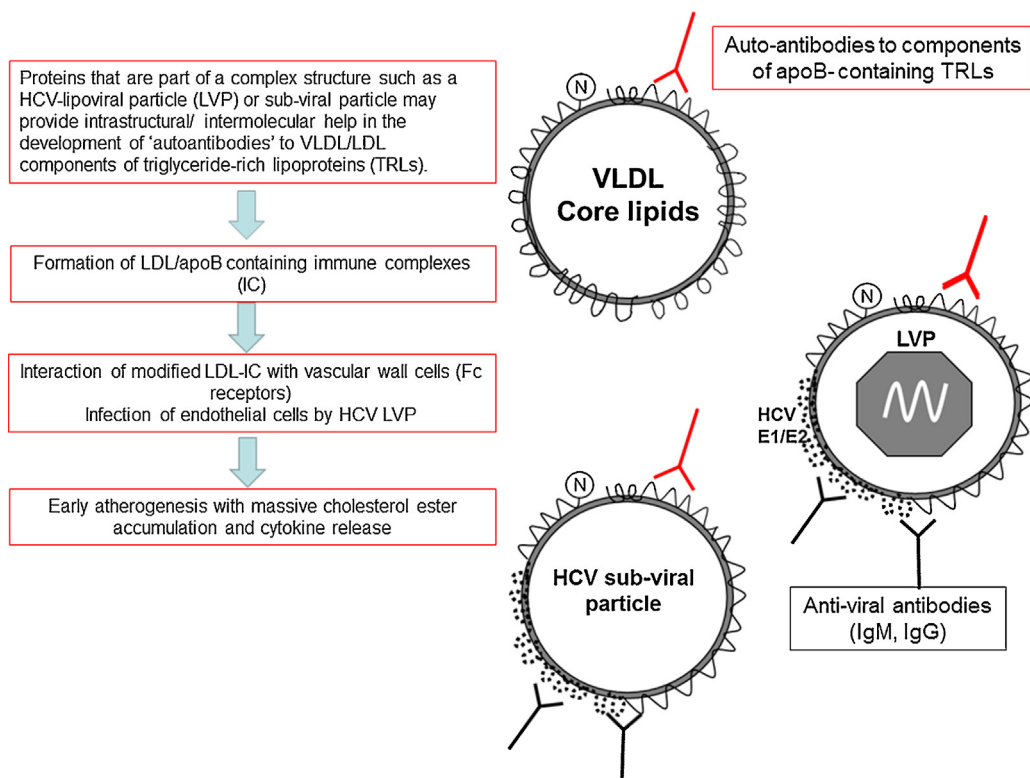


Figure 1 (Auto)immune reactivity to a host antigen(s) within HCV lipo-viral and sub-viral particles may play a role in promoting atherosclerosis.

[47]. B cell-activating factor (BAFF) is a tumour necrosis factor-family cytokine that plays a key role in generating and maintaining the mature B-cell pool. BAFF is known to be involved in the occurrence of autoimmune diseases. BAFF signalling *via* the B-cell activating factor receptor (BAFFR) is essential for B2 cell survival; these cells seem to be proatherogenic. In chronic HCV infection, elevation in serum BAFF has been reported to be associated with HCV-related vasculitis ($P < 0.0001$), and with the presence of anticardiolipin antibodies and of cryoglobulins [48].

Modified LDL-containing immune complexes (mLDL-IC) play a role in the formation of early atherosclerotic lesions (reviewed in [49,50]). Infectious HCV lipoviral particles (LVPs) found in the low density fraction of blood contain HCV-RNA + structural viral proteins + apoB + apoE + apoCII + triglycerides + cholesterol + phospholipids; the majority are complexed with IgG and IgM [51]. However it is now clear that LVPs are a mixed population of particles, comprising predominantly subviral particles which outnumber HCV-RNA containing LVPs by $>1 \times 10^6$. These HCV envelope glycoprotein-positive lipoproteins represent a distinct class of modified lipoproteins within the TRL family [52] and are present in immune-complexes in patients with chronic HCV. We hypothesise that an important mechanism underlying the development of AS in HCV infection is the presence of these circulating low-density immune complexes that are taken up by monocytes *via* Fc gamma receptors, inducing an inflammatory response (Fig. 1). HCV has been found in

cutaneous vasculitic lesions in complex with IgM and IgG in patients with type II cryoglobulinemia [53].

Atherosclerosis initiation and progression are thought to be primarily mediated by cells of the monocyte/macrophage lineage [54,55]. The uptake of mLDL-immune complexes by human macrophages leads to massive cholesterol ester accumulation, cytokine release and overexpression of the LDL receptor (LDLR) [56]. LDLR plays a role in the life-cycle of HCV [57] and HCV infection induces higher expression of LDLR on lymphocytes and monocytes [58]. Monocytes, macrophages and dendritic cells can be infected by HCV, so a direct pro-inflammatory effect may also contribute to AS. In addition HCV infection of monocytes increases immunoregulatory galectin-9 production and there is emerging evidence for a role for galectins in AS [59].

Virologic cure and atherosclerosis

Virologic cure is now achievable in the vast majority of patients treated with direct-acting anti-viral (DAA) therapy and reduces the risk of liver disease progression [60].

The effect of virologic cure on AS progression is however unknown but a significant AS risk has also been reported in those that are HCV antibody positive but HCV RNA negative.

Early atherosclerotic lesions appear to be a feature of chronic HCV infection, despite the virus inducing an apparently favourable lipid profile. AS risk increases with age and

therefore, presumably, duration of chronic viral infection. Current evidence indicates that the risk of a person with chronic hepatitis C developing coronary atherosclerosis is about triple the risk in uninfected persons (OR = 3.06, 95% CI = 1.99–4.72) [61]. Virologic cure will lead to improvements in some AS risk factors outlined above such as insulin resistance [39] and the consequences of direct infection of endothelial cells and monocytes but other factors such as HCV-induced autoimmunity to mLDL may persist. This is suggested by the observation in chimpanzees that the frequency of T-regulatory cells and the extent of suppression is as high in those that recovered from HCV as in persistently HCV-infected animals, suggesting ongoing control of an ‘autoimmune’ response [62].

In addition virologic cure will result in increases in serum cholesterol and LDL-C [63], creating a combination of circumstances that will aggravate early atherosclerotic lesions. This ‘perfect storm’ for AS progression after virologic cure has important clinical and therapeutic implications. Not only should patients be monitored for AS but statin therapy should also be considered. This is particularly pertinent if an autoimmune response to mLDL persists after cure as a recent study has shown that simvastatin therapy in CAD patients lowers small LDL-IgG-IC levels to a greater extent than LDL-cholesterol levels [64].

Disclosure of interest

D.A.Sheridan reports receiving speaker honoraria from Gilead Sciences, AbbVie, Janssen and Alexion Pharmaceuticals.

C.J. Packard reports research grants from Roche and honoraria from Merck, Sharpe & Dohme, and Sanofi.

R.D. Neely reports consultant/advisor roles with Amgen, Sanofi and Regeneron and participation as site-investigator in clinical trials of new pharmaceuticals from IONIS, Amgen, Sanofi-Regeneron and Merck, Sharpe & Dohme.

The other authors have not supplied their declaration of competing interest.

References

- [1] Boccarda F, Lang S, Meuleman C, Ederhy S, Mary-Krause M, Costagliola D, et al. HIV and coronary heart disease: time for a better understanding. *J Am Coll Cardiol* 2013;61(5):511–23.
- [2] Campbell LA, Rosenfeld ME. Infection and atherosclerosis development. *Arch Med Res* 2015;46(5):339–50.
- [3] Ji YN, An L, Zhan P, Chen XH. Cytomegalovirus infection and coronary heart disease risk: a meta-analysis. *Mol Biol Rep* 2012;39(6):6537–46.
- [4] Ridker PM. LDL cholesterol: controversies and future therapeutic directions. *Lancet* 2014;384(9943):607–17.
- [5] Kostis WJ. How low an LDL-C should we go with statin therapy? *Curr Atheroscler Rep* 2014;16(2):388.
- [6] Bassendine MF, Sheridan DA, Bridge SH, Felmler DJ, Neely RD. Lipids and HCV. *Semin Immunopathol* 2013;35(1):87–100.
- [7] Paul D, Madan V, Bartenschlager R. Hepatitis C virus RNA replication and assembly: living on the fat of the land. *Cell Host Microbe* 2014;16(5):569–79.
- [8] Ampuero J, Romero-Gomez M. Assessing cardiovascular risk in hepatitis C: an unmet need. *World J Hepatol* 2015;7(19):2214–9.
- [9] Vassalle C, Masini S, Bianchi F, Zucchelli GC. Evidence for association between hepatitis C virus seropositivity and coronary artery disease. *Heart* 2004;90(5):565–6.
- [10] Roed T, Lebech AM, Kjaer A, Weis N. Hepatitis C virus infection and risk of coronary artery disease: a systematic review of the literature. *Clin Physiol Funct Imaging* 2012;32(6):421–30.
- [11] Maruyama S, Koda M, Oyake N, Sato H, Fujii Y, Horie Y, et al. Myocardial injury in patients with chronic hepatitis C infection. *J Hepatol* 2013;58(1):11–5.
- [12] Mostafa A, Mohamed MK, Saeed M, Hasan A, Fontanet A, Godsland I, et al. Hepatitis C infection and clearance: impact on atherosclerosis and cardiometabolic risk factors. *Gut* 2010;59(8):1135–40.
- [13] Adinolfi LE, Restivo L, Zampino R, Guerrera B, Lonardo A, Ruggiero L, et al. Chronic HCV infection is a risk of atherosclerosis. Role of HCV and HCV-related steatosis. *Atherosclerosis* 2012;221(2):496–502.
- [14] Boddi M, Abbate R, Chellini B, Giusti B, Giannini C, Pratesi G, et al. Hepatitis C virus RNA localization in human carotid plaques. *J Clin Virol* 2010;47(1):72–5.
- [15] Olubamwo OO, Onyeka IN, Miettola J, Kauhanen J, Tuomainen TP. Hepatitis C as a risk factor for carotid atherosclerosis – a systematic review. *Clin Physiol Funct Imaging* 2016;36:249–60.
- [16] He H, Kang R, Zhao Z. Hepatitis C virus infection and risk of stroke: a systematic review and meta-analysis. *PLoS ONE* 2013;8(11):e81305.
- [17] Huang H, Kang R, Zhao Z. Is hepatitis C associated with atherosclerotic burden? A systematic review and meta-analysis. *PLOS ONE* 2014;9(9):e106376.
- [18] Negro F. Facts and fictions of HCV and comorbidities: steatosis, diabetes mellitus, and cardiovascular diseases. *J Hepatol* 2014;61(1 Suppl):S69–78.
- [19] Guitinan AM, Kaidarova Z, Custer B, Orland J, Strollo A, Cyrus S, et al. Increased all-cause, liver, and cardiac mortality among hepatitis C virus-seropositive blood donors. *Am J Epidemiol* 2008;167(6):743–50.
- [20] Butt AA, Xiaoqiang W, Budoff M, Leaf D, Kuller LH, Justice AC. Hepatitis C virus infection and the risk of coronary disease. *Clin Infect Dis* 2009;49(2):225–32.
- [21] Freiberg MS, Chang CC, Skanderson M, McGinnis K, Kuller LH, Kraemer KL, et al. The risk of incident coronary heart disease among veterans with and without HIV and hepatitis C. *Circ Cardiovasc Qual Outcomes* 2011;4(4):425–32.
- [22] Lin MS, Guo SE, Chen MY, Huang TJ, Huang JC, Hu JH, et al. The impact of hepatitis C infection on ischemic heart disease via ischemic electrocardiogram. *Am J Med Sci* 2014;347(6):478–84.
- [23] Pothineni NV, Delongchamp R, Vallurupalli S, Ding Z, Dai Y, Hagedorn CH, et al. Impact of hepatitis C seropositivity on the risk of coronary heart disease events. *Am J Cardiol* 2014;114(12):1841–5.
- [24] Chew KW, Bhattacharya D, McGinnis K, Horwich TB, Tseng CH, Currier J, et al. Coronary heart disease risk by Framingham risk score in hepatitis C and HIV/hepatitis C coinfecting persons. *AIDS Res Hum Retroviruses* 2015;31:718–22.
- [25] Lee MH, Yang HI, Wang CH, Jen CL, Yeh SH, Liu CJ, et al. Hepatitis C virus infection and increased risk of cerebrovascular disease. *Stroke* 2010;41(12):2894–900.
- [26] Hsu YH, Muo CH, Liu CY, Tsai WC, Hsu CC, Sung FC, et al. Hepatitis C virus infection increases the risk of developing peripheral arterial disease: a 9-year population-based cohort study. *J Hepatol* 2015;62(3):519–25.
- [27] Khot UN, Khot MB, Bajzer CT, Sapp SK, Ohman EM, Brenner SJ, et al. Prevalence of conventional risk factors in patients with coronary heart disease. *JAMA* 2003;290(7):898–904.
- [28] Bielinski SJ, Berardi C, Decker PA, Kirsch PS, Larson NB, Pankow JS, et al. P-selectin and subclinical and clinical atherosclerosis:

- the Multi-Ethnic Study of Atherosclerosis (MESA). *Atherosclerosis* 2015;240(1):3–9.
- [29] Fletcher NF, Wilson GK, Murray J, Hu K, Lewis A, Reynolds GM, et al. Hepatitis C virus infects the endothelial cells of the blood–brain barrier. *Gastroenterology* 2012;142(3):634–43.
- [30] Roed T, Kristoffersen US, Knudsen A, Wiinberg N, Lebech AM, Almdal T, et al. Increased prevalence of coronary artery disease risk markers in patients with chronic hepatitis C—a cross-sectional study. *Vasc Health Risk Manag* 2014;10:55–62.
- [31] Ferroni P, Mammarella A, Martini F, Paoletti V, Cardareello CM, Labbadia G, et al. Increased soluble P-selectin levels in hepatitis C virus-related chronic hepatitis: correlation with viral load. *J Investig Med* 2001;49(5):407–12.
- [32] Satoh K, Nagano T, Seki N, Tomita Y, Aida Y, Sugita T, et al. High level of serum cholesteryl ester transfer protein in active hepatitis C virus infection. *World J Hepatol* 2016;8(5):291–300.
- [33] Barter PJ, Rye KA. Cholesteryl ester transfer protein inhibition is not yet dead-pro. *Arterioscler Thromb Vasc Biol* 2016;36(3):439–41.
- [34] Nicholls SJ, Ruotolo G, Brewer HB, Wang MD, Liu L, Willey MB, et al. Evacetrapib alone or in combination with statins lowers lipoprotein(a) and total and small LDL particle concentrations in mildly hypercholesterolemic patients. *J Clin Lipidol* 2016;10(3):519–27.
- [35] McLain JH, Alsterda AJ, Arora RR. Cholesteryl ester transfer protein inhibitors: trials and tribulations. *J Cardiovasc Pharmacol Ther* 2016;(August), pii:1074248416662349.
- [36] Serfaty L, Capeau J. Hepatitis C, insulin resistance and diabetes: clinical and pathogenic data. *Liver Int* 2009;29(Suppl 2):13–25.
- [37] Schnier C, Wild S, Kurdi Z, Povey C, Goldberg DJ, Hutchinson SJ. Matched population-based study examining the risk of type 2 diabetes in people with and without diagnosed hepatitis C virus infection. *J Viral Hepat* 2016;23:596–605.
- [38] Petta S, Maida M, Macaluso FS, Barbara M, Licata A, Craxi A, et al. Hepatitis C virus infection is associated with increased cardiovascular mortality: a meta-analysis of observational studies. *Gastroenterology* 2016;150(1):145–55.
- [39] Jung HJ, Kim YS, Kim SG, Lee YN, Jeong SW, Jang JY, et al. The impact of pegylated interferon and ribavirin combination treatment on lipid metabolism and insulin resistance in chronic hepatitis C patients. *Clin Mol Hepatol* 2014;20(1):38–46.
- [40] Economou EK, Oikonomou E, Siasos G, Papageorgiou N, Tsalamandris S, Mourouzis K, et al. The role of microRNAs in coronary artery disease: from pathophysiology to diagnosis and treatment. *Atherosclerosis* 2015;241(2):624–33.
- [41] Lee CH, Kim JH, Lee SW. The role of microRNAs in hepatitis C virus replication and related liver diseases. *J Microbiol* 2014;52(6):445–51.
- [42] Willeit P, Skrobilin P, Kiechl S, Fernandez-Hernando C, Mayr M. Liver microRNAs: potential mediators and biomarkers for metabolic and cardiovascular disease? *Eur Heart J* 2016.
- [43] Zhou L, Irani S, Sirwi A, Hussain MM. MicroRNAs regulating apolipoprotein B-containing lipoprotein production. *Biochim Biophys Acta* 2016.
- [44] van der Meer AJ, Farid WR, Sonneveld MJ, de Ruiter PE, Boonstra A, van Vuuren AJ, et al. Sensitive detection of hepatocellular injury in chronic hepatitis C patients with circulating hepatocyte-derived microRNA-122. *J Viral Hepat* 2013;20(3):158–66.
- [45] van der Ree MH, van der Meer AJ, van Nuenen AC, de Bruijne J, Ottosen S, Janssen HL, et al. Miravirsin dosing in chronic hepatitis C patients results in decreased microRNA-122 levels without affecting other microRNAs in plasma. *Aliment Pharmacol Ther* 2016;43(1):102–13.
- [46] Tsiantoulas D, Diehl CJ, Witztum JL, Binder CJ. B cells and humoral immunity in atherosclerosis. *Circ Res* 2014;114(11):1743–56.
- [47] Lopes-Virella MF, Virella G. Pathogenic role of modified LDL antibodies and immune complexes in atherosclerosis. *J Atheroscler Thromb* 2013;20(10):743–54.
- [48] Toubi E, Gordon S, Kessel A, Rosner I, Rozenbaum M, Shoenfeld Y, et al. Elevated serum B-lymphocyte activating factor (BAFF) in chronic hepatitis C virus infection: association with autoimmunity. *J Autoimmun* 2006;27(2):134–9.
- [49] Sobenin IA, Salonen JT, Zhelankin AV, Melnichenko AA, Kaikkonen J, Bobryshev YV, et al. Low density lipoprotein-containing circulating immune complexes: role in atherosclerosis and diagnostic value. *Biomed Res Int* 2014;2014:205697.
- [50] Nilsson J, Bjorkbacka H, Fredrikson GN. Apolipoprotein B100 autoimmunity and atherosclerosis – disease mechanisms and therapeutic potential. *Curr Opin Lipidol* 2012;23(5):422–8.
- [51] Andre P, Komurian-Pradel F, Deforges S, Perret M, Berland JL, Sodoyer M, et al. Characterization of low- and very-low-density hepatitis C virus RNA-containing particles. *J Virol* 2002;76(14):6919–28.
- [52] Scholtes C, Ramiere C, Rainteau D, Perrin-Cocon L, Wolf C, Humbert L, et al. High plasma level of nucleocapsid-free envelope glycoprotein-positive lipoproteins in hepatitis C patients. *Hepatology* 2012;56(1):39–48.
- [53] Agnello V, Abel G. Localization of hepatitis C virus in cutaneous vasculitic lesions in patients with type II cryoglobulinemia. *Arthritis Rheum* 1997;40(11):2007–15.
- [54] Woollard KJ. Immunological aspects of atherosclerosis. *Clin Sci (Lond)* 2013;125(5):221–35.
- [55] Moore KJ, Sheedy FJ, Fisher EA. Macrophages in atherosclerosis: a dynamic balance. *Nat Rev Immunol* 2013;13(10):709–21.
- [56] Griffith RL, Virella GT, Stevenson HC, Lopes-Virella MF. Low density lipoprotein metabolism by human macrophages activated with low density lipoprotein immune complexes. A possible mechanism of foam cell formation. *J Exp Med* 1988;168(3):1041–59.
- [57] Albecka A, Belouard S, Op de Beeck A, Descamps V, Goueslain L, Bertrand-Michel J, et al. Role of low-density lipoprotein receptor in the hepatitis C virus life cycle. *Hepatology* 2012;55(4):998–1007.
- [58] Roque-Cuellar MC, Sanchez B, Garcia-Lozano JR, Garrido-Serrano A, Sayago M, Praena-Fernandez JM, et al. Expression of CD81, SR-BI and LDLR in lymphocytes and monocytes from patients with classic and occult hepatitis C virus infection. *J Med Virol* 2012;84(11):1727–36.
- [59] Harwood NM, Golden-Mason L, Cheng L, Rosen HR, Mengshol JA. HCV-infected cells and differentiation increase monocyte immunoregulatory galectin-9 production. *J Leukoc Biol* 2016;99(3):495–503.
- [60] Smith-Palmer J, Cerri K, Valentine W. Achieving sustained virologic response in hepatitis C: a systematic review of the clinical, economic and quality of life benefits. *BMC Infect Dis* 2015;15:19.
- [61] Olubamwo OO, Aregbesola AO, Miettola J, Kauhanen J, Tuomainen TP. Hepatitis C and risk of coronary atherosclerosis – a systematic review. *Public Health* 2016;138:12–25.
- [62] Manigold T, Shin EC, Mizukoshi E, Mihalik K, Murthy KK, Rice CM, et al. Foxp3+CD4+CD25+ T cells control virus-specific memory T cells in chimpanzees that recovered from hepatitis C. *Blood* 2006;107(11):4424–32.
- [63] Meissner EG, Lee YJ, Osinusi A, Sims Z, Qin J, Sturdevant D, et al. Effect of sofosbuvir and ribavirin treatment on peripheral and hepatic lipid metabolism in chronic hepatitis C virus, genotype 1-infected patients. *Hepatology* 2015;61(3):790–801.
- [64] Horl G, Froehlich H, Ferstl U, Ledinski G, Binder J, Cvirn G, et al. Simvastatin efficiently lowers small LDL-IgG immune complex levels: a therapeutic quality beyond the lipid-lowering effect. *PLOS ONE* 2016;11(2):e0148210.