

## Case Reports

**Hypertrophic Olivary Degeneration and Holmes' Tremor Secondary to Bleeding of Cavernous Malformation in the Midbrain**Djalma F. S. Menéndez<sup>1</sup>, Rubens G. Cury<sup>2</sup>, Egberto R. Barbosa<sup>2</sup>, Manoel J. Teixeira<sup>3</sup> & Erich T. Fonoff<sup>3</sup><sup>1</sup> Division of Functional Neurosurgery of the Institute of Psychiatry of the Hospital das Clínicas of the University of São Paulo, <sup>2</sup> Abnormal Movements Unit of the Hospital das Clínicas of the University of São Paulo, <sup>3</sup> Discipline of Neurosurgery of the São Paulo University Medical School**Abstract****Background:** Hypertrophic olivary degeneration (HOD) is a rare phenomenon, probably related to transsynaptic degeneration of the inferior olivary nucleus. It usually occurs as a response to primary injury of dento-rubro-olivary pathways.**Case report:** A young man developed Holmes' tremor 7 months after a cavernous malformation bleed in the midbrain. Typical findings of HOD were observed in the magnetic resonance images: bilateral and asymmetric hypertrophy of the olivary nucleus with slight hypersignal in T2-weighted images. Because of the striking disability related to drug-resistant tremor, the patient underwent stereotactic thalamotomy (nucleus ventralis intermedius of the thalamus/zona incerta) with pronounced functional improvement over time.**Discussion:** Disruption of circuits in the Guillain–Mollaret triangle classically results in palatal myoclonus, however midbrain (Holmes') tremor can also occur, as we now describe.**Keywords:** Olivary nucleus/pathology, tremor/etiology, magnetic resonance imaging, central nervous system vascular malformations, stereotaxic surgery**Citation:** Menéndez DFS, Cury RG, Barbosa ER, et al. Hypertrophic olivary degeneration and Holmes' tremor secondary to bleeding of cavernous malformation in the midbrain. Tremor Other Hyperkinet Mov. 2014; 4. doi: 10.7916/D8PG1PXT**Editor:** Elan D. Louis, Columbia University, USA**Received:** July 11, 2014 **Accepted:** August 18, 2014 **Published:** October 8, 2014**Copyright:** © 2014 Menéndez et al. This is an open-access article distributed under the terms of the Creative Commons Attribution–Noncommercial–No Derivatives License, which permits the user to copy, distribute, and transmit the work provided that the original author(s) and source are credited; that no commercial use is made of the work; and that the work is not altered or transformed.**Funding:** None.**Financial Disclosures:** None.**Conflict of Interest:** The authors report no conflict of interest.**Introduction**

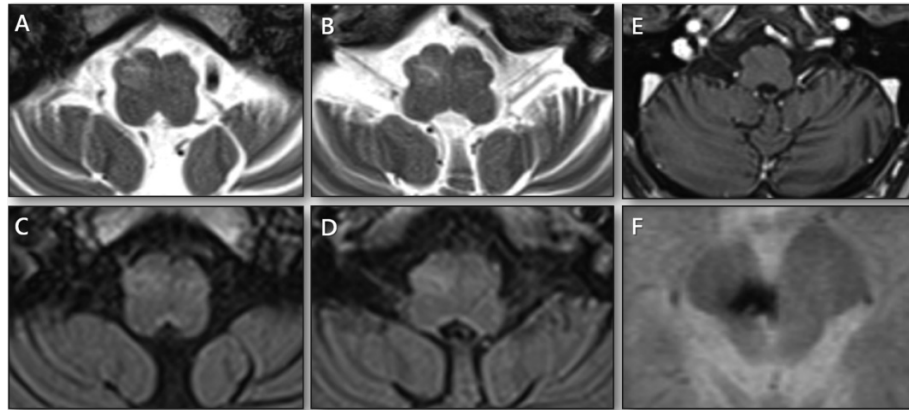
Hypertrophic olivary degeneration (HOD) is a rare form of neuronal degeneration that occurs secondary to injuries that disrupt normal function of the afferent fibers to the inferior olivary nucleus (ION) as part of the dentate-rubro-olivary pathways (triangle of Guillain–Mollaret).<sup>1</sup> The first description of HOD was published by Oppenheim in 1887, and the development of HOD was further described by Guillain and Mollaret in 1931.<sup>2,3</sup>

Insults to this pathway are commonly related to vascular disease, either infarction or hemorrhage. However, HOD may occur after head trauma, tumor, demyelinating or degenerative diseases, and after surgical manipulation.<sup>1,4</sup> HOD is best observed using magnetic resonance imaging (MRI), where it appears as an enlargement of the ION, with increased signal on T2-weighted images.<sup>5</sup>

Symptomatic palatal tremor is a well-defined movement disorder that appears after lesions involving the Guillain–Mollaret triangle and

is classically associated with HOD.<sup>2–4</sup> Although almost all cases of palatal tremor present with HOD, not all cases of HOD are accompanied by palatal tremor.<sup>6</sup> Dentato-rubral tremor, or Holmes' tremor (HT), is a different clinical entity that can be (but is infrequently) accompanied by HOD. HT is a symptomatic tremor that presents with high-amplitude and low-frequency rhythmic complex movements. It usually arises as a delayed manifestation of lesions in the upper brainstem, often related to stroke or head trauma. The Consensus Statement of the Movement Disorder Society on tremor, published in 1998, stated that both the dopaminergic nigrostriatal and the cerebellum–thalamic systems are involved in the occurrence of this type of tremor. Recently, HT associated with a brainstem lesion has been reported as a fairly rare type of tremor.<sup>7</sup>

In the present report, a patient who was diagnosed with HT after a hemorrhage in the midbrain related to a cavernous malformation showed signs of HOD on MRI scans.



**Figure 1. Four-year Follow-up Magnetic Resonance Imaging.** (A,B) serial T2-weighted and (C,D) fluid-attenuation inversion recovery (FLAIR) images showing the olivary nucleus. There is a hyperintense signal in the inferior olivary nucleus bilaterally, signal in T2 more pronounced than FLAIR, and enlargement of olives, slightly more prominent on the right, consistent with HOD. (E) T1-gadolinium image with no enhancement. (F) A rim of signal loss due to hemosiderin on gradient echo sequence, confirming a cavernous malformation on the right midbrain and prior surrounding hemorrhage.

### Case report

A 27-year-old male with a past history of chronic headache presented with a severe thunderclap headache followed by acute left-sided weakness, diplopia, right-eyelid ptosis, and moderate dysarthria. Seven months later he developed severe tremor on his left side. Initially, the tremor arose in his arm and gradually spread to his leg, with proximal involvement worse than distal involvement. Early follow-up MRI showed a rim of low signal due to hemosiderin on a gradient echo sequence without any mass effect or contrast enhancement (gadolinium), confirming a cavernous malformation in the right midbrain and evidence of prior surrounding hemorrhage. Four years after onset of the original headache, the MRI revealed asymmetric enlargement of the olivary nuclei, slightly more prominent on the right, with pronounced hyperintensity in T2 images and reduced intensity in fluid-attenuation inversion recovery (FLAIR) images consistent with HOD. No contrast enhancement (gadolinium) was observed (Figure 1).

The patient was referred to our neurosurgical unit and examination revealed a severe rest tremor that was incessant, worsened with posture, and amplified during intentional movements, with a low frequency of 4 Hz and featuring a typical clinical picture of a severe HT. Furthermore, the tremor caused severe functional impairment and prevented the patient from standing up.

Despite medical treatment with various drugs (trihexyphenidyl 6 mg/day, primidone 500 mg/day, clonazepam 6 mg/day, and propranolol 120 mg/day), the patient did not experience satisfactory tremor control. At this point, the stereotactic procedure was presented as a therapeutic option. An ablative procedure was performed in the zona incerta in the right side, including the bottom of the nucleus ventralis intermedius of the thalamus (VIM). The tremor was markedly reduced after the procedure. The previous clinical scenario of left hemiparesis, right third nerve palsy, and dysarthria were unchanged. Over 95% of the improvement in the tremor was observed directly

after the procedure. This improvement was maintained up to the latest follow-up appointment, which was around 5 years after the operation. The patient also reported a significant improvement in quality of life and social interaction. The abolition of tremor made rehabilitation possible, and the patient's posture and muscle strength improved over time. Neither palatal nor ocular tremor was observed during the last follow-up.

### Discussion

HOD is a unique transsynaptic neuronal degeneration caused by lesions in the circuit of the Guillain–Mollaret triangle. It is defined by three anatomical structures: the dentate nucleus in the cerebellum, the contralateral red nucleus at the level of the midbrain, and the contralateral ION in the medulla oblongata. The dentate nucleus afferents travel via the superior cerebellar peduncle and cross the midline towards the contralateral red nucleus. From the red nucleus, fibers descend in the central tegmental tract to enter the ION. The ION sends its afferents via climbing fibers in the inferior cerebellar peduncle to Purkinje cells of the contralateral cerebellar cortex. The Purkinje cells send their afferents to the ipsilateral dentate nucleus, thus completing the triangle. This triangular circuit exhibits bi-directional pathways between the dentate nucleus and the contralateral ION, creating a coupled feedback control system. The inferior olive tends to demonstrate a slow, rhythmic, spontaneous activity. ION deafferentation may cause hypersensitivity denervation followed by HOD.<sup>3,8,9</sup>

While transsynaptic neuronal degeneration associated with atrophy of the targeted structure is a common response to a confined lesion (e.g., atrophy of the mammillary bodies in lesions involving the fornix), such degeneration resulting in hypertrophy of the targeted region is unique to the ION.<sup>1,10</sup> Post-mortem studies reveal large neuronal cell bodies approximately 3 weeks after the causative event, with a peak in neuronal and glial growth observed at 8–9 months. Pseudohypertrophy (neuronal dissolution and gemistocytic astrocytic reaction)

follows that stage and is usually maintained for several months. Finally, the olivary nucleus atrophies more than a year after injury.<sup>3,4,9,10</sup>

HOD's hallmarks include hypertrophy of the olive with increased T2 signal intensity on MRI, which are correlated with the pathological findings. In the first 6 months following the onset of HOD, there is an increased signal on T2 with normal looking inferior olives. The second stage lasts for about 3 to 4 years and demonstrates an increased signal with evidence of olivary pseudohypertrophy. During the third stage, the atrophy follows the hypertrophy as it resolves, but persistent high-signal T2 can be observed.<sup>2,5</sup>

The differential diagnosis of signal hyperintensity on T2-weighted images within the pontomedullary region includes tumors (malignancies such as primary brainstem astrocytoma or metastasis), demyelinating lesions, infarction, and inflammatory processes (tuberculosis, sarcoidosis, or encephalitis). The lack of contrast enhancement, however, makes hypothetical malignancies and infectious disease less likely to be the cause, while the enlargement of the olivary nucleus itself weans chronic stages of infarction or multiple sclerosis. Therefore, in the setting of a T2-hyperintense non-contrast enhancing lesion, which is accompanied by enlargement of the olivary nucleus, HOD remains the sole diagnosis that explains all of the imaging findings. Identifying an inciting lesion appropriately located to interrupt the dentate-rubro-olivary tracts with the correct timing of the signal change and swelling is the key to diagnosis.<sup>1,4,10</sup>

The clinical manifestation offered by alterations in the Guillain-Mollaret triangle can be quite diverse, and still no unifying theory able to link the pathological changes and the resulting clinical picture has been postulated.<sup>3</sup> Classically, palatal tremor is the most reported neurological sign that accompanies HOD. However, the incidence of HOD after brainstem injury is unknown and the occurrence of palatal tremor with HOD is also variable.<sup>4</sup>

Unusually, other movement disorders can also occur in association with HOD, presenting as HT or ocular myoclonus. Recently, HT associated with a brainstem lesion has been reported as an extremely rare tremor, along with drug-induced tremor, orthostatic tremor, and psychogenic tremor. Furthermore, descriptions of HT associated with HOD are even scarcer.<sup>7</sup> Although lower brainstem hemorrhage is among several common causes of HOD, it has not been appreciated as a cause of midbrain ("rubral") tremor. It is most likely that dysynaptic dentate-rubro-olivary tract degeneration (associated with tremor) and the monosynaptic dentate-olivary tract (associated with HOD) are both components of the rubro-olive-cerebello-rubral loop implicated in midbrain tremors. Their functional convergence makes the combination of tremor and HOD after brainstem damage plausible and even likely.<sup>6</sup>

Pharmacological treatment of HT is usually disappointing, so stereotactic ablative procedures (thalamotomy) or deep brain stimulation are often required in refractory cases and provide encouraging results.<sup>11</sup> Many treatment methods have been tried; however, no gold standard treatments currently exist for HT.<sup>7</sup>

HOD is a unique pathological entity that occurs variably after injury to the brainstem. Specifically, injury to the dentate-rubro-olivary

pathway can result in HOD, which may be associated with palatal tremor and, less often, HT or ocular myoclonus. However, the possibility of developing HOD and its clinical sequelae is a relevant concern for clinicians and patients. Whenever changes are observed in the MRI images that suggest HOD, a simple but careful examination of the pharynx, larynx, and ocular movements should be performed. HOD after injury to any component of the triangle of Guillain-Mollaret should not be confused with neoplastic, vascular, or other primary pathological conditions of the medulla. When HOD is considered in the differential diagnosis, patients can be counseled appropriately, and treatment can be initiated.

## References

1. Gatlin JL, Wineman R, Schlakman B, et al. Hypertrophic olivary degeneration after resection of a pontine cavernous malformation: A case report. *J Radiol Case Rep* 2011;5:24–29, doi: <http://dx.doi.org/10.1186/1752-1947-5-24>.
2. Yun JH, Ahn JS, Park JC, et al. Hypertrophic olivary degeneration following surgical resection or gamma knife radiosurgery of brainstem cavernous malformations: An 11-case series and a review of literature. *Acta Neurochir (Wien)* 2013;155:469–476, doi: <http://dx.doi.org/10.1007/s00701-012-1567-y>.
3. Khojraty F, Wilson T. The dentato-rubro-olivary tract: Clinical dimension of this anatomical pathway. *Case Rep Otolaryngol* 2013;2013:934386.
4. Hornyak M, Osborn AG, Couldwell WT. Hypertrophic olivary degeneration after surgical removal of cavernous malformations of the brain stem: Report of four cases and review of the literature. *Acta Neurochir (Wien)* 2008;150:149–156, doi: <http://dx.doi.org/10.1007/s00701-007-1470-0>.
5. Goyal M, Versnick E, Tuite P, et al. Hypertrophic olivary degeneration: Metaanalysis of the temporal evolution of MR findings. *AJNR Am J Neuroradiol* 2000;21:1073–1077.
6. Shepherd GM, Tauboll E, Bakke SJ, et al. Midbrain tremor and hypertrophic olivary degeneration after pontine hemorrhage. *Mov Disord* 1997;12:432–437, doi: <http://dx.doi.org/10.1002/mds.870120327>.
7. Woo JH, Hong BY, Kim JS, et al. Holmes tremor after brainstem hemorrhage, treated with levodopa. *Ann Rehabil Med* 2013;37:591–594, doi: <http://dx.doi.org/10.5535/arm.2013.37.4.591>.
8. Shinohara Y, Kinoshita T, Kinoshita F, et al. Hypertrophic olivary degeneration after surgical resection of brain tumors. *Acta Radiol* 2013;54:462–466.
9. Conforto AB, Smid J, Marie SK, et al. Bilateral olivary hypertrophy after unilateral cerebellar infarction. *Arq Neuropsiquiatr* 2005;63:321–323, doi: <http://dx.doi.org/10.1590/S0004-282X2005000200022>.
10. Krings T, Foltys H, Meister IG, et al. Hypertrophic olivary degeneration following pontine haemorrhage: Hypertensive crisis or cavernous haemangioma bleeding? *J Neurol Neurosurg Psychiatry* 2003;74:797–799, doi: <http://dx.doi.org/10.1136/jnnp.74.6.797>.
11. Nikkha G, Prokop T, Hellwig B, et al. Deep brain stimulation of the nucleus ventralis intermedialis for Holmes (rubral) tremor and associated dystonia caused by upper brainstem lesions: Report of two cases. *J Neurosurg* 2004;100:1079–1083, doi: <http://dx.doi.org/10.3171/jns.2004.100.6.1079>.