

## Case Reports

# Long-term Effect of Sodium Oxybate (Xyrem®) in Spasmodic Dysphonia with Vocal Tremor

Kristina Simonyan<sup>1,2\*</sup> & Steven J. Frucht<sup>1</sup><sup>1</sup> Department of Neurology, Icahn School of Medicine at Mount Sinai, New York, NY, United States of America, <sup>2</sup> Department of Otolaryngology, Icahn School of Medicine at Mount Sinai, New York, NY, United States of America

## Abstract

**Background:** Symptoms of spasmodic dysphonia (SD) are usually managed successfully with botulinum toxin injections. Vocal tremor (VT), which accompanies SD, has a poor response to this treatment.**Case Report:** We report a case of a female with SD and VT who became symptom-free for 10 months after the intake of a single dose of sodium oxybate (Xyrem®). The long-term treatment effect correlated with attenuated brain activity in the key regions of dystonic brain network.**Discussion:** Our case demonstrates that the novel treatment of sodium oxybate may hold promise for SD patients, especially those who have associated VT.**Keywords:** Focal dystonia, treatment, brain modulation**Citation:** Simonyan K, Frucht SJ. Long-term effect of sodium oxybate (Xyrem®) in spasmodic dysphonia with vocal tremor. Tremor Other Hyperkinet Mov 2013; 3: <http://tremorjournal.org/article/view/206>\*To whom correspondence should be addressed. E-mail: [kristina.simonyan@mssm.edu](mailto:kristina.simonyan@mssm.edu)**Editor:** Elan D. Louis, Columbia University, United States of America**Received:** October 9, 2013 **Accepted:** November 8, 2013 **Published:** December 9, 2013**Copyright:** © 2013 Simonyan et al. This is an open-access article distributed under the terms of the Creative Commons Attribution–Noncommercial–No Derivatives License, which permits the user to copy, distribute, and transmit the work provided that the original author(s) and source are credited; that no commercial use is made of the work; and that the work is not altered or transformed.**Funding:** National Institute on Deafness and other Communication Disorders, National Institutes of Health grant R01DC012545 to K.S. ClinicalTrials.gov Identifier: NCT01961297.**Financial Disclosure:** None.**Conflict of Interest:** The authors report no conflict of interest.

## Introduction

Spasmodic dysphonia (SD), or laryngeal dystonia, is a primary focal dystonia characterized by selective loss of voluntary voice control during speaking due to uncontrolled spasms in the laryngeal muscles. Voice tremor (VT) is characterized by rhythmic alterations in pitch and loudness during vowel production and inability to sustain a vowel for more than a few seconds. Combined SD/VT is a chronic debilitating condition, which often extends beyond vocal communication impairment and causes significant occupational disability and lifelong social isolation. While symptoms of the adductor type of SD can be managed with botulinum toxin injections for an average period of 3–4 months, VT has less predictable and poor results.<sup>1–3</sup> Based on a trial-and-error approach, some patients with SD and VT receive oral medications, such as propranolol, primidone, clonazepam, and lorazepam, which typically provide only mild short-term benefits.<sup>1,4</sup>

## Case report

We report the case of a 38-year-old female with SD and VT who became symptom-free for 10 months after the intake of a single dose of sodium oxybate (Xyrem®). About 1.5 years prior to her visit with us,

she developed a strained, strangled voice with a mild tremor. Voice breaks improved during singing at high pitches, laughing, and whispering. Alcohol intake improved her voice by increasing the volume and decreasing the tremor; however, symptoms returned after the effect of alcohol had worn off. She was diagnosed with adductor SD and VT 6 months after symptom onset by an experienced laryngologist based on fiberoptic nasolaryngoscopy and videostroboscopy, which revealed hyper-adduction and regular symmetrical vibration of the vocal folds. Voice and speech therapy were not beneficial. From the time of diagnosis up to the treatment with sodium oxybate, the patient has received six botulinum toxin injections bilaterally into the thyroarytenoid muscles (1.5 units/each) every 3 months, which were reportedly 90% effective for SD symptoms for a period of 8 weeks; VT symptoms remained unaffected.

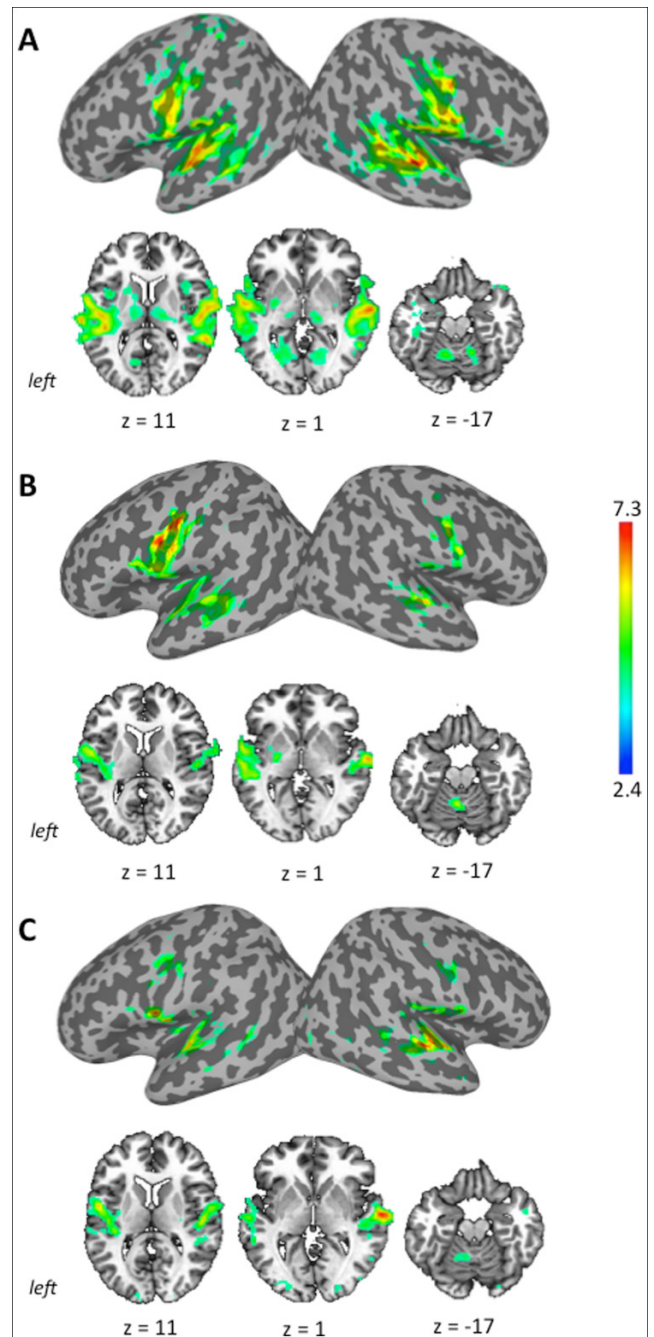
At the time of the visit, the patient was at the end of her botulinum toxin treatment cycle. Her voice was mildly tremulous with straining, strangulations, and moderate breaks on vowels. Her neurological examinations did not reveal any dystonic postures in other body parts; slight action tremor of the hands was observed. After obtaining written informed consent for drug administration and follow-up magnetic

resonance imaging (MRI), which was approved by the Institutional Review Board of Mount Sinai School of Medicine, the patient received 1.0 g of sodium oxybate (Xyrem®) by mouth in the outpatient clinic as part of an ongoing clinical research study. A clear audible improvement of her voice was observed starting 20 minutes after drug intake and was marked by an increase in the projecting volume without voice breaks or tremor. On the visual analog scale from 1 (normal) to 10 (most difficult), the patient indicated that the effort of speaking, crying, and shouting decreased from 9 to 2. Treatment-related transient dizziness improved within 60 minutes of drug intake. No adverse events, such as excessive sleepiness, depression, cardiopulmonary problems, cognitive impairment, or treatment-emergent suicidality, were observed. Five hours after drug intake, the patient was cognitively alert and stable, and her speech was not associated with voice breaks or tremor. During follow-up phone calls on the day after the visit and in the following 8 months, her voice remained without SD-characteristic breaks or tremor. Her evaluation by us at 8 months and by her laryngologist at 9 months after initial drug intake revealed no signs of dystonic posture or tremor and there was a normal laryngeal function with no evidence of adductor SD or VT. During this period, the patient did not receive any additional treatment with either botulinum toxin injections or sodium oxybate. She remained symptom-free for a total of 10 months, before recurrence of SD voice breaks following a stressful event. The patient took the second dose of 1.0 g of sodium oxybate and received benefits for 2 months. The third intake of sodium oxybate (1.0 g) improved her voice for 24 hours with some benefits lasting up to 1 week. At the time of submission of this case, the effects of the most recent drug intake (1.0 g) have lasted for over 1 month.

To examine the central effects of sodium oxybate, we performed a functional MRI (fMRI) before the initial drug intake and about 90 minutes after the first drug intake as part of the ongoing research study. Anatomical MRI was within the normal ranges without any gross abnormalities. Pre-treatment fMRI was conducted before the initial drug intake when the patient’s voice was fully symptomatic. Sentence production showed bilaterally increased brain activity in the sensorimotor cortical regions, basal ganglia, and cerebellum (Figure 1A), which was in line with abnormal brain activity found in larger studies in SD patients.<sup>5,6</sup> Post-treatment fMRI, which was conducted 90 minutes after the drug intake when the patient had improved voice symptoms, showed significantly attenuated brain activity in the primary sensorimotor cortex (right>left), putamen, and cerebellum (Figure 1B). Because of unusually lengthy drug benefits in this patient, we re-examined the effects of the initial dose of sodium oxybate on brain activity at 8 months, when she was still asymptomatic. The brain activity during speech production remained attenuated in the basal ganglia and cerebellum with further normalization of activity in the bilateral sensorimotor cortices compared with the first post-treatment scan (Figure 1C).

**Discussion**

Our observation demonstrates that sodium oxybate significantly improved voice symptoms in an ethanol-responsive SD/VT patient.



**Figure 1. Brain Activity During Production of English Sentences Containing a Large Number of Vowels.** Before treatment with sodium oxybate (A), 90 minutes after treatment (B), and 8 months after treatment (C). Brain activity is shown on the inflated brain surfaces in the standard Talairach–Tournoux space and on the series of axial slices. The color bar represents *t* score.

Although the limitation of this report is that such a lengthy effect of sodium oxybate was observed in one patient only, another four patients (two with abductor SD and two with isolated VT) who participated in our study have reported treatment benefits lasting over 24 hours and up to 2 weeks after intake of 1.0 g of sodium oxybate. This duration of drug

benefits is much longer than typical effects of sodium oxybate on dystonia and tremor of about 3.5–4 hours.<sup>7,8</sup> In the single patient reported here, a long-term effect of sodium oxybate on SD/VT symptoms appeared to be associated with a decrease (normalization) of brain overactivity in the key regions within the dystonic brain network, possibly due to direct modulation of abnormally increased<sup>5,6</sup> brain activation during symptom production. This may be due to the ability of sodium oxybate to mediate gamma-aminobutyric acid (GABA)-B receptor activation and metabolize into GABA,<sup>9</sup> the levels of which are known to be deficient in patients with dystonia.<sup>10,11</sup> It has been suggested that GABA-ergic deficiencies in dystonia may contribute to the loss of inhibition and thus to the generation of dystonic movements.<sup>12</sup> Conversion of sodium oxybate into GABA might have directly increased GABA levels and stabilized the balance between excitation and inhibition within the sensorimotor system.

A limitation of the study is that it was designed as an open-label trial and hence the placebo effects of the drug cannot be ruled out. Although the possibility exists that a sustained voice improvement in this patient could be due to a placebo or psychogenic cause, the nature of her voice disturbance, voice recordings, time course of improvement with the drug, and correlation with imaging measures argue for a biological cause. While we did not expect to see such long-term effects in patients with SD and/or VT, this patient's experience suggests that sodium oxybate may be a promising pharmacological agent for treatment of ethanol-responsive SD and VT patients. Further study of its clinical and central effects is warranted.

### Acknowledgments

We thank Frank Macaluso, Heather Alexander, Amanda Pechman, and Melissa Choy for help with data acquisition.

### References

1. Sulica L, Louis ED. Clinical characteristics of essential voice tremor: a study of 34 cases. *Laryngoscope* 2010;120:516–528, doi: <http://dx.doi.org/10.1002/lary.20702>.

2. Gurey LE, Sinclair CF, Blitzer A. A new paradigm for the management of essential vocal tremor with botulinum toxin. *Laryngoscope* 2013;123:2497–2501.

3. Brin MF, Blitzer A, Stewart C. Laryngeal dystonia (spasmodic dysphonia): observations of 901 patients and treatment with botulinum toxin. *Adv Neurol* 1998;78:237–252.

4. Ludlow CL, Adler CH, Berke GS, et al. Research priorities in spasmodic dysphonia. *Otolaryngol Head Neck Surg* 2008;139:495–505, doi: <http://dx.doi.org/10.1016/j.otohns.2008.05.624>.

5. Simonyan K, Ludlow CL. Abnormal activation of the primary somatosensory cortex in spasmodic dysphonia: an fMRI study. *Cereb Cortex* 2010;20:2749–2759, doi: <http://dx.doi.org/10.1093/cercor/bhq023>.

6. Ali SO, Thomassen M, Schulz GM, et al. Alterations in CNS activity induced by botulinum toxin treatment in spasmodic dysphonia: an H215O PET study. *J Speech Lang Hear Res* 2006;49:1127–1146, doi: [http://dx.doi.org/10.1044/1092-4388\(2006/081\)](http://dx.doi.org/10.1044/1092-4388(2006/081)).

7. Frucht SJ, Bordelon Y, Houghton WH, Reardan D. A pilot tolerability and efficacy trial of sodium oxybate in ethanol-responsive movement disorders. *Mov Disord* 2005;20:1330–1337, doi: <http://dx.doi.org/10.1002/mds.20605>.

8. Frucht SJ, Houghton WC, Bordelon Y, Greene PE, Louis ED. A single-blind, open-label trial of sodium oxybate for myoclonus and essential tremor. *Neurology* 2005;65:1967–1969, doi: <http://dx.doi.org/10.1212/01.wnl.0000188670.38576.bd>.

9. Crunelli V, Ernri Z, Leresche N. Unravelling the brain targets of gamma-hydroxybutyric acid. *Curr Opin Pharmacol* 2006;6:44–52, doi: <http://dx.doi.org/10.1016/j.coph.2005.10.001>.

10. Levy LM, Ziemann U, Chen R, Cohen LG. Rapid modulation of GABA in sensorimotor cortex induced by acute deafferentation. *Ann Neurol* 2002;52:755–761, doi: <http://dx.doi.org/10.1002/ana.10372>.

11. Marjanska M, Lehericy S, Valabregue R, et al. Brain dynamic neurochemical changes in dystonic patients: a magnetic resonance spectroscopy study. *Movement Disord* 2013;28:201–209, doi: <http://dx.doi.org/10.1002/mds.25279>.

12. Hallett M. Neurophysiology of dystonia: the role of inhibition. *Neurobiol Dis* 2011;42:177–184, doi: <http://dx.doi.org/10.1016/j.nbd.2010.08.025>.