

Case Reports

Hairdresser's Dystonia: An Unusual Occupational Dystonia

Maurizio Giorelli^{1*} & Giovanni Bosco Zimatore¹

¹Operative Unit of Neurology, "Dimiccoli" General Hospital, ASL BT, Barletta, Italy

Abstract

Background: Adult-onset focal dystonias (AOFDs) are non-task-specific or task-specific and may spread to other body segments of affected patients.

Case report: We report the case of a barber with non-task-specific craniocervical dystonia and a new occupational focal hand dystonia (while using scissors).

Discussion: Different AOFDs may develop and coexist in the same "vulnerable" patient. Hairdresser's dystonia is a rare task-specific dystonia.

Keywords: Dystonia, task-specificity, blepharospasm, barber, scleroderma

Citation: Giorelli M, Zimatore GB. Hairdresser's dystonia: An unusual occupational dystonia. *Tremor Other Hyperkinet Mov* 2013; 3: <http://tremorjournal.org/article/view/204>

*To whom correspondence should be addressed. E-mail: mauriziogiorelli@alice.it

Editor: Elan D. Louis, Columbia University, United States of America

Received: October 7, 2013 **Accepted:** November 10, 2013 **Published:** December 4, 2013

Copyright: © 2013 Giorelli et al. This is an open-access article distributed under the terms of the Creative Commons Attribution-Noncommercial-No Derivatives License, which permits the user to copy, distribute, and transmit the work provided that the original author(s) and source are credited; that no commercial use is made of the work; and that the work is not altered or transformed.

Funding: None.

Conflict of Interest: The authors report no conflict of interest.

Financial disclosures: None.

Introduction

Dystonia is a movement disorder characterized by involuntary muscle contractions that lead to abnormal postures and/or repetitive movements.¹ Blepharospasm is characterized by involuntary spasms of the orbicularis oculi muscles and/or increased blinking; it is a manifestation of adult-onset focal dystonia (AOFD), and has a high likelihood (50% risk) of spreading beyond the orbicularis oculi over 5 years.² Focal task-specific dystonia (FTSD) and occupational cramps manifest only during the execution of a specific activity and may arise with virtually any task.³ Focal hand dystonia can occur during writing,⁴ and when playing wind instruments, string instruments, or the piano⁵ or when using the mouse of a computer.⁶ Recently, a peculiar form of dystonia was observed in a hairdresser performing a particular technique of hair cutting called "club-cutting."⁷ We describe a barber with blepharospasm who later developed occupational hand dystonia.

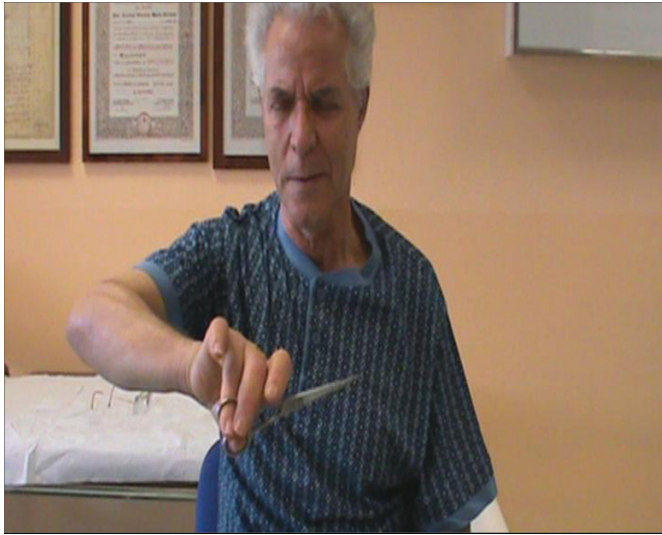Case report

A 65-year-old professional barber visited our outpatient clinic for hyperkinetic movement disorders, reporting a spasm in his right hand when using scissors professionally. He had worked as a barber since his early teens. At age 55 years, he presented with increased blinking and eye dryness, for which he was admitted to an outside hospital after a

neurological examination noted blepharospasm. Brain magnetic resonance imaging (MRI) was normal, and dopamine transporter Single Photon Emission Computed Tomography (SPECT) imaging ruled out the presence of dopaminergic denervation of the basal ganglia. The patient was discharged with the diagnosis of "blepharospasm." When the spasms of the orbicularis oculi worsened, the patient began treatment with botulinum toxin; with the third application, the treatment was suspended due to the appearance of transient iatrogenic ptosis. Five years later, Reynaud's phenomenon and swelling of the fingers of both hands appeared, and the patient underwent a panel of autoimmune tests on the advice of a rheumatologist. Blood tests revealed Anti-Nuclear Antibodies (ANA) positivity (1 × 6,400 with a finely granular pattern), and capillaroscopy displayed alterations typical of scleroderma in the cutaneous microcirculation.


Because the severity of the disease was mild, no immunosuppressive therapy was administered. One year before the patient's visit to our clinic, the patient noticed difficulty maneuvering the scissors while cutting hair. The patient reported that this difficulty was due to stiffness that began in the second and third finger of the right hand and extended along the upper arm to the shoulder.

When we examined him at rest, we observed blepharospasm, and grimacing and contraction of the platysma, which we identified as craniocervical dystonia. When the patient used scissors as he did when



Video 1. Hair cutting dystonia. The patient exhibits extension of the second and fifth finger of the right hand, spasmodic contraction of the muscles of the hand and dystonic posture of the elbow, which slows the cutting procedure. Craniocervical dystonia is present, as well.

cutting hair, we observed extension of the second finger and fifth finger of the right hand and spasmodic contraction of the muscles of the hand. The voluntary posture of the elbow was affected by dystonic contractions and maintained with some effort, thereby inhibiting the cutting procedure (Video 1). Mirror movements emerged in the left unaffected hand during this activity. The patient did not complain of any symptoms while drawing (Video 2). Similarly, no dystonic postures or movements emerged while the patient wrote or held his arms outstretched in a fixed posture in front of his chest (video not available). A neurological examination ruled out the presence of any signs of cerebellar ataxia, akinesia, rigidity or spasticity.



Video 2. Drawing. Drawing does not induce focal hand dystonia.

The patient underwent brain MRI and Fluorodeoxyglucose-Positron Emission Tomography (FDG-PET) study at rest to exclude focal inflammatory or ischemic lesions, deposition of copper, iron, or calcium, or atrophy.

Discussion

We describe a barber affected by craniocervical dystonia who developed occupational hand dystonia. His right-hand abilities were affected only when using scissors, whereas they were not compromised in all other tasks. For example, handwriting and shaving were unaffected. Similarly, a dystonic tremor emerged only while performing a specific hairdressing technique known as “club-cutting”, which was previously described in an Irish female.⁷ Task-specific hand dystonia may arise in “vulnerable” patients²⁻⁷ harboring abnormal neuronal plasticity and impaired sensorimotor processing.² The forceful repetition of specific goal-directed actions with highly skilled motor routines and intensive practice appears necessary for the development of this type of dystonia. In our case, a predisposed individual with one form of pre-existing dystonia, repetitive goal-directed actions might have led to abnormal sensory-motor integration, neuronal plasticity, and the development of a task-specific dystonia. The presentation of blepharospasm in our patient suggests the presence of facilitating neuronal circuitry on which his professional gestures might have acted to create this highly specific dystonia. To the best of our knowledge, this report is only the second case report of hairdresser's dystonia.

References

1. Fahn S, Marsden CD, Calne DB. Classification and investigation of dystonia. In: Marsden CD, Fahn S, editors. *Movement disorders* 2. London: Butterworth; 1987. p. 332–258.
2. Jinnah HA, Berardelli A, Cornelia C, et al. The focal dystonias: current views and challenges for future research. *Movement Disord* 2013;28:926–943, doi: <http://dx.doi.org/10.1002/mds.25567>.
3. Marsden CD. The focal dystonias. *Clin Neuropharmacol* 1986;9:S49–60.
4. Sheehy MP, Marsden CD. Writer's cramp—a focal dystonia. *Brain* 1982; 105:461–480, doi: <http://dx.doi.org/10.1093/brain/105.3.461>.
5. Jankovic J, Shale H. Dystonia in musicians. *Semin Neurol* 1989;9:131–135, doi: <http://dx.doi.org/10.1055/s-2008-1041316>.
6. Linssen M, Delnooz C, van de Warrenburg B. Two task-specific dystonias in one hand. *Tremor Other Hyperkinet Mov* 2013;3:166.
7. Roberts K, Mahon B, O'Rourke K, Lynch T. “Club-cutting” dystonic tremor: a case report. *Tremor Other Hyperkinet Mov* 2013;3:158.