

## Case Report

## Thalamic Deep Brain Stimulation for Orthostatic Tremor

Toby C. Yalho<sup>1</sup> & William G. Ondo<sup>1\*</sup><sup>1</sup> Parkinson's Disease Center and Movement Disorders Clinic, Department of Neurology, Baylor College of Medicine, Houston, Texas, United States of America

## Abstract

**Background:** Orthostatic tremor is an uncommon disorder manifest by high frequency, low amplitude leg tremor upon weight bearing. Treatment with oral tremor agents is inconsistent and usually not satisfactory.

**Methods:** We implanted bilateral ventralis intermedialis nuclei deep brain stimulators into an 82-year-old male with refractory orthostatic tremor.

**Results:** The patient had a marked subjective and objective improvement in leg and arm tremor, mainly manifested by an improved ability to stand.

**Discussion:** Bilateral thalamic deep brain stimulation may be considered in refractory cases of orthostatic tremor.

**Keywords:** Orthostatic tremor; deep brain stimulation; ventral intermediate nucleus of the thalamus

**Citation:** Yalho TC, Ondo WG. Thalamic deep brain stimulation for orthostatic tremor. Tremor Other Hyperkinet Mov 2011;1: <http://www.tremorjournal.org/article/view/26>

\*To whom correspondence should be addressed. E-mail: [wondo@bcm.tmc.edu](mailto:wondo@bcm.tmc.edu)

**Editor:** Elan D. Louis, Columbia University, United States of America

**Received:** April 20, 2011 **Accepted:** June 1, 2011 **Published:** August 10, 2011

**Copyright:** © 2011 Yalho and Ondo. This is an open-access article distributed under the terms of the Creative Commons Attribution–Noncommercial–No Derivatives License, which permits the user to copy, distribute, and transmit the work provided that the original author and source are credited; that no commercial use is made of the work; and that the work is not altered or transformed.

**Funding:** This research received no specific grant from any funding agency in the public, commercial, or not-for-profit sectors.

**Competing Interests:** TCY is a member of the speaker's bureau for Teva Neuroscience and a consultant for Merz Pharmaceuticals. WGO is a member of the speaker's bureau for GlaxoSmithKline, Teva Neuroscience, Boehringer Ingelheim, Allergan, Ipsen, Merz Pharmaceuticals, and Lundbeck.

## Introduction

Orthostatic tremor (OT) was described in 1984 by Heilman as tremor of the legs and trunk when standing, accompanied by unsteadiness or fear of falling, that is relieved by walking or leaning on nearby objects.<sup>1</sup> A characteristic electrophysiological finding of a 13–18 Hz leg tremor is observed while standing. Treatment response with oral medications is often unsatisfactory. We report a patient with medication-refractory OT treated successfully with bilateral ventralis intermedialis nucleus (Vim) thalamic deep brain stimulation (DBS) surgery.

## Case Report

The patient is a 78-year-old, right-handed Caucasian male who presented with a 5-year history of unsteadiness occurring within a few minutes upon standing, later associated with fine tremor of both legs, left worse than right. He would have to sit down or lean against a wall due to concern for falling. The symptoms resolved with walking or sitting. There was no improvement with alcohol. The patient reported difficulty taking a shower and he avoided social functions. His medical history included hyperlipidemia, hypertension, myocardial infarction with placement of three cardiac stents, laminectomy of cervical spine

levels 3–5, and benign prostatic hypertrophy. His brother had a head tremor of unknown duration.

Initial physical examination demonstrated a fine but visible leg tremor with a latency of approximately 1 minute after standing. He was able to stand uncomfortably but independently for a maximum of 2 minutes. Interestingly, he had a mild postural and kinetic flexion-extension hand tremor that was worse when standing and improved with sitting or walking. There was no cogwheel rigidity or evidence of orthostatic hypotension. Surface electromyography (EMG) of the gastrocnemius and vastus lateralis demonstrated a 14 Hz regular tremor consistent with the diagnosis of OT. Magnetic resonance imaging (MRI) of the brain was unremarkable, and MRI of the cervical spine showed postoperative changes from his prior laminectomy. Medications subsequently tried for his OT included clonazepam (3 mg/day), alprazolam (1.5 mg/day), gabapentin (3600 mg/day), topiramate (200 mg/day), levodopa (600 mg/day), pregabalin (225 mg/day), phenobarbital (90 mg/day), and zonisamide (100 mg/day). His symptoms progressed, and at 82 years of age he was only able to stand independently for 30–45 seconds.

Since the patient was completely refractory to medications, he underwent a bilateral Vim thalamic DBS implantation (Soletta,

**Table 1.** Surgical Treatment of Orthostatic Tremor

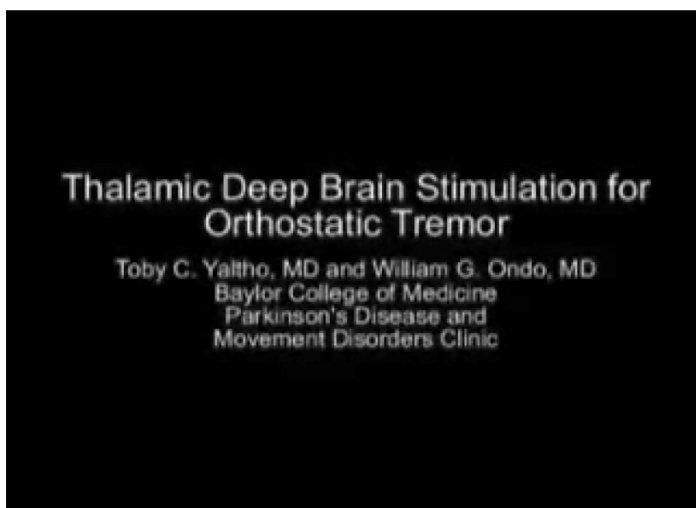
Reference	Patient	Disease Duration (Years)	Age at Surgery (Years)	Surgery	Sustained Clinical Improvement
Krauss et al. <sup>4</sup>	1	10	58	Spinal cord stimulation	Yes
	2	8	72	Spinal cord stimulation	Yes
Guridi et al. <sup>5</sup>	3	11	55	Bilateral Vim DBS	Yes
Espay et al. <sup>6</sup>	4	28	73	Bilateral Vim DBS	Yes
	5	30	67	Unilateral Vim DBS	No
Current patient	6	9	82	Bilateral Vim DBS	Yes

Medtronic, Minneapolis, Minnesota), 9 years after the onset of his symptoms. Pharmacological treatment was discontinued. At 6-months post-implantation his stimulator settings were as follows: amplitude 2.6 V, pulse width 90 us, rate 170 Hz for the right active electrode (case cathodal, contacts 0, 1, 3 anodal); amplitude 2.1 V, pulse width 90 us, rate 135 Hz for the left active electrode (case cathodal, contacts 0 and 3 anodal) after four programming sessions. The patient noted marked improvement in both his OT and hand tremor, and he was able to stand for more than 4 minutes unassisted during follow-up evaluations (Video 1).

### Discussion

OT can negatively impact quality of life,<sup>2</sup> and pharmacologic treatment response is often found to be modest and inconsistent.<sup>3</sup>

#### Video 1. Patient 4 Months Prior to DBS Implantation and 6 Months After DBS Implantation



Segment 1 of the video shows the patient 4 months prior to DBS implantation. He has a 1+ postural tremor of the hands while sitting. Shortly after standing there is a visible tremor of the legs and worsening of his postural hand tremor. The patient appears uncomfortable and has to sit down approximately 45 seconds after standing. He has improvement in his OT symptoms with walking. Segment 2 of the video shows the patient 6 months post-DBS implantation. There is significant improvement in his hand tremor while standing and the leg tremor is not visible. The patient is able to stand for several minutes without difficulty.

Surgical intervention has been tried in a small number of patients with severe OT (Table 1). Spinal cord dorsal column stimulation (SCS), typically used for treatment of medically refractory pain, was beneficial in two patients with OT,<sup>4</sup> suggesting that the spinal cord is associated with the generation or modulation of the tremor. Two patients with OT have been previously reported to benefit from bilateral Vim thalamic DBS implantation.<sup>5,6</sup> However, one patient with unilateral Vim thalamic DBS did not have sustained improvement.<sup>6</sup> Although controlled trials are not available, our case supports the consideration of bilateral thalamic DBS implantation in patients with disabling, medication refractory OT.

While the pathogenesis of OT is not known, it is widely believed to involve a primary central tremor generator and a cerebello-thalamo-cortico-spinal loop. The unique observation that our patient's hand tremor also improved with gait suggests that tremor in OT can overflow to other anatomical regions not directly stimulated by anti-gravity-induced muscle contraction and that the lower-frequency hand tremor and higher-frequency leg tremor share the same pathophysiology. Whether the presence of mild arm tremor predicts a good DBS response for OT awaits confirmation with additional cases.

### References

1. Heilman KM. Orthostatic tremor. *Arch Neurol* 1984;41(8):880–881.
2. Gerschlagner W, Katzenschlagner R, Schrag A, et al. Quality of life in patients with orthostatic tremor. *J Neurol* 2003;250(2):212–215, <http://dx.doi.org/10.1007/s00415-003-0980-9>.
3. Gerschlagner W, Munchau A, Katzenschlagner R, et al. Natural history and syndromic associations of orthostatic tremor: a review of 41 patients. *Mov Disord* 2004;19(7):788–795, <http://dx.doi.org/10.1002/mds.20132>.
4. Krauss JK, Weigel R, Blahak C, et al. Chronic spinal cord stimulation in medically intractable orthostatic tremor. *J Neurol Neurosurg Psychiatry* 2006; 77(9):1013–1016, <http://dx.doi.org/10.1136/jnnp.2005.086132>.
5. Guridi J, Rodriguez-Oroz MC, Arbizu J, et al. Successful thalamic deep brain stimulation for orthostatic tremor. *Mov Disord* 2008;23(13):1808–1811, <http://dx.doi.org/10.1002/mds.22001>.
6. Espay AJ, Duker AP, Chen R, et al. Deep brain stimulation of the ventral intermediate nucleus of the thalamus in medically refractory orthostatic tremor: preliminary observations. *Mov Disord* 2008;23(16):2357–2362, <http://dx.doi.org/10.1002/mds.22271>.