

Clinical Characterization of 66 Patients With Congenital Retinal Disease Due to the Deep-Intronic c.2991+1655A>G Mutation in *CEP290*

Dyon Valkenburg,^{1,2} Caroline van Cauwenbergh,^{3,4} Birgit Lorenz,⁵ Mies M. van Genderen,⁶ Mette Bertelsen,^{7,8} Jan-Willem R. Pott,⁹ Frauke Coppieters,⁴ Julie de Zaeytijd,³ Alberta A. H. J. Thiadens,¹⁰ Caroline C. W. Klaver,^{1,10,11} Hester Y. Kroes,¹² Mary J. van Schooneveld,¹³ Markus Preising,⁵ Carel B. Hoyng,^{1,2} Bart P. Leroy,^{3,4,14} L. Ingeborgh van den Born,¹⁵ and Rob W. J. Collin^{2,16}

¹Department of Ophthalmology, Radboud University Medical Center, Nijmegen, The Netherlands

²Radboud University Medical Center, Donders Institute for Brain, Cognition and Behavior, Cognitive Neuroscience Department, Nijmegen, The Netherlands

³Department of Ophthalmology, Ghent University and Ghent University Hospital, Ghent, Belgium

⁴Center for Medical Genetics Ghent, Ghent University and Ghent University Hospital, Ghent, Belgium

⁵Department of Ophthalmology, Giessen University Medical Center, Giessen, Germany

⁶Bartiméus Institute for the Visually Impaired, Zeist and Doorn, The Netherlands

⁷Department of Ophthalmology, Righospitalet, Glostrup, Denmark

⁸Department of Clinical Genetics, Righospitalet, Copenhagen, Denmark

⁹Department of Ophthalmology, University Medical Center Groningen, University of Groningen, Groningen, The Netherlands

¹⁰Department of Ophthalmology, Erasmus Medical Center, Rotterdam, the Netherlands

¹¹Department of Epidemiology, Erasmus Medical Center, Rotterdam, the Netherlands

¹²Department of Genetics, University Medical Center Utrecht, Utrecht, The Netherlands

¹³Department of Ophthalmology, Academic Medical Center, Amsterdam, The Netherlands

¹⁴Division of Ophthalmology & Center for Cellular & Molecular Therapeutics, The Children's Hospital of Philadelphia, Philadelphia, Pennsylvania, United States

¹⁵The Rotterdam Eye Hospital and Rotterdam Ophthalmic Institute, Rotterdam, The Netherlands

¹⁶Department of Human Genetics, Radboud University Medical Center, Nijmegen, The Netherlands

Correspondence: Rob W. J. Collin, Department of Human Genetics, Radboud University Medical Center, Philips van Leydenlaan 15, 6525 EX Nijmegen, The Netherlands; rob.collin@radboudumc.nl

Submitted: May 18, 2018

Accepted: July 26, 2018

Citation: Valkenburg D, van Cauwenbergh C, Lorenz B, et al. Clinical characterization of 66 patients with congenital retinal disease due to the deep-intronic c.2991+1655A>G mutation in *CEP290*. *Invest Ophthalmol Vis Sci*. 2018;59:4384-4391. <https://doi.org/10.1167/iovs.18-24817>

PURPOSE. To describe the phenotypic spectrum of retinal disease caused by the c.2991+1655A>G mutation in *CEP290* and to compare disease severity between homozygous and compound heterozygous patients.

METHODS. Medical records were reviewed for best-corrected visual acuity (BCVA), age of onset, funduscopy descriptions. Foveal outer nuclear layer (ONL) and ellipsoid zone (EZ) presence was assessed using spectral-domain optical coherence tomography (SD-OCT). Differences between compound heterozygous and homozygous patients were analyzed based on visual performance and visual development.

RESULTS. A total of 66 patients were included. The majority of patients had either light perception or no light perception. In the remaining group of 14 patients, median BCVA was 20/195 Snellen (0.99 LogMAR; range 0.12-1.90) for the right eye, and 20/148 Snellen (0.87 LogMAR; range 0.22-1.90) for the left. Homozygous patients tended to be more likely to develop light perception compared to more severely affected compound heterozygous patients ($P = 0.080$) and are more likely to improve from no light perception to light perception ($P = 0.022$) before the age of 6 years. OCT data were available in 12 patients, 11 of whom had retained foveal ONL and EZ integrity up to 48 years (median 23 years) of age.

CONCLUSIONS. Homozygous patients seem less severely affected compared to their compound-heterozygous peers. Improvement of visual function may occur in the early years of life, suggesting a time window for therapeutic intervention up to the approximate age of 17 years. This period may be extended by an intact foveal ONL and EZ on OCT.

Keywords: retinal dystrophy, genetic diseases, visual development, retina, low vision



Leber congenital amaurosis (LCA) is the most severe subtype of inherited retinal disease and results in severe visual impairment or blindness in the early years of adolescence, affecting children from birth. LCA has an estimated prevalence of 1 in 50,000 in Europe and North-America.^{1,2} While the disease is characterized by early visual loss, amaurotic pupils, nystagmus, and a very low or absent full-field electroretinogram,^{3,4} it is notoriously heterogeneous, both at the genotype and phenotype level, and a wide range of genetic causes can result in various degrees of disease severity.

A genetic cause may be found in up to 70% to 80% of all LCA cases,^{5,6} and of the 23 genes⁷ known to be associated with this disease, *CEP290* is most frequently mutated, with up to 30% of cases explained by pathogenic variants in this gene.⁸⁻¹⁰

The centrosomal protein 290 (*CEP290*) is a 290kDa protein located primarily in the connecting cilium between the photoreceptor inner and outer segments, and is involved in cilium formation and intracellular protein trafficking.^{11,12} Mutations in this gene are a major cause of non-syndromic Leber congenital amaurosis (LCA)^{13,14}; however, cases of retinitis pigmentosa (RP) and cone-rod dystrophy (CD) have also been described.^{15,16} The most common retinal-disease-causing variant in the *CEP290* gene is the deep-intronic c.2991+1655A>G mutation, occurring in more than half of *CEP290*-associated LCA cases.^{10,13} Interestingly, this variant leads to the inclusion of a 128-bp pseudoexon to only a proportion of *CEP290* transcripts and thus can be considered a hypomorphic variant.¹³ Mutations in *CEP290* have also been associated with systemic features, owing to the expression of this gene in other tissues, including the kidney and the brain. Consequently, non-ocular symptoms—including intellectual disability and cystic renal disease—may be present in up to 22.2% of cases,¹⁷ often as part of Joubert or Senior-Loken syndromes.¹²

Currently, no therapy exists for patients suffering *CEP290*-associated retinal disease; however, trials exploring the efficacy of antisense oligonucleotide-based genetic therapy—founded on promising preclinical studies—are being undertaken.¹⁸⁻²² Insight into the natural disease course to evaluate patient eligibility (more importantly, in determining the therapeutic effect and the optimal time window for therapeutic intervention) are vital for the further development and evaluation of these therapies. A recent study on determining the best efficacy outcome measures for clinical trials of *CEP290*-associated LCA suggested minimal change in disease progression over a period of decades, thereby supporting the impracticality of prospective natural history studies²³ and underlining the importance of proper retrospective characterization.

Relatively little is known about the natural disease course of retinal disease associated with the c.2991+1655A>G variant in *CEP290*. In a cohort of 22 *CEP290*-related patients, a recent study²³ has suggested a difference in disease severity between homozygous ($n = 4$) and compound heterozygous patients ($n = 18$) in favor of homozygous patients. The considerable size of the patient cohort in our study ($n = 66$) has enabled us to further investigate this genotype-phenotype correlation, adding to our knowledge and understanding of the phenotypic variability observed in patients carrying this deep-intronic variant.

METHODS

Patient Selection

We identified 34 patients harboring at least one c.2991+1655A>G deep-intronic variant in the *CEP290* gene

through the Dutch national retinal dystrophy database (RD5000-Consortium).²⁴ After contacting other centers in Europe with an expertise in the care for retinal dystrophy patients, we included 15 patients from the University Hospital of Giessen, Germany, 11 patients from the University Hospital of Ghent, Belgium, and 6 patients from the Righospitalet, at Kennedy Center in Glostrup, Denmark. A total of 66 patients were included in this study. Patient data from Belgium, Germany, and Denmark were reviewed and anonymized by the treating physician, and provided to the first author. Ethical approval for the study was acquired before the start of data collection, and all patients provided informed consent for the use of their medical records by the study team. This study adhered to the tenets of the Declaration of Helsinki.

Genetic Analysis

Genetic testing was performed using either the commercially available LCA mutation arrayed primer extension microarray (APEX) chip, version 2008 (Asper Biotech, Asper, Tartu, Estonia) or by direct Sanger sequencing of all 53 coding exons and exon-intron boundaries, and the deep-intronic region in intron 26 of *CEP290*. Human Genome Variation Society (HGVS) mutation nomenclature was used, with the A of the initiation codon ATG as +1.²⁵ In the Danish LCA patients, the *CEP290* c.2991+1655A>G variant was assessed by mutation hotspot screening utilizing the amplification-refractory mutation system (ARMS). Detected variants were amplified, Sanger sequenced, and finally validated with independent polymerase chain reactions (PCR).²⁶ The German cohort was analyzed using direct Sanger sequencing, APEX, and next-generation sequencing.

Clinical Analysis

Medical records of all patients were reviewed, and clinical ophthalmological data, including best-corrected visual acuity (BCVA), age at onset, electroretinography (ERG) results, and data concerning extraocular features and fundus appearance, were extracted.

Visual acuity data were obtained in decimal scale and transformed to the logarithm of the minimal angle of resolution (LogMAR). To determine inter-eye symmetry, arbitrary values for counting fingers (CF), hand movement (HM), light perception (LP) and no light perception (NLP), were used. These values were not used in analysis of baseline visual performance or spontaneous visual improvement.

When available, visual acuity data were analyzed qualitatively over time in order to determine (1) the number of patients who reached a visual acuity of LP or higher, (2) the number of patients who progressed from LP or higher to NLP and, lastly, (3) the number of patients who reportedly had NLP at baseline, and improved to LP or higher. Single-visits were excluded from this analysis, unless the visit occurred at a late age and provided unambiguous information. Additionally, multiple visits in short succession within the first year of life were regarded as a single visit and were consequently excluded from analysis.

Optical coherence tomography (OCT) images were acquired using the Heidelberg HRA Spectralis system (Heidelberg, Germany) or the Stratus OCT (Carl Zeiss Meditec, Inc., Dublin, CA, USA). We evaluated OCT-images for the presence of a structurally intact foveal outer nuclear layer (ONL) and ellipsoid zone.

Statistical Analysis

Statistical analysis was performed using SPSS version 22. Cross tabulation with the Fisher exact test was performed to

determine whether there were statistically significant differences between homozygous and compound heterozygous patients in terms of qualitative visual performance. We investigated inter-eye symmetry at the moment of highest asymmetry using Spearman's rank correlation coefficient.

RESULTS

Genetic Analysis

Our cohort consisted of 20 patients homozygous for the c.2991+1655A>G variant, and 46 compound heterozygous patients in combination with another pathogenic variant in *CEP290*. A detailed overview of all encountered variants can be found in Supplementary Table S1. One patient (10033) was not genetically tested; however, he was presumed to harbor the same compound heterozygous mutations as his sibling (10025). Eight patients carried one of the recently described hypomorphic variants¹⁵ p.(Arg151*) or p.(Lys1575*) in conjunction with the deep-intronic variant of interest. Nine novel variants were identified, only one of which is of unknown pathogenicity (p.Asn1810His).

Retinal Phenotype

Baseline clinical data on all patients are summarized in Supplementary Table S2. In general, the *CEP290*-associated retinal disease phenotype is characterized by severe visual impairment from birth (92.4%), marked hyperopia (68.1%), the presence of nystagmus (77.2%), non-recordable fERG (57.1%), sluggish or absent pupil reflexes (37.8%), and marked fundus abnormalities (87.88%). In 13 patients, extraocular features (EOF) were observed that may be related to a ciliopathy, namely, delayed psychomotor development (5; 38.46%), behavioral problems (4), mental retardation (1), nephronophthisis (1), immotile spermatozoa (1), and epilepsy (1). Five patients with EOF underwent magnetic resonance imaging (MRI), and no abnormalities (specifically cerebellar vermis hypoplasia) were detected.

The presence of nystagmus significantly complicated retinal image acquisition. OCT images were available for only 12 patients, 11 of which showed an intact foveal ONL and ellipsoid zone until the median age of 23 years (range 5–48 years), as depicted in Figure 1.

Fundus photographs were available for 14 patients, and funduscopy descriptions were available for 59 patients (a summary of the fundus appearance can be found in Supplementary Table S3). In general, the fundus appearance progressed in a similar manner, starting with a normal or blonde fundus aspect, later developing into a "salt & pepper"-like appearance with vessel attenuation and optic disc pallor, peripheral and mid-peripheral pigment alterations, and bone spicules. Three patients developed Coats-like vasculopathy, and 11 patients developed cataract (three unilateral, eight bilateral). One patient (10006) had ecstatic corneas that hampered further ophthalmic examination.

Visual Acuity

Visual performance data were available for 63 patients (125 eyes). The median baseline BCVA was 0.99 LogMAR (14 eyes, range 0.12–1.90; 20/195 [range 20/26–20/1588] Snellen) in the right, and 0.87 LogMAR (13 eyes, range 0.22–1.90; 20/148 [range 20/33–20/1588] Snellen) in the left eye. Twenty-one patients had bilateral light perception, two had CF (3 eyes), one saw hand movements only, and 25 had no perception of light.

The median age at baseline examination was 1.67 years (range, 2 months–55 years). Twenty-five out of 66 (38%) patients reportedly had no light perception at baseline examination. Follow-up time and number of examinations varied greatly among patients. The median follow-up time was 5 years (range, 0–58 years), and the median number of examinations was 4 (range, 1–37). Spearman correlation analysis was performed to determine inter-eye symmetry, and no statistically significant difference was found ($P = 0.800$). Interestingly, a total of 4 patients (10001, 10010, 10016, 10017) showed spontaneous improvement of visual performance up to the age of 17 years (median 15 years, range, 11–17 years), with a median gain of 0.25 LogMAR (range, 0.20–0.34 LogMAR), which is equivalent to 2 Early Treatment Diabetic Retinopathy Study (ETDRS) chart lines. Patient 10001 improved from 20/200 Snellen OS at age 9 to 20/125 Snellen OS at age 16. Patient 10010 improved from LP+ ODS at the age of 6.5 years, to 20/125 in both eyes at age 10; the left eye continued to improve to 20/80 at age 17 years. Patient 10016 improved from Snellen 20/200 OD and 20/125 OS at age 3.5 years, to 20/80 OD and 20/40 OS at age 11 years. Finally, patient 10017 improved from 20/100 Snellen OD at age 7 years, to 20/40 OD at age 14 years. Figure 2 summarizes the visual acuity course in these patients.

Differences in qualitative parameters for visual function between homozygous and compound heterozygous patients were investigated. Among the 18 homozygous patients with visual performance data, 17 patients (94.4%) attained light perception at some point during follow-up, compared with 28 out of 39 compound heterozygous patients (71.8%; $P = 0.080$; Fig. 3A). Of the 44 patients with LP or higher BCVA, six (1 homozygous, 5 compound heterozygous) progressed to NLP in at least one eye over a median period of 18 years (range, 1–44 years). There was no statistically significant difference between groups in this regard ($P = 0.385$; Fig. 3B).

When analyzing the improvement of no light perception to light perception, we found that 4 out of 5 homozygous patients, and 2 out of 13 compound heterozygous patients who had no light perception at baseline, improved to light perception or higher visual acuity ($P = 0.022$) over a median period of 4.9 years (range, 11 months–6 years). The remaining homozygous and the 11 compound heterozygous patients did not improve to light perception or higher VA. A summary of these results can be found in Figure 3C.

Interestingly, three patients (10016, 10017, 10057) presented with higher than usual visual acuity in the early years of life. Siblings 10016 and 10017 had a Snellen (LogMAR) visual acuity of 20/80 (0.60) in the right and 20/40 (0.30) in the left eye at 11 years, and 20/50 (0.40) in the right and 20/200 (1.00) in the left eye at the age of 14 years, respectively. Patient 10057 attained a visual acuity of 20/63 (0.50) in both eyes by the age of 11 years. Their clinical presentation was otherwise similar to other patients.

While a classical severe LCA phenotype was present in the majority of patients (64; 96.7%), two patients (10028, 10029) presented with vastly different phenotypes. Patient 10028, compound heterozygous for the c.2991+1655A>G and the c.4705-1G>T variant, had a relatively well-preserved visual acuity of 20/50 (0.40) in both eyes by the age of 15 years and a mildly flecked peripheral retina. An ERG revealed normal scotopic, and lowered photopic (25%–30%) responses. The clinical image resembled cone dystrophy.

Patient 10029, compound heterozygous for the c.2991+1655A>G and the c.5587-1G>C variant, had a relatively well-preserved visual acuity of 20/100 in the right and 20/50 in the left eye until the age of 28 years, after which the right eye slowly declined, and became legally blind at age 34. The left eye started to slowly decline by the age of 33 years

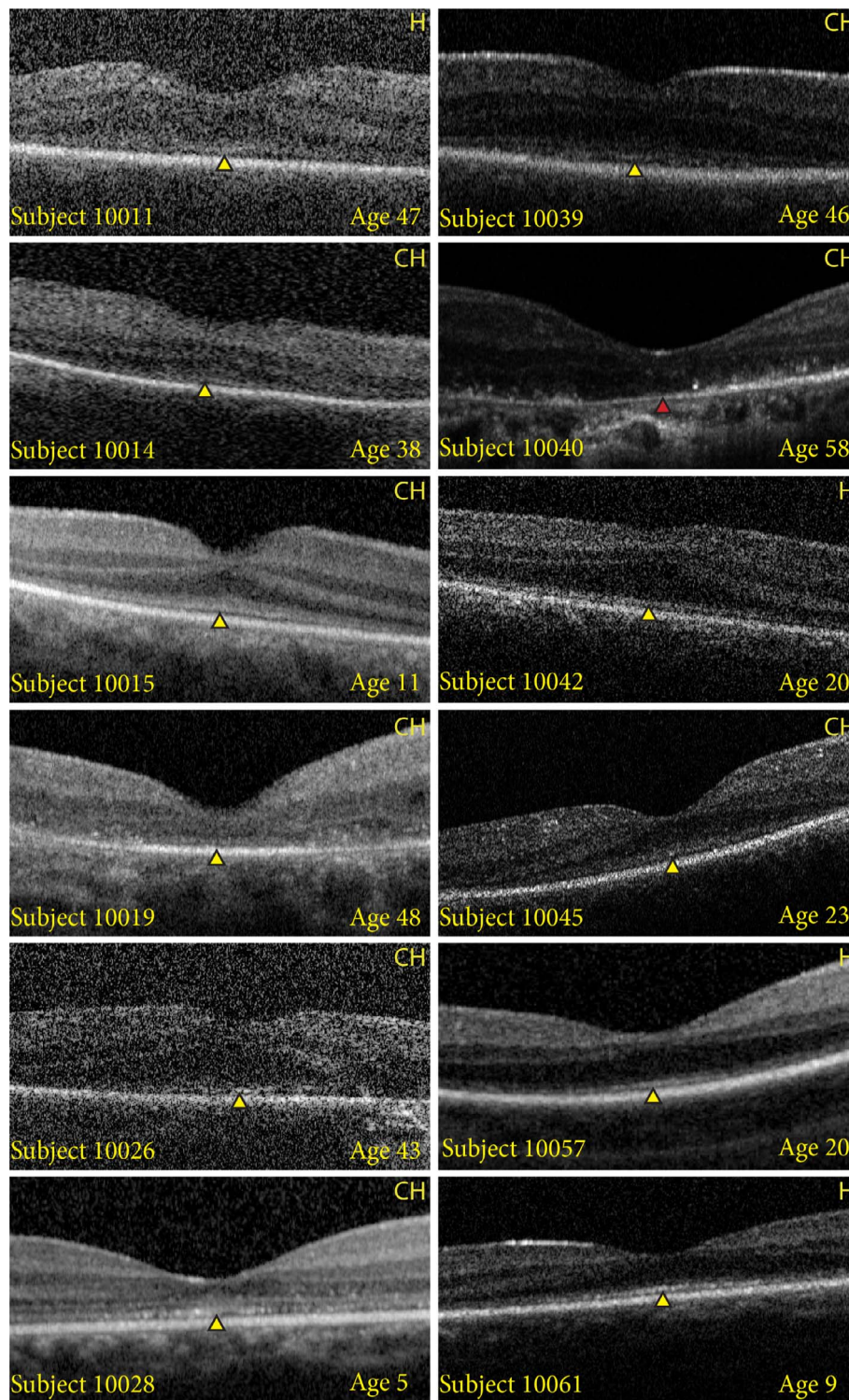


FIGURE 1. Optical coherence tomography (OCT) images of the right eyes of patients (ID indicated in the *lower left corners*, age in years in the *lower right*), showing foveal outer nuclear layer and ellipsoid zone integrity in 11 patients (*yellow triangles*). Patient 10040 was the only exception, as indicated by the *red triangle*. Zygosity is indicated in the *upper right corner*. H, homozygous; CH, compound heterozygous.

and became legally blind by the age of 41 years. The fundoscopic changes were consistent with the diagnosis of RP, with bone spicules in the peripheral retina, and Coats-like serous retinal detachment in the inferotemporal peripheral retina in both eyes. The full-field ERG showed reduced responses in both eyes.

DISCUSSION

In this study, we performed a large retrospective analysis of visual impairment in LCA patients who are either homozygous or compound heterozygous for the common deep-intronic c.2991+1655A>G mutation in *CEP290*. Evidently, despite

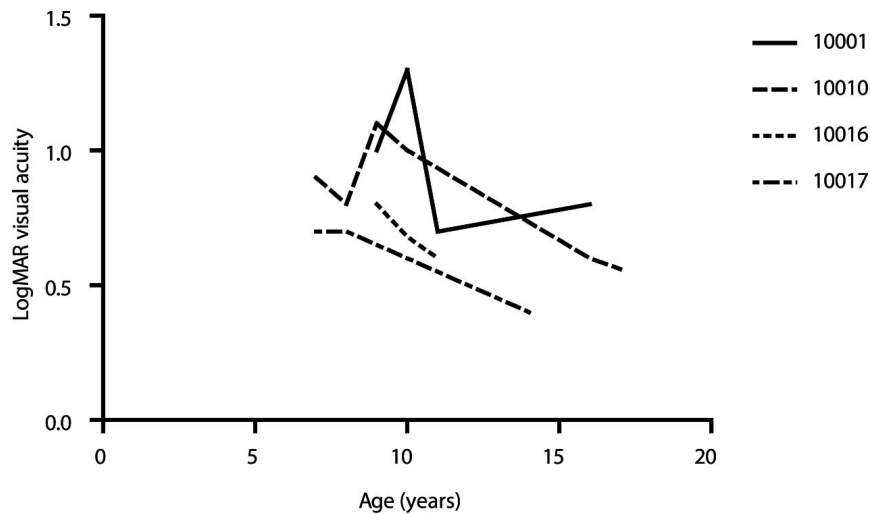


FIGURE 2. Visual acuity course in patients with spontaneous improvement. LogMAR visual acuity in four patients with spontaneous improvement. Note the variability in visual acuity in patient 10001. Lower values mean better visual acuity.

being hypomorphic, this deep-intronic mutation results in a severe retinal phenotype, affecting children from birth and rendering them legally blind at a very young age. Our data support the hypothesis suggesting homozygous patients suffer a less severe phenotype compared with compound heterozygous patients,²³ as we found more favorable visual development in homozygous patients when analyzed qualitatively. However, the difference between groups was relatively small.

Interestingly, six patients' vision seemed to have improved before the age of 6 years, while having no light perception at the time of diagnosis, suggesting the visual system may still improve even when little functional CEP290 protein is present. While an actual increase in visual acuity in these patients is up

for discussion, and visual acuity measurements are notorious for inter-visit fluctuations,²⁷ this phenomenon of transient visual improvement has also been described in RPE65-associated LCA and in CEP290.²⁸⁻³⁰ A possible explanation for this spontaneous improvement in visual performance is the physiological visual maturation, which is usually complete by the age of 5.³¹⁻³³ Alternatively, it could result from an underestimation of the initial visual function due to inadequate determination of light perception, owing to the practical limitations of examining a young child. If this is indeed the result of visual maturation, it is interesting that the period of visual improvement extends well beyond the usually expected 5 years. Additionally, 4 patients with BCVA measurable by

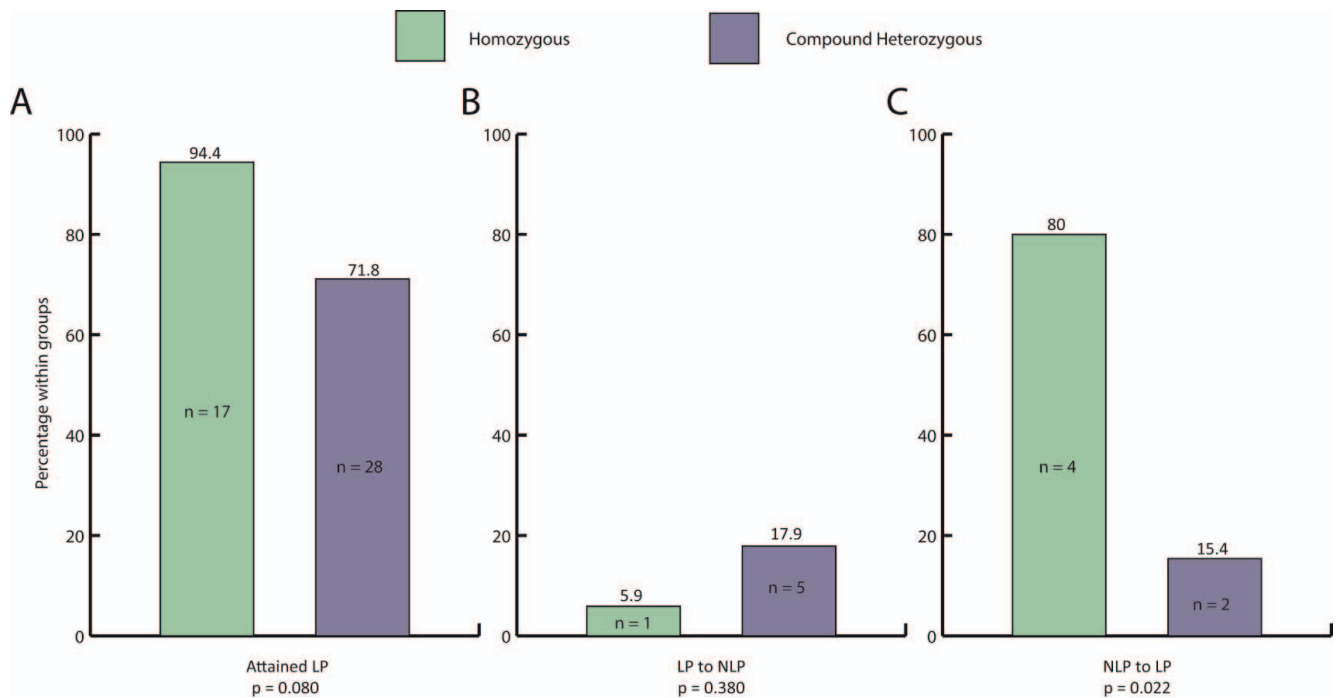


FIGURE 3. Visual outcome of homozygous compared to compound heterozygous patients. Bar graphs representing the percentage of total patients within each group. (A) shows the fraction of patients who attained “light perception or higher visual acuity” at any point during follow-up. (B) The fraction of patients who progressed from “light perception or higher visual acuity” to “no light perception,” and the fraction of patients who developed “light perception or higher visual acuity” after previously having been observed with “no light perception” (C).

ETDRS chart showed spontaneous improvement of visual performance by up to 2 to 3 ETDRS lines, up to until the age of 17 years. It is still unclear whether this is true improvement of visual function or a result of the aforementioned variability in BCVA measurements.

Differences in genetic composition, delayed visual maturation, and transient visual improvement are important features not to be ignored when designing therapeutic efficacy trials. As such, the expected therapeutic effect in compound heterozygous patients might be lower than previously assumed, and the therapeutic effect may be overestimated when tested in patients younger than 17 years. That said, treating patients in this stage might amplify the therapeutic effect, possibly providing physicians with an optimal therapeutic time window. Furthermore, while it is impossible to precisely predict an individual patients' clinical phenotype and disease course, this information should be considered when discussing a patient's prognosis.

A clinical phase 1/2 trial investigating the safety and efficacy of antisense oligonucleotide therapy has recently started,²² and an important inclusion criterion is the required presence of the macular outer nuclear layer (ONL) on OCT. It is likely that a similar criterion will be applicable for other therapeutic studies and possibly for future registered therapies. This underlines the importance of OCT in these patients, despite the presence of nystagmus that complicates the procedure. In our cohort, 11 patients had an intact foveal ONL and ellipsoid zone up to 48 years of age, in some cases even after visual acuity decreased to LP levels. Although only 12 patients successfully underwent OCT imaging, higher success rates have recently been described, as using modern-day equipment increases viability of OCT in these patients.²³ Visual acuity will probably not be a very good predictor of therapeutic efficacy, although in theory, one might expect a rise in BCVA. This is due in part to the inability to accurately determine BCVA at baseline using standard procedures such as ETDRS charts, as well as the uncertainty of their applicability even after visual improvement. Additionally, while visual acuity, visual fields, and contrast sensitivity are generally accepted measures of visual performance, a direct measure of patient mobility is lacking. To address this, multi-luminance mobility testing was developed and validated by Chung et al.³⁴ Recently, this methodology was successfully implemented in clinical gene-therapy trials in RPE65-associated retinal dystrophy.³⁵

Our relatively large study cohort enabled us to investigate the presence and nature of extraocular features associated with the CEP290-associated disease phenotype. We found extraocular features in 13 patients, bringing the prevalence in this population to roughly 1 in 5 (19.7%), which is slightly lower than the 22.2% previously reported in literature.¹⁷ Six of these patients were homozygous, and 7 were compound heterozygous with known pathogenic mutations. A clear link to a certain type of second mutation could not be established, and the factors that determine whether a patient expresses extraocular features thus remain elusive. Additionally, it is unclear whether some forms of developmental delay or mental retardation may result from the severe visual impairment. While homozygous patients do tend to have a less severe retinal phenotype, the relative prevalence of extraocular features in compound heterozygous patients is slightly higher, although this difference was not statistically significant.

The c.2991+1655A>G mutation results in aberrant splicing of the CEP290 pre-mRNA, which leads to a reduction in functional CEP290 protein of about 50% in either lymphoblastoid or fibroblast cells derived from LCA patients homozygously carrying the deep-intronic mutation in CEP290.^{13,18,19,21,36} Intriguingly, Parfitt et al.²¹ found that, whereas in induced pluripotent stem cell (iPSC)-derived RPE cells, the amount of

residual correctly spliced CEP290 pre-mRNA was found to be similar to LCA fibroblasts, only 10% to 20% residual wild-type CEP290 transcript was present in iPSC-derived optic cup photoreceptors. This optic cup model is especially interesting, as it allows for observation of ciliary development in photoreceptors in a controlled setting. Cilia incidence in LCA optic cups was decreased at all stages of development compared to control cups. Furthermore, during the first weeks of optic cup development, the amount of correctly spliced CEP290 pre-mRNA is roughly equivalent to what is observed in fibroblast cells; however, the residual CEP290 transcript diminished to around 10% to 20% after a few months of differentiation. This most likely explains why patients with LCA due to the deep-intronic mutation undergo normal retinal development, sometimes with seemingly delayed visual maturation yet, sooner or later, express profound loss of photoreceptor function.

The compound heterozygous patients in our cohort (nearly) all harbored a loss-of-function mutation next to the deep-intronic variant. This additional reduction in residual full-length CEP290 protein might explain why the compound heterozygous phenotype seems to be more severe. In contrast, however, 8 patients in our cohort harbored a hypomorphic variant in conjunction with the deep-intronic variant, and this did not result in a milder phenotype in terms of visual performance. Furthermore, 2 patients (10016, 10017) with a remarkably high visual acuity were compound heterozygous for another presumed loss-of-function mutation (p.Arg151*). These results suggest that not all CEP290 mutations predicted to result in premature termination of the CEP290 protein can be considered full loss-of-function mutations. In addition, other genetic or environmental factors may modify the disease phenotype.

There are several limitations to this study. First, the retrospective nature of the study leads to differences in follow-up time and visit frequencies. Second, we included patients from different centers, and visual acuity measurement circumstances and imaging protocols varied among the centers. Lastly, imaging was available only in a subset of patients, which complicates an exhaustive analysis of the retinal structure.

In summary, the deep-intronic c.2991+1655A>G mutation in CEP290 leads to a severe form of LCA, marked by severe visual impairment from birth. Delayed visual maturation may explain why some patients, more often homozygous for the aforementioned mutation, still develop some degree of visual function in the early years of life. Transient visual improvement can occur, although this was present in a minority of patients. Visual improvement after the age of 17 was not observed, suggesting this might be an optimal time-window for therapeutic intervention. Presence of a structurally intact foveal outer nuclear layer and ellipsoid zone on OCT may be useful to select optimal therapy candidates, and every effort must be made to acquire foveal OCT images despite the presence of nystagmus.

Acknowledgments

Supported by ProQR Therapeutics, Leiden, The Netherlands; Stichting AF Deutman Oogheekunde Research Fonds (SAFDOR), Nijmegen, The Netherlands; Stichting UitZicht, Ede, The Netherlands; and Research Foundation Flanders, Brussels, Belgium. BPL is a Principal Investigator in ClinicalTrials.gov Identifier: NCT03140969, which uses an RNA antisense oligonucleotide for intravitreal injection, for which the Department of Ophthalmology at the Ghent University Hospital receives a clinical trial grant from ProQR Therapeutics. BPL does not personally benefit financially

from any of the activities related to this trial or any other research activities.

Disclosure: **D. Valkenburg**, None; **C. van Cauwenbergh**, None; **B. Lorenz**, None; **M.M. van Genderen**, None; **M. Bertelsen**, None; **J.-W.R. Pott**, None; **F. Coppiters**, None; **J. de Zaeytijd**, None; **A.A.H.J. Thiadens**, None; **C.C.W. Klaver**, None; **H.Y. Kroes**, None; **M.J. van Schooneveld**, None; **M. Preising**, None; **C.B. Hoyng**, None; **B.P. Leroy**, None; **L. Ingeborgh van den Born**, None; **R.W.J. Collin**, None

References

- Koenekoop RK. An overview of Leber congenital amaurosis: a model to understand human retinal development. *Surv Ophthalmol*. 2004;49:379-398.
- Stone EM. Leber congenital amaurosis - a model for efficient genetic testing of heterogeneous disorders: LXIV Edward Jackson Memorial Lecture. *Am J Ophthalmol*. 2007;144:791-811.
- Franceschetti A, Dieterle P. Diagnostic and prognostic importance of the electroretinogram in tapetoretinal degeneration with reduction of the visual field and hemeralopia [in French]. *Confinia neurologica*. 1954;14:184-186.
- Leber T. Über retinitis pigmentosa und angeborene amaurose [in German]. *Graefes Arch Klin Ophthalmol*. 1869;1-25.
- Kumaran N, Moore AT, Weleber RG, Michaelides M. Leber congenital amaurosis/early-onset severe retinal dystrophy: clinical features, molecular genetics and therapeutic interventions. *The Br J Ophthalmol*. 2017;101:1147-1154.
- Hancin S, Perrault I, Gerber S, et al. Leber congenital amaurosis: comprehensive survey of the genetic heterogeneity, refinement of the clinical definition, and genotype-phenotype correlations as a strategy for molecular diagnosis. *Hum Mutat*. 2004;23:306-317.
- The University of Texas Health Science Center. Genetic Causes of Retinal Dystrophies. Available at: <https://sph.uth.edu/retinet>. Accessed October 10, 2017.
- den Hollander AI, Roepman R, Koenekoop RK, Cremers FP. Leber congenital amaurosis: genes, proteins and disease mechanisms. *Prog Retin Eye Res*. 2008;27:391-419.
- Wang S, Zhang Q, Zhang X, Wang Z, Zhao P. Clinical and genetic characteristics of Leber congenital amaurosis with novel mutations in known genes based on a Chinese eastern coast Han population. *Graefes Arch Clin Exp Ophthalmol*. 2016;254:2227-2238.
- Coppiters F, Casteels I, Meire F, et al. Genetic screening of LCA in Belgium: predominance of CEP290 and identification of potential modifier alleles in AHI1 of CEP290-related phenotypes. *Hum Mutat*. 2010;31:E1709-E1766.
- Chang B, Khanna H, Hawes N, et al. In-frame deletion in a novel centrosomal/ciliary protein CEP290/NPHP6 perturbs its interaction with RPGR and results in early-onset retinal degeneration in the rd16 mouse. *Hum Mol Genet*. 2006;15:1847-1857.
- Drivas TG, Holzbaur EL, Bennett J. Disruption of CEP290 microtubule/membrane-binding domains causes retinal degeneration. *J Clin Invest*. 2013;123:4525-4539.
- den Hollander AI, Koenekoop RK, Yzer S, et al. Mutations in the CEP290 (NPHP6) gene are a frequent cause of Leber congenital amaurosis. *Am J Hum Genet*. 2006;79:556-561.
- Coppiters F, Lefever S, Leroy BP, De Baere E. CEP290, a gene with many faces: mutation overview and presentation of CEP290base. *Hum Mutat*. 2010;31:1097-1108.
- Roosing S, Cremers FPM, Riemsdag FCC, et al. A rare form of retinal dystrophy caused by hypomorphic nonsense mutations in CEP290. *Genes (Basel)*. 2017;8:E208.
- Littink KW, Pott JW, Collin RW, et al. A novel nonsense mutation in CEP290 induces exon skipping and leads to a relatively mild retinal phenotype. *Invest Ophthalmol Vis Sci*. 2010;51:3646-3652.
- Yzer S, Hollander AI, Lopez I, et al. Ocular and extra-ocular features of patients with Leber congenital amaurosis and mutations in CEP290. *Mol Vis*. 2012;18:412-425.
- Collin RW, den Hollander AI, van der Velde-Visser SD, Bennicelli J, Bennett J, Cremers FP. Antisense oligonucleotide (AON)-based therapy for Leber congenital amaurosis caused by a frequent mutation in CEP290. *Mol Ther Nucleic Acids*. 2012;1:e14.
- Garanto A, Chung DC, Duijkers L, et al. In vitro and in vivo rescue of aberrant splicing in CEP290-associated LCA by antisense oligonucleotide delivery. *Hum Mol Genet*. 2016;25:2552-2563.
- Gerard X, Perrault I, Hancin S, et al. AON-mediated exon skipping restores ciliation in fibroblasts harboring the common Leber congenital amaurosis CEP290 mutation. *Mol Ther Nucleic Acids*. 2012;1:e29.
- Parfitt DA, Lane A, Ramsden CM, et al. Identification and correction of mechanisms underlying inherited blindness in human iPSC-derived optic cups. *Cell Stem Cell*. 2016;18:769-781.
- Study to evaluate QR-110 in subjects with Leber's congenital amaurosis (LCA) due to the c.2991+1655A>G mutation (p.Cys998X) in the CEP290 gene. Available at: <https://clinicaltrials.gov/ct2/show/NCT03140969?term=cep290&rank=2>. Accessed October 24, 2017.
- Jacobson SG, Cideciyan AV, Sumaroka A, et al. Outcome measures for clinical trials of Leber congenital amaurosis caused by the intronic mutation in the CEP290 gene. *Invest Ophthalmol Vis Sci*. 2017;58:2609-2622.
- van Huet RAC, Oomen CJ, Plomp AS, et al. The RD5000 database: facilitating clinical, genetic, and therapeutic studies on inherited retinal diseases. *Invest Ophthalmol Vis Sci*. 2014;55:7355-7360.
- den Dunnen JT, Antonarakis SE. Mutation nomenclature extensions and suggestions to describe complex mutations: a discussion. *Hum Mutat*. 2000;15:7-12.
- Astuti GD, Bertelsen M, Preising MN, et al. Comprehensive genotyping reveals RPE65 as the most frequently mutated gene in Leber congenital amaurosis in Denmark. *Eur J Hum Genet*. 2016;24:1071-1079.
- Roman AJ, Cideciyan AV, Schwartz SB, Olivares MB, Heon E, Jacobson SG. Intervisit variability of visual parameters in Leber congenital amaurosis caused by RPE65 mutations. *Invest Ophthalmol Vis Sci*. 2013;54:1378-1383.
- Paunescu K, Wabbel B, Preising MN, Lorenz B. Longitudinal and cross-sectional study of patients with early-onset severe retinal dystrophy associated with RPE65 mutations. *Graefes Arch Clin Exp Ophthalmol*. 2005;243:417-426.
- Perrault I, Rozet JM, Ghazi I, et al. Different functional outcome of RetGCI and RPE65 gene mutations in Leber congenital amaurosis. *Am J Hum Genet*. 1999;64:1225-1228.
- McAnany JJ, Genead MA, Walia S, et al. Visual acuity changes in patients with Leber congenital amaurosis and mutations in CEP290. *JAMA Ophthalmol* 2013;131:178-182.
- Daw NW. Critical periods and strabismus: what questions remain? *Optom Vis Sci*. 1997;74:690-694.
- Leat SJ, Yadav NK, Irving EL. Development of visual acuity and contrast sensitivity in children. *J Optom*. 2009;2:19-26.
- Lewis TL, Maurer D. Multiple sensitive periods in human visual development: evidence from visually deprived children. *Dev Psychobiol*. 2005;46:163-183.

34. Chung DC, McCague S, Yu ZF, et al. Novel mobility test to assess functional vision in patients with inherited retinal dystrophies. *Clin Exp Ophthalmol*. 2018;46:247-259.
35. Russell S, Bennett J, Wellman JA, et al. Efficacy and safety of voretigene neparvovec (AAV2-hRPE65v2) in patients with RPE65-mediated inherited retinal dystrophy: a randomised, controlled, open-label, phase 3 trial. *Lancet*. 2017;390:849-860.
36. Gerard X, Garanto A, Rozet JM, Collin RW. Antisense Oligonucleotide therapy for inherited retinal dystrophies. *Adv Exp Med Biol*. 2016;854:517-524.