



<b>Title</b>	Impaction of swallowed dentures in the sigmoid colon requiring sigmoid colectomy
<b>Author(s)</b>	Flanagan, Michael; Clancy, Cillian; O'Riordain, Micheal G.
<b>Publication date</b>	2018
<b>Original citation</b>	Flanagan, M., Clancy, C. and O'Riordain, M. G. (2018) 'Impaction of swallowed dentures in the sigmoid colon requiring sigmoid colectomy', International Journal of Surgery Case Reports, 47, pp. 89-91. doi: 10.1016/j.ijscr.2018.04.033
<b>Type of publication</b>	Article (peer-reviewed)
<b>Link to publisher's version</b>	<a href="https://www.sciencedirect.com/science/article/pii/S2210261218301597">https://www.sciencedirect.com/science/article/pii/S2210261218301597</a> <a href="http://dx.doi.org/10.1016/j.ijscr.2018.04.033">http://dx.doi.org/10.1016/j.ijscr.2018.04.033</a> Access to the full text of the published version may require a subscription.
<b>Rights</b>	© 2018, Published by Elsevier Ltd on behalf of IJS Publishing Group Ltd. This is an open access article under the CC BY-NC-ND license ( <a href="http://creativecommons.org/licenses/by-nc-nd/4.0/">http://creativecommons.org/licenses/by-nc-nd/4.0/</a> ).
<b>Item downloaded from</b>	<a href="http://hdl.handle.net/10468/6876">http://hdl.handle.net/10468/6876</a>

Downloaded on 2018-09-30T19:28:30Z



Contents lists available at ScienceDirect

## International Journal of Surgery Case Reports

journal homepage: [www.casereports.com](http://www.casereports.com)

# Impaction of swallowed dentures in the sigmoid colon requiring sigmoid colectomy

Michael Flanagan\*, Cillian Clancy, Micheal G. O Riordain

Department of Colorectal Surgery, Mercy University Hospital, Cork, Ireland

## ARTICLE INFO

### Article history:

Received 11 February 2018  
Received in revised form 17 April 2018  
Accepted 29 April 2018  
Available online 7 May 2018

### Keywords:

Case report  
Foreign body  
Dental plate  
Sigmoid colectomy

## ABSTRACT

**INTRODUCTION:** Foreign body (FB) ingestion results in perforation in 1% of cases and is associated with significant morbidity and rarely mortality. Clinical presentation is variable and can present a diagnostic challenge. We report our experience and management of a patient with a delayed presentation of a sigmoid colon foreign body as a result of ingestion of a dental plate.

**PRESENTATION OF CASE:** A 67 year old female attended the colorectal outpatient clinic following an incidental finding of a sigmoid mass on computed tomography (CT) abdomen. Further investigation identified a dental plate impacted in a thickened sigmoid colon. On further questioning the patient recalled losing her dentures three years previously. At surgery the dental plate had partially eroded through the sigmoid colon into the pelvic side wall. A sigmoid colectomy and hand sewn end-to-end colo-colic anastomosis was performed.

**DISCUSSION:** Localised perforation following ingestion of a foreign body may result in significant morbidity. Extra luminal migration and local inflammatory response resulted in the formation of a walled off collection. Delayed complications of perforation include abscess and fistula formation.

**CONCLUSION:** Clinicians need to exhibit a high index of suspicion when treating edentulous patients and alcohol and drug abusers who present with an acute abdomen or a sub-acute presentation with associated atypical imaging and endoscopic findings. The decision regarding intervention and management strategy in cases of perforation by foreign body depends on chronicity of the case, extent of localised or diffuse peritonitis, and size of the lesion or area of bowel involved.

© 2018 Published by Elsevier Ltd on behalf of IJS Publishing Group Ltd. This is an open access article under the CC BY-NC-ND license (<http://creativecommons.org/licenses/by-nc-nd/4.0/>).

## 1. Introduction

The majority of ingested foreign bodies (FB) pass through the gastro-intestinal tract spontaneously with 20% becoming impacted at varying levels of transit [1,2] and 1% resulting in complications of intestinal perforation [3]. FB impaction is most likely to occur at narrow, angled or pouching zones with the most common site of perforation being the ileocaecal and rectosigmoid regions as well as at sites of surgical anastomoses, adhesions and diverticula [4].

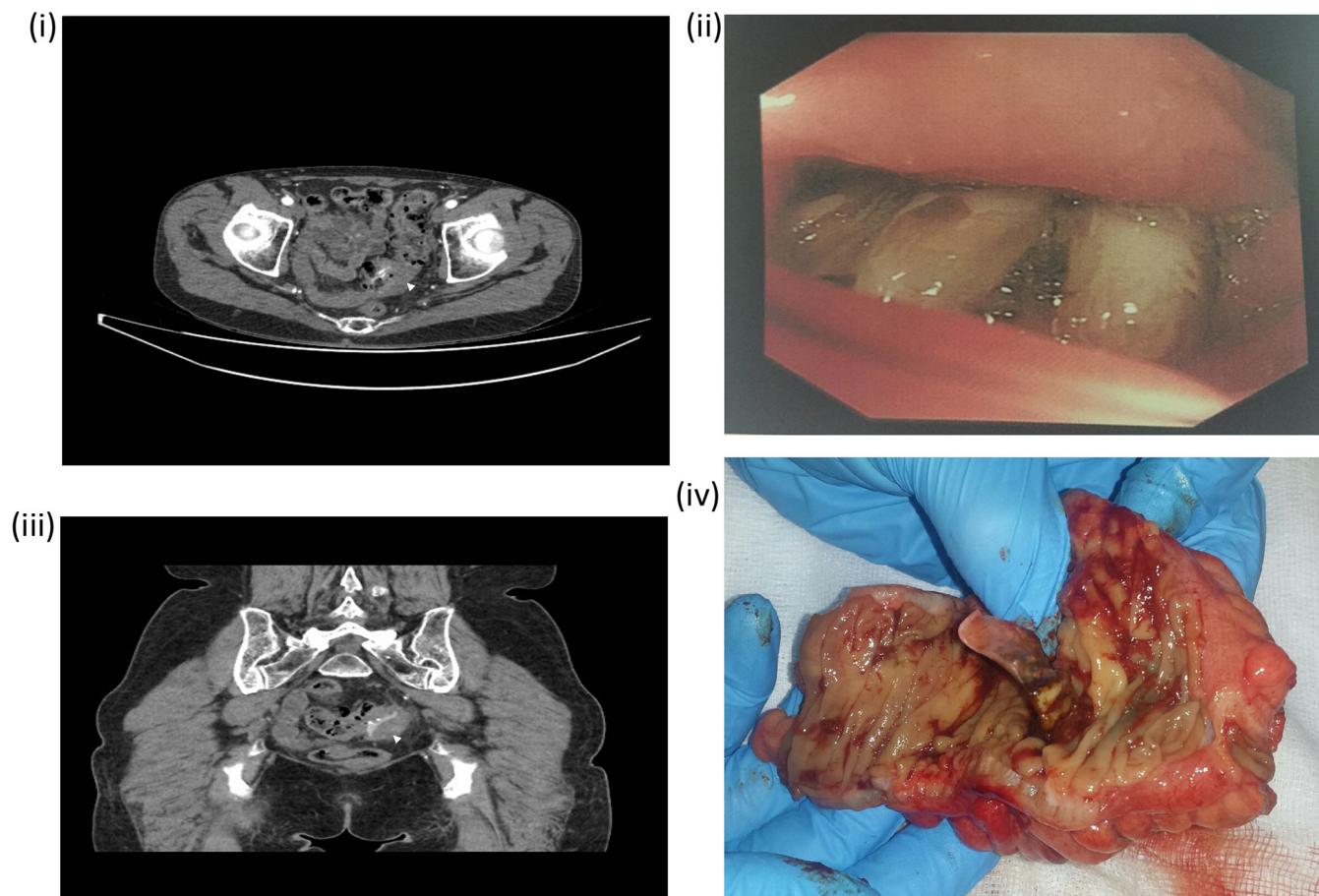
We report a rare case of an elderly female patient who presented with generalized abdominal pain three years after ingestion of a dental plate. At laparotomy, thickened sigmoid colon with a small localised perforation containing a foreign body lodged in the pelvic side wall was identified as a partial dental plate perforating through sigmoid colon. This work has been reported in line with SCARE criteria [5].

## 2. Case

A 67 year old white female with a history of peripheral vascular disease, dyslipidaemia and chronic obstructive pulmonary disease, was referred to a vascular service for investigation of symptoms of intermittent claudication and reduced right sided lower limb pulses. The patient also reported symptoms of abdominal cramping associated with defecation and passing occasional small volumes of fresh blood per rectum. She did not report weight loss, altered bowel habit, nausea, vomiting, abdominal pain or fevers. Computed tomography (CT) angiogram noted occlusion of the right long superficial femoral artery and an incidental finding of sigmoid diverticulosis and an irregular area of wall thickening in the sigmoid colon (Fig. 1). Colonoscopy identified sigmoid diverticulosis and a large colonic lesion at 30 cm through which the scope could not pass. Further investigation with CT colonography identified a focal area of concentric thickening of approximately 5 cm in length in an area of severe diverticular disease concerning for a neoplastic process. Repeat colonoscopy identified an impacted foreign body at 30 cm suspicious for impacted dentures (Fig. 1). On direct questioning after the procedure the patient recalled that she had lost her dentures three years previously. Repeat CT abdomen pelvis demonstrated a partially opaque foreign body in the thick-

\* Corresponding author.

E-mail address: [michaelflanagan@rcsi.ie](mailto:michaelflanagan@rcsi.ie) (M. Flanagan).



**Fig. 1.** (i) CT angiography image of irregular wall thickening in the sigmoid colon (arrowhead). (ii) Colonoscopic image of dentures within the sigmoid colon. (iii) CT abdomen and pelvis image of radiodense sigmoid colon contents/foreign body (arrowhead). (iv) Resected thickened and locally perforated sigmoid colon containing dentures.

ened sigmoid colon consistent with impacted dentures (Fig. 1). A decision was made to resect the diseased segment of bowel containing the foreign body. At operation the dentures were found to have penetrated through the lateral wall of the sigmoid colon and were embedded in the lateral pelvic side wall. The thickened sigmoid colon was resected (Fig. 1) and a hand sewn full thickness seromuscular single layer end to end colo-colic anastomosis was performed with 3-0 PDS suture. The patient was discharged home day 4 post op. Histology of the resected specimen identified no evidence of malignancy and reactive changes only in the lymph nodes. There was no evidence of chronic inflammation or fibrosis such as foreign body granulomas. No chronic ischaemic changes were identified to suggest impaction of the foreign body in a pre-existing stricture secondary to chronic ischaemia.

The patient represented postoperative day 11 with general malaise, vomiting and fevers. Repeat CT abdomen identified a large pelvic collection at the site from which the foreign body was previously dislodged. The patient underwent re-laparotomy and washout of infected haematoma. Colonoscopy at the time of operation identified a healthy anastomosis with no air leak or methylene blue noted intra abdominally. A 27 French Robinson drain and two Shirley drains with applied irrigation and low grade suction were sited. The patient was discharged home well on readmission post-operative day 13.

### 3. Discussion

Colon perforation is most commonly the result of diverticulitis, carcinoma, obstruction or rarely trauma. FB ingestion resulting

in colonic perforation is uncommon. Most foreign bodies ingested pass through the colon unimpeded due to the solidity of large bowel effluent and its larger diameter. Colonic perforation secondary to FB impaction most commonly occurs as a result of accidental ingestion of animal bones. Denture use or use of an orthodontic appliance is a risk factor for ingestion of FB as their use reduces sensation to the palate. In a cases series of 33 patients operated on for intestinal perforation due to an ingested FB, Rodriguez-Hermosa et al. identified denture use (73% of cases) as the most common risk factor [6]. Other risk factors for accidental ingestion of FBs include advanced age, edentulous patients, alcohol abuse, intravenous drug use, intellectual disability, visual impairment, rapid ingestion or swallowing, maxillofacial trauma and general anaesthesia [7–9]. Patients are most at risk of FB ingestion while eating or drinking, during or after a fall, during sleep or when unconscious as a result of intoxication or a convulsion.

FB impaction most commonly occurs in the terminal ileum and sigmoid colon. Late complications associated with FB impaction include fistula formation, abscess, sigmoid colon perforation, and extra luminal migration. Ingested dentures resulting in perforation occur most commonly in the sigmoid colon and typically present as an acute abdomen secondary to peritonitis [10,11]. In one case mortality was attributed to denture ingestion [12]. Acute morbidity associated with perforation from ingested FB is the most common presentation, however, symptoms may present long after ingestion and in some cases the patient may be unaware of the FB ingestion. Chronic sub-acute symptoms as a result of FB perforation may lead to a delay in appropriate referral and presents a significant diagnostic challenge.

Imaging studies typically have a low diagnostic yield in cases of FB ingestion. Despite some models of orthodontic appliance incorporating metal components, dentures are fabricated most commonly with radiolucent materials such as acrylic resins, polymethyl-methacrylate and porcelain. X-ray may be informative, however, in identifying pneumoperitoneum resulting from intestinal perforation, small and large bowel dilatation or the presence of emphysema of soft tissues of the neck or pneumomediastinum in cases of oesophageal impaction and perforation. Computed tomography is sensitive for impacted acrylic dentures in the gastrointestinal tract, and will also identify air entrapment around the denture and the presence of local inflammation in the area [13].

In the case of our patient who presented following an incidental finding on imaging, with sub-acute symptoms years after ingestion of a FB, multiple investigations using endoscopic and imaging modalities were required before a definitive diagnosis was made.

We hypothesize that progressive impaction of the FB in the intestinal wall resulted in perforation into the adjacent lateral pelvis, and collection formation walled off with fibrin, omentum, and adjacent bowel loops, preventing leakage of gas or fluid into abdominal cavity.

Complications of ingested FB include intestinal haemorrhage, obstruction, hollow viscus necrosis, perforation, and fistula formation. Surgical resection at laparotomy as well as decision to perform a colostomy depends on various factors including chronicity of the ingested FB, extent of localised or diffuse peritonitis, and size of the lesion or area of bowel involved. Indications for operation in this patient included obstructive symptoms and suspicion for malignancy. We present an unusual case of an ingested dental plate manifesting as abdominal pain 3 years after ingestion requiring surgical resection. Sub-acute abdominal symptoms as a result from an ingested FB present a diagnostic challenge.

#### Conflicts of interest

None.

#### Funding

None.

#### Ethical approval

The patient described in this case report has given written consent to permit our institution to publish the details pertaining to the incident and treatment thereafter for educational benefit. For this reason ethical approval was exempted from our institution.

#### Consent

Written informed consent was obtained from the patient for publication of this case report and accompanying images. A copy

of the written consent is available for review by the Editor-in-Chief of this journal on request.

#### Author contribution

Michael F. was responsible for data collection, data analysis and writing the paper. Cillian C was responsible for study design and Michael O'R was responsible for study concept.

#### Registration of research studies

N/A.

#### Guarantor

Prof Michael O'Riordain.

#### References

- [1] W. Cheng, P.K. Tam, Foreign-body ingestion in children: experience with 1,265 cases, *J. Pediatr. Surg.* 34 (10) (1999) 1472–1476.
- [2] W.A. Webb, Management of foreign bodies of the upper gastrointestinal tract: update, *Gastrointest. Endosc.* 41 (1) (1995) 39–51.
- [3] A. Pinero Madrona, J.A. Fernandez Hernandez, M. Carrasco Prats, J. Riquelme Riquelme, P. Parrila Paricio, Intestinal perforation by foreign bodies, *Eur. J. Surg.* 166 (4) (2000) 307–309.
- [4] N.G. Velitchkov, G.I. Grigorov, J.E. Losanoff, K.T. Kjossev, Ingested foreign bodies of the gastrointestinal tract: retrospective analysis of 542 cases, *World J. Surg.* 20 (8) (1996) 1001–1005.
- [5] R.A. Agha, A.J. Fowler, A. Saeta, I. Barai, S. Rajmohan, D.P. Orgill, et al., The SCARE statement: consensus-based surgical case report guidelines, *Int. J. Surg.* 34 (2016) 180–186.
- [6] J.I. Rodriguez-Hermosa, A. Codina-Cazador, J.M. Sirvent, A. Martin, J. Girones, E. Garsot, Surgically treated perforations of the gastrointestinal tract caused by ingested foreign bodies, *Colorectal Dis.* 10 (7) (2008) 701–707.
- [7] E.D. Hodges, T.M. Durham, R.T. Stanley, Management of aspiration and swallowing incidents: a review of the literature and report of case, *ASDC J. Dent. Child.* 59 (6) (1992) 413–419.
- [8] T. Toshima, M. Morita, N. Sadanaga, R. Yoshida, K. Yoshinaga, H. Saeki, et al., Surgical removal of a denture with sharp clasps impacted in the cervicothoracic esophagus: report of three cases, *Surg. Today* 41 (9) (2011) 1275–1279.
- [9] S. Neustein, M. Beicke, Ingestion of a fixed partial denture during general anesthesia, *Anesth. Prog.* 54 (2) (2007) 50–51.
- [10] S. Khadda, A.K. Yadav, A. Ali, A. Parmar, H. Beniwal, A. Nagar, A rare case report of sigmoid colon perforation due to accidental swallowing of partial denture, *Indian J. Surg.* 77 (2) (2015) 152–154.
- [11] B. Peison, B. Benisch, E. Lim, Perforation of the sigmoid colon following ingestion of a dental plate, *N. J. Med.* 92 (7) (1995) 452–453.
- [12] A. Ghori, N.J. Dorricott, D.S. Sanders, A lethal ectopic denture: an unusual case of sigmoid perforation due to unnoticed swallowed dental plate, *J. R Coll. Surg. Edinb.* 44 (3) (1999) 203–204.
- [13] M. Gachabayov, M. Isaev, L. Orujova, E. Isaev, E. Yaskin, D. Neronov, Swallowed dentures: Two cases and a review, *Ann. Med. Surg. (Lond.)* 4 (4) (2015) 407–413.

#### Open Access

This article is published Open Access at [sciencedirect.com](https://www.sciencedirect.com). It is distributed under the [IJSCR Supplemental terms and conditions](#), which permits unrestricted non commercial use, distribution, and reproduction in any medium, provided the original authors and source are credited.