



**QUEEN'S
UNIVERSITY
BELFAST**

Epimacular Brachytherapy for Previously Treated Neovascular Age-Related Macular Degeneration (MERLOT) A Phase 3 Randomized Controlled Trial Presented in part at: Retina Day, American Academy of Ophthalmology Annual Meeting, November 2015, Las Vegas, Nevada.

Jackson, T. L., Desai, R., Simpson, A., Neffendorf, J. E., Petrarca, R., Smith, K., ... Chakravarthy, U. (2016). Epimacular Brachytherapy for Previously Treated Neovascular Age-Related Macular Degeneration (MERLOT) A Phase 3 Randomized Controlled Trial Presented in part at: Retina Day, American Academy of Ophthalmology Annual Meeting, November 2015, Las Vegas, Nevada. *Ophthalmology*, 123(6), 1287-1296. <https://doi.org/10.1016/j.ophtha.2016.02.028>

Published in:
Ophthalmology

Document Version:
Publisher's PDF, also known as Version of record

Queen's University Belfast - Research Portal:
[Link to publication record in Queen's University Belfast Research Portal](#)

Publisher rights

Copyright 2016 the authors.
This is an open access article published under a Creative Commons Attribution-NonCommercial-NoDerivs License (<https://creativecommons.org/licenses/by-nc-nd/4.0/>), which permits distribution and reproduction for non-commercial purposes, provided the author and source are cited.

General rights

Copyright for the publications made accessible via the Queen's University Belfast Research Portal is retained by the author(s) and / or other copyright owners and it is a condition of accessing these publications that users recognise and abide by the legal requirements associated with these rights.

Take down policy

The Research Portal is Queen's institutional repository that provides access to Queen's research output. Every effort has been made to ensure that content in the Research Portal does not infringe any person's rights, or applicable UK laws. If you discover content in the Research Portal that you believe breaches copyright or violates any law, please contact openaccess@qub.ac.uk.



Epimacular Brachytherapy for Previously Treated Neovascular Age-Related Macular Degeneration (MERLOT)

A Phase 3 Randomized Controlled Trial

Timothy L. Jackson, PhD, FRCOphth,^{1,2} Riti Desai, MPhil, MSc,² Andrew Simpson, MBBS, FRCOphth,^{1,2} James E. Neffendorf, MA, MBBS,^{1,2} Robert Petrarca, MD (Res), FRCOphth,^{1,2} Kelly Smith, MS,³ Janet Wittes, PhD,³ Cornelius Lewis, PhD,^{1,4} Luke Membrey, MD, FRCOphth,⁵ Richard Haynes, MD, FRCOphth,⁶ Mark Costen, FRCOphth,⁷ David H.W. Steel, FRCOphth,⁸ Alyson Muldrew, PhD,⁹ Usha Chakravarthy, PhD, FRCOphth,⁹ on behalf of the Macular Epiretinal Brachytherapy versus Ranibizumab (Lucentis) Only Treatment (MERLOT) Study Group*

Purpose: To assess the safety and efficacy of epimacular brachytherapy (EMB) for patients with chronic, active, neovascular age-related macular degeneration (AMD).

Design: Phase 3 randomized controlled trial.

Participants: Patients (n = 363) with neovascular AMD already receiving intravitreal ranibizumab injections.

Intervention: Either pars plana vitrectomy with 24-gray EMB and ongoing pro re nata (PRN) ranibizumab (n = 224) or ongoing PRN ranibizumab monotherapy (n = 119).

Main Outcome Measures: The coprimary outcomes, at 12 months, were the number of PRN ranibizumab injections and Early Treatment of Diabetic Retinopathy Study (ETDRS) best-corrected visual acuity (VA). Secondary outcomes included the proportion of participants losing fewer than 15 ETDRS letters, angiographic total lesion size, choroidal neovascularization (CNV) size, and optical coherence tomography (OCT) foveal thickness. A predefined subgroup analysis tested the influence of baseline ocular characteristics on the response to EMB.

Results: The mean number of PRN ranibizumab injections was 4.8 in the EMB arm and 4.1 in the ranibizumab monotherapy arm ($P = 0.068$). The mean VA change was -4.8 letters in the EMB arm and -0.9 letters in the ranibizumab arm (95% confidence interval of difference between groups, -6.6 to -1.8 letters). The proportion of participants losing fewer than 15 letters was 84% in the EMB arm and 92% in the ranibizumab arm ($P = 0.007$). In the EMB arm, the mean total lesion size increased by 1.2 mm^2 versus 0.4 mm^2 in the ranibizumab arm ($P = 0.27$). The CNV size decreased by 0.5 mm^2 in the EMB arm and by 1.3 mm^2 in the ranibizumab arm ($P = 0.27$). The OCT foveal thickness decreased by $1.0 \mu\text{m}$ in the EMB arm and by $15.7 \mu\text{m}$ in the ranibizumab arm ($P = 0.43$). Most subgroups favored ranibizumab monotherapy, some significantly so. One participant showed retinal vascular abnormality attributed to radiation, but otherwise safety was acceptable.

Conclusions: These results do not support the use of EMB for chronic, active, neovascular AMD. Safety is acceptable out to 12 months, but radiation retinopathy can occur later, so further follow-up is planned. *Ophthalmology* 2016;123:1287-1296 Crown Copyright © 2016 Published by Elsevier Inc. on behalf of American Academy of Ophthalmology. This is an open access article under the CC BY-NC-ND license (<http://creativecommons.org/licenses/by-nc-nd/4.0/>).



*Supplemental material is available at www.aajournal.org.

Epimacular brachytherapy (EMB) uses radiation to treat neovascular age-related macular degeneration (AMD).¹ Radiation is known to preferentially damage the proliferating vascular endothelium and fibroblastic and inflammatory cells that cause tissue damage in neovascular AMD.²⁻⁴ The EMB devices use a strontium 90 source housed in an endoscopic probe. Patients undergo a pars plana vitrectomy, and then the device is held over the AMD lesion for about 3 to 4 minutes to deliver 24 gray of β radiation. Because of the short

range of strontium β particles in tissue, neighboring structures such as the optic nerve and lens receive a dose well below the safety threshold.⁵ Therefore, EMB has the ability to deliver radiation directly to the AMD lesion, with stabilized eye position and with low off-target dosing.

The initial results with EMB were encouraging. An uncontrolled study of 34 treatment-naïve participants reported that 91% lost fewer than 15 Early Treatment of Diabetic Retinopathy (ETDRS) letters over 1 year, despite the fact that

26 required no ongoing anti-vascular endothelial growth factor (VEGF) therapy after 2 mandated induction injections of bevacizumab.¹ No cases of radiation retinopathy were reported. As a result, the Choroidal Neovascularization (CNV) Secondary to Age-Related Macular Degeneration Treated with Beta Radiation Epiretinal Therapy (CABERNET) study was established to test EMB in a phase 3 randomized controlled trial of treatment-naïve neovascular AMD.^{6,7} The study failed to replicate the early results, missing both its primary visual acuity (VA) end points.⁶

However, the CABERNET study was not designed to test whether EMB reduced the demand for anti-VEGF therapy, or whether it was suitable as a second-line treatment. Specifically, those in the EMB arm received ranibizumab at baseline then monthly pro re nata (PRN), whereas those in the ranibizumab arm received 3 consecutive monthly injections from baseline, then quarterly mandated injections with PRN dosing in the intervening months. Thus, it was not possible to determine if EMB reduces the demand for anti-VEGF therapy; moreover, the increased dosing in the control arm may well have improved the VA in that group, given that increased dosing may be associated with better visual outcomes.⁸ Therefore, it was unknown if EMB may be suitable as a second-line intervention when used as an adjunct to anti-VEGF therapy and if it reduces the demand for anti-VEGF therapy.

The Macular Epiretinal Brachytherapy in Treated Age-Related Macular Degeneration (MERITAGE) study was a multicenter phase 2 trial of 53 previously treated patients who underwent EMB. The trial suggested that EMB may reduce demand for anti-VEGF therapy with acceptable visual results out to 1 year.^{9,10} However, because this study was not controlled, it was not possible to conclude whether EMB caused the apparent reduction in anti-VEGF therapy. We therefore initiated the phase 3 Macular Epiretinal Brachytherapy versus Ranibizumab (Lucentis) Only Treatment (MERLOT) trial, which was designed to investigate whether EMB was a safe and efficacious second-line treatment for chronic, active neovascular AMD. Specifically, we aimed to test the hypothesis that EMB reduces the ongoing need for anti-VEGF therapy in those who had already commenced intravitreal injections, while maintaining a noninferior visual outcome compared with anti-VEGF monotherapy.

Methods

Study Design

The MERLOT study was an investigator-initiated, multicenter, phase 3 randomized controlled trial sponsored by a United Kingdom university hospital. Multicenter research ethics committee approval was obtained to cover all 24 sites, all participants provided written informed consent, and the study was conducted in accordance with the tenets of the Declaration of Helsinki.

Participants

The study enrolled 363 participants with chronic, active neovascular AMD who were receiving ranibizumab therapy at the time of screening. Enrollment ran from November 10, 2009, through January

30, 2012. Inclusion criteria included completion of a loading phase of 3 anti-VEGF induction injections, followed by ongoing monthly PRN therapy, with a minimum of 4 ranibizumab treatments in the previous 12 months or 2 ranibizumab treatments in the previous 6 months. Exclusion criteria included VA worse than 24 letters (20/80), prior AMD treatment other than anti-VEGF injections, subfoveal scarring, known diabetes or features suggesting diabetic retinopathy, intraocular surgery within the prior 12 weeks, and previous radiation therapy to the eye, head, or neck (Appendix 2, available at www.aaojournal.org). If both eyes were eligible, the patient could elect which eye to treat, in discussion with the clinical investigator, who should address lens status, clinical response to ranibizumab, risk factors, VA, visual potential, and other relevant factors.

Randomization and Masking

Participants were randomized in a 2:1 ratio to pars plana vitrectomy and 24-gray EMB with ongoing monthly PRN ranibizumab (n = 224) or to ongoing monthly PRN ranibizumab monotherapy (n = 119). Online electronic randomization was undertaken immediately after eligibility was confirmed by recruiting sites using a commercial system (MedSciNet, Stockholm, Sweden) and was stratified by lens status (phakic or pseudophakic) and angiographic lesion type (predominantly classic, minimally classic, or occult) as determined at the baseline visit. It was not feasible to mask surgery, but VA testing and macular imaging (which were the most commonly used criteria to necessitate ranibizumab retreatment) were undertaken by masked assessors.

Study Treatment

Epimacular brachytherapy could involve either a 20-, 23-, or 25-gauge full pars plana vitrectomy, but the EMB probe (NeoVista, Fremont, CA) was 20 gauge, and therefore, if necessary, a smaller-gauge port was enlarged to insert the probe. The EMB device houses a strontium source in a shielded handpiece (Fig 1, available at www.aaojournal.org). One end of the handpiece is connected to a remote handheld actuator by a thin actuator cable. The other end of the handpiece has a steel, 20-gauge endoprobe that is inserted into the eye after vitrectomy. The probe is positioned over the area of greatest disease activity and the actuator is depressed, causing the strontium source to leave the handpiece and travel down the probe to near the tip. The probe then is held in position for the requisite time needed to deliver 24 gray (the exact time, which is calibrated for each probe, is typically within a range from 3 to 4 minutes).

Intravitreal 0.5 mg ranibizumab (Lucentis, Novartis, Frimley, UK) was administered to participants in both study groups using a monthly PRN dosing regimen if the attending clinical investigator determined that at least 1 of the following retreatment criteria was met: a loss of more than 5 ETDRS letters from baseline attributable to active neovascular AMD; an increase of more than 50 μ m in optical coherence tomography (OCT) central retinal thickness from the lowest measurement secondary to new or increased subretinal fluid, intraretinal fluid, or subretinal pigment epithelial fluid; new or increased subretinal or intraretinal blood; and new neovascularization as confirmed by fluorescein angiography (FA).

Study Examinations, Optical Coherence Tomography, and Fluorescein Angiography

Participants attended monthly visits with protocol refraction and testing of best-corrected VA (BCVA) using the ETDRS chart and methodology, ocular examination, and OCT. Three sites used time-domain OCT, 14 sites used spectral-domain OCT, and 7 sites used a mixture of both over the course of the study. Fundus photography

and FA images were obtained at baseline and month 12. All assessments were performed by masked, trial-certified staff using certified equipment. Anonymized baseline and month 12 imaging outputs (color photography, FA, and OCT) were uploaded to a central server and assigned randomly to 1 of the 3 netWORK United Kingdom reading centers (Belfast, Liverpool, and London). Graders, who were masked to site, participant details, and treatment status, undertook structured grading of the imaging outputs including angiographic lesion descriptors, area measurements, tomographic descriptors, and thickness measurements. Final grading was confirmed by a senior arbitrator (U.C.).

Efficacy Outcome Measures

The coprimary efficacy outcome measures were mean change in ETDRS BCVA over 12 months and the mean number of PRN ranibizumab retreatments per participant over 12 months. For the calculation of the mean number of PRN ranibizumab treatments, we excluded any treatments administered at the enrollment visit from the predefined primary outcome because these reflect pre-existing disease activity, but we included any injections required at the month 12 visit to provide a total of 12 possible treatments. Visual secondary efficacy outcomes were the percentage of participants losing fewer than 15 ETDRS letters, gaining 0 letters or more, and gaining 15 letters or more from enrollment to month 12. Structural secondary efficacy outcomes at month 12 were mean change in angiographic total lesion size, angiographic CNV size, and OCT foveal thickness.

Safety Outcomes

Safety outcomes included all adverse events (AEs) and serious adverse events (SAEs), coded by an independent contractor using the Medical Dictionary for Regulatory Activities (MedDRA) preferred terms. One of 2 trial ophthalmologists (T.L.J. and J.E.N.) resolved queries.

A key safety outcome was the presence of microvascular abnormalities (MVAs) that may be attributable to radiation. Graders were trained to identify MVAs of the retinal circulation and reported their presence and location with respect to the neovascular AMD lesion (in the retina overlying the lesion or in the retina outside the lesion). If MVAs were observed at any visit, these were arbitrated by the senior clinician for each reading center to confirm if they were present. All cases of MVA were subjected to a final arbitration by one of the netWORK United Kingdom clinicians (U.C.).

Subgroup Analysis

The CABERNET study suggested several baseline ocular characteristics that may influence the clinical response to EMB.¹¹ Accordingly, the MERLOT statistical analysis plan included a predefined, exploratory subgroup analysis of the coprimary outcomes based on baseline lens status (phakic or pseudophakic), BCVA (≤ 53 letters or > 53 letters), lesion type (predominantly classic, minimally classic, or occult), and lesion size (≤ 3.5 or > 3.5 optic disc areas).

Statistical Analysis

Unless otherwise specified, continuous variables are summarized using mean \pm standard deviation and categorical variables are summarized using proportions. All analyses used 2-sided tests with a type I error rate of 0.05. All analyses were prespecified in a statistical analysis plan. Those analyses that adjust for baseline lesion type considered the 5 participants whose lesions were

classified as retinal angiomatous proliferation as having occult lesions.

Calculation of Sample Size. We expected each group to have a baseline VA of 65.5 ETDRS letters with a standard deviation of 14.6 letters. We expected 8 injections in the ranibizumab monotherapy arm with a standard deviation of 4, and 6 injections in the EMB arm with a standard deviation of 3. A sample size of 330 participants (220 in the EMB arm and 110 in the ranibizumab monotherapy arm) would provide 90% power for a 5-letter non-inferiority margin for VA and more than 90% power to detect a difference of 2 injections with a 2-sided significance level of 5%. An additional 10% of participants were added, which gave a final sample size of 363. The assumptions used in these calculations are based on the results of the Prospective Optical Coherence Tomography Imaging of Patients with Neovascular AMD Treated with Intraocular Ranibizumab study.^{12,13}

Analysis of Coprimary Outcomes. The study was designed to test the hypothesis that EMB would reduce the frequency of ranibizumab retreatment that patients require while maintaining VA. Therefore, the VA coprimary outcome was tested for non-inferiority of the EMB group to the ranibizumab monotherapy group, and the ranibizumab retreatment outcome was tested for superiority. For the noninferiority outcome, a 2-sided test at the 0.05 significance level is equivalent to a 1-sided test at the 0.025 significance level. No adjustment to the type I error rate was made because rejection of the null hypothesis required both noninferior VA and fewer retreatment injections in the EMB arm.

We used an analysis of covariance model adjusted for baseline VA, lens status (phakic or pseudophakic), and lesion type (predominantly classic, minimally classic, or occult) to test whether the change in VA in the EMB group was noninferior to the change in the ranibizumab monotherapy group. To show noninferiority, the lower bound of the 95% confidence interval of the mean difference between the groups in change in VA must lie above the predetermined noninferiority margin of -5 letters. We used an analysis of covariance model adjusted for baseline lens status and lesion type to test whether the 2 groups differed in the frequency of their ranibizumab use. The analysis used the intention-to-treat population, comprising all randomized participants regardless of eligibility (inclusion or exclusion) error, postrandomization withdrawal, and whether the correct study treatments were received or other interventions were received.

Analysis of Secondary Efficacy Outcomes. The VA secondary efficacy outcomes are summarized using proportions. *P* values are from stratified Mantel-Haenszel tests adjusting for baseline lens status and lesion type. The OCT and angiographic secondary outcomes were summarized using least squares means, standard deviations were calculated from least squares standard errors ($SE \times \sqrt{n}$), and *P* values were calculated from analysis of covariance models of the outcome adjusted for the baseline of the outcome, lens status, and lesion type.

Missing Data. All analyses of VA included all 363 participants. We used multiple imputation to impute the month 12 VA measurement for the 13 participants who were missing their month 12 measurement. The ranibizumab retreatment injection analysis also included all participants. Because these injections may be more likely to occur toward the early part of the 12-month period before any potential benefit of radiation manifests, no correction was made for those participants who withdrew early. At baseline, 8 participants were missing FA data and 8 were missing OCT data. At month 12, FA images were not available for 26 eyes and OCT images were not available for 19 eyes. We did not perform any imputation for these missing data; all analyses based on the angiographic and OCT data include only participants with both baseline and month 12 measurements.

Results

Baseline Demographics

Of the 363 participants, 350 (96.4%) completed 12 months of follow-up. Participant allocation and disposal are shown in Figure 2. All participants were white. The mean age was 76.9 ± 7.2 years in the EMB arm and 75.8 ± 7.6 years in the ranibizumab monotherapy arm (combined, 76.5 ± 7.2 years; range, 56–96 years). There was a smaller proportion of men in the EMB arm (36% vs. 48%), but adding gender as a predictor in the models for the coprimary outcomes did not affect the inference. The 2 arms were well balanced with respect to baseline ocular characteristics (Table 1). Overall, the reading center determined the lesion composition at enrollment to be occult in 75%, minimally classic in 12%, predominantly classic in 12%, and retinal angiomatous proliferation in 1%. Those in the EMB arm had received a mean of 11.6 ± 5.5 anti-VEGF injections before enrollment, compared with 10.6 ± 5.0 injections in the ranibizumab arm.

Number of Ranibizumab Retreatments

The mean number of PRN ranibizumab injections in the 363 participants, from month 1 to 12 inclusive, was 4.8 ± 3.2 in the EMB arm ($n = 244$) and 4.1 ± 2.4 in the ranibizumab monotherapy arm ($n = 119$; Fig 3). Accordingly, the study failed to show superiority of EMB in terms of fewer injections. The difference between groups was not statistically significant ($P = 0.068$). The percentage of participants by number of injections is shown in Figure 4 (available at www.aaojournal.org).

Visual Acuity

The mean change in BCVA from baseline to month 12 was -4.8 ± 10.8 letters in the EMB arm ($n = 244$) and -0.9 ± 9.7 letters in the ranibizumab monotherapy arm ($n = 119$; Fig 5). The 95% confidence interval of the difference between groups was -6.6 to -1.8 letters, and so the study did not demonstrate noninferiority at the prespecified 5-letter inferiority margin;

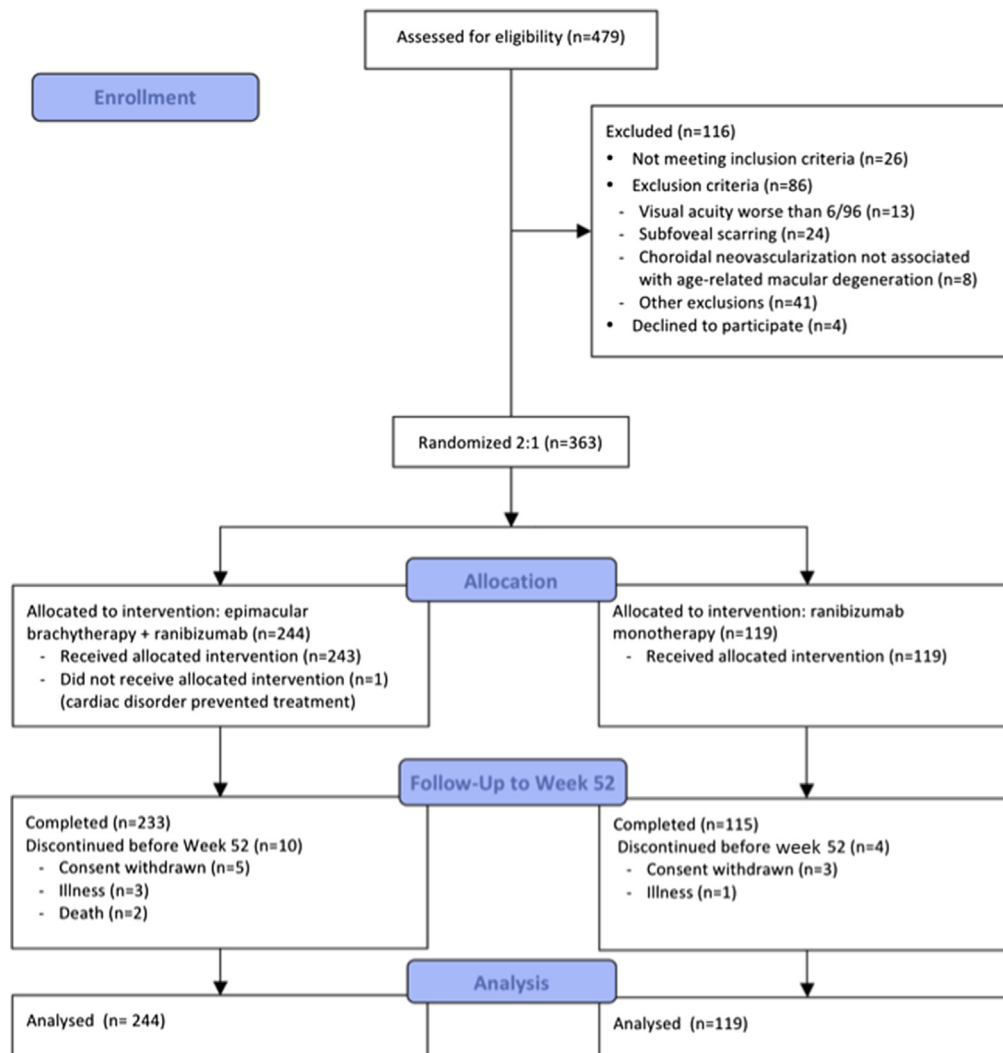


Figure 2. Diagram showing the Consolidated Standards of Reporting Trials (CONSORT) allocation and disposal of study participants up to the 12-month primary outcome. The statistical analysis plan included provision for missing visual acuity and injection data, hence the number of participants included in the analysis was greater than those reaching the 12-month end point.

Table 1. Baseline Ocular Characteristics

	Epimacular Brachytherapy (n = 244)	Ranibizumab (n = 119)	Total (n = 363)
Baseline ETDRS letters			
No.	244	119	363
Mean (SD)	62.7 (13.7)	64.4 (12.9)	63.2 (13.5)
Range (minimum–maximum)	13–86	34–88	13–88
Quartiles (25th, median, 75th)	53, 66, 73	56, 67, 74	54, 66, 73
Lens status, no. (%)			
Phakic	174 (71)	90 (76)	264 (73)
Pseudophakic	70 (29)	29 (24)	99 (27)
Lesion type, no. (%)			
Occult with no classic	180 (74)	91 (76)	271 (75)
Minimally classic	31 (13)	13 (11)	44 (12)
Predominantly classic	30 (12)	13 (11)	43 (12)
RAP	3 (1)	2 (2)	5 (1)
Total lesion size (mm ²)			
No.	240	115	355
Mean (SD)	9.1 (7.7)	9.8 (7.0)	9.3 (7.5)
Range (minimum–maximum)	0–45	0–43	0–45
Quartiles (25th, median, 75th)	4, 7, 12	4, 8, 14	4, 7, 13
Total lesion size category (DA), no. (%)			
≤3.5	143 (60)	61 (53)	204 (57)
>3.5	97 (40)	54 (47)	151 (43)
Total CNV size (mm ²)			
No.	240	115	355
Mean (SD)	5.7 (7.4)	5.7 (6.3)	5.7 (7.0)
Range (minimum–maximum)	0–45	0–43	0–45
Quartiles (25th, median, 75th)	0, 4, 8	1, 4, 9	0, 4, 9
Foveal thickness (μm)			
No.	238	117	355
Mean (SD)	378.0 (189.3)	415.0 (396.0)	390.2 (275.1)
Range (minimum–maximum)	60–1776	119–3996	60–3996
Quartiles (25th, median, 75th)	256, 344, 445	252, 338, 452	254, 341, 448
Anti-VEGF injections before enrollment			
No.	244	119	363
Mean (SD)	11.6 (5.5)	10.6 (5.0)	11.3 (5.4)
Range (minimum–maximum)	5–36	5–30	5–36
Quartiles (25th, median, 75th)	7, 10, 15	7, 9, 13.2	7, 10, 14

CNV = choroidal neovascularization; DA = disc area; ETDRS = Early Treatment Diabetic Retinopathy Study; RAP = retinal angiomatous proliferation; SD = standard deviation; VEGF = vascular endothelial growth factor.

rather, it showed significantly better BCVA in the ranibizumab monotherapy group. The secondary visual outcomes are shown in [Table 2](#) (available at www.aaojournal.org).

Optical Coherence Tomography

Of 363 participants, 336 (93%) completed both baseline and month 12 OCT examinations. The mean foveal thickness reduced minimally by -1.0 ± 215 μm in the EMB arm (n = 225) and by -15.7 ± 196 μm in the ranibizumab monotherapy arm (n = 111; $P = 0.43$).

Fluorescein Angiography

In the 329 of 363 participants (91%) with completed baseline and 12-month FA results, the total lesion size increased by 1.2 ± 8.3 mm² in the EMB arm (n = 219) and by 0.4 ± 7.6 mm² in the ranibizumab monotherapy arm (n = 110; $P = 0.27$). The CNV size decreased by 0.5 ± 7.6 mm² in the EMB arm and by 1.3 ± 7.0 mm² in the ranibizumab arm ($P = 0.27$).

Safety

[Table 3](#) (available at www.aaojournal.org) shows the AEs that occurred in the study eye. More AEs occurred in eyes in the EMB arm than in eyes in the control arm. The most common ocular AE was visually significant cataract requiring surgical intervention, which occurred in 33.6% of eyes treated with EMB versus 9.2% of eyes in the control arm, followed by reduced VA (16.0% vs. 6.7%, respectively) and eye pain (7.8% vs. 4.2%). Most other ocular AEs were uncommon.

[Table 4](#) (available at www.aaojournal.org) shows all AEs, excluding those in the study eye. There was a similar proportion of nonocular AEs in both groups.

The SAEs in the study eye, and their relatedness to treatment, are shown in [Table 5](#). The most clinically serious event was 1 case of endophthalmitis. The participant underwent EMB with cataract surgery 6 months later. Four weeks after cataract surgery culture-positive *Streptococcus pneumoniae* endophthalmitis developed, leading to rapid corneal perforation and subsequent evisceration. Two other patients initially were

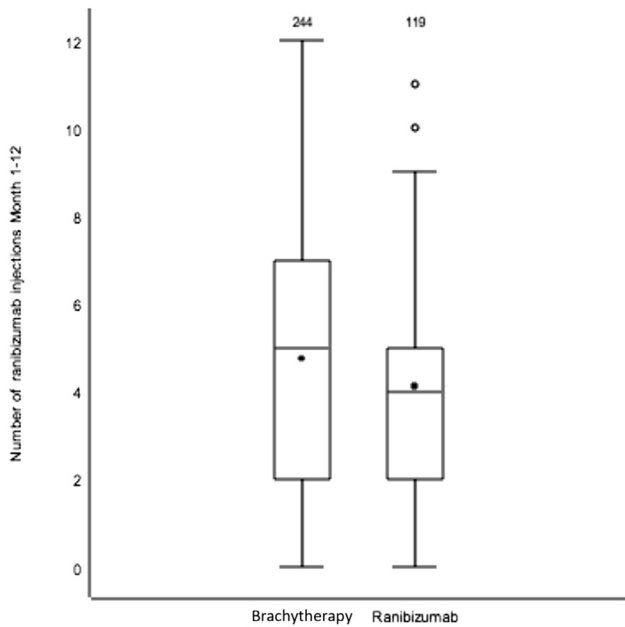


Figure 3. Box-and-whisker plot showing the number of pro re nata ranibizumab injections given up to and including month 12, but excluding any injections given at enrollment because of pre-existing disease activity. The top and bottom of the box show the third and first quartiles, respectively, with the median shown as the band inside the box. The top and bottom error bar show the highest observation still within 1.5 times the interquartile range (IQR) of the upper quartile, and the lowest observation still within 1.5 IQR of the lower quartile. Outliers are shown as unfilled circles. The mean is shown as a filled square inside the box.

diagnosed with presumed endophthalmitis, but the principal investigators subsequently changed the diagnosis to severe post-operative uveitis. One of these patients sought treatment 2 days after EMB with hypopyon and reduced vision, and therefore was treated with intravitreal antibiotics. There was a light growth of *Staphylococcus epidermidis* in the vitreous sample, but the microbiologists considered this to be a contaminant. The BCVA in this participant was 49 letters at baseline and 28 letters at month 12. In the second patient, 3 days after EMB, a hypopyon with reduced vision developed, and the patient was treated with intravitreal antibiotics. Aqueous and vitreous culture results were negative, and a full visual recovery occurred with no lasting sequelae (BCVA was 41 letters at baseline and 46 letters at month 12). Three retinal detachments occurred in the EMB group. [Table 6](#) (available at www.aaojournal.org) shows all SAEs, excluding those in the study eye. A total of 202 SAEs occurred in the EMB group and 93 in the control group.

The reading center inspection for radiation damage found 1.1% (4/350) of study eyes had an MVA at baseline, all of which were in the EMB arm. There were no MVAs in fellow eyes. At month 12, 1.4% (5/350) of study eyes had MVAs, all of which occurred in the EMB arm. [Table 7](#) (available at www.aaojournal.org) shows the types of MVAs. In 1 of the 5 patients with an MVA, the month 12 analysis revealed a new tortuous or dilated vessel with capillary nonperfusion that was not present at baseline ([Fig 6](#)). This was attributed to radiation damage, and the BCVA in this patient dropped from 54 ETDRS letters at baseline to 35 letters at month 12. In the other 4 patients, the same MVAs occurred at

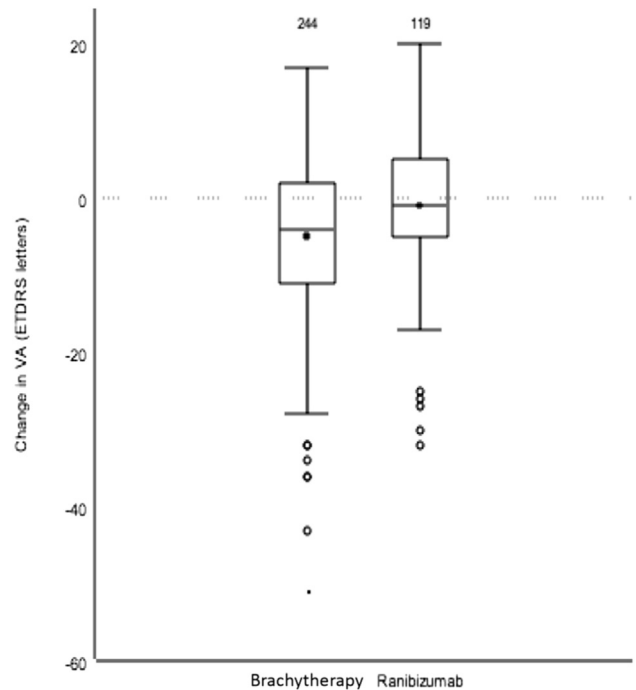


Figure 5. Box-and-whisker plot showing the change in Early Treatment of Diabetic Retinopathy Study (ETDRS) visual acuity (VA) at 12 months after enrollment, comparing the epimacular brachytherapy group with the ranibizumab monotherapy group. Figure conventions are the same as detailed in the legend to [Figure 3](#). Extreme outliers (those more than 3 IQR above the upper quartile or below the lower quartile) are shown as filled circles.

baseline as month 12, and the reading center determined that these were not radiation damage.

Subgroup Analysis

[Figure 7](#) (available at www.aaojournal.org) shows that most subgroups favored the ranibizumab monotherapy group in terms of the mean number of PRN ranibizumab injections, but the baseline characteristics associated with a smaller difference between groups were phakic lens, VA better than 53 letters, classic lesions, and small lesions (3.5 disc areas or less). The subgroup analysis of VA also tended to favor the ranibizumab group, but the baseline ocular characteristics associated with a smaller difference between groups were phakic lens, VA of 53 letters or worse, occult lesions, and small lesions ([Fig 8](#), available at www.aaojournal.org). Although some baseline characteristics were associated with a better response to EMB, none of the EMB subgroups showed noninferiority of VA or significantly fewer injections than the ranibizumab monotherapy arm.

Discussion

This study tested the safety and efficacy of EMB for patients with chronic, active neovascular AMD already receiving ranibizumab monotherapy. On the basis of phase 2 data, we hypothesized that EMB would reduce the number of

Table 5. Ocular Serious Adverse Events in the Study Eye and Relatedness to Treatment

Eye Disorders	Events	%	Intensity	Epimacular Brachytherapy	Vitrectomy	Ranibizumab	Intravitreal Injection
Epimacular brachytherapy (n = 244)							
Visual acuity reduced	4	1.6	Severe	Possibly	Possibly	Unlikely	Possibly
			Severe	Possibly	Likely	Unlikely	Unlikely
			Severe	Unlikely	Unlikely	Unlikely	Unlikely
			Moderate	Not related	Not related	Possibly	Likely
Vitreous hemorrhage	1	0.4	Moderate	Not related	Not related	Possibly	Likely
			Retinal hemorrhage	3	1.2	Severe	Unlikely
Retinal detachment	3	1.2	Moderate	Unlikely	Unlikely	Unlikely	Unlikely
			Severe	Unlikely	Unlikely	Unlikely	Unlikely
			Severe	Possibly	Possibly	Possibly	Possibly
Vision blurred	1	0.4	Moderate	Not related	Definitely	Not related	Not related
			Severe	Unlikely	Likely	Possibly	Possibly
Endophthalmitis	1	0.4	Severe	Possibly	Possibly	Possibly	Possibly
Vitreous floaters	1	0.4	Severe	Not related	Possibly	Not related	Not related
Postoperative uveitis	2	0.8	Severe	Possibly	Possibly	Unlikely	Unlikely
			Severe	Possibly	Possibly	Unlikely	Possibly
Ranibizumab monotherapy (n = 119)							
Visual acuity reduced	1	0.8	Moderate	N/A	N/A	Unlikely	Unlikely
Retinal hemorrhage	1	0.8	Moderate	N/A	N/A	Unlikely	Unlikely

N/A = not applicable.

ranibizumab injections that these patients require and would maintain a noninferior VA. The results do not support either hypothesis. Indeed, at 12 months those who underwent EMB averaged more injections (albeit not significantly more) and had VA that was significantly worse than those who continued with ranibizumab monotherapy. Therefore, the results of this study do not support the use of EMB in previously treated patients with neovascular AMD.

The current results differ from the phase 2 MERITAGE study of EMB, which suggested that EMB reduces the frequency of anti-VEGF retreatment in chronic, active neovascular AMD.^{9,10} The MERITAGE study recruited a very similar patient population and used the same EMB device, dose, and technique.⁹ Retreatments criteria also were similar. The MERITAGE study found that the anti-VEGF injection rate reduced by one-third comparing treatment before and after EMB, but there was no control group. Of 53 participants, 81% lost fewer than 15 ETDRS letters, which is similar to the current result (84%) and not dissimilar to the natural history of chronic AMD, which is often characterized by reducing VA after the initial improvement at the start of anti-VEGF treatment.^{14,15} By contrast, the control group in MERLOT showed a very stable VA, with 92% losing fewer than 15 letters and a mean loss of only -0.9 letters over 12 months. Therefore, the current EMB VA results are similar to the phase 2 study, but the control group displayed better than expected vision. By contrast, the expected reduction in injection frequency seen in MERITAGE was not evident in MERLOT, relative to the control group. The reason for these differences are speculative, but may relate to surgical technique, clinician experience and training, case selection, chance, or some other unidentified factor or factors.

The VA results seem similar to those of the CABERNET study, a large randomized controlled trial of EMB in

treatment-naïve disease.^{6,7} That study also failed to establish noninferiority of VA using a similar noninferiority margin of -10%. However, because the CABERNET control group received a more intensive, mandated injection regimen, it was difficult to isolate the beneficial or deleterious effect of EMB. Furthermore, CABERNET was not designed to establish whether EMB reduced the need for anti-VEGF therapy, although participants in the EMB arm received relatively few injections (an average of 6.2 over the 2-year study).⁶ It is possible that the VA results in the CABERNET EMB arm were the result of undertreatment; however, this was not the case in MERLOT, where the radiotherapy arm showed a trend for worse VA than the control arm, despite receiving more injections.

The results of this study are in contrast with those of the IRay in Conjunction with Anti-VEGF Treatment for Patients with Wet AMD (INTREPID) study.¹⁶ The INTREPID study met its primary end point, showing a statistically significant reduction in anti-VEGF therapy after radiotherapy. It had a similar study design, enrolling participants with previously treated neovascular AMD who then were randomized to combined radiotherapy and anti-VEGF therapy or to anti-VEGF monotherapy. The dose of radiotherapy also was similar comparing INTREPID and MERLOT. The main difference lay in radiotherapy delivery, with INTREPID using teletherapy and MERLOT using intraocular brachytherapy. Thus, INTREPID avoided the effects of vitrectomy.

There are several possible explanations for the very different results between EMB and stereotactic teletherapy. First, EMB requires manual positioning of the probe over the area of greatest disease activity. For occult lesions (75% of those in the present study), it can be hard to define the area of greatest activity. This risk is amplified by the short range

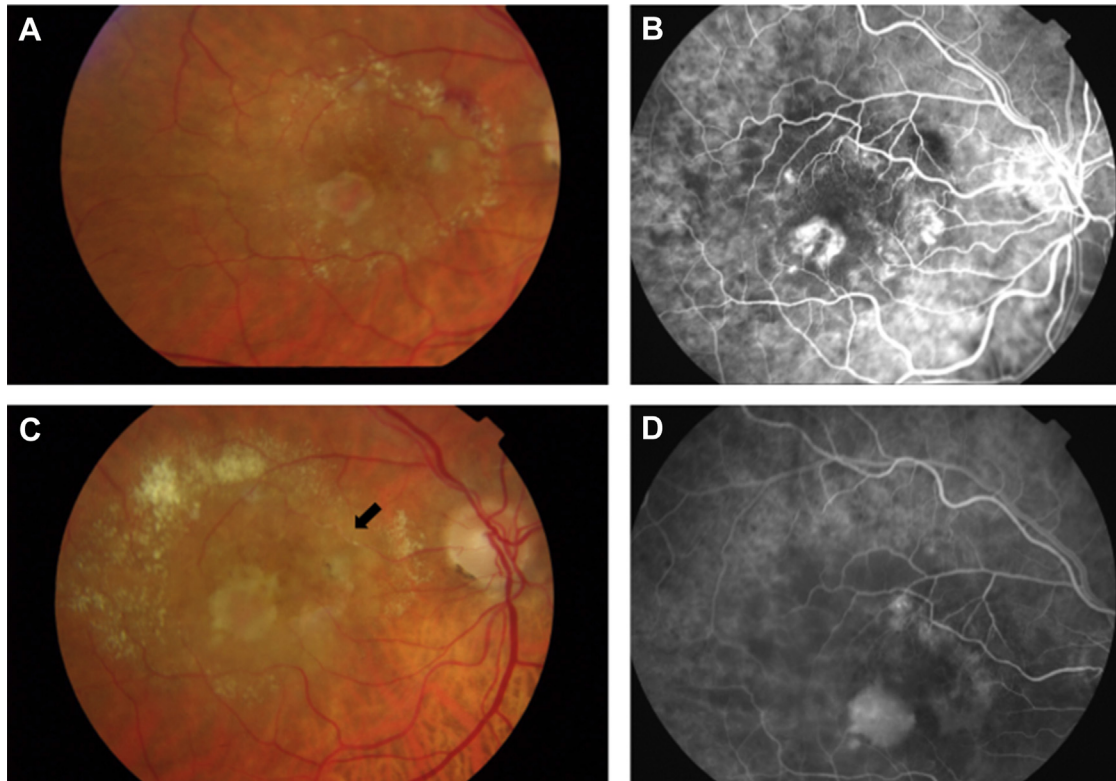


Figure 6. Fundus photographs and angiograms of the participant in whom retinal microvascular abnormality secondary to epimacular brachytherapy developed: baseline (A) fundus photograph and (B) fundus fluorescein angiogram, (C) month 12 fundus photograph showing a new tortuous and dilated vessel (black arrow), and (D) month 12 angiogram showing capillary dropout adjacent to the abnormal vessel.

of the strontium β particles in tissue,⁵ compounded by the fact that surgeons may hold the probe away from the retinal surface to reduce the risk of trauma. Vitrectomy is known to cause cataract, whereas stereotactic radiotherapy was not noted to do so.¹⁶ Vitrectomy also reduces intravitreal drug half-life,^{17–19} so if there is any residual disease activity, this may be harder to control or it may require more frequent injections to maintain a therapeutic effect.

More AEs and SAEs occurred in EMB-treated eyes, including a higher rate of cataract. Radiation has the potential to induce cataract, but the dose received by the lens during EMB is approximately one thousandth of that thought to cause lens opacity.²⁰ By contrast, vitrectomy is well known to cause cataract in most phakic eyes.²¹ It seems likely, then, that the higher rate of cataract was caused by vitrectomy rather than by EMB. More cases of retinal detachment and endophthalmitis occurred in the EMB-treated eyes, but this was also true of the fellow eye, and with very low numbers of events, these may have occurred by chance. The SAEs in the study were not usually attributed to EMB, and the severe endophthalmitis case occurred 7 months after EMB, but only 1 month after cataract surgery, suggesting the latter may have been responsible. The other organ classes with higher than expected AEs and SAEs did not point to any expected or theoretical risk, such as neoplasia secondary to radiation exposure, although such a risk cannot be excluded. The rate

of arteriothrombotic events was lower in the EMB arm, despite receiving more ranibizumab injections.

Fundus photographs, FA images, and OCT images analyzed by an independent reading center failed to show any benefit from EMB. Although not significantly different, all the predefined structural outcomes favored the control group, including change in angiographic lesion size, CNV size, and OCT thickness.

The subgroup analysis was designed to help refine case selection if EMB was shown to be effective or to identify subsets of patients for whom EMB may be effective if the group as a whole did not show benefit, subject to confirmatory studies. Unfortunately, we failed to identify participants who did significantly better than ranibizumab monotherapy, and our results do not seem to justify further studies.

Strengths of the MERLOT study include its size, randomized controlled design, and independent reading center evaluation of structural outcomes. It was not possible to mask the study fully because there is no feasible way to mimic vitrectomy. This may have had relatively little effect on VA assessment, which was carried out according to a strict protocol by masked assessors. Bias may be more likely to influence AE reporting and retreatment decisions, but the retreatment criteria were well defined and the key parameters driving retreatment decisions were masked (BCVA) or automated (OCT). Furthermore, we would have anticipated fewer injections assuming clinicians may be more inclined

not to inject EMB-treated eyes if they expected EMB to reduce the injection frequency, and injecting may be perceived as a treatment failure. We cannot exclude confounding resulting from cataract occurring after vitrectomy, which could improve the perceived benefit of EMB falsely if pre-existing lens opacity was removed subsequently or could reduce VA if developing cataract did not yet warrant removal. However, our predefined subgroup analysis in pseudophakic eyes also showed VA favoring ranibizumab monotherapy.

In summary, this study does not support the use of EMB for previously treated neovascular AMD. Indeed, the VA results suggest vision may be worse than with ranibizumab monotherapy, and there was a trend for worse structural outcomes. We did not identify any subgroup of patients who respond well to EMB or who warrant further study. Three years of safety follow-up is planned because radiation retinopathy can occur beyond the current 12-month milestone.

Acknowledgments. The authors thank the members of the MERLOT study group and the Reading Centre clinicians (Appendix 1, available at www.aaojournal.org), the Data Monitoring Committee and Trial Steering Committee members (Appendix 3, available at www.aaojournal.org), and the trial participants.

References

- Avila MP, Farah ME, Santos A, et al. Twelve-month short-term safety and visual-acuity results from a multicentre prospective study of epiretinal strontium-90 brachytherapy with bevacizumab for the treatment of subfoveal choroidal neovascularisation secondary to age-related macular degeneration. *Br J Ophthalmol* 2009;93:305–9.
- Chakravarthy U, Gardiner TA, Archer DB, Maguire CJ. A light microscopic and autoradiographic study of non-irradiated and irradiated ocular wounds. *Curr Eye Res* 1989;8:337–48.
- Kirwan JF, Constable PH, Murdoch IE, Khaw PT. Beta irradiation: new uses for an old treatment: a review. *Eye (Lond)* 2003;17:207–15.
- Spaide RF. Rationale for combination therapy in age-related macular degeneration. *Retina* 2009;29(6 Suppl):S5–7.
- Petrarca R, Richardson M, Douiri A, et al. Safety testing of epimacular brachytherapy with microperimetry and indocyanine green angiography: 12-month results. *Retina* 2013;33:1232–40.
- Dugel PU, Bebhuk JD, Nau J, et al. Epimacular brachytherapy for neovascular age-related macular degeneration: a randomized, controlled trial (CABERNET). *Ophthalmology* 2013;120:317–27.
- Jackson TL, Dugel PU, Bebhuk JD, et al. Epimacular brachytherapy for neovascular age-related macular degeneration (CABERNET): fluorescein angiography and optical coherence tomography. *Ophthalmology* 2013;120:1597–603.
- Martin DF, Maguire MG, Fine SL, et al. Ranibizumab and bevacizumab for treatment of neovascular age-related macular degeneration: two-year results. *Ophthalmology* 2012;119:1388–98.
- Dugel PU, Petrarca R, Bennett M, et al. Macular epiretinal brachytherapy in treated age-related macular degeneration: MERITAGE study: twelve-month safety and efficacy results. *Ophthalmology* 2012;119:1425–31.
- Petrarca R, Dugel PU, Nau J, et al. Macular epiretinal brachytherapy in treated age-related macular degeneration (MERITAGE): month 12 optical coherence tomography and fluorescein angiography. *Ophthalmology* 2013;120:328–33.
- Jackson TL, Dugel PU, Bebhuk JD, et al. Epimacular brachytherapy for neovascular age-related macular degeneration (CABERNET): fluorescein angiography and optical coherence tomography. *Ophthalmology* 2013;120:1597–603.
- Lalwani GA, Rosenfeld PJ, Fung AE, et al. A variable-dosing regimen with intravitreal ranibizumab for neovascular age-related macular degeneration: year 2 of the PrONTO study. *Am J Ophthalmol* 2009;148:43–58 e1.
- Fung AE, Lalwani GA, Rosenfeld PJ, et al. An optical coherence tomography-guided, variable dosing regimen with intravitreal ranibizumab (Lucentis) for neovascular age-related macular degeneration. *Am J Ophthalmol* 2007;143:566–83.
- Holz FG, Amoaku W, Donate J, et al. Safety and efficacy of a flexible dosing regimen of ranibizumab in neovascular age-related macular degeneration: the SUSTAIN study. *Ophthalmology* 2011;118:663–71.
- Writing Committee for the UK Age-Related Macular Degeneration EMR Users Group. The neovascular age-related macular degeneration database: multicenter study of 92 976 ranibizumab injections: report 1: visual acuity. *Ophthalmology* 2014;121:1092–101.
- Jackson TL, Chakravarthy U, Kaiser PK, et al. Stereotactic radiotherapy for neovascular age-related macular degeneration: 52-week safety and efficacy results of the INTREPID study. *Ophthalmology* 2013;120:1893–900.
- Chin HS, Park TS, Moon YS, Oh JH. Difference in clearance of intravitreal triamcinolone acetonide between vitrectomized and nonvitrectomized eyes. *Retina* 2005;25:556–60.
- Christoforidis JB, Xie Z, Jiang A, et al. Serum levels of intravitreal bevacizumab after vitrectomy, lensectomy and non-surgical controls. *Curr Eye Res* 2013;38:761–6.
- Kakinoki M, Sawada O, Sawada T, et al. Effect of vitrectomy on aqueous VEGF concentration and pharmacokinetics of bevacizumab in macaque monkeys. *Invest Ophthalmol Vis Sci* 2012;53:5877–80.
- Petrarca R, Jackson TL. Radiation therapy for neovascular age-related macular degeneration. *Clin Ophthalmol* 2011;5:57–63.
- Jackson TL, Donachie PH, Sparrow JM, Johnston RL. United Kingdom National Ophthalmology Database Study of Vitreoretinal Surgery: report 1; case mix, complications, and cataract. *Eye (Lond)* 2013;27:644–51.

Footnotes and Financial Disclosures

Originally received: February 2, 2016.

Final revision: February 12, 2016.

Accepted: February 12, 2016.

Available online: April 13, 2016.

Manuscript no. 2016-224.

¹ School of Medicine, King's College London, London, United Kingdom.

² Department of Ophthalmology, King's College Hospital, London, United Kingdom.

³ Statistics Collaborative, Inc, Washington, DC.

⁴ Department of Engineering and Physics, King's College Hospital, London, United Kingdom.

⁵ Department of Ophthalmology, Maidstone Hospital, Maidstone, United Kingdom.

⁶ Bristol Eye Hospital, Bristol, United Kingdom.

⁷ Hull and East Yorkshire Eye Hospital, Hull, United Kingdom.

⁸ Sunderland Eye Infirmary, Sunderland, United Kingdom, and the Institute of Genetic Medicine, Newcastle University, Newcastle Upon Tyne, United Kingdom.

⁹ Central Angiographic Reading Centre, Queen's University of Belfast, Belfast, United Kingdom.

Presented in part at: Retina Day, American Academy of Ophthalmology Annual Meeting, November 2015, Las Vegas, Nevada.

*A full listing of the MERLOT Study Group is available in [Appendix 1](#), available at www.aaojournal.org.

Financial Disclosure(s):

The author(s) have made the following disclosure(s): T.L.J.: Financial support – NeoVista (Fremont, CA); Financial support (to employer) – NeoVista; Oraya (Newark, CA); Novartis (Frimley, UK)

J.W.: Consultant – NeoVista (Fremont, CA); Oraya

K.S.: Financial support – NeoVista (Fremont, CA); Genentech (South San Francisco, CA); Alcon (Fort Worth, TX)

R.H.: Financial support – NeoVista (Fremont, CA)

NeoVista (Fremont, CA) provided unrestricted research funding but had no role in data collection, analysis, or in the preparation or review of this manuscript.

Supported by the United Kingdom National Institute of Health Research Comprehensive Clinical Research Network. Study sponsored by King's College Hospital, London, United Kingdom.

Author Contributions:

Conception and design: Jackson (protocol author and Chief Investigator), Desai, Simpson, Petrarca, Wittes

Analysis and interpretation: Jackson, Desai, Simpson, Petrarca, Smith, Wittes, Membrey, Costen, Steel, Neffendorf, Haynes, Chakravarthy

Data collection: Jackson, Desai, Chakravarthy, Muldrew, Neffendorf, Simpson, Petrarca, Lewis, Membrey, Costen, Steel

Obtained funding: Jackson

Overall responsibility: Jackson, Desai, Simpson, Petrarca, Smith, Wittes, Lewis, Membrey, Costen, Steel

Abbreviations and Acronyms:

AMD = age-related macular degeneration; **BCVA** = best-corrected visual acuity; **CABERNET** = Choroidal Neovascularization Secondary to Age-Related Macular Degeneration Treated with Beta Radiation Epiretinal Therapy; **CNV** = choroidal neovascularization; **EMB** = epimacular brachytherapy; **ETDRS** = Early Treatment of Diabetic Retinopathy Study; **INTREPID** = IRay in Conjunction with Anti-VEGF Treatment for Patients with Wet AMD; **MERITAGE** = Macular Epiretinal Brachytherapy in Treated Age-Related Macular Degeneration; **MERLOT** = Macular Epiretinal Brachytherapy versus Ranibizumab (Lucentis) Only Treatment; **MVA** = microvascular abnormality; **OCT** = optical coherence tomography; **PRN** = pro re nata; **VA** = visual acuity; **VEGF** = vascular endothelial growth factor.

Correspondence:

Timothy L. Jackson, PhD, FRCOphth, Department of Ophthalmology, School of Medicine, King's College London, King's College Hospital, London SE5 9RS, United Kingdom. E-mail: t.jackson1@nhs.net.