

PDF hosted at the Radboud Repository of the Radboud University Nijmegen

The following full text is a publisher's version.

For additional information about this publication click this link.

<http://hdl.handle.net/2066/51088>

Please be advised that this information was generated on 2017-12-06 and may be subject to change.

CLINICAL STUDY

Transsphenoidal pituitary surgery via the endoscopic technique: results in 35 consecutive patients with Cushing's disease

R T Netea-Maier¹, E J van Lindert², M den Heijer¹, A van der Eerden¹, G F F M Pieters¹, C G J Sweep³, J A Grotenhuis² and A R M M Hermus¹

¹Pituitary Centre Nijmegen, Department of Endocrinology ²Department of Neurosurgery and ³Department of Chemical Endocrinology, Radboud University Nijmegen Medical Centre, Geert Grooteplein 8, 6500 HB, Nijmegen, The Netherlands

(Correspondence should be addressed to Romana T Netea-Maier; Email: R.Netea-Maier@endo.umcn.nl)

Abstract

Objective and design: The endoscopic technique has been recently introduced in the field of transsphenoidal pituitary surgery. This technique allows inspection of sellar, supra- and parasellar structures and removal of the tumor under direct visualization, is minimally traumatic and permits easier reoperations. This is the first report on the results of endoscopic surgery for patients with Cushing's disease. Our aim was to retrospectively analyze the results of pituitary surgery in 35 consecutive patients with Cushing's disease operated in our hospital after the introduction of the endoscopic technique (1998–2004).

Methods: Remission was defined as suppression of plasma cortisol (≤ 50 nmol/L) after 1 mg dexamethasone overnight determined in the first 3 months after surgery and disappearance of clinical signs and symptoms of hypercortisolism. The patients were followed for an average of 27 months (range 4 to 81 months, median 20 months).

Results: Pituitary MRI showed a macroadenoma in 6 patients, a microadenoma in 17 patients and no adenoma in 12 patients. After the initial surgery 27 patients (77%) were in remission. None of the patients had a relapse during follow-up. In the remaining 8 patients hypercortisolemia persisted after surgery. Three of them had a second endoscopic pituitary surgery resulting in remission in two patients. In one patient a second endoscopic pituitary surgery will soon follow. The remaining four patients were treated with radiotherapy postoperatively. Two of them were at the time of data collection in remission. One patient from the remission group had a serious epistaxis and three patients had cerebrospinal fluid leakage, one requiring an external lumbar drain, shortly after surgery. No complications were recorded in the failure group. Postoperatively 34% of all patients required substitution with levothyroxine, 40% required substitution with glucocorticoids, 17% received estrogens or testosterone and 6% still required desmopressin.

Conclusions: Endoscopic transsphenoidal pituitary surgery resulted in our series of patients with Cushing's disease in an excellent postoperative remission rate. A randomized clinical trial, comparing endoscopic and conventional pituitary surgery in patients with Cushing's disease, is needed to determine the pros and cons of both techniques.

European Journal of Endocrinology 154 675–684

Introduction

Hypersecretion of ACTH by a pituitary adenoma (Cushing's disease) is the most common cause of endogenous hypercortisolism. The condition is potentially life threatening and requires aggressive therapy. Transsphenoidal pituitary microsurgery is the treatment of choice for these patients. However, even in experienced hands no more than 50 to 90% of patients are in remission after surgery (1–15). This may be due to the fact that ACTH producing adenomas are small and thus cannot be visualized, even with modern imaging techniques, making it difficult for the surgeon to find the

adenoma. Moreover, hypercortisolemic patients are prone to complications during surgery (16). Long-term follow-up has shown that the quality of life of patients with Cushing's disease who are in remission after a first pituitary operation is better than in those patients who need additional treatment (17). Therefore, a successful initial pituitary operation is highly desirable for patients with Cushing's disease.

The endoscopic technique has been recently introduced in the field of pituitary surgery (18–23). Traditional surgical approaches to pituitary tumors are based on transseptal or sublabial transsphenoidal access to the sella turcica (20). The endoscopic

endonasal approach avoids transseptal dissection, thus reducing patient discomfort and postoperative pain. The endoscope has increasingly been used in pituitary surgery since the mid 1990s either in conjunction with the microscopic technique (24) or as a pure endoscopic procedure (18, 25, 26). Especially the better panoramic visualization of sellar, supra- and parasellar anatomy with increased illumination and magnification are recognized as major advantages offered by the endoscopic technique (21, 25, 27). Some concerns have been raised regarding the lack of stereoscopic view with the endoscope and the lack of maneuverability as surgeons can only manipulate tools with one hand unless a holder is used, which in turn may crowd the operative field (19, 27, 28). These disadvantages can, however, be reduced by using more refined instrumentation (19, 27). Initial reports showed a decrease in postoperative discomfort and hospitalization time as well as a quick recovery in patients operated by the endoscopic technique in comparison with the conventional microscopic technique (25, 29–31). Decreased operative time and decreased blood loss as compared with open transsphenoidal surgery have also been reported (31–33). The endoscopic approach is safe, all authors reporting low complication rates (25, 26, 30–35). It is minimally traumatic and permits easier reoperations (18–21, 23). This makes the endoscopic pituitary approach attractive for patients with Cushing's disease in an attempt to avoid bleeding complications that are particularly feared because of the hypercortisolemic status.

To our knowledge, there are no specific studies on the results of endoscopic pituitary surgery in patients with Cushing's disease. Endoscopic pituitary surgery was introduced in our hospital in 1997 and it has been applied in all patients with Cushing's disease treated in our centre since 1998. The aim of our study was to analyze retrospectively the results of pituitary surgery in the 35 consecutive patients with Cushing's disease who have been operated in our hospital after the introduction of the endoscopic technique (1998–2004).

Patients and methods

Patients

The medical records of the 35 consecutive patients with Cushing's disease undergoing endoscopic pituitary surgery in our hospital between 1998 and 2004 were analyzed. There were 25 females and 10 males, age at the time of diagnosis was 41.0 ± 14.8 years and BMI was 28.7 ± 5.3 kg/m². We collected data on the preoperative and the early postoperative evaluation, on complications that occurred during the operation or in the early postoperative period and on the last evaluation at the most recent follow-up visit.

Preoperative evaluation

Diagnosis of hypercortisolism was based on clinical grounds and biochemical tests including repeated 24-h urinary free cortisol (UFC) measurements, assessment of the circadian rhythm of plasma cortisol with midnight plasma cortisol measurement and determination of plasma cortisol after overnight low dose dexamethasone (1 mg at 2300 h) (36). Pituitary imaging by MRI with i.v. contrast (gadolinium) was performed in all patients. Six of the 35 patients had a macroadenoma (defined as ≥ 1 cm in diameter) on the preoperative MRI. In the other patients the MRI showed either a tumor < 1 cm (17 patients) or no evidence of a tumor (12 patients). In addition, the results of the CRH test (100 μ g human CRH i.v.) (37), and the high-dose dexamethasone test (7 mg dexamethasone in 7 hours i.v.) (38) were used to demonstrate the pituitary origin of the hypercortisolism. In 12 patients bilateral catheterisation of the inferior petrosal sinuses was performed with blood sampling before and after i.v. stimulation with 100 μ g human CRH (39), to confirm the pituitary origin of the hypercortisolism in all 12 patients.

Treatment with cortisol lowering agents before surgery and with glucocorticoids in the perioperative period

Treatment with cortisol lowering agents, metyrapone and/or ketoconazole, was given in 30 patients for a period of 4 months preoperatively. On the day of surgery, administration of glucocorticoids i.v. was started (prednisolone, 25 mg every 8 h i.v. for two days) with the first dose one hour before the start of the operation. Thereafter, the dose of glucocorticoids was decreased rapidly (prednisolone orally 50 mg on day 2, 25 mg on day 3 and 4) during the next days so that the patients received the last dose of glucocorticoids as 10 mg prednisolone orally on the fifth day postoperatively. Thereafter, no further glucocorticoids were administered until the seventh day postoperatively, after blood sampling for the first endocrine evaluation. The interval between the last dose of glucocorticoids and the first postoperative measurement of fasting plasma cortisol was at least 48 h.

Surgical technique

Our technique is based on the pioneering work of Jho *et al.* (22, 23) and Cappabianca *et al.* (18, 19). However, we (EJvL and JAG) modified the technique by using a binostriil, transsphenoidal, endoscopic approach to the sella turcica with a handheld endoscope.

The optic instrument used was a 5° lensscope with a diameter of 4 mm and a separate shaft around it for irrigation and suction to clear the front lens. This instrument allows by its pistol grip an easy and comfortable handling (Richard Wolf GmbH, Knittlingen, Germany). The maximal outer diameter of the oval-shaped shaft is

6.3 mm. A 25° optic is available for use in specific situations.

The camera used is the Stereosite™ (Vista Medical Technologies Inc., Carlsbad, California, USA). This camera system incorporates a Head-Mounted Display (HMD) that is worn by the surgeon during all phases of the operation. The endoscopic picture is projected on LCD-screens from the HMD with a resolution of 640 * 480 pixels. The instruments used are principally the same as those used during a conventional microsurgical procedure.

In cases where the tumor is identified by MRI or during the operation, selective adenomectomy is performed. In case of negative MRI investigations and a negative pituitary exploration, a hemihypophysectomy is performed, preferentially based on lateralization of ACTH levels during inferior petrosal sinus sampling. Only in cases of persisting hypercortisolism after surgery, a total adenohypophysectomy is performed in a second surgical procedure.

Postoperative evaluation

The early postoperative biochemical evaluation consisted of measuring the fasting (0800 h) plasma levels of ACTH and cortisol on the seventh day after surgery (48 h after the last dose of glucocorticoids). In patients with a basal plasma cortisol concentration below 200 nmol/L substitution therapy with hydrocortisone, 30 mg once daily, or cortisone acetate, 37.5 mg once daily, was prescribed. Patients were re-evaluated every 24 weeks during the first 3 months and thereafter at 2–3 months intervals during the first year after surgery and at least yearly thereafter. At each visit the fasting plasma cortisol concentration was measured after withdrawal of glucocorticoid substitution for 24 h. In addition, a low dose dexamethasone suppression test (1 mg overnight) was performed at 1 and 3 months after surgery. In every patient in whom glucocorticoid substitution was started after surgery, we tried to reduce the dose of oral glucocorticoids starting 3 months after surgery and to stop glucocorticoid substitution within 12 months after surgery. After stopping glucocorticoid substitution the integrity of the hypothalamic-pituitary-adrenal axis was assessed in these patients by the insulin-hypoglycemia test (40). In all patients who were in remission of hypercortisolism after pituitary surgery, low dose dexamethasone suppression tests (1 mg overnight) were performed yearly and of course earlier when there was a clinical suspicion of recurrence of the hypercortisolism.

Assessment of the thyrotropic, gonadotropic and somatotropic axis was performed at regular intervals by measuring the serum concentrations of thyrotropin (TSH), free thyroxine (FT4), gonadotropins (LH and FSH), testosterone, estradiol and insulin-like growth factor-1 (IGF-1). In case of clinical suspicion of growth hormone (GH) deficiency a GH stimulation

test (preferably an insulin-hypoglycemia test) was performed.

Criteria for remission and relapse

Remission was defined as adequate suppression of plasma cortisol (≤ 50 nmol/L) after 1 mg dexamethasone overnight determined in the first 3 months after surgery and disappearance of clinical signs and symptoms of hypercortisolism.

Relapse was defined as development of inadequate suppression of plasma cortisol after 1 mg dexamethasone overnight in a patient who was postoperatively in remission according to the above-mentioned criteria.

Assays

ACTH was measured in EDTA plasma by a two-step immunoradiometric assay (IRMA, Dynotest BRAHMS, Berlin, Germany). Within and between assay coefficients of variations (CV) were 5.8% and 7.4% at a level of 2.4 pmol/L and 4.7% and 4.0% at a level of 29.9 pmol/L. A functional detection limit of 0.8 pmol/L was established. The reference range is 2.2–13.2 pmol/L.

Plasma cortisol was measured by radioimmunoassay. In patients who were treated with metyrapone and/or ketoconazole the radioimmunoassay was done after previous extraction and paper chromatography (41). To summarize briefly, before extraction 3H-cortisol was added to correct for procedural losses. After chromatography, the location of the cortisol zone was identified by radiochromatogram scanning, the zone was cut out and soaked in buffer. The recovered radioactivity was measured by liquid scintillation counting of an aliquot from the eluate. Subsequently, cortisol tracer and antiserum were added and after incubation, free and bound tracers were separated by means of dextran coated charcoal. The antibody bound radioactivity was assessed by liquid scintillation counting of the supernatant. The calculations were performed by special software designed for correction of the mass and radioactive contribution of the recovery tracer in the RIA. Using a sample volume of 0.05 ml, the detection limit was 1.4 nmol/L. The between-assay CV was 5.9% at a level of 320 nmol/L. Accuracy was assessed over a longer period of time by measurement of QC samples in which the cortisol levels had been established by GC/MS, which resulted in $100.7 \pm 2.4\%$ ($n = 40$) of the target value.

The reference range is 190–500 nmol/L (at 0800 h).

Statistics

Chi-square tests were used to test for differences in the proportion of patients with macroadenomas, histological confirmation of the ACTH producing adenoma and use of cortisol lowering medication between the

remission and failure groups. Statistical significance was considered when $P < 0.05$ (two-tailed).

Results

The results of endoscopic transsphenoidal pituitary surgery in the 35 patients with Cushing's disease are shown in Fig. 1. The individual data of the 35 patients are given in Table 1. The mean follow-up was 27 months (range 4 to 81 months; median 20 months). After initial pituitary surgery 25 patients were in remission according to the criteria mentioned above. In two patients (patients 7 and 17) a 1 mg dexamethasone suppression test was not done postoperatively. However, both had a clearly subnormal basal cortisol level postoperatively and went into clinical remission and still received glucocorticoid substitution at the last follow-up visit. Including these two patients the remission rate in our series was 77%. During the follow-up none of the patients in our series had a relapse of Cushing's syndrome. In 8 patients initial pituitary surgery failed to cure the hypercortisolism. In three of these patients (patients 6, 10 and 11) the tumor could not be localized, either preoperatively on MRI or during pituitary surgery, and one patient (patient 18) had a lesion suspect for a microadenoma on the preoperative MRI. No ACTH producing adenoma was found on histological examination of tissue removed during the first surgery in these four patients. Three of them (patients 6, 10 and 11) had a second endoscopic pituitary operation between 3 and 11 months after the initial surgery. In none of these patients histological examination of the tissue removed during the second operation showed evidence of an ACTH producing adenoma. Nevertheless, two of them became in remission after the second operation (patients 6 and 10). In the third patient hypercortisolism persisted after the second operation and she finally had a bilateral adrenalectomy eight months later (patient 11). In the fourth patient (patient 18) the second pituitary surgery will soon follow. Four other patients with a failure of the first pituitary operation were treated postoperatively

with radiotherapy (patients 4, 9, 21 and 34). Two of these patients had macroadenomas with invasion of the cavernous sinus (patients 9 and 21) and one had a microadenoma on the MRI (patient 4). In one patient the tumor could not be visualized either on the MRI, or during the exploration of the pituitary (patient 34). The presence of an ACTH producing adenoma was confirmed on histological examination in the three patients in whom the tumor was visualized. At the time of the last follow-up visit (45 and 34 months after radiotherapy), two of these patients (patients 4 and 9) were in remission. The second patient with a macroadenoma is improving clinically after radiotherapy. At the moment (11 months after radiotherapy) he uses ketoconazole in decreasing dosage (patient 21). The fourth patient has only recently received radiotherapy and is still receiving ketoconazole (patient 34).

As can be seen in Table 1, there was a gradual increase in the number of patients receiving endoscopic surgery per year. During the first four years after the introduction of the endoscopic technique, in 6 out of 10 patients (60%) a remission was achieved after initial pituitary surgery. However, in the following three years a remission was achieved in 21 of the 25 patients (84%). Remission was achieved in 29 patients (83%) after the first or second pituitary surgery. There have been no recurrences in these 29 patients during follow-up.

When comparing the groups of patients with successful and unsuccessful initial pituitary surgery, a macroadenoma was present in 25% of the patients with unsuccessful and in 14% of the patients with successful surgery ($P = 0.37$), whilst the percentage of patients that were treated preoperatively with cortisol lowering agents was the same (85.5% in both groups). The percentage of patients in whom the presence of an ACTH producing adenoma was confirmed histologically was 81% in the successfully operated compared to 50% in the unsuccessfully operated patients ($P = 0.061$).

Ten of the 27 patients who had a successful initial surgery had complications perioperatively. Two patients

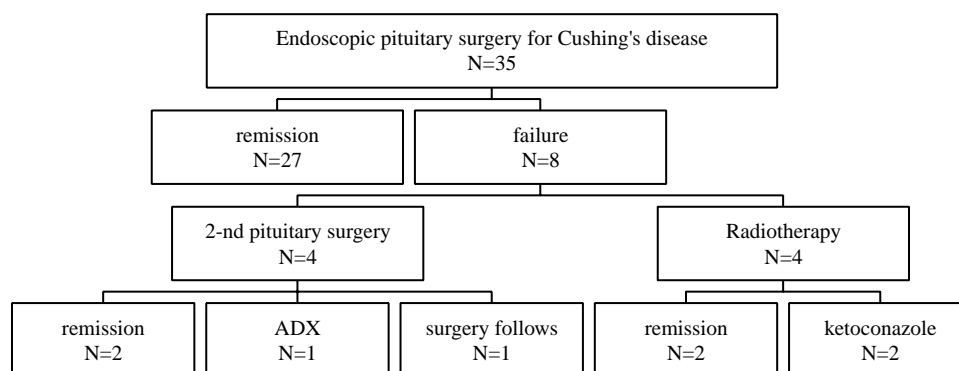


Figure 1 Results of endoscopic pituitary surgery in patients with Cushing's disease (1998–2004). (ADX: bilateral adrenalectomy).

Table 1 Clinical characteristics of the 35 consecutive patients with Cushing's disease operated by endoscopic transsphenoidal pituitary surgery between 1998 and 2004.

Patient no., gender, age (years)	CLA	MRI	SPS	Year of TS	Histology	Cortisol (nmol/L)		TS result	Additional therapy	Hormona substitution	Follow-up (months)
						Basal	After Dex				
1. m, 35	M	-	left	1998	+	<20	<20	R	-	-	81
2. f, 22	K	<10	left	1998	+	30	-	R	-	E, GH, T	81
3. f, 46	M	-	NP	1998	+	<20	40	R	-	-	74
4. f, 42	M	<10	NP	2000	+	560	200	F	CR (45 Gy)	G, GH	57
5. f, 32	-	-	NP	2000	-	70	<20	R	-	E	50
6. f, 45	K	-	right	2000	-	440	430	F	TS	E, G, T	49
7. f, 44	M	<10	NP	2001	+	80	-	R	-	G	24†
8. f, 51	-	-	right	2001	+	70	40	R	-	-	41
9. m, 23	-	18	NP	2001	+	280	70	F	RS (20 Gy)	T	39
10. m, 29	M	-	left	2001	-	270	110	F	TS	A, G, T	37
11. f, 36	M, K	-	right	2002	-	400	530	F	TS, ADX	G, T	35
12. m, 23	-	35	NP	2002	+	110	20	R	-	-	33
13. f, 62	K	<10	NP	2002	+	<20	-	R	-	G, D	31
14. f, 22	-	-	NP	2002	+	20	<20	R	-	E	27
15. f, 31	K	<10	NP	2002	+	40	-	R	-	G, T	25
16. m, 63	M	<10	NP	2002	+	<20	20	R	-	A	25
17. f, 37	K	<10	right	2003	-	70	-	R	-	G	22
18. f, 20	M	<10	right	2003	-	90	140	F	TS follows	-	20
19. f, 41	M, K	<10	left	2003	+	350	20	R	-	-	18
20. f, 49	M	18	NP	2003	+	190	50	R	-	-	17
21. m, 39	M	12	NP	2003	+	290	110	F	RS (35 Gy)	-	17
22. m, 14	M	<10	left	2003	-	20	30	R	-	T	14
23. f, 66	M	<10	NP	2003	+	150	30	R	-	G	13
24. f, 55	M	<10	NP	2003	+	90	<30	R	-	T, D	12
25. m, 38	M	-	left	2004	-	200	<20	R	-	T	11
26. f, 55	K	17	NP	2004	+	90	<30	R	-	G	10
27. f, 68	K	<10	NP	2004	+	270	40	R	-	G	9
28. f, 64	M	<10	NP	2004	+	560	<20	R	-	-	9
29. f, 53	M, K	-	NP	2004	-	300	20	R	-	-	8
30. f, 37	K	-	NP	2004	+	320	20	R	-	-	8
31. f, 32	M	<10	NP	2004	+	<20	-	R	-	G, T	6
32. f, 55	M	<10	NP	2004	+	30	-	R	-	G, T	6
33. f, 30	M	<10	NP	2004	+	60	40	R	-	G, T	4
34. m, 55	M	-	left	2004	-	470	160	F	RS (19 Gy)	-	4
35. m, 21	M	20	NP	2004	+	90	50	R	-	-	4

f: female; m: male; CLA: preoperative therapy with cortisol lowering agents; M: metyrapone; K: ketoconazole; MRI: magnetic resonance imaging results given as maximal diameter of the visualized tumor in mm, MRI-: no tumor visualized on the MRI; SPS: sampling of inferior petrosal sinuses; left: lateralisation to the left inferior petrosal sinus; right: lateralisation to the right petrosal sinus; NP: not performed; Histology +: evidence of ACTH producing adenoma on histological examination; Histology -: no evidence of ACTH producing adenoma on histological examination; Cortisol basal: fasting plasma cortisol level at 0800 h on the seventh day after surgery (48 h after the last dose of glucocorticoids); after Dex: plasma cortisol level at 0800 h after 1 mg dexamethasone overnight; TS: endoscopic transsphenoidal pituitary surgery; R: remission; F: failure; CR: conventional radiotherapy; RS: radiosurgery; ADX: bilateral adrenalectomy; A: androgens, D: desmopressin; E: estrogens, G: glucocorticoids, GH: growth hormone; T: levothyroxine; †patient deceased.

had mild epistaxis controlled with nasal tampons (patients 12 and 25). In one patient (patient 13), a bleeding originating in the sphenopalatine artery occurred postoperatively. This required a second exploration with successful coagulation of the artery. In this patient bleeding was not present at the end of the first surgery, most likely due to vasoconstriction by injection of epinephrine around the sphenoid ostium. The patient recovered within a few days after the second operation without other complications. Three patients had mild cerebrospinal fluid (CSF) leakage that resolved spontaneously in two of them within a few days (patients 3 and 23) and in the third patient CSF drainage was performed using a lumbar external drain (patient 22). There were two episodes of sudden drop in blood pressure that occurred one week after surgery (patients 23 and 32) caused by glucocorticoid deficiency as both patients were at that time 48 h after withdrawal of glucocorticoids and they both recovered shortly after administration of glucocorticoids. Three additional patients received transiently desmopressin due to polyuria that resumed after the first days postoperatively. One patient developed mild hyponatremia two weeks after surgery, probably due to a combination of inappropriate ADH secretion and concomitant use of thiazide diuretics. This resolved within two days after the diuretics were discontinued and after starting water restriction. There has been no complication in the failure group.

According to the last follow-up data, 22 (17 from the remission group and 5 from the failure group) of the 35 patients received substitution therapy for deficiency of one or more hormones. These data are summarized in Table 1. Of all patients, 34% required substitution with levothyroxine, 40% required substitution with glucocorticoids, 17% received estrogens or testosterone and 5.7% still required desmopressin. Six of the 14 patients still using glucocorticoids had a follow-up of less than 18 months with glucocorticoid dosages still being tapered, so a definitive statement of their adrenal function cannot yet be made.

Discussion

In the present study we report the results of endoscopic pituitary surgery in 35 consecutive patients with Cushing's disease operated in our centre. In our seven years experience, remission of hypercortisolism was achieved in 77% of the patients after the first pituitary operation and in 83% of the patients after the first and the second pituitary operation taken together. This is the largest reported series of endocrinological results in patients with Cushing's disease operated via the endoscopic technique.

Due to its recent introduction, there are only few reports describing larger series of patients with pituitary tumors operated via the endoscopic technique

(25, 29, 35). It seems that the endocrine outcomes of the patients reported in these initial series are similar to those achieved by the conventional microscopic technique. Cappabianca *et al.* (29) reported on 87 patients with various pituitary adenomas, including 8 patients with Cushing's disease, that were treated with endoscopic endonasal transsphenoidal pituitary surgery between 1997 and 1999. As remission criterion for patients with Cushing's disease the authors adopted a restoration of the circadian rhythm of cortisol together with the normalization of urinary cortisol levels. Three of these 8 patients had a macroadenoma, one of whom showed parasellar extension with incomplete third cranial nerve palsy. Among the patients with a microadenoma, one underwent a second operation one day after the first surgery because of residual tumor detected on the MRI. Only one patient (having a microadenoma) of this series remained hypercortisolemic after the pituitary operation and was treated additionally by bilateral adrenalectomy. The authors reported no complications during or after surgery in the patients with Cushing's disease. Jho *et al.* (25) reported in a series of 128 patients with pituitary adenomas operated by endoscopic transsphenoidal surgery, including 16 patients with Cushing's disease, that 70% of the patients with Cushing's disease had a (sub-)normal postoperative cortisol level. Although these results seem promising, the number of patients with Cushing's disease in these series was too small and postoperative biochemical evaluation was not extensive.

The short follow-up of the patients in our series, due to the recent introduction of the endoscopic technique in the field of pituitary surgery, does not allow us to make any comments on the long-term remission rates of our patients. As previously shown in other series of patients with Cushing's disease, recurrences may develop many years after apparently successful surgical treatment (1–3, 5, 7–10, 12–15). However, our early postoperative results of endoscopic pituitary surgery in a large number of patients with Cushing's disease are in line with the previous studies, reporting on smaller number of patients (25, 29, 35) and with the results of other large single center series of patients operated by traditional transsphenoidal pituitary microsurgery previously reported (Table 2). Early postoperative cure rates ranging from 68.5 to 87% have been reported in those large series (1–3, 5, 7–10, 12–15). These differences in remission rates can be at least, in part explained by the different remission criteria used in those studies. Based on the principle that high preoperative plasma cortisol levels suppress normal corticotroph cell function and that complete removal of a corticotroph adenoma will render the patient ACTH deficient with low to undetectable cortisol levels postoperatively, some authors have adopted as criterion for remission a postoperative plasma cortisol value of <50 nmol/L (3, 12, 42). However Yap *et al.* (3) showed that even a cortisol level <50 nmol/l early

Table 2 Review of the criteria used to define remission of Cushing's disease after pituitary surgery in the most recent published single centre series (1995–2004).

Author	Single surgeon	N	Remission criteria	Perioperative G regimen	Remission %
Sonino, 1996 (14)	Yes	103	Regression of clinical signs, UFC < 248 nmol/l and suppressable C (reference not mentioned) to low dose Dex 5–15 days from TS at least 24 h after G withdrawal.	Not mentioned	76.7
Petruson, 1997 (4)	No	31	24-h UFC < 300 nmol/ day and normal circadian rhythm of serum C, including a midnight value < 150 nmol/l within 5 weeks from TS and 48 h after G withdrawal.	100 mg HC i.v. on day 1 and 50 mg/day CA for the next 7 days	77
Estrada, 1997, 2001 (10, 45)	Yes	82	Normal UFC < 331 nmol/24 h, adequate suppression of plasma C to overnight 1 mg Dex (< 5 ug/dl, 138 nmol/l), 8 to 12 days after TS, 24 h after G withdrawal.	300 mg HC on TS day, gradually reduced till hormonal evaluation.	75.5
Blevins, 1998 (6)	Not mentioned	96	Basal C < 5 ug/dl or UFC < 15ug/24 h, or suppression of plasma and urinary C to Dex within 6 months after TS.	Not mentioned	85.6
Swearingen, 1999 (15)	No	154	Fasting serum C < 138 nmol/l and UFC < 55 nmol/l within 10 days after TS.	Not mentioned	87
Chee, 2001 (2)	Yes	61	Resolution of clinical signs, suppression of C < 100 nmol/l after 1.5–2 mg Dex overnight and reduction of C to normal range for both morning and midnight values, 48 h after G withdrawal, within 5 days after TS.	Not mentioned	78.7
Yap, 2002 (3)	Yes	97	Basal C < 50 nmol/l 3–4 days after TS, 24-h after G withdrawal.	Not mentioned	68.5
Rees, 2002 (12)	No	54	Basal C < 50 nmol/l within 1 week from TS, 24 h after G withdrawal.	100 mg/6 h HC i.v. on day 1, thereafter HC substitution.	77
Pereira, 2003 (1)	Yes	78	Regression of clinical signs, suppression of C < 100 nmol/l to 1 mg Dex and normal 24-h UFC 6 months after TS.	1 mg/12 h Dex on day 1, gradually reduced to 0.5 mg/day on day 5.	72
Rollin, 2004 (13)	Yes	41	Clinical remission, G dependence, serum C < 3 ug/dl (82,8 nmol/l) after overnight 1 mg Dex within 10–12 days after TS.	HC 100 mg i.v intraoperatively and 50 mg/6 h for 48 h, followed by prednisone 5 mg/day for 5–6 days (17 TS) and no G substitution (28 TS).	85.3
Hammer, 2004 (5)	Yes	289	Basal or 1 mg Dex suppressed C < 140 nmol/l within 1 week from TS or low/normal plasma C and UFC and no additional therapy within 6 months.	Not mentioned.	82

C: cortisol; Dex: dexamethasone; HC: hydrocortisone; CA: cortisone acetate; TS transsphenoidal pituitary surgery; G: glucocorticoids; UFC: urinary fractionated cortisol excretion.

after surgery does not always predict the long-term remission of Cushing's disease. Interestingly, Pereira *et al.* (1) recently found that a fasting cortisol level <138 nmol/L measured 3 months after the operation is a stronger predictor for long-term relapse than a plasma cortisol level <50 nmol/L measured early postoperatively. As most of our patients were treated preoperatively with cortisol lowering medication, that renders them less prone to hypocortisolism early postoperatively, we adopted as biochemical remission criterion in these patients suppression of the plasma cortisol level to 1 mg dexamethasone overnight.

The endoscopic technique requires the use of refined instruments, specific skills of the pituitary surgeon and a learning curve (20). In our centre endoscopic pituitary surgery was introduced in 1997 but it has been applied in patients with Cushing's disease only since 1998. All operations were performed by the same two experienced neurosurgeons who both were already very familiar with the endoscopic technique. As the number of patients with Cushing's disease operated per year increased, the neurosurgery team became more experienced and the number of 'failures' decreased (success percentages 60% in patients operated between 1998 and 2001 versus 88% in patients operated between 2002 and 2004). As in other studies (6, 43, 44), we found that the remission percentages were worse in patients with a macroadenoma (66% vs 79% in patients with microadenoma) and in those who did not have an ACTH producing adenoma proven on pathology (50% vs 84% in patients with positive pathology findings). While the endoscopic technique offers advantages in removing macroadenomas due to the wide-angle view, one might argue on optical grounds that it would be more difficult to discriminate the microadenomas from the surrounding tissue than when using the binocular microscopic technique. However, apart from the optics other factors may contribute as well to the successful identification and removal of microadenomas by endoscopy, e.g. the superior illumination of the surgical field. In addition, the increased elevation of the patients head and trunk during endoscopic surgery may decrease venous bleeding during surgery, providing thus a better visualization of the surgical field. Our results show that, in the hands of experienced neurosurgeons, similar remission percentages were obtained in patients with both macro- and microadenomas as in previously reported series of patients with Cushing's disease operated by the conventional microscopic technique (1–3, 5, 7–10, 12–15).

In our series there were only few serious surgical complications postoperatively. One serious bleeding requiring a reoperation took place and only one patient had CSF leakage requiring a lumbar external drain, which is similar to the experience of Hammer *et al.* (5) in their series of 289 patients with Cushing disease treated by conventional microscopic transsphenoidal surgery, in which 13 patients required a drain or surgi-

cal repairment for CSF leakage (5). An important aspect that needs to be stressed when comparing the frequency of complications reported in various studies (1–3, 5, 7–10, 12–15) is that, in these studies, different definitions are used for each complication. Moreover, as all of these studies report retrospective results, one must be careful in interpreting and comparing these results that basically rely on the accuracy by which the complications were recorded in each individual patient.

We cannot make a statement on whether applying the endoscopic technique can modify the postoperative hospitalization time. The protocol used in our hospital, both before and after the introduction of endoscopic pituitary surgery, is that all patients treated for Cushing's disease remain under clinical observation for 7 days until the early postoperative endocrine evaluation has taken place. In this way we ensured a uniform and objective early postoperative observation and registration of postoperative events.

In our series the surgery was as selective as possible in order to avoid damaging of normal pituitary tissue. Nevertheless, 63% of the patients required hormonal substitution therapy with one or more preparations at the time of last follow-up, including those requiring temporary glucocorticoid substitution. When patients requiring only glucocorticoid replacement therapy were excluded, hypopituitarism, defined as proven deficiency of at least one of the pituitary hormones, was present in 48% of the patients. However, 6 of the 14 patients who received substitution therapy with glucocorticoids at the time of data collection were in the process of decreasing their glucocorticoid substitution. In addition 5 of the patients who were receiving substitution therapy at the time of the last follow-up had a failure of the first pituitary surgery and were treated subsequently with more extensive surgery or additional radiotherapy. Furthermore, there seemed to be more combined hormone deficiencies in the patients operated in the early years (1998–2001). Our data on postoperative pituitary insufficiency are in keeping with results of previously reported series of patients operated by the conventional microscopic technique (2, 3, 8, 12, 15, 42). The rate of hypopituitarism defined as at least one deficient pituitary hormone axis after pituitary surgery ranges from 14–62% in these previous reports and seems to be related to more extensive surgical approaches.

In our study, inferior petrosal sinuses sampling was not performed in order to identify the side of the pituitary where the adenoma is located, but to confirm the pituitary origin of the hypercortisolism in patients with equivocal results of initial endocrine function tests, regardless the findings on MRI. Only in case of negative MRI investigations and a negative pituitary exploration, a hemihypophysectomy was performed, based on results of ACTH levels at the right and at the left side during inferior petrosal sinus sampling, if

available. The same strategy has been previously used in other reported series (5).

In conclusion, endoscopic transsphenoidal pituitary surgery, in the hands of experienced surgeons, resulted in our series of patients with Cushing's disease in an excellent early postoperative remission rate which was as good as those previously reported by experienced centres using conventional microscopic techniques. Surgical complications and discomfort for the patients were minimal. The question that remains to be answered is whether endoscopic pituitary surgery will also result in a favourable long-term outcome of patients with Cushing's disease. Furthermore, a randomized clinical trial, comparing endoscopic and conventional pituitary surgery in patients with Cushing's disease, is needed to determine the pros and cons of both techniques.

Acknowledgements

We gratefully acknowledge Dr. B Haugen UCHSC, Denver, USA for his valuable comments on the manuscript.

References

- Pereira A, van Aken M, van Dulken H, Schutte P, Biermasz N, Smit J, Roelfsema F & Romijn J. Long-term predictive value of post-surgical cortisol concentrations for cure and risk of recurrence in Cushing's disease. *Journal of Clinical Endocrinology and Metabolism* 2003 **88** 5858–5864.
- Chee G, Mathias D, James R & Kendall-Taylor P. Transsphenoidal pituitary surgery in Cushing's disease: can we predict outcome? *Clinical Endocrinology* 2001 **54** 617–626.
- Yap L, Turner HE, Adams C & Wass JAH. Undetectable postoperative cortisol does not always predict long-term remission in Cushing's disease: a single centre audit. *Clinical Endocrinology* 2002 **56** 25–31.
- Petruson K, Jakobsson K-E, Petruson B, Lindstedt G & Bengtsson B-A. Transsphenoidal adenomectomy in Cushing's disease via lateral rhinotomy approach. *Surgical Neurology* 1997 **48** 37–45.
- Hammer G, Tyrrell J, Lamborn K, Applebury C, Hannegan E, Bell S, Rahl R, Lu A & Wilson C. Transsphenoidal microsurgery for Cushing's disease: initial outcome and long-term results. *Journal of Clinical Endocrinology and Metabolism* 2004 **89** 6348–6357.
- Blevins L, Christy J, Khajavi M & Tindall G. Outcomes of therapy for Cushing's disease due to adrenocorticotropin-secreting pituitary macroadenomas. *Journal of Clinical Endocrinology and Metabolism* 1998 **83** 63–67.
- Barbetta L, Dall'Astra C, Tomei G, Locatelli M, Giovanelli M & Ambrosi B. Assessment of cure and recurrence after pituitary surgery for Cushing's disease. *Acta Neurochirurgica* 2001 **143** 477–482.
- Cannavo S, Almoto B, Dall'Astra C, Corsello S, Lovicu RM, De Menis E, Trimarchi F & Ambrosi B. Long-term results of treatment in patients with ACTH-secreting pituitary macroadenomas. *European Journal of Endocrinology* 2003 **149** 195–200.
- Devoe D, Miller W, Conte F, Kaplan S, Grumbach M, Rosenthal S, Wilson C & Gitelman S. Long-term outcome in children and adolescents after transsphenoidal surgery for Cushing's disease. *Journal of Clinical Endocrinology and Metabolism* 1997 **82** 3196–3202.
- Estrada J, Garcia-Uria J, Lamas C, Alfaro J, Lucas T, Diez S, Salto L & Barcelo B. The complete normalization of the adrenocortical function as a criterion of cure after transsphenoidal surgery for Cushing's disease. *Journal of Clinical Endocrinology and Metabolism* 2001 **86** 5695–5699.
- Pieters G, Hermus A, Meijer E, Smals A & Kloppenborg P. Predictive factors for initial cure and relapse rate after pituitary surgery for Cushing's disease. *Journal of Clinical Endocrinology and Metabolism* 1989 **69** 1122–1126.
- Rees D, Hanna F, Davies J, Mills R, Vafidis J & Scanlon M. Long-term follow-up results of transsphenoidal surgery for Cushing's disease in a single centre using strict criteria for remission. *Clinical Endocrinology* 2002 **56** 541–551.
- Rollin G, Ferreira N, Junges M, Gross J & Czepielewski M. Dynamics of serum cortisol levels after transsphenoidal surgery in a cohort of patients with Cushing's disease. *Journal of Clinical Endocrinology and Metabolism* 2004 **89** 1131–1139.
- Sonino N, Zielesny M, Fava G, Fallo F & Boscaro M. Risk factors and long-term outcome in pituitary-dependent Cushing's disease. *Journal of Clinical Endocrinology and Metabolism* 1996 **81** 2647–2652.
- Swearingen R, Biller B, Barker F, Katznelson L, Grinspoon S, Klibanski A & Zervas N. Long-term mortality after transsphenoidal surgery for Cushing's disease. *Annals of Internal Medicine* 1999 **130** 821–824.
- Reitmeyer M, Vance M & Laws E. The neurosurgical management of Cushing's disease. *Molecular and Cellular Endocrinology* 2002 **197** 73–79.
- Lindholt J, Juul S, Jorgensen J, Astrup J, Bjerre P, Feldt-Rasmussen U, Hagen C, Jorgensen J, Kosteljanetz M, Kristensen L, Laurberg P, Schmidt K & Weeke J. Incidence and late prognosis of Cushing's syndrome: a population-based study. *Journal of Clinical Endocrinology and Metabolism* 2001 **86** 117–123.
- Cappabianca P, Alfieri A & de Devitiis E. Endoscopic endonasal transsphenoidal approach to the sella: towards functional endoscopic pituitary surgery. *Minimally Invasive Neurosurgery* 1998 **41** 66–73.
- Cappabianca P, Alfieri A, Thernes S, Buonamassa S & de Devitiis E. Instruments for endoscopic endonasal transsphenoidal surgery. *Neurosurgery* 1999 **45** 392–396.
- Cappabianca P & de Devitiis E. Endoscopy and transsphenoidal surgery. *Neurosurgery* 2004 **54** 1043–1050.
- Cappabianca P, Cavallo LM & de Devitiis E. Endoscopic endonasal surgery. *Neurosurgery* 2004 **55** 933–941.
- Jho H-D & Carrau R. Endoscopic endonasal transsphenoidal surgery: experience with 50 patients. *Journal of Neurosurgery* 1997 **87** 44–51.
- Jho H-D & Alfieri A. Endoscopic transsphenoidal pituitary surgery: various surgical techniques and recommended steps for procedural transition. *British Journal of Neurosurgery* 2000 **14** 432–440.
- Jarrahay R, Berci G & Shahinian H. Assessment of the efficacy of endoscopy in pituitary adenoma resection. *Archives of Otolaryngology – Head and Neck Surgery* 2000 **126** 1487–1490.
- Jho H-D. Endoscopic transsphenoidal surgery. *Journal of Neurosurgery* 2001 **54** 187–195.
- Thomas R, Monacci W & Mair E. Endoscopic image-guided transethmoid pituitary surgery. *Otolaryngology Head and Neck Surgery* 2002 **127** 409–416.
- Badie B, Brooks N & Souweidane M. Endoscopic and minimally invasive microsurgical approaches for treating brain tumor patients. *Journal of Neurooncology* 2004 **69** 209–219.
- Couldwell W. Transsphenoidal and transcranial surgery for pituitary adenoma. *Journal of Neurooncology* 2004 **69** 237–256.
- Cappabianca P, Cavallo LM, Colao A, Del Basso De Caro M, Esposito F, Cirillo S, Lombardi G & de Devitiis E. Endoscopic endonasal transsphenoidal approach: outcome analysis of 100 consecutive procedures. *Minimally Invasive Neurosurgery* 2002 **45** 193–200.
- Casler J, Doolittle A & Mair E. Endoscopic surgery of the anterior skull base. *Laryngoscope* 2005 **115** 16–24.

- 31 Cho D-Y & Liau W-R. Comparison of endonasal endoscopic surgery and sublabial microsurgery for prolactinomas. *Surgical Neurology* 2002 **58** 371–376.
- 32 Ogawa T, Matsumoto K, Nakashima T, Okano M, Ono Y, Fukushima K, Yuuen K, Akagi H & Nishizaki K. Hypophysis surgery with or without endoscopy. *Auris Nasus Larynx* 2001 **28** 143–149.
- 33 White D, Sonnenburg R, Ewend M & Senior B. Safety of minimally invasive pituitary surgery (MIPS) compared with a traditional approach. *Laryngoscope* 2004 **114** 1945–1948.
- 34 Cavallo LM, Briganti F, Cappabianca P, Maiuri F, Valente V, Tortora F, Volpe A, Messina A, Elefante A & de Devitiis E. Hemorrhagic vascular complications of endoscopic transsphenoidal surgery. *Minimally Invasive Neurosurgery* 2004 **47** 145–150.
- 35 Nasser S, Kasperbauer J, Strome S, McCaffrey T, Atkinson J & Meyer F. Endoscopic transnasal pituitary surgery: report on 180 cases. *American Journal of Rhinology* 2001 **15** 281–287.
- 36 Wood PJ, Barth JH, Freedman DB, Perry L & Sheridan B. Evidence for the low dose dexamethasone suppression test to screen for Cushing's syndrome—recommendations for a protocol for biochemistry laboratories. *Annals of Clinical Biochemistry* 1997 **34** 222–229.
- 37 Newell-Price J, Morris DG, Drake WM, Korbonits M, Monson JP, Besser GM & Grossman AB. Optimal response criteria for the human CRH test in the differential diagnosis of ACTH-dependent Cushing's syndrome. *Journal of Clinical Endocrinology and Metabolism* 2002 **87** 1640–1645.
- 38 Biemond P, de Jong FH & Lamberts SW. Continuous dexamethasone infusion for seven hours in patients with the Cushing syndrome. A superior differential diagnostic test. *Annals of Internal Medicine* 1990 **112** 738–748.
- 39 Oldfield EH, Doppman JL, Nieman LK, Chrousos GP, Miller DL, Katz DA, Cutler GB Jr & Loriaux DL. Petrosal sinus sampling with and without corticotropin-releasing hormone for the differential diagnosis of Cushing's syndrome. *New England Journal of Medicine* 1991 **325** 897–905.
- 40 Plumpton FS & Besser GM. The adrenocortical response to surgery and insulin-induced hypoglycaemia in corticosteroid-treated and normal subjects. *British Journal of Surgery* 1969 **56** 216–219.
- 41 MacKenzie M, Hoefnagels W, Jansen R, Benraad T & Kloppenborg P. The influence of glycyrrhizinic acid on plasma cortisol and cortisone in healthy young volunteers. *Journal of Clinical Endocrinology and Metabolism* 1990 **70** 1637–1643.
- 42 Trainer P, Lawrie H, Verhelst J, Howlett T, Lowe D, Grossman A, Savage M, Afshar F & Besser G. Transsphenoidal resection in Cushing's disease: undetectable serum cortisol as the definition of successful treatment. *Clinical Endocrinology* 1993 **38** 73–78.
- 43 Salenave S, Gatta B, Percheur S, San-Galli F, Visot A, Lasjaunias P, Roger P, Berge J, Young J, Tabarin A & Chanson P. Pituitary magnetic resonance imaging findings do not influence surgical outcome in adrenocorticotropic-secreting microadenomas. *Journal of Clinical Endocrinology and Metabolism* 2004 **89** 3371–3376.
- 44 Barrou Z, Abecassis JP, Guilhaume B, Thomopoulos P, Bertagna X, Derome P, Bonnin A & Luton JP. Magnetic resonance imaging in Cushing disease. Prediction of surgical results. *Presse Medicale* 1997 **26** 7–11.
- 45 Estrada J, Boronat M, Mielgo M, Magallon R, Millan I, Diez S, Lucas T & Barcelo B. The long-term outcome of pituitary irradiation after unsuccessful transsphenoidal surgery in Cushing's disease. *New England Journal of Medicine* 1997 **336** 172–177.

Received 5 December 2005

Accepted 7 February 2006