

PDF hosted at the Radboud Repository of the Radboud University Nijmegen

The following full text is a publisher's version.

For additional information about this publication click this link.

<http://hdl.handle.net/2066/49382>

Please be advised that this information was generated on 2018-07-07 and may be subject to change.

We report the case of a patient with mitral valve disease and septal hypertrophy in whom systolic anterior motion and left ventricular outflow tract obstruction developed after mitral valve replacement with preservation of the mitral subvalvar apparatus. This condition was successfully treated by transaortic septal myectomy and resection of the anterior subvalvar apparatus. The present case suggests that preservation of the anterior leaflet during mitral valve replacement might be deleterious if marked septal hypertrophy is present. If preservation is mandatory, a solution of partial resection of the anterior leaflet as described by David [7] or Rose and Oz [8] might be preferred. Careful preoperative transthoracic echocardiography detection of septal hypertrophy and perioperative transesophageal echocardiography should enable the surgeon to anticipate this complication and thus select the appropriate surgical approach.

References

1. Miki S, Ueda Y, Tahata T, Okita Y. Mitral valve replacement with preservation of chordae tendineae and papillary muscles. *Ann Thorac Surg* 1995;60:225-6.
2. Morrow AG. Hypertrophic subaortic stenosis: operative methods utilized to relieve left ventricular outflow obstruction. *J Thorac Cardiovasc Surg* 1978;76:423-30.
3. Perier P, Hagen T, Stümpf Y. Septal myectomy for left ventricular outflow obstruction after mitral valve repair. *Ann Thorac Surg* 1994;57:1328-30.
4. Jiang L, Levine RA, King ME, Weyman AE. An integrated mechanism for systolic anterior motion of the mitral valve in HCMO based on echocardiographic observations. *Am Heart J* 1987;113:633-44.
5. Lee KS, Stewart WJ, Lever HM, Underwood PL, Cosgrove DM. Mechanism of outflow tract obstruction causing failed mitral valve repair. *Circulation* 1993;88:24-9.
6. DeAndra A Jr, Komeda M, Nikolic SD, Daughters GT, Ingels NB, Miller DC. Left ventricular function, twist, and recoil after mitral valve replacement. *Circulation* 1995;92:458-66.
7. David TE. Mitral valve replacement with preservation of chordae tendineae: rationale and technical considerations. *Ann Thorac Surg* 1986;41:680-2.
8. Rose EA, Oz MC. Preservation of anterior leaflet chordae tendineae during mitral valve replacement. *Ann Thorac Surg* 1994;57:768-9.

INVITED COMMENTARY

In patients with left ventricular hypertrophy, iatrogenic left ventricular outflow tract obstruction may occur after mitral valve replacement. The outflow obstruction most frequently results from implantation of a high-profile, large-diameter prosthesis. If the prosthesis is not oriented properly, a strut may obstruct the outflow tract. In a patient with a calcified annulus, such as the one described in this report, a 29-mm prosthesis may be excessively large. In addition, sparing the chordae by splitting and reattaching the segments of the anterior leaflet may have contributed to the obstruction in this case. A hypertrophied posteromedial papillary muscle with fibrosed chordae may be a contraindication to this technique.

Although no reference was made to idiopathic hypertrophic subaortic stenosis as a preoperative finding, id-

iopathic hypertrophic subaortic stenosis may also have contributed to the outflow obstruction in this patient. When mitral valve replacement is used to relieve idiopathic hypertrophic subaortic stenosis, the anterior mitral leaflet should be removed, the posteromedial papillary muscle excised, and a small-diameter, low-profile mechanical prosthesis inserted.

Denton A. Cooley, MD

*Texas Heart Institute
PO Box 20345, MC 3-258
Houston, TX 77225-0345*

Postoperative Myocardial Ischemia Caused by Chest Tube Compression of Vein Graft

Rolf Svedjeholm, MD, PhD, and Erik Håkanson, MD, PhD

Departments of Cardiothoracic Surgery and Cardiothoracic Anesthesia, Linköping Heart Center, University Hospital, Linköping, Sweden

Here we report an unexpected and possibly overlooked cause of postoperative myocardial ischemia: a chest tube compressing a vein graft. After the position of the chest tube was adjusted, graft flow was reestablished, right ventricular contractility returned, and myocardial infarction was probably prevented. The literature on chest tube complications is briefly reviewed and experience from our institution is reported.

(*Ann Thorac Surg* 1997;64:1806-8)

© 1997 by The Society of Thoracic Surgeons

A variety of complications have been described in association with closed chest tube insertion. However, data on complications from mediastinal chest tubes inserted in association with cardiac operations are limited. Here we report an unexpected and possibly overlooked cause of postoperative myocardial ischemia: a chest tube compressing a vein graft. The literature on chest tube complications is briefly reviewed and experience from our institution is reported.

The patient, a 77-year-old man with hypertension, elevated serum lipid levels, rheumatoid arthritis, and angina for 3 years was hospitalized for myocardial infarction. Subsequently unstable angina developed and a semiurgent coronary angiogram was performed. The angiogram showed an 80% left main stenosis, occlusion of the left anterior

Accepted for publication August 8, 1997.

Address reprint requests to Dr Svedjeholm, Department of Cardiothoracic Surgery, Linköping Heart Center, University Hospital, S-581 85 Linköping, Sweden (e-mail: rolf.svedjeholm@thx.us.lio.se)

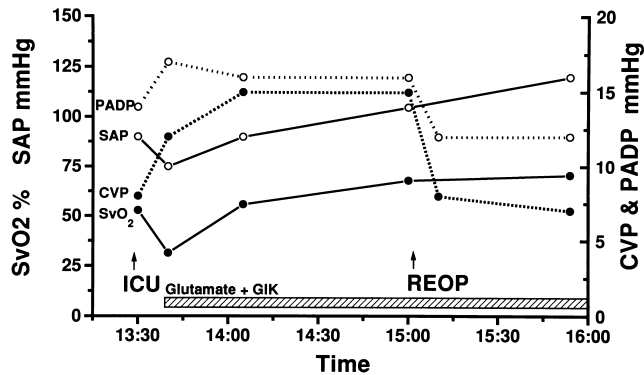


Fig 1. Hemodynamic development from the arrival of the patient to the intensive care unit (ICU) at 13:30 until the chest was closed after reoperation (15:50). Mixed venous oxygen saturation (SvO₂) is illustrated by the solid line with solid circles, central venous pressure (CVP) is illustrated by the dotted line with solid circles, systolic arterial pressure (SAP) is illustrated by the solid line with open circles, and pulmonary artery diastolic pressure (PADP) is illustrated by the dotted line with open circles. The horizontal hatched bar indicates treatment with glutamate and glucose-insulin-potassium (GIK).

descending artery, 90% stenosis of the first and second diagonal branches, 90% stenosis of the first marginal branch, 90% stenosis of the right coronary artery, 70% stenosis of the right posterior descending artery, and 50% stenosis of the posterolateral branch. Echocardiography demonstrated well-preserved left ventricular function.

The patient was accepted for an urgent coronary artery bypass operation. He received six peripheral anastomoses including left internal mammary artery grafting of the left anterior descending artery. Aortic cross-clamp time was 68 minutes and the duration of cardiopulmonary bypass was 108 minutes.

Weaning from cardiopulmonary bypass was uneventful. However, on arrival to the intensive care unit mixed venous oxygen saturation was only 53%, whereas other hemodynamic parameters were within normal limits. Within 15 minutes overt signs of cardiac failure developed: mixed venous oxygen saturation decreased to 31%, systolic arterial blood pressure decreased to 75 mm Hg, pulmonary artery diastolic pressure increased from 14 to 20 mm Hg, and central venous pressure increased from 8 to 12 mm Hg (Fig 1). Electrocardiographic monitoring did not show any evident signs of ischemia. Metabolic support with glutamate infusion ($1.5 \text{ mL} \cdot \text{kg body weight}^{-1} \cdot \text{h}^{-1}$ of a 0.125 mol/L solution) was immediately started and later supplemented with glucose-insulin-potassium. The hemodynamics stabilized and within 30 minutes mixed venous oxygen saturation had increased to 56% (another half hour later it was 68%) with a concomitant systolic arterial blood pressure of 105 to 110 mm Hg. However, as atrial filling pressures remained moderately elevated and emergency echocardiography demonstrated poor contractility of the right ventricle and the posterior left ventricular wall, a decision was taken to transfer the patient to the operating theater.

At reopening of the chest we found that the right chest tube had dislocated to the left, completely compressing the vein graft supplying the right posterior descending

artery and the posterolateral branch against the bulging right ventricle. After the position of the chest tube was adjusted, graft flow immediately returned. The ultrasonic flow meter (HT107 medical volume flowmeter; Transonic Systems Inc, Ithaca, NY) indicated a graft flow of 150 to 200 mL/min. Immediate decreases of central venous pressure from 15 to 8 mm Hg and pulmonary artery diastolic pressure from 16 to 12 mm Hg were observed. Recovery of right ventricular contractility was evident by visual inspection and was confirmed by transesophageal echocardiography. Systolic arterial blood pressure stabilized at 120 mm Hg, and there was a further increase in mixed venous oxygen saturation to 71%.

The further postoperative course was uneventful, and there were no electrocardiographic or enzymatic signs of perioperative myocardial infarction. Aspartate aminotransferase level on the morning after the operation was $1.3 \mu\text{kat/L}$. The patient was transferred to the ward on the following morning and discharged after another 6 days.

Comment

In our opinion this case demonstrates the importance of diagnostic efforts to elucidate the cause of circulatory failure developing in the intensive care unit. If potentially benign causes such as hypovolemia or tamponade can be excluded, recurrent myocardial ischemia and evolving myocardial infarction have to be considered. The present case displayed typical signs of right-sided cardiac failure and a cause of postoperative cardiac failure that was unexpected, but easy to deal with: mechanical compression of a vein graft by a dislocated chest tube against the bulging right ventricle. After the position of the chest tube was adjusted, graft flow was reestablished, right ventricular contractility returned, and myocardial infarction was probably prevented.

Reviewing the literature, we found an array of complications reported in association with closed chest tube insertion. They range from uncommon serious complications—such as direct injuries to the lung, perforation of the diaphragm and intraabdominal organs, cardiac and major vascular injury, chylothorax, infectious complications (empyema, necrotizing fasciitis), neurologic complications (Horner's syndrome, winging of the scapula, acute diaphragmatic paralysis), unilateral pulmonary edema associated with reexpansion of a pneumothorax—to more common complications such as pain, malposition of tubes, subcutaneous emphysema, and pneumothorax [1, 2]. Many of these complications are related to the closed insertion technique or withdrawal of the tubes, and the incidence depends on the experience of the physician [2]. In contrast, data in the literature on mediastinal chest tube complications in association with cardiac operations are limited. The complications may have been considered common knowledge or too benign to merit publication. Certainly, most surgeons have encountered cases of pneumothorax on withdrawal of tubes or patients suffering from pain because of chest tubes. A less common complication is entrapment of chest tubes under sternal sutures. Berkow and Salo [3] reported 5 cases among 759 median sternotomies performed. However, serious complications are also caused by chest

tubes in this setting. At our institution we are aware of a case of intestinal perforation (transverse colon) during insertion of a chest tube and a case of massive hemorrhage caused by rupture of a vein graft varicosity that was sucked into the tube. In the literature we found one report of myocardial ischemia after a congenital heart operation, presumably caused by tube suction in a closed pericardium, that resolved when suction was discontinued [4]. We suggest that postoperative myocardial ischemia due to compression of vein grafts by chest tubes may have been overlooked previously.

To conclude, the present case demonstrated an unexpected and possibly overlooked cause of myocardial ischemia: a chest tube compressing a vein graft. Furthermore, this case illustrates the value of diagnostic measures and early correction of the cause of postoperative myocardial ischemia.

References*

1. Miller KS, Sahn SA. Chest tubes: indications, technique, management and complications. *Chest* 1987;91:258-64.
2. Etoch SW, Bar-Natan MF, Miller FB, Richardson JD. Tube thoracostomy. Factors related to complications. *Arch Surg* 1995;130:521-6.
3. Berkow AE, Salo BC. The kinky chest tube: a sign of entrapment following median sternotomy. *AJR* 1977;129:883-4.
4. Chapin JW, Kahre J, Newland M. Acute myocardial ischemia caused by mediastinal chest tube suction. *Anesth Analg* 1980;59:386-7.

* A more extensive reference list can be obtained from the authors.

Truncus Arteriosus With Patent Ductus Arteriosus and Normal Aortic Arch

Dennis M. Mello, MD, Doff B. McElhinney, MS, Andrew J. Parry, MD, Norman H. Silverman, MD, and Frank L. Hanley, MD

Divisions of Cardiothoracic Surgery and Pediatric Cardiology, University of California, San Francisco, San Francisco, California

In hearts with a common arterial trunk (truncus arteriosus), there is almost always an inverse development of the aortic arch and the ductus arteriosus. Truncus with a normal aortic arch and a patent ductus is a rare echocardiographic and surgical finding. In this report, we describe 2 neonates in whom truncus arteriosus with a normal aortic arch and a medium or large patent ductus was diagnosed by preoperative echocardiography (without catheterization) and confirmed intraoperatively.

(*Ann Thorac Surg* 1997;64:1808-10)

© 1997 by The Society of Thoracic Surgeons

Accepted for publication July 14, 1997.

Address reprint requests to Dr Mello, 505 Parnassus Avenue, M593, San Francisco, CA 94143-0118.

In their 1965 report, the Van Praeghs [1] observed an inverse development of the fourth and sixth pharyngeal arches in hearts with a common arterial trunk. In specimens with a well-developed aortic arch (fourth arch derivative), the ductus arteriosus (sixth arch derivative) was nearly always absent, whereas when a large patent ductus was present, the aortic arch was interrupted. This inverse relationship has been explained on the basis of blood flow patterns in the developing heart and truncus [2]. Although hemodynamics in utero most likely contribute to this pattern, a more fundamental defect in neural crest development or migration is almost certainly involved as well. This is supported by the association of both truncus arteriosus and interrupted aortic arch with microdeletions of chromosome 22q11 [3, 4], and by the high incidence of truncus arteriosus produced by ablating the neural crest region that contributes to the development of the fourth arch in chicks [5]. There have been several reports of truncus arteriosus with a well-developed fourth arch and a patent ductus in autopsy studies [1, 6, 7], although the ductus in these cases has generally been small. In clinical series of truncus repair, there has been little mention of this finding, and it is generally known to be the case that truncus with a normal aortic arch and a patent ductus is a rare echocardiographic and surgical finding [8-10].

Between July 1992 and December 1996, primary complete repair of truncus arteriosus was performed in 30 neonates at our institution. In 2 of these patients with truncus arteriosus and a normal aortic arch, the unusual finding of a medium-sized or large patent ductus along with a normal aortic arch was observed on preoperative echocardiography (without catheterization) and confirmed intraoperatively. These cases are presented below.

Case Reports

Patient 1

The patient presented on the second day of life with respiratory distress and was diagnosed to have truncus arteriosus by echocardiography. Prostaglandins were not administered. When the patient arrived at our institution, repeat echocardiography demonstrated a typical truncus arteriosus, with normal-sized pulmonary arteries originating from the posterior aspect of the common trunk. Arising from the central left pulmonary artery, at the point of separation between the ascending aorta and pulmonary artery, a large ductus was visualized.

At 17 days of age the patient was taken to the operating room. The heart was exposed through a median sternotomy, and it was immediately observed that there was a very large patent ductus arteriosus with an intact, unobstructed aortic arch and a common arterial trunk. The left pulmonary artery and the ductus arose from the left side of the truncal root and the right pulmonary artery originated from the posterior aspect of the trunk. At the institution of bypass, the ductus was ligated and the branch pulmonary arteries were clamped. After cardioplegic arrest, a large posterior patch of truncal tissue