

PDF hosted at the Radboud Repository of the Radboud University Nijmegen

The following full text is a publisher's version.

For additional information about this publication click this link.

<http://hdl.handle.net/2066/49285>

Please be advised that this information was generated on 2017-12-06 and may be subject to change.

A patient with swollen ears and ECG abnormalities

H.W.M. van Laarhoven^{1*}, M.J. Veerkamp², M. Pruszczynski³, M. van Deuren¹

Departments of ¹Internal Medicine, ²Rheumatology and ³Pathology, Radboud University Nijmegen Medical Centre, Nijmegen, the Netherlands, *corresponding author: tel.: +31 (0)24-361 88 19, fax: +31 (0)24-354 17 34, e-mail: h.vanlaarhoven@onco.umcn.nl

KEYWORDS

Atrioventricular dissociation, polychondritis

CASE REPORT

A 30-year-old male presented to the Emergency Room complaining of feeling generally unwell with nausea and vomiting. He had been well until the morning of presentation, except for some symptoms of dyspnoea and a mild, stabbing pain in the left of his chest on deep inspiration. He had recently been investigated by the otolaryngologist because of hearing problems, and had been under the care of the rheumatologist for a year because of joint pain, red eyes and swollen painful red ears. He was taking non-steroidal anti-inflammatory drugs (NSAIDs) because of his joint pains and bronchodilatory inhalation because of asthma. On examination he was afebrile and not in distress, blood pressure 110/60 mmHg, pulse rate irregular at 50 to 60 beats/min. On both ears the antehelix was nearly absent (*figure 1*). Further general physical examination revealed no abnormalities. D-dimers were <500 ng/ml and troponin-I <0.20 µg/l, CRP was <5 (all normal). The chest X-ray was normal and the ECG is shown in *figure 2*.

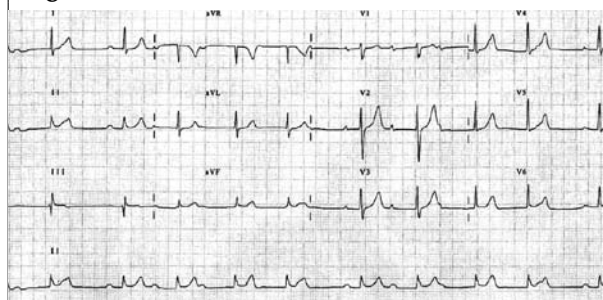
WHAT IS YOUR DIAGNOSIS?

See page 132 for the answer to this photo quiz.

Figure 1. Disappearing antehelix

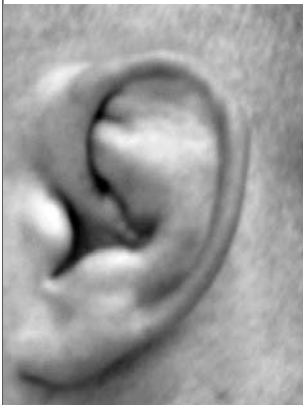

Figure 2. ECG on admission



ANSWER TO PHOTO QUIZ (ON PAGE 130)

A PATIENT WITH SWOLLEN EARS AND ECG ABNORMALITIES

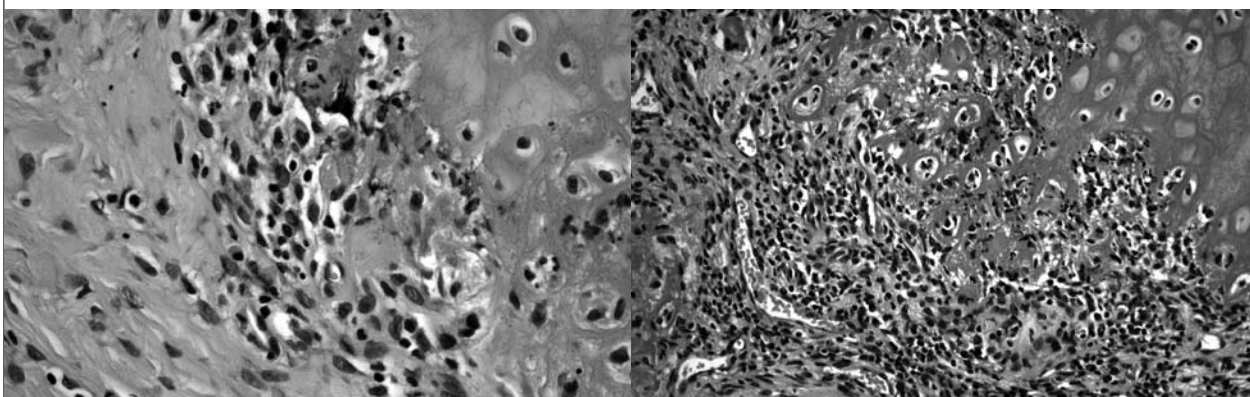
DIAGNOSIS

The patient presented with general malaise. Because of dyspnoea and chest pain, an ECG was performed. This showed a complete atrioventricular block. The abnormalities of the ears observed in this patient, together with a history of scleritis/ uveitis, hearing problems and joint pain are compatible with the diagnosis relapsing polychondritis. This diagnosis had been confirmed a few months earlier, by a biopsy of the auricle that showed chronic perichondritis with resorption of cartilage and fibrosis (figure 3). Relapsing polychondritis is characterised by recurrent inflammation and destruction of the cartilage.¹ Subacute onset of pain, redness and swelling of the ear, due to auricular chondritis, is the most frequent presenting symptom.² In addition, inflammation of the eyes, nose and laryngotracheal cartilage may occur. Involvement of the external auditory canal or Eustachian tube or serous otitis media may result in conductive hearing loss. According to the original McAdam's criteria the presence of three or more of the following clinical features is required to define relapsing polychondritis:³

- Bilateral auricular chondritis.
- Nonerosive, seronegative inflammatory polyarthritis.
- Nasal chondritis.
- Ocular inflammation (conjunctivitis, keratitis, scleritis/episcleritis, uveitis).
- Chondritis of the respiratory tract.
- Cochlear and/or vestibular dysfunction (conductive hearing loss, tinnitus and/or vertigo).

A histologically compatible biopsy (ear, nose, respiratory tract) is recommended unless the diagnosis is clinically obvious. Cardiovascular manifestations are described in 24 to 52% of the patients,⁴ heart valvular disease being the most common cardiovascular abnormality. However, in 4 to 6% of the patients a first to third degree atrioventricular block develops,⁴ most probably due to fibrosis of the cardiac conducting system.⁵ Steroids or other immunosuppressive drugs may be effective in acute inflammatory heart block, but in the long term a permanent pacemaker is often required.⁴ Regular cardiological follow-up is mandatory in patients with relapsing polychondritis. The case shows that serious cardiac complications can develop, even when disease activity on other more easily recognised sites has disappeared.

Figure 3. Microscopic picture of the excision from elastic auricular cartilage



In the perichondrium a mixed inflammatory infiltrate is seen with lymphocytes, some neutrophilic and eosinophilic granulocytes. Cellular infiltrate penetrates through the perichondrium into the cartilage, which is eroded and displays loss of basophilia. Destroyed cartilage is replaced by connective tissue. The picture is consistent with perichondritis with extension of the inflammatory process into the cartilage. This lesion in combination with clinical signs and symptoms may lead to the diagnosis of relapsing polychondritis.

REFERENCES

1. Kent PD, Michet CJ Jr, Luthra HS. Relapsing polychondritis. *Curr Opin Rheumatol* 2004;16:56-61.
2. Van Wermeskerken GK, van den Bergh WM, Frijns CJ. Diagnostic image (171). A man with a painful red ear. Relapsing polychondritis. *Ned Tijdschr Geneeskd* 2004;148:22.
3. McAdam LP, O'Hanlan MA, Bluestone R, Pearson CM. Relapsing polychondritis: prospective study of 23 patients and a review of the literature. *Medicine (Baltimore)* 1976;55:193-215.
4. Del Rosso A, Petix NR, Pratesi M, Bini A. Cardiovascular involvement in relapsing polychondritis. *Semin Arthritis Rheum* 1997;26:840-4.
5. Bowness P, Hawley IC, Morris T, Dearden A, Walport MJ. Complete heart block and severe aortic incompetence in relapsing polychondritis: clinicopathologic findings. *Arthritis Rheum* 1991;34:97-100.