



Peake, L. K., D'Abate, F., Farrah, J., Morgan, M., & Hinchliffe, R. J. (2018). The Investigation and Management of Iliac Artery Endofibrosis: Lessons Learned from a Case Series. *European Journal of Vascular and Endovascular Surgery*, 55(4), 577-583.  
<https://doi.org/10.1016/j.ejvs.2018.01.018>

Peer reviewed version

License (if available):  
CC BY-NC-ND

Link to published version (if available):  
[10.1016/j.ejvs.2018.01.018](https://doi.org/10.1016/j.ejvs.2018.01.018)

[Link to publication record in Explore Bristol Research](#)  
PDF-document

This is the author accepted manuscript (AAM). The final published version (version of record) is available online via Elsevier at <https://www.sciencedirect.com/science/article/pii/S1078588418300546?via%3Dihub>. Please refer to any applicable terms of use of the publisher.

## University of Bristol - Explore Bristol Research

### General rights

This document is made available in accordance with publisher policies. Please cite only the published version using the reference above. Full terms of use are available:  
<http://www.bristol.ac.uk/pure/about/ebr-terms>

# The investigation and management of iliac artery endofibrosis – lessons learned from a case series

Lewis K Peake<sup>a</sup>, Fabrizio D'Abate<sup>b</sup>, John Farrah<sup>b</sup>, Maria Morgan<sup>c</sup>,  
Robert J Hinchliffe<sup>a,c</sup>

a. Centre for Surgical Research, School of Social and Community Medicine, University of Bristol, UK

b. St George's University Hospitals NHS Foundation Trust, UK

c. North Bristol NHS Trust, UK

Lewis K Peake: lewis.peake@nhs.net

Fabrizio D'Abate: fabrizio.d'abate@nhs.net

John Farrah: johnfarrah@nhs.net

Maria Morgan: maria.morgan@nbt.nhs.uk

Robert J Hinchliffe: robert.hinchliffe@bristol.ac.uk

## **Corresponding Author:**

Professor Robert Hinchliffe

Professor of Vascular Surgery

Centre for Surgical Research, University of Bristol

[Robert.Hinchliffe@bristol.ac.uk](mailto:Robert.Hinchliffe@bristol.ac.uk)

**Category for submission:** original article

**Short title:** Iliac artery endofibrosis - lessons from a series

**Word count** (including abstract and references): 3319

**Key words:** Endofibrosis, External Iliac Artery, Cycling, Case Series

## Abstract

**Objectives:** To summarise the lessons learned, and evolution in local practice over the past seven years, in the investigation and surgical management of iliac artery endofibrosis.

**Design:** Retrospective case series

**Methods:** A case note review of consecutive patients investigated for suspected iliac artery endofibrosis by a single surgeon, over a seven-year period, was undertaken. Included were cases of first presentation and those who had previously undergone intervention.

**Results:** Some 63 patients were referred with suspected endofibrosis in the period 2011-17, four of whom had previously undergone surgery for the condition. After investigation of both limbs, 50 symptomatic limbs in 46 patients had a confirmed diagnosis; amongst those 46 patients, iliac artery endofibrosis was found in a further six asymptomatic, contralateral limbs. Individuals were diagnosed at a median age of 36 years (range 18 to 52) and typically presented with thigh claudication, foot numbness and limb weakness on exercise. The median delay to diagnosis was 3 years (range 0 to 14). Complete external iliac artery occlusion was a feature in three cases.

Overall, 27 limbs in 25 patients underwent operative repair; a further five limbs in four patients underwent operative repair at other centres internationally. There were three post-operative superficial wound infections (11%) and one below-knee deep vein thrombosis (3.7%). Symptoms resolved in 23 cases (85%) with a median follow up of 2.1 years (range 65 days to 5.7 years). Of the four limbs developing recurrent symptoms, two had undergone surgery for an occluded external iliac artery.

**Conclusions:** Surgical repair in the medium term appears effective in resolving symptoms in most patients. Further investigation is needed to establish the durability of surgery and to delineate the natural history of the disease.

### What this paper adds

The paper reports clinical data on a large series of patients with iliac artery endofibrosis. Through examination of current practice, it presents important learning points such as: the benefit of non-invasive diagnostic imaging, the need for awareness of disease in non-classic sites (e.g. the profunda femoris) and the evolution in surgical and peri-operative management. Most importantly, it reinforces the viability of surgical intervention as a treatment option for patients with iliac artery endofibrosis and raises awareness of a condition that is becoming increasingly identified in the patient population.

## Introduction

Iliac artery endofibrosis is a cause of claudication classically seen in young endurance athletes, especially cyclists. The condition, marked by sub-intimal fibrosis, is pathologically distinct from atherosclerosis with different risk factors. It is likely under-appreciated, with one report suggesting that haemodynamic evidence of disease is present in up to 10-20% of professional road cyclists<sup>(1)</sup>. Lack of understanding often leads to a delay in diagnosis causing anxiety, loss of earnings (professional athletes) and unnecessary musculoskeletal and neurological investigations.

Increasing awareness of iliac artery endofibrosis over recent years has led to collaborative working, diagnostic algorithms<sup>(2, 3)</sup> and a consensus report from the 'INternational Study group for Identification and Treatment of Endofibrosis (INSITE)'<sup>(4)</sup>. A recent systematic review<sup>(2)</sup> outlined findings from the handful of published series concerning iliac artery endofibrosis, individually reporting between four and 25 cases<sup>(5-8)</sup>. One additional paper detailed 350 limbs<sup>(9)</sup>, but focused predominantly on histology rather than decision making around management and surgical intervention. The remainder of the literature is made up of individual case reports focussing on short term outcomes.

This report outlines the lessons learned from a single surgeon's clinical experience of managing patients with iliac endofibrosis over a seven-year period.

## Methods

The PROCESS guideline<sup>(10)</sup> was used to report this consecutive case series. The project was registered with and approved by the North Bristol Trust audit department.

### **Data collation**

All patients referred to one surgeon with a high clinical suspicion (or existing diagnosis) of iliac artery endofibrosis between 2011 and 2017 were included. Cases included first presentations as well as those who had previously undergone endofibrosis surgery elsewhere (Figure 1). The service was run in close collaboration with sports and exercise specialists. The standard referral pathway was via a primary care physician, but was frequently made by other vascular surgeons or sports physicians.

A medical note review was undertaken for cases in this consecutive series. Sources of information were clinic letters, investigation reports, operation notes and discharge letters. The data points collected covered the assessment, peri-operative and post-operative stages.

### **Investigation protocol**

Standard investigation protocol throughout the series included an ankle-brachial pressure index (ABPI) and a Doppler Ultrasound of both lower limbs and iliac arteries, performed by an experienced vascular sonographer. In both circumstances, measurements were taken before and immediately after (within 1 minute) a period of exercise (cycling or running on static equipment), halted after exhaustion or the development of symptoms.

In all reports, a peak systolic velocity (PSV) in the EIA, common iliac artery (CIA), common femoral artery (CFA) and profunda femoris artery (PFA) was either documented, or severity of stenosis commented on (i.e. severe, moderate or mild). Ultrasound findings suggestive of

severe disease<sup>(3)</sup> included a PSV of >350cm/sec, end diastolic velocity >150 cm/sec and monophasic post-exercise Doppler waveforms throughout the iliac arteries (Table 3). Later in the series, the CFA intima-media thickness was specifically looked for and reported if thickened in comparison to the contralateral limb.

Early in the series, patients were also considered for a variety of other non-invasive and/or invasive imaging modalities, including angiogram (with vasodilator and intra-procedural pressure measurements, deemed diagnostic for endofibrosis if there was symptom recurrence plus a >10mmHg BP drop observed in the affected vessel after injecting GTN). For later cases, only an exercise ABPI and Duplex Ultrasound were felt necessary to confirm diagnosis<sup>(3)</sup>.

### **Operative protocol**

Prior to any intervention, all patients were counselled on the risks. Except for a few early patients, all received an information sheet (see Appendix 1) which explained the diagnosis, known aetiology, operative approach and rehabilitation schedule. This was produced from data analysed and presented in a contemporary systematic literature review<sup>(2)</sup> and feedback from early patients in the series. The lack of prognostic information in the literature was also explained. This resource enabled patients to reflect on their diagnosis and decide on operative intervention.

For those undergoing endarterectomy and patch angioplasty, the standard approach to the external iliac artery was via a transverse lower quadrant incision and extra-peritoneal approach. After muscle splitting, 5000 units of heparin was administered, followed by clamping of the common iliac (CIA), internal iliac (IIA) and external iliac artery (EIA) distal to the extent of disease. A further vertical groin incision was made if access to the common



femoral artery (CFA) was deemed necessary, being cautious to preserve any side branches and not splitting the inguinal ligament. Arteriotomy was performed longitudinally from the CIA bifurcation to the distal EIA or CFA depending on disease burden. Endarterectomy was then performed (except in instances where a plane could not be identified). A patch was sutured with 5-0 or 6-0 prolene. The operative site was closed in layers, using PDS for the external oblique aponeurosis over a drain (removed the following morning). Prophylactic antibiotics were administered at the start of all procedures.

Patients underwent a Duplex USS on the first post-operative day, to assess the patch and ensure no haemodynamic issues. No other investigations (e.g. angiogram) were undertaken. Patients were advised to abstain from exercise for three months (six weeks towards the end of the series) post-procedure. VTE prophylaxis (5000 IU of low molecular weight heparin) was administered peri-operatively and daily low dose (75mg) Aspirin prescribed for three months. A six-week post-op clinic appointment was arranged for wound check and a repeat Duplex USS to confirm graft patency.

For the purposes of reporting, primary and secondary patency are as defined by standard criteria guidelines<sup>(11)</sup>.

## Results

Some 63 patients were referred for assessment of possible iliac endofibrosis (Figure 1) between 2011 and 2017. Four of these had been previously diagnosed and undergone attempted repair elsewhere, but suffered from non-resolution of symptoms: one external iliac artery (EIA) shortening procedure and three endarterectomies with patch angioplasty. After clinical assessment and investigation, 56 limbs (50 symptomatic and six asymptomatic) in 46 patients (73% of all patients referred) received a positive diagnosis.. Alternative diagnoses in those with negative work-up included peripheral artery disease (atherosclerosis) or musculoskeletal pain and were referred to appropriate specialties.

Of those with confirmed iliac endofibrosis, males made up the majority (34/46, 74%), with the left leg more frequently affected (38/56, 68%). Median age at presentation was 36 (range 18 to 52) years with a median delay between symptom onset and referral of three years (range 0 to 14). In one instance, there was a possible paternal history of endofibrosis symptoms. All patients in the cohort engaged in sport to some degree (professionally or otherwise), with an extensive cycling history being a common feature (35/46, 76%). Athletes of other sporting backgrounds were also represented (six runners, four triathletes and one 'other'). The most frequent presenting symptom was thigh claudication as reported in 30 (54%) limbs. In six instances, bilateral disease was identified in patients presenting with unilateral symptoms. A femoral bruit, with the hip in flexion and/or extension, was an occasional finding documented in eight limbs (14%).

### **Investigations**

Investigation results were as described in Table 3. Pre- and post- exercise ABPI was performed in all but two cases (both had undergone surgery previously, referred with recurrent disease).

Amongst these, a post-exercise drop of  $>0.3$  (as recommended for diagnostic purposes with the INSITE collaboration<sup>(4)</sup>) was identified in 47 of 56 limbs (84%). The median ABPI drop post exercise was  $-0.48$  (range  $-0.07$  to  $-0.92$ ).

Complete occlusion (chronic) of the EIA was present in three cases. Vessel kinking (an inflection of two or more segments of an artery with an internal angle of  $90^\circ$  or less<sup>(3)</sup>) and tortuosity (nonrectilinear stretch of an artery with an internal angle of  $90^\circ$  or less<sup>(3)</sup>) was observed in a further five (one severe, three moderate and one mild kink) (9%) and three (5%) limbs respectively. Both were infrequent and not considered a feature of endofibrosis unless associated with significant stenosis.

There was variation in the reporting of intima-media thickness in the CFA. In only 24 limbs was an IMT measurement recorded, 13 of which was greater than 0.7mm. In a further four instances, IMT was simply recorded as 'thickened'. The remaining 28 limbs made no mention of IMT.

Investigation confirmed endofibrosis in 56 limbs, 50 of which were symptomatic. No asymptomatic limbs were offered surgery; annual surveillance was recommended.

### **Operative**

Some 27 limbs proceeded to surgery, the majority undergoing an EIA endarterectomy and patch angioplasty (Figure 1) from the CIA bifurcation to the limit of disease burden as assessed intra-operatively; the CFA was involved in 13 instances. Endarterectomy was not performed on the EIA after being transected at the CIA and externalised, as presented elsewhere in the literature<sup>(12)</sup>. Rather, an arteriotomy was performed at the point of fibrotic disease and patch angioplasty undertaken with the vessel in its native position. A venous patch was used for the

first 12 cases; the rest made use of Bovine pericardium (XenoSure® Biologic Vascular Patch, 1cm x 10cm, LeMaitre™). A laparoscopic approach was used in four cases.

In one instance, a full endarterectomy was not performed; the vessel wall was thickened but no dissection plain identifiable. A patch was nevertheless positioned, improving vessel circumference and patency of flow.

Isolated endofibrosis in the profunda femoris artery was a feature in one case, treated by profunda endarterectomy and patch angioplasty extending in to the CFA.

Only two of the three cases of complete occlusion underwent surgery (the other declining intervention). One underwent a CIA to CFA bypass (having re-occluded following an endarterectomy and patch angioplasty elsewhere, the cause for which was not identified) and has now stopped all cycling. The other proceeded to a thrombectomy and endarterectomy.

### **Post-operative**

Observed post-operative complications included three superficial wound infections and one below-knee deep vein thrombosis of which there were no sequelae (Grade II, Clavien-Dindo classification). There was one instance of benign venous patch dilatation (2cm) which has remained static and not to-date required re-intervention. Numbness in the distribution of the lateral cutaneous nerve of thigh was reported in five limbs (19%). This feeling of numbness has improved objectively over time. There was no short or long-term mortality associated with intervention.

For the 27 limbs operated on, 24 have maintained primary patency at the time of reporting (89%), with a median follow up of 2.1 years (range 30 days to 5.7 years). There was one instance of secondary patency (complete occlusion of a CIA to CFA bypass graft, for which no

cause was identified, that underwent successful thrombolysis) and two of primary assisted patency. Of these, one suffered graft stenosis and required angioplasty whilst the other developed graft stenosis (following laparoscopic repair) which resolved after an open procedure six-months later.

Overall 23 limbs (85%) reported no ongoing symptoms after surgical intervention. There was one instance of non-resolution of symptoms (a laparoscopic repair, which then proceeded to an open re-do) and three instances of return of pre-operative symptoms.

Patients undergoing operative repair are offered clinical review and Duplex ultrasound on an annual basis to assess symptomatology and patency of vessels. Those that were managed conservatively were not offered regular follow up, but advised to re-present in there was a change in clinical picture.

## Discussion

This consecutive case series has highlighted the local evolution in diagnosis and management of iliac artery endofibrosis, as well as demonstrating some of the issues that still exist. There have been many lessons learnt over the past seven years.

### **Investigations**

There has been a refinement in the diagnostic process for endofibrosis (Figure 2 for proposed algorithm). Cross sectional imaging (such as CT and MR angiography) and invasive modalities such as angiogram appeared to offer little added value as the sensitivity of exercise ABPI and ultrasound Doppler became apparent<sup>(3)</sup>. In this author's opinion, with the right technical expertise, ABPI and Doppler ultrasound are sufficient to diagnose iliac artery endofibrosis and cross-sectional imaging should be reserved for: instances of diagnostic uncertainty, where the extent of proximal disease cannot be visualised through USS, or for the panning of re-intervention.

All patients that present with unilateral symptoms should have both lower limbs fully investigated to allow for comparison of findings. In all, 50 limbs with symptomatic endofibrosis were assessed; in six instances a degree of disease was also identified in an asymptomatic, contralateral limb.

The way in which ultrasound is used has also changed. The authors recommend Duplex assessment throughout the PFA in addition to more typical sites such as the EIA. Similarly, early identification of an increased intima-media thickness and flow limitations through the CFA can help guide the surgeon to extend the endarterectomy from the EIA into this vessel. When doing so, it is not necessary to transect the EIA or split the inguinal ligament.

## **Operative**

In all cases, the decision to proceed to surgical intervention was multifactorial and considered severity of symptoms, impact on quality of life and level of disease.

This service now routinely favours bovine patches over venous or synthetic materials . On one occasion, following use of a vein patch, we observed a benign dilatation post-operatively (stable, not requiring re-intervention). As a result, in contrast to INSITE recommendations of venous patches<sup>(4)</sup>, we now use bovine patches routinely.

A laparoscopic approach was undertaken in four limbs during this series. One of these limbs required an open re-intervention and, anecdotally, there seemed to be little clinical benefit to a minimally invasive technique. It presented a greater technical challenge and on average was twice the duration of an open approach.

In this series, vessel shortening was only performed in two instances, and always as part of a 'standard' endarterectomy and patch angioplasty procedure. This was only done when there appeared to be significant lengthening and kinking of the artery as judged intra-operatively. One limb was referred to our service that had previously undergone a stand-alone EIA shortening, from which the patient had no clinical benefit.

Finally, a stent was never placed therapeutically for any patient in this series, as per recommendations from the INSITE group<sup>(4)</sup>. Percutaneous angioplasty was performed in two limbs but never as a definitive procedure.

## **Post-operative**

Outcomes to date have been promising. A large proportion of limbs (85%) were, and remain to be, symptom free after surgical intervention and suffer no ongoing impairment in sporting

ability. Operative complications tended to be non-serious (e.g. mild wound infections), with one incidence of below knee DVT.

Numbness in the distribution of the lateral cutaneous nerve of thigh was not uncommon post-operatively and is an important outcome of which to counsel patients; although the neurology largely improved with time, the effects on a population focused on physical performance (i.e. professional athletes) can be substantial. Caution should be taken intra-operatively to avoid excessive retraction of the inguinal ligament, to reduce the risk of intra-operative neuropraxia.

Abstinence of exercise for a time post-op is vital for the arterialization of any graft; early exercise could increase the risk of vein graft dilatation. Initially a three-month abstinence was recommended; this was relaxed to six weeks and was more agreeable to the patient population.

Of the four cases with non-resolution of symptoms, half had originally presented with complete occlusion. Occlusion was not always preceded by severe, worsening claudication symptoms and could support the argument for screening amongst at-risk populations. In this series, the median lag between symptoms onset and diagnosis was three years (range 0 – 14 years).

The predominance towards endofibrosis disease in the left leg is well described elsewhere <sup>(2, 5, 12, 13)</sup> but remains unexplained and needs further investigation. Similarly, outcomes for endofibrosis cohorts managed non-operatively are poorly reported in the literature.

The final lesson learnt is how difficult it is counselling patients on the natural history of the condition. Prospective follow up is difficult in this young, international cohort often time



limited by professional sporting pressures. Only robust, prospective studies will be able to capture data on cycling habits after diagnosis (with or without intervention) and help to inform the natural history.

Following some high-profile cases within the cycling community, Iliac artery endofibrosis is being identified more frequently, but surgery remains the only definitive treatment option. This series is one of the largest presented and demonstrates a successful approach to investigating and managing the condition. It reinforces work done by the INSITE group<sup>(4)</sup> to standardise diagnostic work-up. Further work is needed to better understand the pathogenesis of the condition and what factors lead to development of endofibrosis in some athletes but not others. Prospective data in the form of a registry would be a useful tool to collect post-operative outcomes and to draw conclusions about the conditions natural history.

## Author Declarations

There are no conflicts of interest declared by any authors in relation to the publication of this article. This work did not receive any specific grant from funding agencies in the public, commercial, or not-for-profit sectors. The findings formed the basis of an award-winning presentation at the South West Vascular Surgeons Meeting 2017, Cheltenham, United Kingdom.

## References

1. Hinchliffe RJ. Iliac Artery Endofibrosis. *EJVES*. 2016;52(1):1-2.
2. Peach G, Schep G, Palfreeman R, Beard JD, Thompson MM, Hinchliffe RJ. Endofibrosis and kinking of the iliac arteries in athletes: a systematic review. *EJVES* 2012;43(2):208-17.
3. D'Abate F, Paraskevas KI, Oates C, Palfreeman R, Hinchliffe RJ. Color Doppler Ultrasound Imaging in the Assessment of Iliac Endofibrosis. *Angiology*. 2016.
4. Collaborators I. Diagnosis and Management of Iliac Artery Endofibrosis: Results of a Delphi Consensus Study. *EJVES*. 2016;52(1):90-8.
5. Schep G, Bender MH, van de Tempel G, Wijn PF, de Vries WR, Eikelboom BC. Detection and treatment of claudication due to functional iliac obstruction in top endurance athletes: a prospective study. *Lancet*. 2002;359(9305):466-73.
6. Alimi YS, Accrocca F, Barthelemy P, Hartung O, Dubuc M, Boufi M. Comparison between duplex scanning and angiographic findings in the evaluation of functional iliac obstruction in top endurance athletes. *EJVES*. 2004;28(5):513-9.
7. Rousselet MC, Saint-Andre JP, L'Hoste P, Enon B, Megret A, Chevalier JM. Stenotic intimal thickening of the external iliac artery in competition cyclists. *Hum Pathol*. 1990;21(5):524-9.
8. Smith WB, Olmsted KA, Zierler ER. Iliac Artery Endofibrosis in Athletes: A Case Series. *JVU*. 2008;32(4):7.
9. Feugier P, Chevalier JM. Endofibrosis of the iliac arteries: an underestimated problem. *Acta Chir Belg*. 2004;104(6):635-40.

10. Agha RA, Fowler AJ, Rajmohan S, Barai I, Orgill DP, Group P. Preferred reporting of case series in surgery; the PROCESS guidelines. *Int J Surg.* 2016;36(Pt A):319-23.
11. Rutherford RB, Baker JD, Ernst C, Johnston KW, Porter JM, Ahn S, et al. Recommended standards for reports dealing with lower extremity ischemia: revised version. *J Vasc Surg.* 1997;26(3):517-38.
12. Bender MH, Schep G, Bouts SW, Backx FJ, Moll FL. Endurance athletes with intermittent claudication caused by iliac artery stenosis treated by endarterectomy with vein patch--short- and mid-term results. *EJVES.* 2012;43(4):472-7.
13. Rouvière O, Feugier P, Gutiérrez JP, Chevalier JM. Arterial endofibrosis in endurance athletes: angiographic features and classification. *Radiology.* 2014;273(1):294-303.

## Tables

**TABLE 1: Data points collected from clinical records**

Patient information	Gender Presenting symptoms Laterality (left / right / both) Age at symptoms onset Age at diagnosis confirmation Occupation Sporting activity and competition level Smoking history Other cardiovascular risk factors
Clinical assessment	Presence of femoral bruit ABPI at rest ABPI after exercise Ultrasound sonography findings Other imaging findings (angiogram/DSA, CT angiogram)
Peri-operative	Procedure performed Date of procedure Patch material, where applicable (vein, bovine) External iliac artery anatomy, where documented in operation note Pre-discharge ultrasound findings
Post-operative	Period abstained from exercise Duration aspirin taken Symptomology after re-introduction of exercise Post-op complications Re-intervention, where applicable Last appointment date

DSA: Digital Subtraction Angiography

*Data points as collected for the case series. Data was collected from a variety of sources including clinical notes, investigation reports and discharge summaries.*

**TABLE 2: Demographics and examination findings of endofibrosis cases.**

Gender:		
	Male (%)	34 (74)
	Female (%)	12 (26)
Median age at diagnosis, <i>years</i> (range)		
		36 (18 – 52)
Median delay to referral, <i>years</i> (range)		
		3 (0 – 14)
Laterality of symptoms, <b>n=56 limbs</b> :		
	Left (%)	37 (66)
	Right (%)	13 (23)
	Asymptomatic* (%)	6 (11)
Primary sport, <b>n=46 patients</b> :		
	Cycling <sup>†</sup> (%)	35 (76)
	Running (%)	6 (13)
	Triathlon (%)	4 (9)
	Other (%)	1 (2)
Sporting level achieved, <b>n=46 patients</b> :		
	Professional / Ex-professional (%)	27 (59)
	Elite amateur <sup>‡</sup> (%)	3 (6)
	Amateur (%)	16 (35)
Documented smoking history		
		5 <sup>§</sup>
Documented cardiovascular risk factors		
		5 <sup>#</sup>
Presenting symptoms, <b>n=56 limbs</b> :		
	Thigh claudication / pain (%)	30 (54)
	Paraesthesia / numbness (%)	15 (27)
	Weakness / lack of power (%)	12 (21)
	Heaviness / 'dead-leg' feeling (%)	5 (9)
	Pallor / cold leg (%)	2 (4)
	Asymptomatic (%)	6 (11)
Clinical assessment		
	Femoral bruit (%)	8 (14)

*Endofibrosis in males was seen more frequently, with the left leg being more commonly affected than the right. More cases were seen in those who identified as professional athletes, as those who engaged in sport extensively but recreationally. A smoking history was seen in a limited number of cases. Symptoms, which could be multiple, most frequently included thigh claudication and paraesthesia in the limb.*

*\*Cases where disease was identified bilaterally, but presented with only unilateral symptoms. Includes one left limb (total 38) and five right limbs (total 18). <sup>†</sup>Includes any form of cycling i.e. road, track, mountain.*

*<sup>‡</sup>Defined as elite amateur where he/she engages in competitions but does not do so professionally. <sup>§</sup>All ex-smokers. <sup>#</sup>Includes three instances of ischaemic heart disease in the family and two cases of known hypercholesterolemia.*

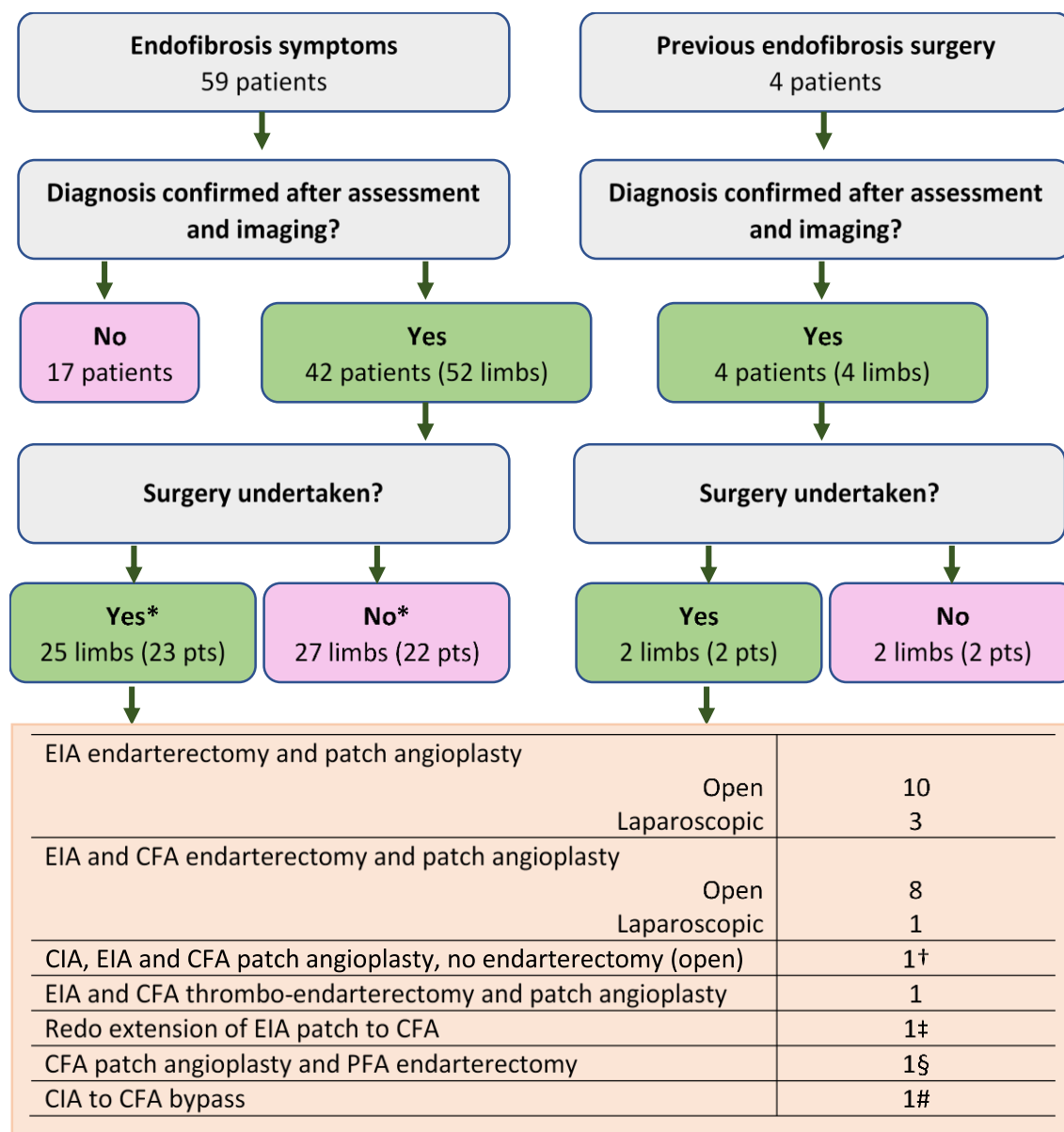
**TABLE 3: Summary of Ultrasound Duplex findings in limbs with confirmed endofibrosis**

<b>Degree of stenosis*, n=56 limbs:</b>		
	Severe stenosis (>75%) (%)	40 (71.)
	Mild (<50%) or moderate (50-74%) stenosis (%)	13 (23)
	Complete occlusion (%)	3 (5)
<b>Degree of stenosis in limbs operated on, n=32 limbs<sup>†</sup>:</b>		
	Severe stenosis (>75%) (%)	24 (75)
	Mild (<50%) or moderate (50-74%) stenosis (%)	6 (19)
	Complete occlusion (%)	2 (6)
<b>Vessel affected, n=56 limbs</b>		
	Common iliac artery (%)	3 (5.4)
	External iliac artery (%)	49 (87.5)
	Internal iliac artery (%)	1 (1.8)
	Common femoral artery (%)	8 <sup>‡</sup> (14.3)
	Profunda femoris artery (%)	5 (8.9)
<b>Other findings, n=56 limbs</b>		
	EIA kink <sup>§</sup>	5 (9)
	EIA tortuosity <sup>#</sup>	3 (5)
	Dissection flap	3 (5)
	<b>Intima-media thickness &gt;0.7mm in EIA, CFA or PFA</b>	<b>13 (23.2)</b>

*\*Degree of stenosis as documented by ultrasonographer at time of imaging, or inferred by a significantly raised PSV (>350cm/s) in an affected vessel and monophasic wave forms post-exercise. <sup>†</sup>Includes five cases that underwent surgical intervention elsewhere. <sup>‡</sup>A further 4 cases (10 in total) had evidence of CFA disease when assessed intra-operatively. <sup>§</sup>Defined as an inflection of two or more segments of an artery with an internal angle of 90° or less. <sup>#</sup>Defined as a nonrectilinear stretch of an artery with an internal angle of 90° or less.*

## Legends for illustrations

**FIGURE 1: Referral pathways, investigation outcomes and operations performed**



*In total, 63 patients were referred for assessment. Some 56 limbs across 46 patients were confirmed to be affected. Some 27 limbs in 25 patients underwent operative repair. \*10 patients had bilateral disease: two patients underwent bilateral repair (not done concurrently), three patients had one limb operated on and five underwent no treatment. Of the 29 limbs that did not proceed to surgery, five (in four patients) underwent operative repair in other centres including three outside the United Kingdom. A further number are still considering surgery.*

*†In one instance, no plain could be identified intra-operatively for endarterectomy and so a patch angioplasty alone was performed. ‡On one occasion, a patch placed in another institution was extended into the CFA due to ongoing symptoms. §There was one instance of endofibrosis presenting exclusively in the profunda femoris (PFA) and so endarterectomy was performed for this vessel. #A common iliac to common femoral bypass was performed in one case of complete obstruction.*



**FIGURE 2: A proposed diagnostic algorithm for external iliac artery endofibrosis**

