

## PDF hosted at the Radboud Repository of the Radboud University Nijmegen

The following full text is a publisher's version.

For additional information about this publication click this link.

<http://hdl.handle.net/2066/27150>

Please be advised that this information was generated on 2018-07-07 and may be subject to change.

# De-novo expression of CD44 and survival in gastric cancer

Barbara Mayer, Karl W Jauch, Ursula Günthert, Carl G Figdor, Friedrich W Schildberg, Ilona Funke, Judith P Johnson

## Summary

We have examined the cell surface molecule CD44, which is attracting interest because of reports that isoforms are associated with metastasis. The prognostic value of CD44 expression has yet to be assessed for a solid tumour.

Benign (59) and malignant (primary 61, metastatic 59) gastric tissues were examined with antibodies directed at epitopes common to known CD44 isoforms. Normal mucosa was CD44 negative. In atrophic gastritis and intestinal metaplasia expression was restricted to the epithelial cells of the basal glands and was positively correlated with an increased leucocyte infiltrate and with the expression of HLA DR by mucosal cells. These observations suggest a role for chronic inflammation in the induction of CD44 expression on benign mucosa. No such association was observed between inflammatory infiltrate and CD44 expression on gastric tumours.

CD44 expression, observed in only 49% of primary tumours, was associated with distant metastases at time of diagnosis and, among 31 curatively resected patients, with tumour recurrence ( $p=0.0014$ ) and increased mortality ( $p=0.001$ ) during follow-up averaging 17 months. When we used an antibody directed against the CD44 variant exon 9v, we found a good correlation between the expression of total CD44 and of exon 9v containing isoforms, and 9v expression in primary tumours was significantly and positively associated with tumour recurrence and mortality.

*Lancet* 1993; **342**: 1019–22

## Introduction

CD44 is a highly glycosylated cell surface molecule which appears to be involved in cell-cell and cell-matrix interactions.<sup>1–3</sup> CD44 is a family of molecules encoded by one gene but differing in the number and combination of variant exons inserted into the framework ("standard") form.<sup>3,4</sup> Interest has been aroused by the discovery that the expression of one isoform of CD44 distinguished metastatic from non-metastatic adenocarcinoma cell lines in the rat.<sup>5</sup> Proof that CD44 itself has a role in metastasis came from the demonstration that transfection with cDNA encoding this isoform converted non-metastatic carcinoma and sarcoma rat cells into metastatic cells.<sup>5</sup>

Human tumours express a variety of CD44 isoforms<sup>6–10</sup> and a role for this molecule has been suggested in the development of metastatic potential in man—indeed, high CD44 expression has been shown to correlate with tumour dissemination and poor prognosis in diffuse large-cell lymphoma.<sup>11</sup> Gastric carcinoma seemed an appropriate malignancy in which to look at CD44 expression and progression in a solid tumour because the different histomorphological types differ both in their organotropism to distant metastases and in their prognosis.<sup>12,13</sup>

## Materials and methods

### Tissue specimens

Gastric mucosa and primary tumour samples from 60 patients with previously untreated gastric cancer undergoing gastrectomy at the Klinikum Grosshadern, Munich, were obtained up to 30 min after surgical removal, snap frozen in liquid nitrogen, and stored at  $-80^{\circ}\text{C}$ . From patients with advanced cancer, samples were also obtained from regional lymph-node metastases (32) and from distant metastases to liver (10) and omentum (17). Cryostat sections ( $5\ \mu\text{m}$ ) of specimens from 1 patient were placed on the same slide to compare directly primary and metastatic tumours with normal.

### Clinicopathological indices

All histopathological and prognostic factors were evaluated by pathologists on internationally established criteria. Benign mucosa was assessed for gastritis and intestinal metaplasia. Staining results in primary tumours were correlated with prognostic features, including tumour-node-metastasis (TNM) staging, Borrmann, Lauren, and WHO classifications, grading, tumour localisation, tumour diameter, and lymphatic invasion.<sup>14</sup> Since histology often varied within the same tumour the diagnosis was based on the dominant pattern.

### Monoclonal antibodies and immunoperoxidase staining

Monoclonal antibodies NKI-P1 (IgG<sub>1</sub>, ascites, diluted 1 in 1000)<sup>15</sup> and 25-32 (IgG<sub>1</sub>, supernatant, diluted 1 in 100)<sup>16</sup> are directed against the CD44 standard form. CD44 9v expression was determined with FW11-24 (IgG<sub>1</sub>, supernatant, diluted 1 in 50) (unpublished). Epithelial cells were identified with HEA125, directed against a 3 kD molecule common to simple epithelium (IgG<sub>1</sub>, diluted 1 in 100; Dako) and leucocytes with anti-CD45 M701 clone 2B4 (IgG<sub>1</sub>, diluted 1 in 100; Dako). HLA DR

Department of Surgery, Klinikum Grosshadern, University of Munich, 81366 Munich, Germany (B Mayer BS, K W Jauch MD, F W Schildberg MD, I Funke MD); Basel Institute for Immunology, Basel, Switzerland (U Günthert PhD); Division of Immunology, Netherlands Cancer Institute, Amsterdam (C G Figdor PhD); and Institute for Immunology, University of Munich (J P Johnson PhD)

Correspondence to: Ms Barbara Mayer



Index	No*	CD44 expression		p
		Positive	Negative	
<b>Leucocyte infiltrate</b>	56			0.0003
Weak		2	20	
Moderate, strong		30	4	
<b>HLA DR expression</b>	55			0.0003
Positive		32	7	
Negative		2	14	
<b>Gastritis</b>	59			0.0002
Absent, superficial		1	20	
Atrophic		33	5	
<b>Intestinal metaplasia</b>	46			0.0003
Yes		21	2	
No		7	16	

\*Variation in numbers reflects fact that not all information was available for every patient.

Table 1: CD44 expression in benign gastric mucosa correlated with histopathological and prognostic indices

expression was evaluated with L243 (IgG2a; ATCC) as undiluted culture supernatant. Isotype-matched myeloma proteins MOPC21 (IgG<sub>1</sub>) and UPC10 (IgG<sub>2</sub>), both at 10 µg/mL (Sigma), were negative controls.

Tissue sections were stained with an indirect immunoperoxidase technique.<sup>14</sup> The percent of CD44, CD44 9v, and HLA DR positive epithelial cells was estimated together with HEA125 expression pattern on consecutive sections. The degree of leucocyte infiltration was judged by the proportion of cells in the section that were CD45 positive: weak=single dispersed cells between the glands, moderate=under 50% of the cells accumulated in the lamina propria between the glands, strong=over 50% of the cells accumulated in the lamina propria between the glands.

#### Statistical analysis

The correlation between CD44 expression and clinicopathological indices was analysed by Fisher's exact test. Correlation between the fraction of CD44 positive epithelial cells in gastric mucosa and autologous primary tumours and in primary and autologous metastatic lesions was assessed by the Spearman rank correlation coefficient. The same test was used to correlate CD44 and CD44 9v expression in individual tissues. Overall survival rates were calculated by the Kaplan-Meier method, and for differences between curves the p value was calculated by logrank test.

## Results

#### CD44 in benign gastric mucosa

Despite strong reactivity of a wide variety of different cell types, CD44 expression on epithelial cells was seen only in 34 (58%) of the 59 samples of benign gastric mucosa. Expression was restricted to the gastric glands near the muscularis mucosae and extending up the basal third of the mucosa, the area where epithelial cells also express the HNK-1 (CD57) epitope.<sup>17</sup> Although the fraction of positive glands varied (from below 10% to above 80%), CD44 expression was never observed on the upper part of the glandular area near the gastric pits, on the epithelium lining the pits, or at the luminal surface.

CD44 expression on glandular cells was associated with moderate or strong leucocyte infiltration (table 1). Pits, however, were CD44 negative even in the presence of strong leucocyte infiltration. With two exceptions, CD44-positive gastric mucosa also expressed HLA DR, indicating activation of epithelial cells. In contrast to the spatially restricted pattern of CD44 expression, HLA DR positive cells were found throughout the mucosal cells, from the basal part of the glands up to the epithelial surface.

These histological observations suggest that CD44 expression on benign mucosa is associated with inflammation. A significant correlation was seen between

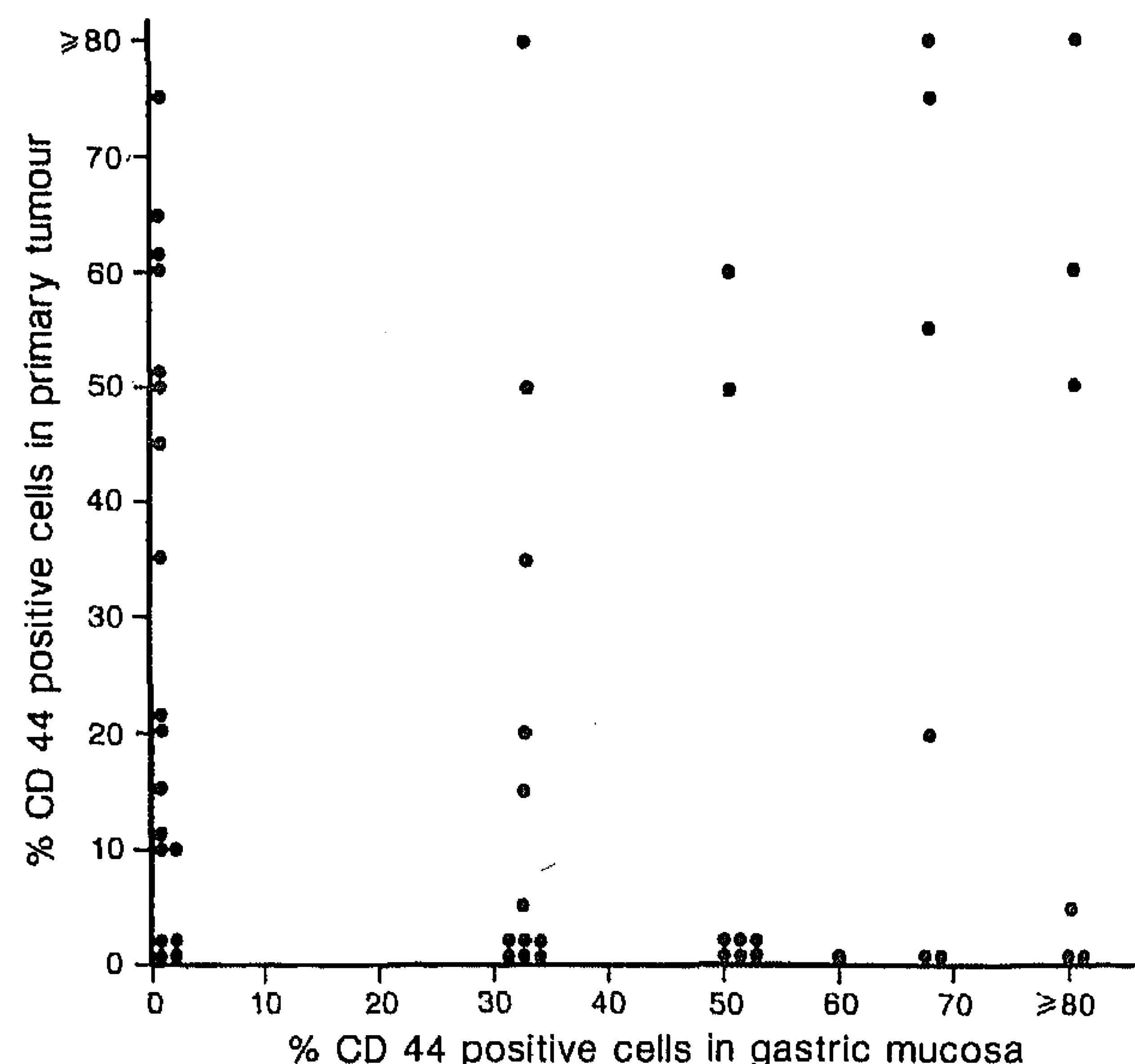


Figure 1: CD44 expression in gastric mucosa and in autologous primary tumours in 51 individual patients

Correlation not significant (Spearman's  $r=0.019$ ,  $p=0.45$ ).

the presence of CD44 positive glandular cells and both atrophic gastritis and intestinal metaplasia, a condition always accompanied by atrophic gastritis. Specimens classified as normal or as only superficial gastritis were CD44 negative (table 1).

#### CD44 in primary gastric cancer

CD44 expression was observed in 30 (49%) of 61 primary gastric carcinomas. The fraction of CD44 positive cells ranged from 15% to more than 80%. However, leucocyte infiltration was not associated with CD44 positive tumours and co-expression of CD44 and HLA DR antigens was not found (table 2).

Despite a correlation between CD44 in primary tumours and autologous gastric mucosa (table 2), there was no correlation between the extent of CD44 expression in the two specimens (figure 1). 14 patients with CD44 positive tumours had negative mucosae and 17 patients with CD44 negative tumours had positive mucosae.

CD44 expression was correlated with tissue differentiation (Lauren and WHO classifications). Differentiated tumours with glandular structures were more often CD44 positive than were undifferentiated carcinomas consisting of diffusely arranged tumour cells (table 2). Evaluation of other prognostic factors (table 2) revealed a significant correlation only between CD44 expression and M-stage. Patients with distant metastases apparent at the time of surgery had CD44 positive primary tumours more often than patients without detectable distant metastases.

#### CD44 expression in metastatic lesions

CD44 expression was observed in 45 (76%) of 59 metastatic lesions (lymph node 32, liver 10, omentum 17) but no differences in CD44 expression were found for metastatic lesions at the three locations. As in the primary tumours no correlation was found between CD44 expression and leucocytes ( $p=0.09$ ), and there was no co-expression of CD44 and HLA DR antigens ( $p=0.32$ ).

In most cases CD44 positive metastases derived from patients with CD44 positive primary tumours and CD44

Index	No	CD44 expression		p
		Positive	Negative	
<b>Leucocyte infiltrate</b>	58			0.12
Weak		21	17	
Moderate, strong	7	13		
<b>HLA DR expression</b>	55			0.58
Positive		9	9	
Negative	19	18		
<b>CD44 expression on benign gastric mucosa</b>	51			0.04
Positive		16	17	
Negative	14	4		
<b>Tissue architecture (Lauren)</b>	61			0.002
Intestinal		24	12	
Diffuse	6	19		
<b>Tissue architecture (WHO)*</b>	61			0.004
Adenocarcinoma		22	11	
Signet carcinoma	8	20		
<b>Cellular differentiation</b>	61			0.64
G1/2		10	10	
G3/4/X	20	21		
<b>Tumour localisation</b>	61			0.07
Cardia		12	6	
Other	18	25		
<b>Tumour diameter</b>	61			0.33
≤5 cm		9	12	
>5 cm	21	19		
<b>Gross appearance</b>	60			0.15
Borrmann B1/2		18	13	
B3/4	12	17		
<b>Lymphatic vessel invasion</b>	58			0.24
No		3	6	
Yes	26	23		
<b>Depth of invasion</b>	61			0.45
T1/2		17	16	
T3/4	13	15		
<b>Nodal status</b>	61			0.1
N0		3	8	
N1/2	27	23		
<b>Distant metastasis</b>	61			0.02
M0		11	21	
M1	19	10		

\*Adenocarcinoma includes papillary, tubular, and mucinous adenocarcinomas and separates them from signet ring cell carcinomas.

Table 2: CD44 expression in primary gastric cancer correlated with histopathologic and prognostic indices

negative metastases derived from CD44 negative primaries, but the correlation was not strong (Spearman's  $r=0.349$ ,  $p=0.009$ ) (figure 2). 10 patients with CD44 negative primary tumours had CD44 positive metastases (15–80% positive cells) and 5 patients with CD44 positive tumours developed CD44 negative metastatic lesions.

#### Expression of CD44 exon 9v

The antibodies used to examine CD44 expression react with several isoforms. To obtain information on CD44 isoform expression in gastric epithelial cells, tissue sections still available from the non-isoform-specific studies were stained with a monoclonal antibody directed against the variant exon 9v. In contrast to total CD44 reactivity, 9v expression was restricted to epithelial cells. Lymphoid cells, connective tissue, endothelial cells, and smooth muscle cells were 9v negative.

31 benign gastric mucosa specimens and 35 primary and 44 metastatic lesions were examined for reactivity with anti-CD44 9v. In all cases a good correlation was observed between reactivity with anti-CD44 and with anti-CD44 9v in terms both of the number of positive lesions and the percent of positive cells (benign mucosae,  $r=0.846$ ,  $p=0.0001$ ; primary lesions,  $r=0.863$ ,  $p=0.0001$ ; metastatic lesions,  $r=0.341$ ,  $p=0.01$ ). Even so in some lesions, the fraction of 9v positive cells appeared to be less than the fraction of CD44 positive cells. This was especially true for

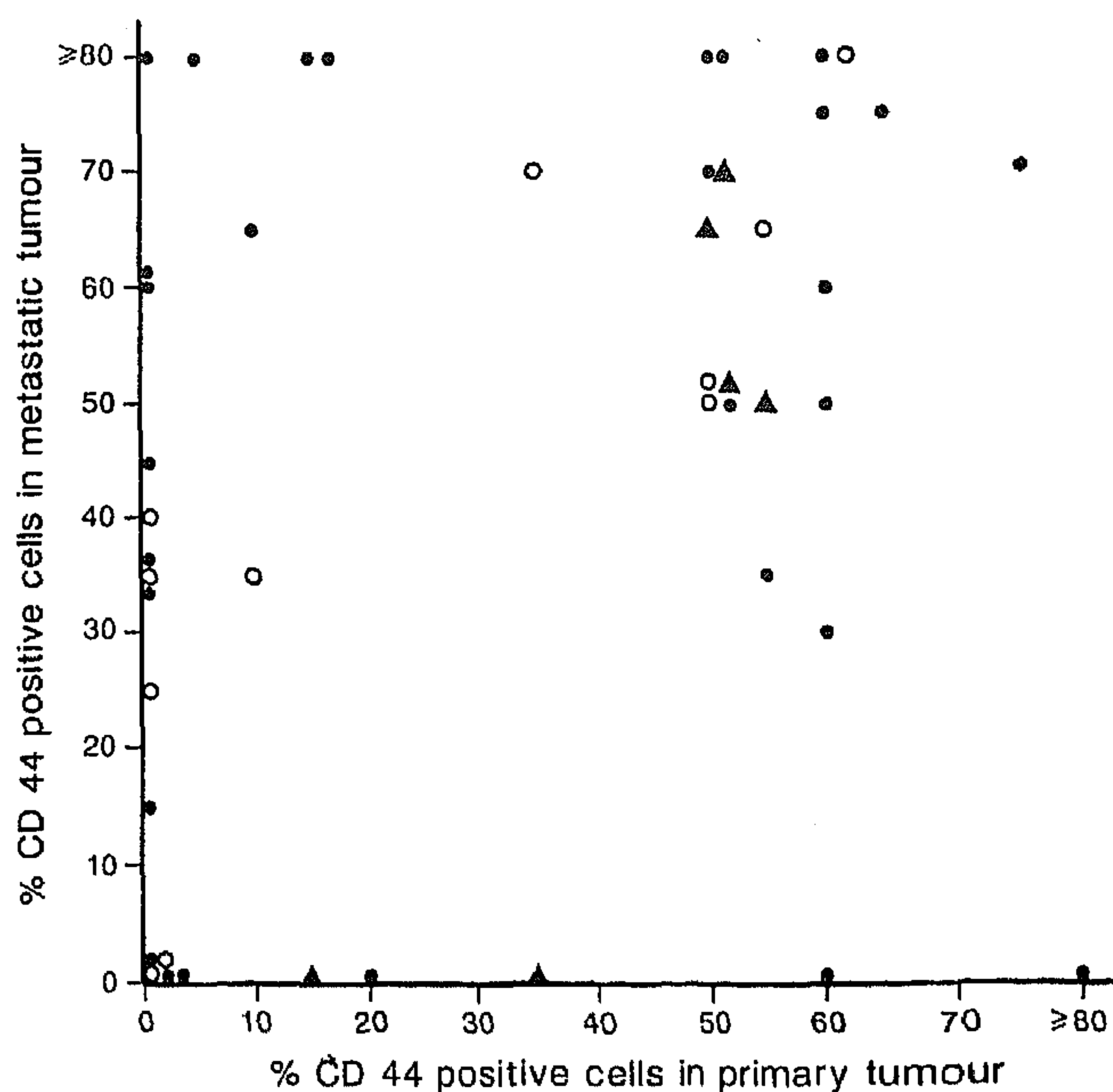


Figure 2: CD44 expression in primary and in autologous metastatic tumours in individual patients

Closed circles represent lymph node, triangles liver, and open circles omental metastases. Correlation significant (Spearman's  $r=0.349$ ,  $p=0.009$ ).

the metastatic lesions, where 3 CD44 positive lymph-node metastases (over 70% cells) appeared to be 9v negative.

#### CD44 and prognosis

CD44 expression on primary gastric tumours was examined for its correlation with recurrence and with tumour-induced mortality in 31 curatively resected patients. During follow-up of 6–39 months (mean 17 months) 10 of 13 patients with CD44 positive primaries had local recurrence or distant metastases, while in CD44 negative patients tumour recurrence was less frequent (3/18,  $p=0.001$ ). Moreover, tumour-induced mortality was more frequent in CD44 positive patients (11/13 vs 2/18,  $p=0.003$ ). The Kaplan-Meier curves (figure 3) show that patients with CD44 positive primary tumours had a shorter survival time than those with CD44 negative tumours. Only 22 curatively resected patients were examined for CD44 9v expression, but the same association was seen between expression of this variant and survival ( $p=0.005$ ).

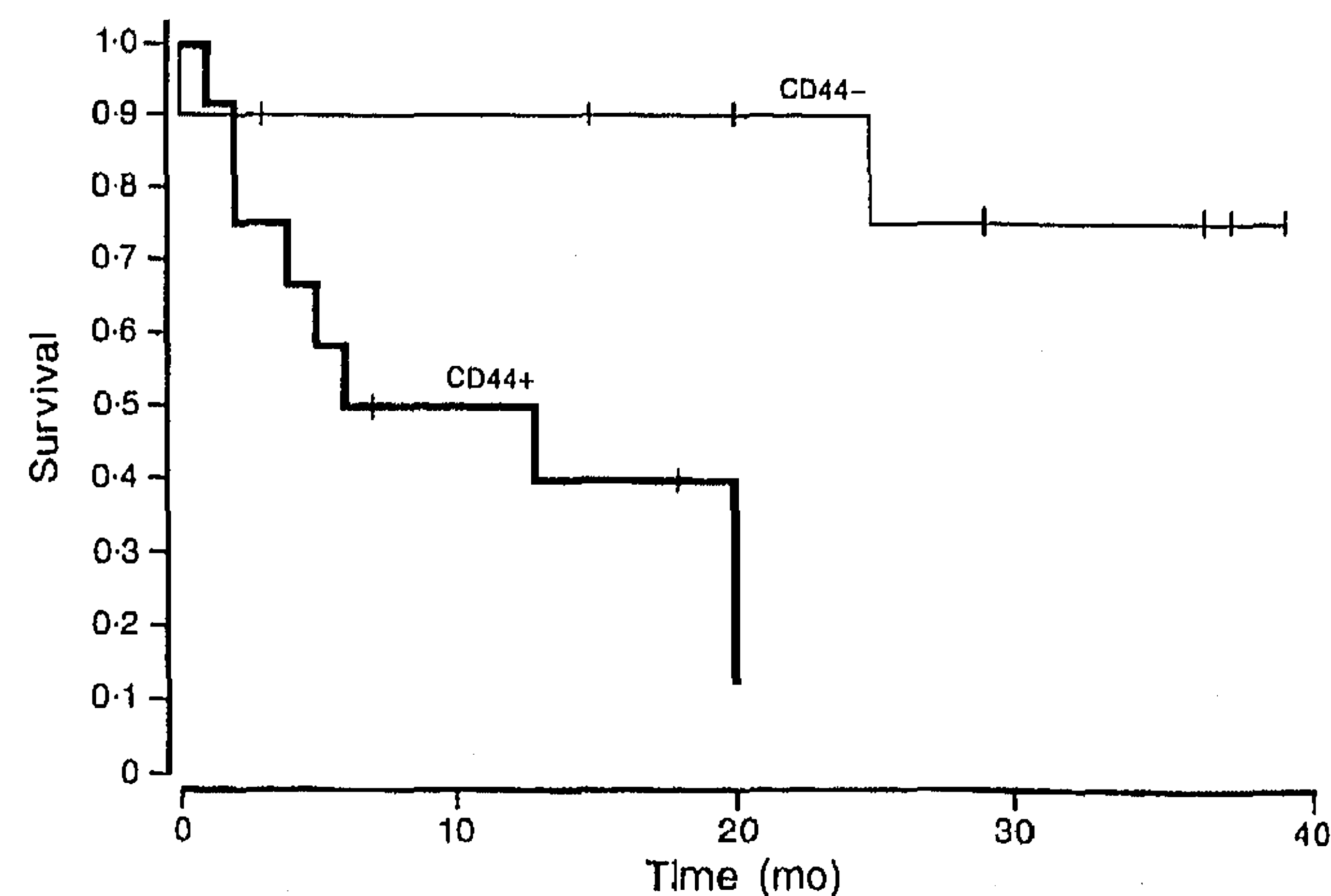


Figure 3: Kaplan-Meier survival curves for 31 curatively resected gastric cancer patients, subdivided according to CD44 expression



To compare the prognostic significance of CD44 expression with other clinical indices, we did multivariate regression analyses using the Cox hazard model. In this small group of patients CD44 expression was an independent prognostic factor ( $p=0.0002$ ), over and above Borrmann classification ( $p=0.01$ ), TNM staging ( $p=0.02$ ), grading ( $p=0.04$ ), and tumour diameter ( $p=0.04$ ).

## Discussion

We show here that in primary gastric carcinomas, expression of CD44 is significantly associated with distant metastases and, in curatively resected patients, with tumour recurrence and increased mortality. The use of antibodies that detect all CD44 isoforms to analyse the correlation between CD44 expression and prognosis was possible because, although CD44 isoforms are expressed on most cell types, normal gastric mucosa is CD44 negative and in benign mucosa it was expressed only when there was atrophic gastritis associated with a leucocyte infiltrate. These observations suggest that CD44 expression may be induced on the mucosal cells through direct or cytokine-mediated interaction with inflammatory cells. Up-regulation of CD44 has been observed at other sites of chronic inflammation<sup>19</sup> and can be induced on lymphocytes.<sup>10,20,21</sup> No such association between leucocyte infiltrate or cell activation and CD44 expression was observed for the carcinoma cells, suggesting that different regulatory mechanisms are involved in CD44 expression in benign and malignant gastric tissues.

Immunohistochemical expression of the CD44 family was detected on only 49% of the primary carcinomas so we doubt if CD44 variant analysis<sup>7</sup> will be a useful diagnostic marker for gastric cancer. Significant association was found between CD44 expression in primary tumours and distant metastases at the time of diagnosis (M1). Although a correlation was also found between CD44 and glandular structure, this may be in part a reflection of the difficulty of identifying CD44 positive cells in diffuse tumours, where tumour cells are surrounded by CD44-positive stroma and leucocytes. Most metastases from patients with CD44 positive tumours were also CD44 positive. No association was found between CD44 expression and location of metastases, suggesting an equal involvement of CD44 in both lymph-borne and haematogenous spread of tumour.

An increase in the expression of variant CD44 isoforms has been associated with tumour progression in breast and colorectal carcinomas.<sup>7-9</sup> Although the exact nature of the CD44 isoforms expressed on the gastric epithelial cells remains to be determined, staining of several gastric tissue samples with an antibody directed specifically at the exon 9v variant revealed a good correlation between expression of isoforms bearing this variant and total CD44. Moreover, as for total CD44, expression of 9v containing isoforms was closely associated with increased tumour recurrence and mortality. 9v has been identified in nine CD44 isoforms;<sup>3</sup> it is also present in the epithelial form (CD44E or CD44R1) expressed by normal keratinocytes and by a wide variety of carcinoma cells;<sup>22</sup> and it is the major form of CD44 which is up-regulated in tumours.<sup>7-9</sup> The finding of a few strongly CD44 positive metastases which were 9v negative suggests that some tumours may express additional isoforms.

In diffuse large-cell lymphoma the expression of CD44 has been shown to correlate with reduced survival.<sup>10,11</sup> The clinical findings presented here provide evidence for a close

correlation between CD44 expression and poor prognosis in solid tumours too.

We thank Dr J Seeleitner, Dr U Grützner, and Dr M M Heiss for organisation of the clinical data, F Leitl and R Babic for diagnostic evaluation, and H Ansari for statistical help. This study was supported by the Deutsche Krebshilfe, Dr Mildred Scheel Stiftung, and Curt-Bohnewand-Fonds.

## References

- Haynes BF, Telen MJ, Hale LP, Denning SM. CD44—a molecule involved in leucocyte adherence and T-cell activation. *Immunol Today* 1989; 10: 423–28.
- Haynes BF, Liao H-X, Patton KL. The transmembrane hyaluronate receptor (CD44): multiple functions, multiple forms. *Cancer Cells* 1991; 3: 347–50.
- Günthert U. CD44: a multitude of isoforms with diverse functions. *Curr Top Microbiol Immunol* (in press).
- Screaton GR, Bell MV, Jackson DG, Cornelis FB, Gerth U, Bell JI. Genomic structure of DNA encoding the lymphocyte homing receptor CD44 reveals at least 12 alternatively spliced exons. *Proc Natl Acad Sci* 1992; 89: 12160–64.
- Günthert U, Hofmann M, Rudy W, et al. A new variant of glycoprotein CD44 confers metastatic potential to rat carcinoma cells. *Cell* 1991; 65: 13–24.
- Hofmann M, Rudy W, Zöller M, et al. CD44 splice variants confer metastatic behavior in rats: homologous sequences are expressed in human tumor cell lines. *Cancer Res* 1991; 51: 5292–97.
- Matsumura Y, Tarin D. Significance of CD44 gene products for cancer diagnosis and disease evaluation. *Lancet* 1992; 340: 1053–58.
- Tanabe KK, Ellis LM, Saya H. Expression of CD44R1 adhesion molecule in colon carcinomas and metastases. *Lancet* 1993; 341: 725–26.
- Heider KH, Hoffmann M, Horst E, et al. A human homologue of the rat metastasis associated variant of CD44 is expressed in colorectal carcinomas and adenomatous polyps. *J Cell Biol* 1993; 120: 227–33.
- Koopman G, Heider K-H, Horst E, et al. Activated human lymphocytes and aggressive Non-Hodgkin's lymphomas express a homologue of the rat metastasis-associated variant of CD44. *J Exp Med* 1993; 177: 897–904.
- Horst E, Meijer CJLM, Radaszkiewicz T, Ossekoppele GJ, van Krieken JHJM, Pals ST. Adhesion molecules in the prognosis of diffuse large cell lymphoma: expression of a lymphocyte homing receptor (CD44), LFA-1 (CD11a/18) and ICAM-1 (CD54). *Leukemia* 1990; 4: 595–99.
- Duarte J, Lianos O. Pattern of metastases in intestinal and diffuse types of carcinoma of the stomach. *Hum Pathol* 1981; 12: 237–42.
- Schmitz-Moormann P, Heider HA, Thomas C. Cancer of the stomach—prognosis, independent of therapy. In: Herfarth CH, Schlag P, eds. Gastric cancer. New York: Springer, 1979: 172–81.
- Mayer B, Johnson JP, Leitl F, et al. E-cadherin expression in primary and metastatic gastric cancer: downregulation correlates with cellular dedifferentiation and glandular disintegration. *Cancer Res* 1993; 53: 1690–95.
- Pals ST, Hogervorst F, Keizer GD, Thepen T, Horst E, Figdor CC. Identification of a widely distributed 90-kda glycoprotein that is homologous to the Hermes-1 human lymphocyte homing receptor. *J Immunol* 1989; 143: 851–57.
- Mackay CR, Maddox JF, Wijffels GL, Mackay IR, Walker ID. Characterization of a 95,000 molecule on sheep leucocytes homologous to murine Pgp-1 and human CD44. *Immunology* 1988; 65: 93–99.
- Wahab ZA, Wright GL. Monoclonal antibody (anti-Leu 7) directed against natural killer cells react with normal, benign and malignant prostate tissues. *Int J Cancer* 1985; 36: 677–83.
- Jackson DG, Screaton GR, Bell MV, Bell JI. CD44 and cancer. *Lancet* 1993; 341: 252.
- Haynes BF, Hale LP, Patton KL, Martin ME, McCallum RM. Measurement of an adhesion molecule as an indicator of inflammatory disease activity: up-regulation of the receptor for hyaluronate (CD44) in rheumatoid arthritis. *Arthritis Rheum* 1991; 34: 1434–43.
- Arch R, Wirth K, Hoffmann M, et al. Participation in normal immune responses of a metastasis-inducing splice variant of CD44. *Science* 1992; 257: 682–85.
- Camp RL, Kraus TA, Birkelan ML, Pure E. High levels of CD44 expression distinguish virgin from antigen-primed B cells. *J Exp Med* 1991; 3: 763–66.
- Brown TA, Bouchard T, John TSt, Wayner E, Carter WG. Human keratinocytes express a new CD44 core protein (CD44E) as a heparan-sulfate intrinsic membrane proteoglycan with additional exons. *J Cell Biol* 1991; 113: 207–21.