Radboud Repository

Radboud University Nijmegen

PDF hosted at the Radboud Repository of the Radboud University Nijmegen

The following full text is a publisher's version.

For additional information about this publication click this link.
http://hdl.handle.net/2066/25830

Please be advised that this information was generated on 2017-12-05 and may be subject to change.

Eur J Dermatol 1997; 7: 164-8

Marie-Jeanne P. GERRITSEN
Peter C.M. van de KERKHOF
Ivonne M.J.J. van VLIJMEN-WILLEMS
Peter M. STEIJLEN

Expression of filaggrin, involucrin and tenascin in monogenic disorders of keratinization

Disorders of keratinization comprise a large spectrum of distinct disease entities. Filaggrin and involucrin are major components of the keratinization process. On the other hand, the extracellular matrix molecule, tenascin, is expressed predominantly in disorders characterized by epidermal proliferation such as epidermal neoplasms and psoriasis. In the present investigation, the expression of filaggrin, involucrin and tenascin was assessed in various keratinization disorders. Filaggrin proved to be specifically absent or minimally expressed in patients with autosomal dominant ichthyosis vulgaris. In disorders of keratinization with increased epidermal proliferation, the expression of filaggrin, involucrin and tenascin was markedly increased, whereas the normoproliferative disorders of keratinization displayed normal expression of these markers for keratinization and extracellular matrix. *(Key words: filaggrin, involucrin, monogenic disorders of keratinization, tenascin.)*

M.J.P. Gerritsen, P.C.M. van de Kerkhof, I.M.J.J. van Vlijmen-Willems, P.M. Steijlen: Department of Dermatology, University Hospital Nijmegen, P.O. Box 9101, 6500 HB Nijmegen, The Netherlands.

Reprints: P.M. Steijlen.
Fax: (+31) 24.354.1184.
E-mail: P. STEIJLEN@DERMA.AZN.NL

A hallmark of the majority of monogenic disorders of keratinization is a thickening of the stratum corneum or hyperkeratosis, which can be the result of an acceleration of epidermopoiesis, with an increased production of corneocytes (proliferation hyperkeratosis), or of an impaired desquamation process in which too few corneocytes are shed at the skin surface (retention hyperkeratosis) [1].
During keratinization, the formation of filaggrin and involucrin plays an important role. Filaggrin is a basic protein normally present in the stratum corneum of the epidermis. Profilaggrin, the precursor of filaggrin, is synthesized at the level of the granular layer, where it is stored in keratohyalin granules [2, 3]. After dephosphorylation and proteolysis by specific enzymes, profilaggrin is processed into filaggrin, during cornification of keratinocytes [4-7] *(Fig. 1)*.
Involucrin is normally present in the upper third of the epidermis of healthy skin. The protein becomes incorporated in the cornified envelope under the plasma membrane. Because involucrin is not related to keratins, neither immunologically nor biochemically, it is a distinct marker for terminal differentiation [8-10].
Tenascin is an extracellular matrix glycoprotein. *In vitro* studies suggest that proliferating epithelium induces the production of tenascin by mesenchymal cells [11]. In normal human skin, tenascin expression is found diffusely in the subepidermal dermis adjacent to basement membranes, around the eccrine sweat glands, and blood vessels [12]. An increased expression of tenascin has been observed in the upper dermis in hyperproliferative skin diseases such as psoriasis, basal cell carcinoma, Bowen's disease and actinic keratosis [13].
In the present investigation we compared the expression of filaggrin, involucrin and tenascin in several monogenic disorders of keratinization with that observed in normal skin.

Material and methods

Patients and biopsies

Four mm punch biopsies were taken from 48 patients with disorders of keratinization and healthy volunteers. These were embedded in Tissue Tek OCT compound, snap frozen in liquid nitrogen and stored at – 80° C, until use.
The groups comprised 7 patients with autosomal dominant ichthyosis vulgaris (ADIV), 6 patients with X-linked ichthyosis vulgaris (XRI), 12 patients with autosomal recessive

Figure 1. *Filaggrin expression in non-erythrodermic autosomal recessive lamellar ichthyosis is markedly increased compared with normal skin.*

lamellar ichthyosis of the non-erythrodermic and erythrodermic type (NEARLI and EARLI), 6 patients with bullous ichthyosis of the Siemens and Brocq type, 2 collodion babies, 1 patient with erythrokeratoderma variabilis Mendes da Costa, 3 patients with Darier's disease and 1 patient with an epidermolytic naevus.

Monoclonal antibodies

We used a mouse monoclonal antibody against filaggrin (BTI, BT576, 1:800) and a monoclonal antibody against involucrin (Mon-150, 1:50) [14]. The monoclonal antibody against tenascin (1/2000, T2H5) was obtained from A.A. Verstraeten, The Netherlands Cancer Institute, Amsterdam, the Netherlands [13].

Staining procedure

An indirect immunoperoxidase technique was used. After washing, the slides were incubated for 30 min with RAMPO (rabbit anti-mouse immunoglobulin conjugated with peroxidase, 1/80). After 2 washes with a phosphate buffer, only the slides with anti-filaggrin were incubated with DAB-solution (diaminobenzidine, 5 mg/10 ml in PBS solution). Afterwards the slides were washed with water and stained with $CuSO_4$. The slides were dehydrated with 100% alcohol and xylene and mounted in Permount. For the tenascin and anti-involucrin staining, a preincubation with sodium acetate buffer (pH 4.9), a solution of 3-amino-9-ethylcarbazole (AEC) in sodium-acetate buffer containing 0.01% H_2O_2, was performed for 10 min.
All slides were counterstained with Mayer's haematoxylin (Sigma, St. Louis MO USA) and mounted in glycerol gelatin.

Histological examination

The histological examination was performed blind. In every slide, 2 representative areas were examined and the mean of these observations was calculated. Filaggrin and involucrin expression was assessed by calculating the ratio of positive cell layers/total cell layers of the living epidermis. This was performed at the tip of a dermal papilla and between two dermal papillae *(Fig. 2)*.

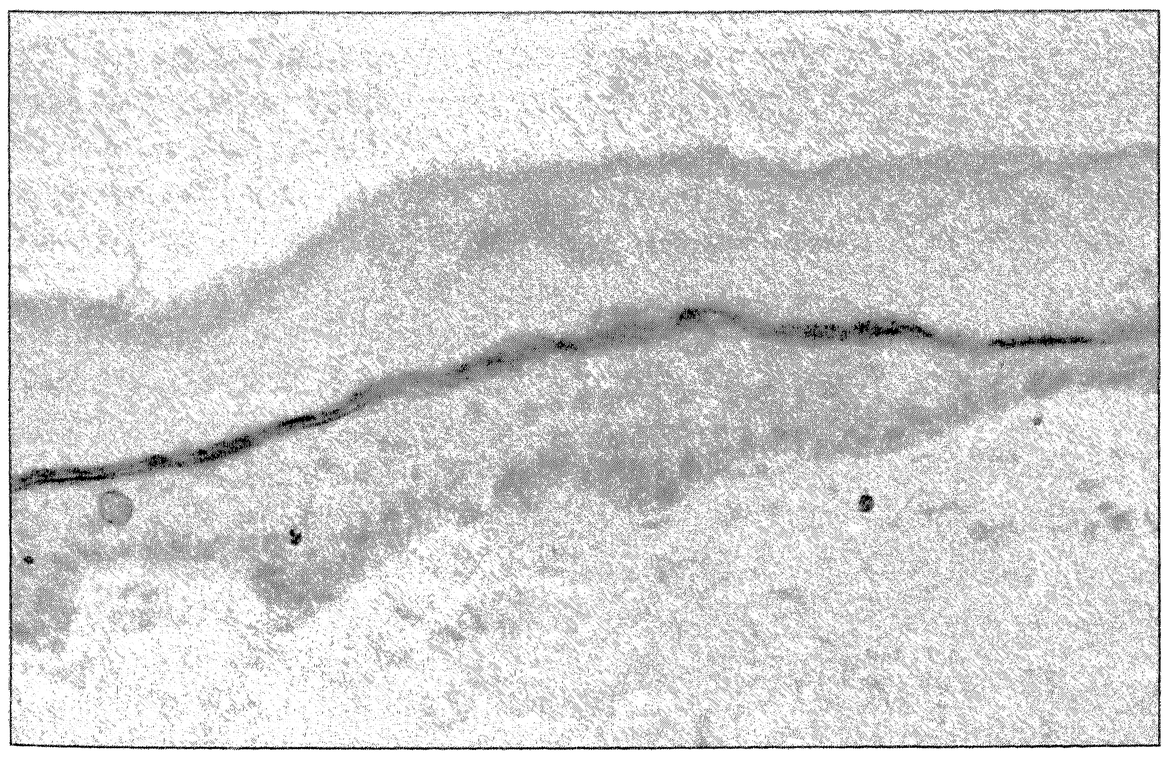

Figure 2. *Involucrin expression in the X-chromosomal recessive ichthyosis, which is comparable with the expression in normal healthy skin.*

The distribution in the papillary dermis was assessed using the following grading system: (1) continuous expression adjacent to the basal lamina *versus* discontinuous expression adjacent to the basal lamina; (2) staining intensity.

Statistical evaluation

For statistical analysis the Mann-Whitney test was used.

Results

The results are shown in *Tables I* to *III*.
In disorders of keratinization other than ADIV and in normal skin, filaggrin showed a continuous expression in the granular layer. In patients with Darier's disease, and even more marked in various forms of congenital ichthyosis (lamellar ichthyosis and bullous ichthyosis) filaggrin positive cell layers were significantly and markedly increased compared to normal skin. Only in ADIV was filaggrin expression markedly decreased and discontinuous. No expression of filaggrin was observed in one patient, while in two patients filaggrin expression was restricted to one cell layer, and in four patients a sporadic expression was seen *(Table I)*.

Table I. ***The filaggrin expression in keratinization disorders, expressed as mean ± standard deviation of the mean and the p-value compared with normal healthy skin. Expression was assessed by calculating the ratio of positive cell layers/total cell layers of the living epidermis (%). This was performed at two sites: at the tip of a dermal papilla and between two dermal papillae (%)***

Disease	Filaggrin, tip dermal papilla	Filaggrin, inter-papillary	Number of patients
Normal human skin	16 ± 2.15	8 ± 1.1	4
Autosomal dominant ichthyosis vulgaris	0	0	1
	4 ± 3.07	4 ± 1.54	2
	11 ± 2.46	7 ± 0.84	4
X-linked ichthyosis	15 ± 1.62 (NS)	10 ± 1.96 (NS)	6
Non-erythrodermic autosomal recessive lamellar ichthyosis	40 ± 3.19 (p = 0.01)	20 ± 2.3 (p = 0.02)	6
Erythrodermic autosomal recessive lamellar ichthyosis	45 ± 3.4 (p = 0.02)	28 ± 3.75 (p = 0.02)	4
Erythrodermic ichthyosiformis congenita bullosa (Brocq)	43 ± 4.2 (p = 0.02)	36 ± 5.5 (p = 0.02)	4
Ichthyosis bullosa of Siemens	44 ± 3.5	37 ± 7.5	2
Collodion baby	42 ± 8.5	27 ± 2.5	2
Erythrokeratoderma variabilis	31	32	1
Darier's disease	37 ± 0.02 (p = 0.03)	25 ± 5.8 (p = 0.03)	3
Epidermolytic naevus	20	6	1

Table II. *The involucrin expression in keratinization disorders, expressed as mean ± standard deviation of the mean and the p-value compared with normal healthy skin. Expression was assessed by calculating the ratio of positive cell layers/total cell layers (%) of the living epidermis. This was performed at two sites: at the tip of a dermal papilla and between two dermal papillae (%)*

Disease	Involucrin, tip dermal papilla (mean %± SD)	Involucrin, inter-papillary (mean %± SD)	Number of patients
Normal human skin	19 ± 1.0	9 ± 0.42	4
Autosomal dominant ichthyosis vulgaris	21 ± 3.7 (NS)	12.4 ± 1.9 (NS)	7
X-linked ichthyosis	18 ± 2.3 (NS)	11 ± 1.3 (NS)	6
Non-erythrodermic autosomal recessive lamellar ichthyosis	14 ± 0.6 (p = 0.02)	8 ± 0.4 (NS)	6
Erythrodermic autosomal recessive lamellar ichthyosis	44 ± 0 (p = 0.03, n = 3)	27 ± 0.9 (p = 0.03, n = 3)	4
Erythrodermic ichthyosiformis congenita bullosa (Brocq)	44 ± 3.8 (p = 0.02)	28 ± 1.9 (p = 0.02)	4
Ichthyosis bullosa of Siemens	50 ± 17.6	29 ± 10.5	2
Collodion baby	29 ± 13.1	18 ± 7.5	2
Epidermolytic naevus	69 ± 6.1 (p = 0.06)	67 ± 5.6 (p = 0.06)	4
Darier's disease	31 ± 6.8 (NS)	15 ± 4.5 (NS)	3

Table III. *Tenascin expression in the keratinization disorders*

Disease	Tenascin, staining intensity (n)	Tenascin, continuous expression (n)	Tenascin, discontinuous expression (n)	Number of patients
Normal human	diffuse (4)	0	4	4
Autosomal dominant ichthyosis vulgaris				
	diffuse (4)	0	4	4
X-linked ichthyosis				
	diffuse (5)	0	5	5
Non-erythrodermic autosomal recessive lamellar ichthyosis				
	diffuse (3)	2	1	4
	increased (1)	0	1	
Erythrodermic autosomal recessive lamellar ichthyosis				
	increased (3)	3	0	4
	diffuse (1)	0	1	
Erythrodermic ichthyosiformis congenitalis bullosa (Brocq)				
	increased (3)	3	0	4
	diffuse (1)	1	0	
Ichthyosis bullosa of Siemens				
	partly increased partly diffuse (2)			
	increased (2)	4	0	4
Collodion baby	diffuse (2)	0	2	2
Darier's disease	increased (2)	2	0	3
	diffuse (1)	1		
Epidermolytic naevus				
	increased (1)	1	0	1

The distribution of tenascin in the papillary dermis was assessed using the following grading system: continuous expression adjacent to the basal lamina versus *discontinuous expression adjacent to the basal lamina, and staining intensity. This table summarizes the various expressions of tenascin in a number of patients.*

Involucrin expression in non-erythrodermic autosomal recessive lamellar ichthyosis was decreased compared with healthy skin.

In contrast, in erythrodermic autosomal lamellar ichthyosis, the number of involucrin positive cell layers was increased *(Fig. 3)*. Involucrin staining in 3 out of 4 patients with erythrodermic autosomal recessive ichthyosis showed a pronounced and significant increase compared with normal human skin (p = 0.03). The two patients with epidermolytic naevus and two patients with Darier's disease showed an increased involucrin expression. In one of the patients with Dariers' disease we observed normal involucrin expression. In patients with bullous ichthyosis the increase was even more pronounced.

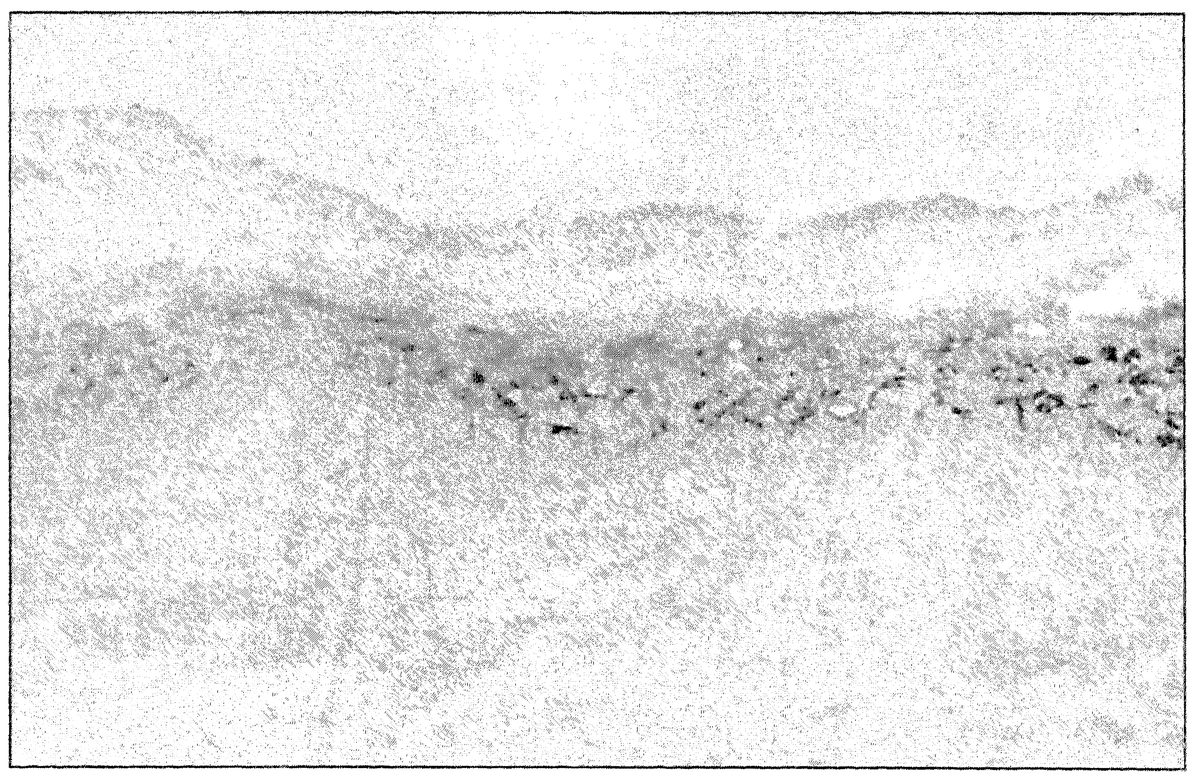

Figure 3. *Markedly increased expression of involucrin in erythrodermic autosomal recessive lamellar ichthyosis.*

Tenascin expression was observed, not only as a discontinuous staining pattern adjacent to the interfollicular epidermis but also around capillaries, eccrine sweat glands and hair follicles. Although the expression in ADIV, X-linked ichthyosis and of the collodion babies was virtually normal, patients with lamellar ichthyosis, bullous ichthyosis, Darier's disease and epidermolytic naevi showed an increased and continuous staining pattern with the antitenascin antibody. In the 3 cases of non-erythrodermic autosomal recessive lamellar ichthyosis, we observed diffuse tenascin staining, however 2 out of these 3 biopsies showed a continuous staining pattern adjacent to the basal membrane. Another biopsy in this group showed an increased but discontinuous tenascin expression *(Fig. 4)*.

Discussion

In the present study, the expression of filaggrin, involucrin and tenascin was studied in disorders of keratinization and

Figure 4. *A marked increased but discontinuous expression of tenascin in erythrodermic autosomal recessive lamellar ichthyosis.*

the results were compared with the expression of these antigens in normal human skin.

In normal skin, filaggrin was observed in the stratum corneum and stratum granulosum with 8% expression in the epidermal layers at the tip of dermal papillae and 16% expression in the interpapillary epidermis *(Table I)*. Although Kanitakis *et al.* [15] reported a decreased filaggrin expression in X-linked ichthyosis compared with healthy skin, in the present study such a decrease could not be confirmed. It must be kept in mind that the study of Kanitakis *et al.* [15] was performed on paraffin-embedded sections, while we used frozen sections. The markedly decreased expression of filaggrin in autosomal dominant ichthyosis vulgaris is in agreement with the finding that in ADIV, the granular layer is thin or absent and is in keeping with the observations of Kanitakis *et al.* [15].

Non-erythrodermic autosomal recessive lamellar ichthyosis, the erythrodermic autosomal recessive lamellar ichthyosis, the bullous congenital ichthyosiform erythroderma of Brocq, and Darier's disease are characterized by hypergranulosis. Kanitakis *et al.* [15] observed a similar increase of filaggrin expression in erythrodermic autosomal recessive lamellar ichthyosis and Darier's disease. However, they did not investigate filaggrin expression in non-erythrodermic autosomal recessive lamellar ichthyosis and bullous ichthyotic erythroderma of Brocq.

The biopsies of the patients with ichthyosis bullosa of Siemens, collodion baby and erythrokeratoderma variabilis showed a markedly increased staining of filaggrin; however the small number of patients does not permit statistical analysis.

In normal human skin, involucrin expression has been observed around the inner root sheath, the infundibulum, the sebaceous duct, the acrosyringium, in the granular layer and in the upper cell layers of the stratum spinosum [16, 17]. These observations are confirmed by our investigations. Involucrin expression in normal human skin appeared to be 9% at the tip of a dermal papilla and 19% interpapillarly. The percentage staining of anti-filaggrin and anti-involucrin seemed to be quite similar. However, filaggrin expression was observed in the stratum granulosum and corneum, while involucrin expression was observed in the stratum granulosum and a part of the stratum spinosum. It must be kept in mind that in our study, a quantitative evaluation method was used, while in most of the other investigations a descriptive method was used.

Expression of involucrin in ADIV and X-linked ichthyosis was comparable with the expression in normal skin and in line with the observations of Kanitakis *et al.* [17]. Involucrin expression in the cases of collodion babies was variable. This variability is possibly due to the fact that collodion baby is probably heterogeneous. The underlying disease may be non-erythrodermic autosomal recessive lamellar ichthyosis, erythrodermic autosomal recessive lamellar ichthyosis or autosomal dominant ichthyosis vulgaris. Moreover, 10% of collodion babies do not develop ichthyosis in later life. From the present and earlier observations it seems apparent that its expression correlates with the degree of epidermal turnover [18]. In the hyperproliferative keratinization disorders (lamellar ichthyosis, ichthyosis bullosa of the Brocq and Siemens type, collodion baby, epidermolytic naevus, Darier's disease, psoriasis), involucrin expression is increased. Recruitment of cycling epidermal cells is activated by protein kinase C. The activation of protein kinase C results in increased TGFα expression, IL-8 production, and involucrin expression of keratinocytes [19]. TGFα induces keratinocyte proliferation. The association between hyperproliferation of the epidermis and increased involucrin expression is intriguing.

In normal human skin, expression of tenascin can be observed around hair follicles, eccrine sweat glands, capillaries and, more sparsely, in the upper dermis adjacent to the basal membrane [12, 13]. In the present study, the tenascin expression in normal skin was comparable with earlier observations [11-13]. Recently, an increased expression of tenascin has been reported in other hyperproliferative skin diseases as psoriasis, basal cell carcinoma, Bowens' disease and keratosis solaris [13]. The non-erythrodermic autosomal recessive lamellar ichthyosis (NEARLI) showed a variable tenascin expression. An explanation for this variability might be the variable degree of concomitant dermal inflammation in our NEARLI group. Schalkwijk *et al.* [20] noticed in 6 out of 7 patients with NEARLI, absent or sparse staining.

The present findings suggest a relationship between epidermal proliferation, inflammation and tenascin expression. An increased epidermal turnover is accompanied by a high tenascin expression adjacent to the basal membrane in the upper dermis. The source of tenascin is not clear. *In vitro* experiments suggest that proliferating epithelium induce the production of tenascin by mesenchymal cells [11]. In an investigation on the wound healing process in rat epithelium, an increased tenascin expression under the migrating proliferating epidermis was found [11]. It is attractive to hypothesize that the expression of tenascin by activated epithelium is of significance for the maintenance of the hyperproliferative state.

The present investigation suggests that filaggrin staining might be of help in the diagnosis of autosomal dominant ichthyosis vulgaris. A markedly decreased filaggrin expression proved to be a selective change in this disorder of keratinization. Involucrin and tenascin expression were not involved specifically in one single disease but were rather compatible with the degree of epidermal proliferation. Therefore, the present study suggests that increased epidermal proliferation, and increased expression of tenascin and involucrin are associated processes in so-called hyperproliferative ichthyotic conditions. ■

References

1. Frost P, Weinstein GD, Van Scott EJ. The ichthyosiform dermatoses: autoradiographic studies of epidermal proliferation. *J Invest Dermatol* 1966; 47: 561-7.
2. Dale BA, Ling SY. Immunologic cross-reaction of stratum corneum basic protein: a keratohyalin granule protein. *J Invest Dermatol* 1979; 72: 257-61.
3. Sibrack LA, Gray RH, Bernstein IA. Localization of the histidine-rich protein in keratohyalin: a morphologic and macromolecular marker in epidermal differentiation. *J Invest Dermatol* 1974; 62: 394-405.
4. Haugen-Scofield J, Resing KA, Dale BA. Characterization of an epidermal phosphatase specific for filaggrin phosphorylated by casein kinase II. *J Invest Dermatol* 1988; 91: 553-9.
5. Kashima M, Fukuyama K, Kikuchi M, Epstein WL. Limited proteolysis of high molecular weight histidine-rich protein of rat epidermis by epidermal proteinases. *J Invest Dermatol* 1988; 90: 829-933.
6. Resing K, Walsh KA, Haugen Scofield J, Dale BA. Identification of proteolytic cleavage sites in the conversion of profilaggrin to filaggrin in mammalian epidermis. *J Biol Chem* 1989; 264: 1837-45.
7. Richards S, Scott IR, Harding CR, Liddel JE, Powell GM, Curtis CG. Evidence for filaggrin as a component of the cell envelope of the newborn rat. *Biochem J* 1988; 253: 153-60.
8. Rice RH, Green H. Presence in human epidermal cells of a soluble protein precursor of the cross-linked envelope: activation of the cross linking by calcium ions. *Cell* 1979; 18: 681-94.
9. Murphy GF, Flynn TC, Rice RH, Pinkus GS. Involucrin expression in normal and neoplastic human skin: a marker for keratinocyte differentiation. *J Invest Dermatol* 1984; 82: 453-7.
10. Green H. The keratinocyte as differentiated cell type. *Harvey Lect* 1979; 74: 101-39.
11. Mackie EJ, Halfter W, Liverani D. Induction of tenascin in healing wounds. *J Cell Biol* 1988; 107: 2757-67.
12. Lightner VA, Gumkowski FD, Bigner DD, *et al.* Tenascin/hexabrachion in human skin: biochemical identification and localization by light and electron microscopy. *J Cell Biol* 1989; 108: 2483-93.
13. Schalkwijk J, Vlijmen I Van, Oosterling B, *et al.* Tenascin expression in hyperproliferative skin diseases. *Br J Dermatol* 1991; 124: 13-20.
14. Duijnhoven HLP Van, Schalkwijk J, Kranenborgh MHGC, *et al.* MON-150, a versatile monoclonal antibody against involucrin; characterization and application. *Arch Dermatol Res* 1992; 284: 167-72.
15. Kanitakis J, Ramirez-Bosca A, Reano A, *et al.* Filaggrin expression in normal and pathological skin. *Virch Archiv A Pathol Anat Histopathol* 1988; 412: 375-82.
16. Banks-Schlegel S, Green H. Involucrin synthesis and tissue assembly by keratinocytes in natural and cultured human epithelia. *J Cell Biol* 1981; 90: 732-7.
17. Kanitakis J, Zambruno G, Viac J, Thivolet J. Involucrin expression in keratinization disorders of the skin – a preliminary study. *Br J Dermatol* 1987; 117: 479-86.
18. Frost P. Ichthyosiform dermatoses. *J Invest Dermatol* 1973; 60: 541.
19. Lizuka H, Takahashi H. Psoriasis, involucrin and protein kinase C. *Int J Dermatol* 1993; 32: 333-8.
20. Schalkwijk J, Steijlen PM, Vlijmen-Willems IMJJ Van, *et al.* Tenascin expression in human dermis is related to epidermal proliferation. *Am J Pathol* 1991; 139: 1143-50.