

PDF hosted at the Radboud Repository of the Radboud University Nijmegen

The following full text is a publisher's version.

For additional information about this publication click this link.

<http://hdl.handle.net/2066/25643>

Please be advised that this information was generated on 2017-12-05 and may be subject to change.

Differential Effect of Macrophage Depletion on Two Forms of Experimental Uveitis Evoked by Pigment Epithelial Membrane Protein (EAPU), and by Melanin-Protein (EMIU)

R. M. BROEKHUYSE*, I. HUITINGA^a, E. D. KUHLMANN, N. VAN ROOIJEN^b
AND H. J. WINKENS

Institute of Ophthalmology, University of Nijmegen, 6500 HB Nijmegen;

^a*Departments of Pharmacology and* ^b*Cell Biology, Free University, 1081 BT Amsterdam, The Netherlands*

(Received Cleveland 1 April 1997 and accepted in revised form 14 August 1997)

The purpose of the present study was to clinically and histologically investigate the influence of macrophage depletion on the development of experimental autoimmune pigment epithelial membrane protein-induced uveitis (EAPU), and experimental melanin-protein induced uveitis (EMIU) in the Lewis rat. EAPU is mainly characterized by pigment epitheliitis. Posterior mononuclear cell accumulations enclose and destroy the retinal pigment epithelium (RPE). In EMIU the inflammation is specifically localized in the uvea.

EAPU was induced by immunization with RPE membrane protein, and EMIU was evoked by immunization with purified choroidal melanin. Systemic treatment with dichloromethylene diphosphonate (Cl₂MDP)-containing liposomes just before the expected beginning of the clinical signs of EAPU (at day 7 and 9 after immunization) resulted in a considerable delay of the uveitis process. In the treated animals the typical plaque shaped cell accumulations (containing many macrophages) along the RPE were lacking. Two weeks after the treatment, severe rebound EAPU developed. Local treatment by subconjunctival liposome injections did not exert any effect on EAPU. In EMIU, macrophage depletion by systemic treatment did not noticeably influence the clinical and histological development of the inflammation.

Systemic treatment at the peak stage of EAPU (at day 12 and 14 after immunization) resulted in the rapid disappearance of the clinical signs of uveitis. Vitreous and anterior chamber cells were virtually absent two days later. This situation remained unchanged until the experiment was terminated two weeks later. Already deposited cell accumulations along the RPE did not regress but stopped their progression.

Hematogenous macrophages thus appear to play a crucial role in the development of EAPU but the effect of early macrophage depletion on EAPU appeared to be temporary due to blood repopulation. A possible explanation for the differential influence of macrophage depletion on EAPU and EMIU is discussed, and is based on differences in immunopathogenesis. © 1997 Academic Press Limited

Key words: experimental autoimmune pigment epithelial membrane protein-induced uveitis (EAPU); experimental melanin-protein induced uveitis (EMIU); macrophages; uvea; retinal pigment epithelium; pigment epithelial membrane protein; dichloromethylene diphosphonate (Cl₂MDP).

1. Introduction

Three markedly different types of experimental autoimmune uveitis have been described which can be evoked in Lewis rats by immunization with uveoretinal antigens. In experimental autoimmune uveoretinitis (EAU) induced by photoreceptor proteins, inflammatory foci develop within the photoreceptor cell layer which is the target tissue (Faure, 1980; Gery, Mochizuki and Nussenblatt, 1986). In experimental autoimmune pigment epithelial membrane protein-induced uveitis (EAPU), the RPE is the target tissue, and inflammatory foci do not develop within the neuroretina. Mononuclear cells (mainly infiltrated macrophages) accumulate along both sides of the RPE-Bruch's membrane layer which is destroyed. Uveitogenic pigment epithelial proteins (PEP) with Mr 65, 43 and 28/30 (PEP-65, PEP-43 and PEP-

28/30) have been isolated from the microsomal fraction of RPE cells, and evoke EAPU after immunization (Broekhuysse et al., 1992b; Broekhuysse and Kuhlmann, 1997). In experimental melanin protein-induced uveitis (EMIU; also called experimental autoimmune anterior uveitis, EAAU), the primary inflammation is confined to the uvea whereas the retina is spared. The inciting antigen can be prepared from the melanin granules from the bovine retinal pigment epithelium (RPE) or from the uveal tissues (Broekhuysse et al., 1991, 1992a; Broekhuysse and Kuhlmann, 1993; Chan et al., 1994; Bora et al., 1995). Little is known about the immunopathogenesis of the latter two forms of experimental uveitis. In autoimmune diseases like experimental autoimmune encephalomyelitis (EAE) and EAPU, ED1 positive macrophages are known to play a crucial role (Huitinga et al., 1995; Broekhuysse et al., 1996). In these models, and in experimental autoimmune arthritis, and nephritis, the cells that infiltrate the target tissues first have been

* Corresponding author: Dr R. M. Broekhuysse.

shown to be newly recruited ED1+ exudate macrophages. Data obtained from macrophage elimination studies indicate that the newly recruited macrophages are crucial for the generation of clinical signs (Bauer et al., 1996, review).

In the present study we have applied the technique of liposome-mediated macrophage depletion in order to investigate the role of macrophages in EAPU and EMIU. Liposomes containing dichloromethylene diphosphonate (Cl_2MDP) are known to be phagocytized by macrophages in the spleen, the liver, and by blood monocytes (Van Rooijen et al., 1990; Huitinga et al., 1990, 1992). Once internalized, Cl_2MDP is released and kills the cells (Van Rooijen, 1989). EAPU and EMIU have been evoked in Lewis rats, and the animals have been injected with the liposomes immediately before the start and at the peak stage of uveitis in order to investigate a possible prevention or amelioration of uveitis.

2. Materials and Methods

Antigens

Two uveitogenic antigens were prepared to evoke EAPU, the Triton X-100 soluble-(TS) fraction of RPE microsomal cell membranes (RPE-TS), and its main constituent the 65 kD pigment epithelial protein PEP-65 (Broekhuysse et al., 1992b, 1996). Briefly, RPE cells were isolated from the cups of fresh bovine eyes by brushing and rinsing. The cells were freed from rod outer segments and other tissue fragments by five to seven sedimentations from buffered sucrose (0.25 M; 15 mM phosphate buffer; pH 7.3) at 140 g (10 min, 20°C). The RPE cells were extracted by phosphate buffered physiological saline pH 7.4 (PBS), and the insoluble membranous 10^5 g sediment was extracted by Triton X-100. The combined supernatants containing the RPE-TS protein were stored at -25°C . Its main constituent PEP-65 was prepared from RPE-TS by preparative sodium dodecyl sulfate (SDS)-polyacrylamide gel electrophoresis (PAGE), and electro-elution. The obtained protein was precipitated from the detergent solution by cold acetone precipitation (0°C), dried under nitrogen, dissolved in 1% Triton X-100 in PBS, and stored at -25°C . PEP-65 was used as uveitogen in the initial studies of EAPU, and its activity was compared to RPE-TS.

Choroidal melanin was purified in order to evoke EMIU. Bovine eye cups were obtained as described above, and the choroid was removed with forceps. The tissues were rubbed in a mortar with a rough surface with minimal amounts of water. The suspended material was filtered through gauze, and the extraction of the tissue was repeated five times. The combined filtered suspensions were centrifuged (10^4 g, 10 min, 4°C), and the crude sedimented melanosomes were washed with PBS. Afterwards they were suspended in 2% SDS in distilled water (1 ml for the

melanin of each choroid), and heated at 75°C for 10 min. After centrifugation, the purified melanin was washed twice with distilled water at room temperature, and stored in water at -25°C (Broekhuysse and Kuhlmann, 1993).

The determinations of soluble, membrane-, and melanin-protein, SDS-PAGE, the check for purity by SDS-PAGE and immunoblotting have been described previously (Broekhuysse et al., 1991, 1992a, b, 1993).

Animal Experiments

Groups of female Lewis rats [LEW/Ola/Hsd(albino); 150–180 g] composed as represented in Table I, were immunized with 150 μg RPE-TS, or 100 μg PEP-65 to evoke EAPU, and with 10 or 25 μg melanin-protein to induce EMIU. The animals originated from Harlan Olac Ltd, Bicester, England. Half the antigen dose was emulsified in Freund's complete adjuvant (CFA; Difco Laboratories, Detroit, MI, U.S.A.), and injected in the hind foot pads (0.1 ml per pad). The other half was mixed with 1 ml PBS containing 2 μg pertussis toxin (Sigma Chemical Company, St. Louis, MO, U.S.A.) and injected intraperitoneally. The 10 μg melanin-protein dose was injected with 1 μg toxin. General controls were similarly injected with the toxin and with CFA/PBS emulsions but without antigen.

Shortly before, or after the start of EAPU and EMIU, the animals were intravenously injected with 1.8 ml Cl_2MDP -liposomes, PBS-containing liposomes, or PBS, as indicated in the Results section (Table I). In a separate experiment, 50 μl Cl_2MDP -liposomes were injected subconjunctivally at the right eyes of five rats at day 7 and 9 after immunization. Liposomes were prepared as described (Huitinga et al., 1995). Cl_2MDP was a gift of Boehringer, Mannheim, Germany. Starting from day 9 after immunization, the eyes were examined daily for 2 weeks and subsequently twice a week. Clinical signs of uveitis were monitored by direct slit-lamp biomicroscopy after dilation of the pupils by tropicamide (0.17%). The observations were graded on a scale of 0–4 as described for EAPU (Broekhuysse et al., 1992b), and for EMIU (Broekhuysse et al., 1991). The experiments were terminated 2 to 4 weeks after immunization as indicated in Table I, and the histopathology of eyes, liver and spleen was examined.

Histopathology

Eyes were fixed in Bouin solution, and processed according to standard histological techniques. All eyes were sectioned parallel to the optic axis. Macrophage depletion phenomena were checked in frozen sections of spleen, liver and in bloodsmears of rats 2 weeks after immunization. Bloodsmears were stained with May Grünwald-Giemsa, and frozen sections were stained with monoclonal antibody ED1 as described (Broekhuysse et al., 1996).

TABLE I

The effect of treatment with Cl_2 MDP liposomes on the development of EAPU and EMIU

Inciting antigen¶	Treatment*		Incidence of uveitis†			Clinical uveitis scores§	
	Liposome type	Days	Incidence	Mild	Severe	Early phase [day 12–15]	Late phase [day 26–30]
PEP-65	Cl_2 MDP	7 and 9	4/4	3	1	1.6 ± 0.3 [13]**	3.3 ± 0.4 [26]**
PEP-65	PBS	7 and 9	5/5	3	2	2.4 ± 0.4 [13]****	1.3 ± 0.3 [26]
PEP-65	[PBS solution]	7 and 9	4/4	0	4	3.4 ± 0.3 [13]	1.3 ± 0.5 [26]
RPE-TS	Cl_2 MDP	7 and 9	4/7	4	0	0.0 [12–15]**	2.1 ± 0.6 [30]***
RPE-TS	PBS	7 and 9	7/7	0	7	2.5 ± 0.3 [12]	1.5 ± 0.6 [30]
RPE-TS	Cl_2 MDP	12 and 14	5/5	2‡	3‡	2.5 ± 0.3 [12]	
						0.3 ± 0.1 [15]**	0.8 ± 0.4 [26]**
RPE-TS	PBS	12 and 14	5/5	2‡	3‡	2.9 ± 0.4 [12]	
						2.4 ± 0.4 [15]	1.8 ± 0.4 [26]
Melanin/25	Cl_2 MDP	7 and 9	4/4	0	4	4.0 ± 0.0 [12]	
Melanin/25	PBS	7 and 9	2/2	0	2	4.0 ± 0.0 [12]	
Melanin/25	[PBS-solution]	7 and 9	3/3	0	3	4.0 ± 0.0 [12]	
Melanin/10	Cl_2 MDP	7 and 9 and 12	4/4	0	4	4.0 ± 0.0 [14]	
Melanin/10	PBS	7 and 9 and 12	2/2	0	2	4.0 ± 0.0 [14]	

* Cl_2 MDP, PBS; mannosylated liposomes containing Cl_2 MDP or PBS were injected intravenously shortly before or after the start of EAPU or EMIU, i.e. at days 7 and 9 (and 12) (prevention) or 12 and 14 (therapy), respectively. [PBS solution], PBS injected without liposomes.

† Maximum score attained within the entire experimental period. Mild, score 1 and 2; severe, score 3 and 4.

‡ No maximum inflammation reached in all rats; incidences at day 12 are represented, the time of the first injection of liposomes close to the inflammatory peak activity of EAPU.

§ Mean score (\pm S.E.M.). Early phase, day 12–15 after immunization, shortly after the start of EAPU or EMIU (peak of inflammation) when the most characteristic effects of treatment are noticed; late phase, day 26–30. *P* values represent analysis of scores of Cl_2 MDP-liposomes treated rats vs. control rats. ***P* < 0.01, ****P* < 0.05. **** Analysis of PBS-liposomes-treated rats vs. PBS-injected rats: *P* < 0.01.

¶ Melanin injected in two different melanin-protein doses to evoke EMIU: 25 μ g (2 μ g pertussis toxin), and 10 μ g (1 μ g pertussis toxin).

Statistical Analysis

For testing the significance of difference in uveitis scores, Fisher's exact test was applied.

3. Results

Clinical Effects of Macrophage Depletion

EAPU treatment, Cl_2 MDP-liposomes at day 7 and 9; controls Table I represents the results of two types of experiments in Lewis rats which were immunized to develop EAPU. In the first type of experiment, Cl_2 MDP-liposomes were injected intravenously just before and at the day on which clinical signs of ocular inflammation were expected to start. The results of slit-lamp examinations show that PEP-65 in PBS controls evoked severe EAPU (score 3.4 at day 13). If the rats were treated with Cl_2 MDP-liposomes at day 7 and 9 after immunization, only a very mild vitritis was noticed (score 1.6 at day 13). The inhibition of uveitis was not permanent because EAPU still developed two weeks later (score 3.3 at day 26). PBS-liposomes (control treatment) also had a weak inhibiting effect on the disease; the highest score attained in controls was 2.4 (day 13). The scores of both control groups finally decreased to 1.3 (day 26). Two similar experiments (not recorded in Table I) confirmed this effect of PBS-liposomes. It occurred from day 12 to 20, and disappeared afterwards. Hence, all three groups de-

veloped uveitis but according to different patterns. Because the experiments described below showed that RPE-TS and PEP-65 were equally well suitable to evoke EAPU while RPE-TS was easier to prepare, this antigen was further used as the inciting uveitogen.

Table I shows that control rats injected with RPE-TS developed severe EAPU (peak inflammation at day 12; score 2.5) at day 12 whereas Cl_2 MDP-liposomes treatment totally inhibited the development of clinical EAPU at that time. Like in PEP-65-induced EAPU treated with Cl_2 MDP-liposomes, the disease still developed a few weeks later, in controls on the other hand, the signs of clinical EAPU gradually decreased. Cl_2 MDP-liposomes deposition subconjunctivally at one eye, did not result in macrophage depletion and suppression of EAPU. The uveitis scores were equally high for treated (OD) and untreated eyes (OS) at the time uveitis was at its peak of inflammation (scores 3.0 to 3.3 at day 13).

EAPU treatment, Cl_2 MDP-liposomes at day 12 and 14; controls In the second type of experiments, therapeutic treatment of EAPU at the time of its peak stage was investigated. Cl_2 MDP-liposomes were intravenously injected at day 12 and 14 when moderate to severe EAPU was clinically manifest (Table I). The treatment resulted in a rapid decrease of the slit-lamp score from 2.5 at day 12 to 0.3 at day 15 whereas control rats injected with PBS-liposomes exhibited little change of their ocular condition. During the

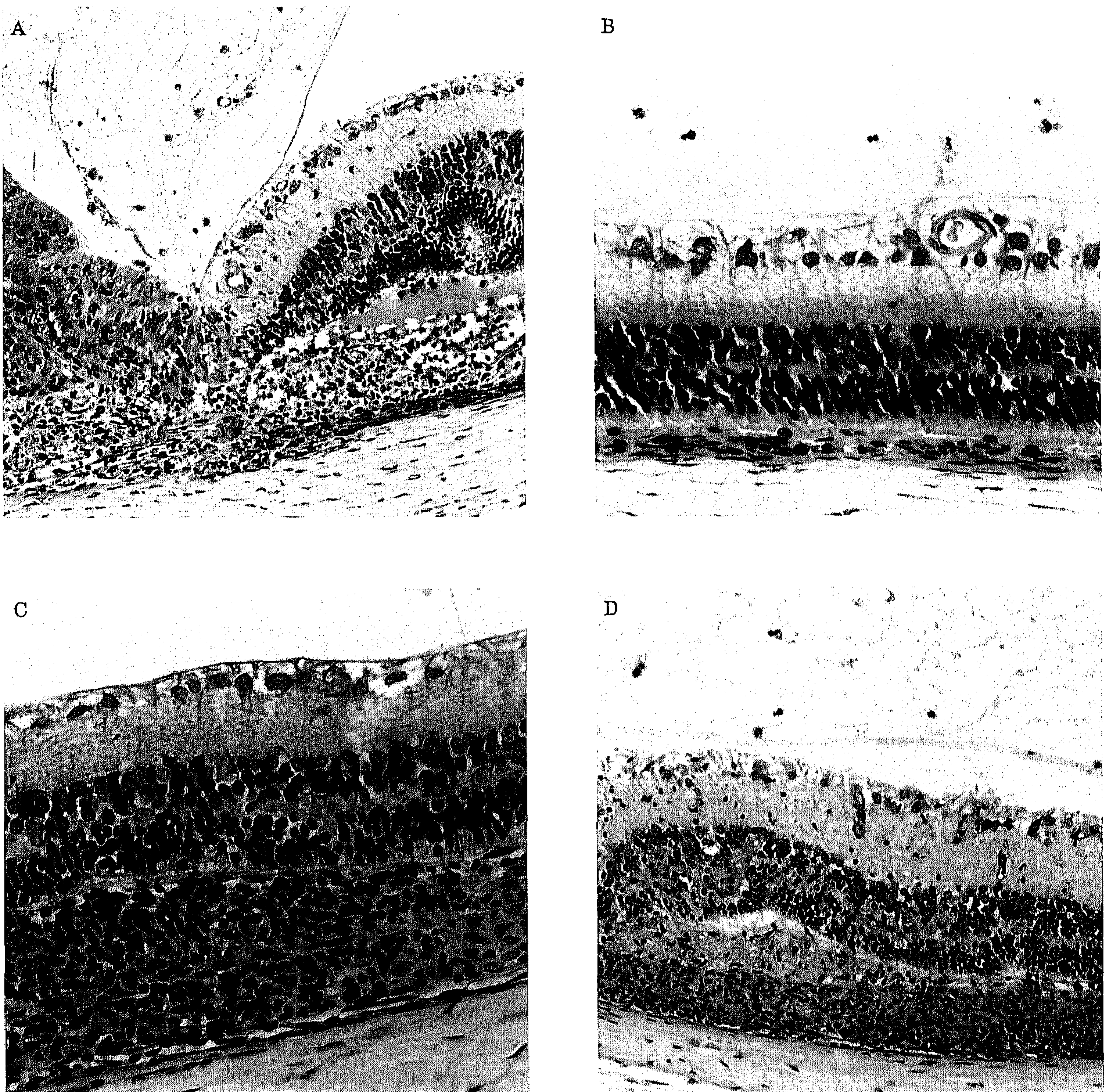


FIG. 1. Histopathology of EAPU in Lewis rats treated with Cl_2 MDP-liposomes (suppression) or PBS-liposomes (controls). (A) Severe EAPU in controls at day 13 after immunization (PBS-liposomes at day 7 and 9). Subretinal exudate, subretinal and choroidal cell accumulations extending into the dystrophic ciliary body. The RPE has been eliminated. $\times 170$. (B) Absence of EAPU at day 13 after immunization as a result of suppression of uveitis by macrophage elimination by Cl_2 MDP-liposome injections at day 7 and 9. Scarce mononuclear cells infiltrated into the choroid and vitreous. $\times 340$. (C) Severe EAPU at day 26 after immunization following initial suppression by Cl_2 MDP-liposome injections at day 7 and 9. Dense chorio-subretinal mononuclear cell accumulations along the destroyed RPE. No inflammatory foci within the neural retina. $\times 340$. (D) Late stage (day 26 after immunization) of very severe EAPU after treatment of the disease by Cl_2 MDP-liposome injections at day 12 and 14 after immunization. Subretinal fibrosis and decay of phagocytes, irregular nuclear layers, dystrophic and absent rod outer segments. $\times 170$.

experimental period of 26 days no recurrence of clinical EAPU was observed in treated rats while the score in controls changed from 2.9 to 1.8 mainly because vitritis gradually decreased.

EMIU treatment, Cl_2 MDP-liposomes at day 7 and 9 (and 12); controls EMIU was induced by two different doses melanin-protein, 10 and 25 μ g, accompanied by 1 and 2 μ g pertussis toxin, and the rats were injected with liposomes at day 7 and 9 or at day 7 and 9 and 12,

respectively. Table I shows that none of the treatments had any influence on the clinical development of EMIU. The scores reached the maximum of 4 in the eyes of treated as well as control rats.

Histopathology

EAPU controls: PBS and PBS-liposomes at day 7 and 9 According to the described clinical observations, the development of EAPU appeared to be effectively

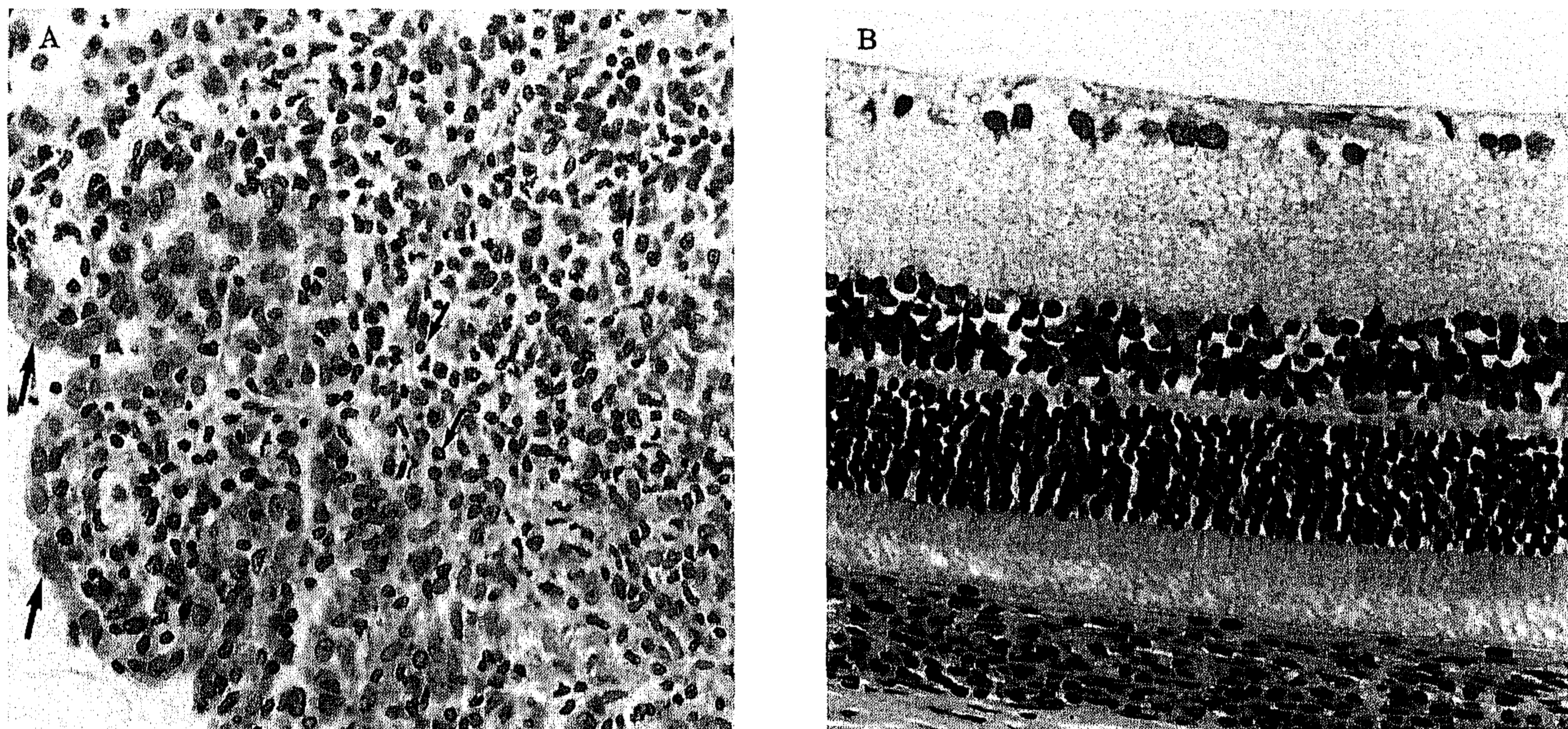


FIG. 2. Histopathology of EMIU in the Lewis rat. (A) Day 12 after immunization, clinical onset of inflammation in PBS-solution injected controls. Massive mononuclear cell infiltration of the ciliary body predominantly consisting of small lymphocytes (small arrows). The ciliary epithelium is at the left (big arrows). $\times 340$. (B) Day 14 after immunization. The animals were treated with Cl_2 MDP-liposomes at day 7 and 9. The choroid is invaded by many mononuclear cells whereas the retina and its RPE remain unaffected. $\times 340$.

inhibited by macrophage depletion. During the development of PBS-liposome treated EAPU (controls), the severity of the clinically observed inflammation closely correlated with those seen histopathologically. In sections of eyes with slit-lamp score 1 (some anterior chamber cells and slight iris vessel dilatation) the entire uvea was slightly infiltrated by mononuclear cells. At slit-lamp scores 2 to 4, severe choroiditis had developed during days 1–5 after the onset of EAPU (at day 9). At the same time, cell accumulations occurred focally adjacent to the RPE-Bruch's membrane layer, some with the appearance of small Dálen-Fuchs-like nodules. These accumulations enlarged further during the development of severe uveitis, and extended along both sides of the RPE-Bruch's membrane layer while the enclosed structure of this layer was destroyed [Fig. 1(A)]. No polymorphonuclear cells or plasma cells were found. The majority of the mononuclear cells were macrophages, but these cells were not found within the photoreceptor cell layer. No inflammatory foci were found to develop within the neuroretina.

Four weeks after immunization of the controls, the cell accumulations had extended still further along both sides of the RPE suggesting that the process of cell accumulation progressed continuously. Many accumulations were situated at the chorioretinal periphery, and in very severe inflammatory reactions the ciliary body became involved. The layer of retinal rods showed thinned areas without the presence of inflammatory cells, and was focally absent. The iris and ciliary body contained only slight mononuclear cell infiltrations even at this advanced stage. Sclera and cornea were not involved. We found no differences between the patterns of EAPU development evoked by PEP-65 and by RPE-TS. The higher slit-lamp scores in

rats with PEP-65 induced EAPU and injected with PBS histopathologically corresponded to more severe choroiditis while the cell accumulations were more extensive.

EAPU treatment, Cl_2 MDP-liposomes at day 7 and 9
Liver and spleen sections exhibited efficient elimination of ED1 + macrophages by the Cl_2 MDP-liposomes in agreement with a previous report (Van Rooijen et al., 1990), while bloodsmears showed the presence of enlarged and vacuolated monocytes indicating that the cells were affected by the Cl_2 MDP-liposomes (Huitinga et al., 1992). In contrast to the observations in control rats, clinical uveitis scores and histopathological observations often did not correspond in the treated groups. In the early stage [day 13], chorioretinal cell infiltrations were absent in the RPE-TS-immunized rats treated with Cl_2 MDP-liposomes which were clinically without signs of uveitis. Yet, slight vitreous cell infiltrations were found in eye sections [Fig. 1(B)]. Some small chorioretinal inflammatory foci were found in the similarly treated PEP-65-immunized rats indicating a slightly higher pathogenicity of this antigen at the applied dose. Two weeks later, severe rebound EAPU developed in both groups. Extensive cell accumulations were then noted along both sides of the RPE [Fig. 1(C)]. At this late stage, the choroid and retinal photoreceptor layer became more or less dystrophic, and the rod outer segments were often disappearing, depending on the severity of EAPU that developed. The phenomena further closely resembled EAPU in controls at its peak stage.

Subconjunctivally injected Cl_2 MDP-liposomes did not inhibit EAPU, and the eyes of these rats and the corresponding controls exhibited the typical histo-

logical features of the peak stage of severe EAPU at the moment of termination of the experiment, day 13. Liver and spleen sections of both groups did not exhibit ED1+ macrophage depletion.

EAPU controls: PBS-liposomes at day 12 and 14 The histopathology of the early [day 12 and 15] and late [day 26] stages exhibited a similar appearance as noted in undisturbed EAPU development at the same timepoints.

EAPU treatment, Cl₂MDP-liposomes at day 12 and 14 In these experiments, the Cl₂MDP- and PBS-liposomes were injected at the peak stage of EAPU development of the group. The histopathological features of this stage in controls have been described above. Clinically, the treated group exhibited a sudden drop in uveitis activity by the disappearance of vitreous and anterior chamber cells during the two days following the injections (as reflected in a drop in the uveitis score, Table I). However, both the sections of eyes enucleated at day 15 and at day 26 exhibited the characteristic histopathological features of the peak stage of EAPU. Hence, already deposited cell accumulations along the RPE [Fig. 1(D)] seemed neither to regress nor to expand during the period of disappearance and absence of the clinical uveitic changes (days 12–26). The number of inflammatory foci also remained constant during this period.

EMIU treatment: Cl₂MDP-liposomes at day 7 and 9, and 7 and 9 and 12; controls Histopathological examination confirmed the clinical observation that Cl₂MDP-liposome treatment did not inhibit or ameliorate EMIU. At the onset of EMIU, the entire uvea was densely infiltrated by mononuclear cells [predominantly lymphoid cells; Fig. 2(A)]. The anterior uvea was swollen and atrophic. These aspects were not different from the ocular histopathology of the PBS-liposome and PBS-solution control groups. The neuroretina was neither affected in the controls nor in the treated rats [Fig. 2(B)]. Sections of liver and spleen showed an effective depletion of macrophages.

General controls: no antigen, no treatment In the eyes of the general controls we did not find any sign of inflammation.

4. Discussion

Effect of Cl₂MDP-liposomes

Among the many possibilities to stop uveoretinitis especially corticosteroids, and more recently cyclosporin have been used in patients. The latter substance also suppresses EAU, EMIU and EAPU as these are T-cell dependent diseases (Gery et al., 1986; Broekhuysse et al., 1992a; 1992b; 1993). As described above (Introduction), these forms of autoimmune uveitis

exhibit different characteristics, and are evoked by antigens originating from different retinal or uveal cell types. The present study shows that hematogenous macrophages are of crucial importance for the generation of EAPU because macrophage depletion by Cl₂MDP-containing liposomes results in a two weeks lasting suppression of EAPU. This treatment is especially effective if applied just before the appearance of the first clinical signs of inflammation, i.e. at day 7 and 9. Treatment at day 8 and 10 appeared to be equally effective but injections at earlier or later points of time injection were less inhibitory (results not shown), in agreement with the findings for EAE suppression by the same protocols (Huitinga et al., 1990). Previous studies have demonstrated that Cl₂MDP-containing liposomes have no effect on the functioning of other cells of the immune system (Claassen, Van Rooijen and Claassen, 1990). Liposomes-encapsulated Cl₂MDP is internalized by the macrophages in liver and spleen, and by the blood monocytes (Van Rooijen, 1989; Huitinga et al., 1990; 1992). As a result, the relative concentration of monocytes decreases whereas increased proportions of enlarged and desintegrating blood monocytes, and polymorphonuclear cells are observed after liposome injections. Repopulation of the depleted tissues and blood has been observed within two weeks. This corresponds to the period of about two weeks after which EAPU started to develop after the initial suppression by Cl₂MDP-liposome injections at day 7 and 9. Macrophage depletion thus seems to be the sole or main cause of the suppression of EAPU. PBS-liposomes slightly ameliorate EAPU, presumably because they are similarly phagocytized by blood monocytes as Cl₂MDP-liposomes, and occupy phagocytic capacity.

Ocular penetration of liposomes before the onset of uveitis in a way that noticeably influences the RPE or other crucial tissue cells in EAPU seems unlikely. Investigations of the central nervous system using the same conditions and type of liposomes showed that the liposomes could not cross the blood-brain barrier until it was damaged by the inflammatory response (Huitinga, 1992). We did not observe histological alteration of retina or uvea in the period between the first intravenous liposome injection and the onset of EMIU when the liposome concentrations were highest while the blood-ocular barrier was still intact (Broekhuysse et al., unpublished result). Subconjunctivally deposited Cl₂MDP-liposomes did not exert any influence on the development of EAPU showing that these liposomes do not easily migrate through the tissues. Furthermore, no focal modification of the disease process was noted during the development of the uveitis process when (remaining) liposomes could have entered the eye via the damaged blood-ocular barrier. At that site, the functionally important RPE cells were immediately destroyed by infiltrating effector cells. In agreement with these considerations, the features of EMIU as well

as of EAPU development in Cl₂MDP-liposome injected rats were the same as in PBS-solution injected controls.

Immunopathogenic Mechanisms in EAPU and EMIU

A marked difference between EAPU, and models like EAE, EMIU and EAU concerns the characteristic massive posterior influx of macrophages in EAPU. These cells accumulate along both sides of the RPE and the presence of such high numbers of blood-borne macrophages suggests that these cells are important effector cells. In general, the important role of (ED1 +) macrophages is in agreement with the present knowledge about the generation of autoimmune inflammations (Huitinga et al., 1992, 1995; Bauer et al., 1996). The macrophages (including those infiltrated in the choroidal-subretinal space) can secrete many products that may play multiple roles in non-specific inflammatory reactions. Effector molecules produced by activated macrophages like eicosanoids, reactive oxygen species, proteinases, IL-1, IL-6, and TNF- α can damage the blood-ocular barriers and attract and activate immunocompetent cells. This is one of the possible explanations why early macrophage depletion is so effective in EAPU. The rebound effect two weeks afterwards may be evoked by still intact RPE attracting RPE-protein specific T-cells after the appearance of new macrophages. It has been argued that an additional important attractor of phagocytes in this stage may be the damage-activated RPE, possibly through the action of the release of cytokines (Broekhuysse et al., 1996). Hence, when the RPE has focally been destroyed (resulting in termination of cytokine release) the accumulation along these areas ceases, as has been noted. In view of this cytokine-mediated phagocyte attraction, the successful suppression of EAPU by macrophage depletion after its onset might in addition be explained by the elimination of the accumulating cell type irrespective of its effector cell function.

Our experiments show that EMIU does not respond to macrophage depletion in contrast to EAPU (Table I). Hence, macrophages seem to be less important for the initiation of EMIU. Other effector cells like cytotoxic T-cells may exert this function (polymorphonuclear cells have not been found among the early invading cells). Thus the investigated two forms of autoantigen-induced uveitis in the Lewis rat could be evoked by more or less different immunopathogenic mechanisms because the injected cell-specific uveitogenic antigens from RPE cell membranes and choroidal melanocytes evoke different effector mechanisms. The immunopathogenesis of EAPU appears to be macrophage-dependent whereas that in EMIU is not. In both forms of uveitis, T-cells have been found to enter the uveal tissue. In developing EAPU they constitute a minor fraction of the invading mononuclear cells which consists predominantly of macrophages. However, at the onset of EMIU lymphoid cells virtually constitute

the entire population of the infiltrating cells in the uvea where the antigen is localized. The observed scarce presence of macrophages in the uvea at the onset of EMIU is in agreement with previous studies of Broekhuysse et al. (1991, 1992a). Chan et al. (1994) reported the predominance of lymphocytes over macrophages during the whole course of EMIU. These data are in line with the above hypothesis. No primary RPE involvement has been noticed in EMIU that could result in the generation of signals like cytokine release. Possibly this is another reason why a massive macrophage influx like in EAPU is not triggered at the onset of EMIU. To study the significance of these phenomena and the role of the RPE, further immunological investigations are needed, and immunocytochemical analyses are in progress.

Acknowledgement

Part of this study (aspects of macrophage depletion) was financed by the Dutch Multiple Sclerosis Foundation 'Friends MS Research'.

References

- Bauer, J., Ruuls, S. R., Huitinga, I. and Dijkstra, C. D. (1996). The role of macrophage subpopulations in autoimmune disease of the central nervous system. *Histochem. J.* 28, 83-97.
- Bora, N. S., Kim, M. C., Kabeer, N. H., Simpson, S. C., Tandhasetti, M. T., Cirrito, T. P., Kaplan, A. D. and Kaplan, H. J. (1995). Experimental autoimmune anterior uveitis. Induction with melanin-associated antigen from the iris and ciliary body. *Invest. Ophthalmol. Vis. Sci.* 36, 1056-66.
- Broekhuysse, R. M. and Kuhlmann, E. D. (1993). Experimental autoimmune anterior uveitis. The preparation of uveitogenic ocular melanin. *Invest. Ophthalmol. Vis. Sci.* 34, 698-700.
- Broekhuysse, R. M. and Kuhlmann, E. D. (1997). Uveitogenic 28/32 and 43 kD polypeptides in pigment epithelial membranes of the retina. *Ocular Imm. Inflamm.* 5, 19-26.
- Broekhuysse, R. M., Kuhlmann, E. D., Winkens, H. J. and Van Vugt, A. H. M. (1991). Experimental autoimmune anterior uveitis (EAAU), a new form of experimental uveitis. I. Induction by a detergent-insoluble, intrinsic protein fraction of the retinal pigment epithelium. *Exp. Eye Res.* 52, 465-74.
- Broekhuysse, R. M., Kuhlmann, E. D. and Winkens, H. J. (1992a). Experimental autoimmune anterior uveitis (EAAU). II. Dose-dependent induction and adoptive transfer using a melanin-bound antigen of the retinal pigment epithelium. *Exp. Eye Res.* 55, 401-11.
- Broekhuysse, R. M., Kuhlmann, E. D. and Winkens, H. J. (1992b). Experimental autoimmune posterior uveitis accompanied by epitheloid cell accumulations (EAPU). A new type of experimental ocular disease induced by immunization with PEP-65, a pigment epithelial polypeptide preparation. *Exp. Eye Res.* 55, 819-29.
- Broekhuysse, R. M., Kuhlmann, E. D. and Winkens, H. J. (1993). Experimental autoimmune anterior uveitis (EAAU). III. Induction by immunization with purified uveal and skin melanins. *Exp. Eye Res.* 56, 575-83.
- Broekhuysse, R. M., Kuhlmann, E. D., Peters, T. and Kuypers,

- W. (1996). Macrophage subpopulations and RPE elimination in the pathogenesis of experimental autoimmune pigment epithelial protein-induced uveitis (EAPU). *Exp. Eye Res.* **62**, 471-80.
- Chan, C. C., Hikita, N., Dastgheib, K., Whitcup, S. M., Gery, I. and Nussenblatt, R. B. (1994). Experimental melanin-protein induced uveitis in the Lewis rat: immunopathological processes. *Ophthalmology* **101**, 1275-80.
- Claassen, Y., Van Rooijen, N. and Claassen, E. (1990). A new method for removal of mononuclear phagocytes from heterogenous cell populations in vitro, using liposome-encapsulated dicloromethylene diphosphate. *J. Immunol. Methods* **134**, 153-61.
- Faure, J. P. (1980). Autoimmunity and the retina. In: *Current topics in eye research*, Vol. 2. Pp. 215-302. Academic Press: London, U.K.
- Gery, I., Mochizuki, M. and Nussenblatt, R. (1986). Retinal specific antigens and the immunopathogenic process they provoke. *Progr. Ret. Res.* **5**, 75-109.
- Huitinga, I. (1992). The role of macrophages in the pathogenesis of experimental allergic encephalomyelitis. Thesis, Amsterdam, Chapter III-2.
- Huitinga, I., Van Rooijen, N., De Groot, C. J. A., Uitdehaag, B. M. J. and Dijkstra, C. D. (1990). Suppression of experimental allergic encephalomyelitis in Lewis rats after elimination of macrophages. *J. Exp. Med.* **172**, 1025-33.
- Huitinga, I., Ruuls, S. R., Jung, S., Hartung, H. P., Van Rooijen, N. and Dijkstra, C. D. (1992). The role of macrophages in the central nervous system of Lewis rats with T-cell induced experimental allergic encephalomyelitis. *Immunobiol.* **185**, 11-9.
- Huitinga, I., Ruuls, S. R., Jung, S., Van Rooijen, N., Hartung, H. P. and Dijkstra, C. D. (1995). Macrophages in T cell line-mediated, demyelinating and chronic relapsing experimental autoimmune encephalomyelitis in Lewis rats. *Clin. Exp. Immunol.* **100**, 344-51.
- Van Rooijen, N. (1989). The liposome mediated macrophage 'suicide' technique. *J. Immunol. Methods* **124**, 1-6.
- Van Rooijen, N., Kors, N., Van de Ende, M. and Dijkstra, C. D. (1990). Depletion and repopulation of macrophages in spleen and liver of rat after intravenous treatment with liposomes-encapsulated dichloromethylene diphosphate. *Cell Tiss. Res.* **260**, 215-22.