

PDF hosted at the Radboud Repository of the Radboud University Nijmegen

The following full text is a publisher's version.

For additional information about this publication click this link.

<http://hdl.handle.net/2066/25160>

Please be advised that this information was generated on 2017-12-05 and may be subject to change.

H. Brink
A. Deutman
L. Beex

Unusual retinal pigment epitheliopathy and choroidopathy in carcinomatosis: a rare case of cancer-associated retinopathy

Received: 22 April 1996
Revised version received: 23 August 1996
Accepted: 30 September 1996

H. Brink (✉)
Institute of Ophthalmology,
Bosch Medicentrum, PO Box 90153,
5200 ME's-Hertogenbosch,
The Netherlands
Tel. +31-73-6862878;
fax +31-24-3540522

A. Deutman
Institute of Ophthalmology,
Nijmegen University Hospital,
Nijmegen, The Netherlands

L. Beex
Institute of Endocrinology,
Nijmegen University Hospital,
Nijmegen, The Netherlands

Abstract ● **Background:** Cancer-associated retinopathy is a syndrome causing ocular symptoms. It is a rare entity and only a few cases have been reported. ● **Methods:** A 67-year-old woman with small-cell endometrial carcinoma suffering from deterioration of visual acuity is presented. ● **Results:** The patient presented with extensive mottled changes of the retinal pigment epithelium, accompanied by diffuse subretinal fluid in the posterior pole and exudative retinal detachments inferior in both eyes. ● **Conclusion:** This patient suffered from a rare variety of cancer-associated retinopathy.

Introduction

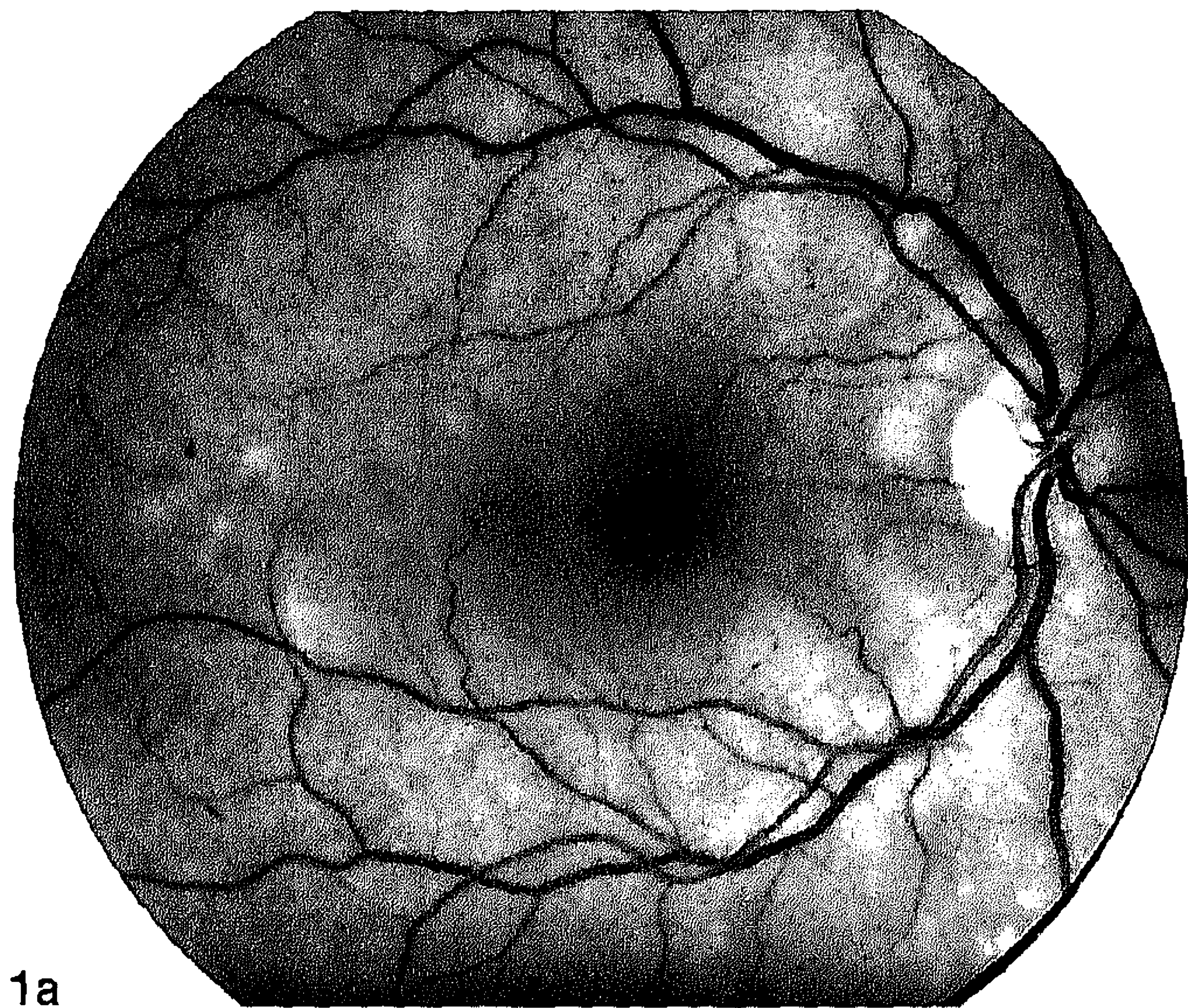
Patients with malignant disease may suffer from ocular complaints caused by metastatic disease to the eye and orbit or ascribed to the side effects of cytotoxic drugs. Cancer-associated retinopathy is another, rare entity causing visual complaints and ocular symptoms. We present a patient with an unusual manifestation of malignant disease.

Case report

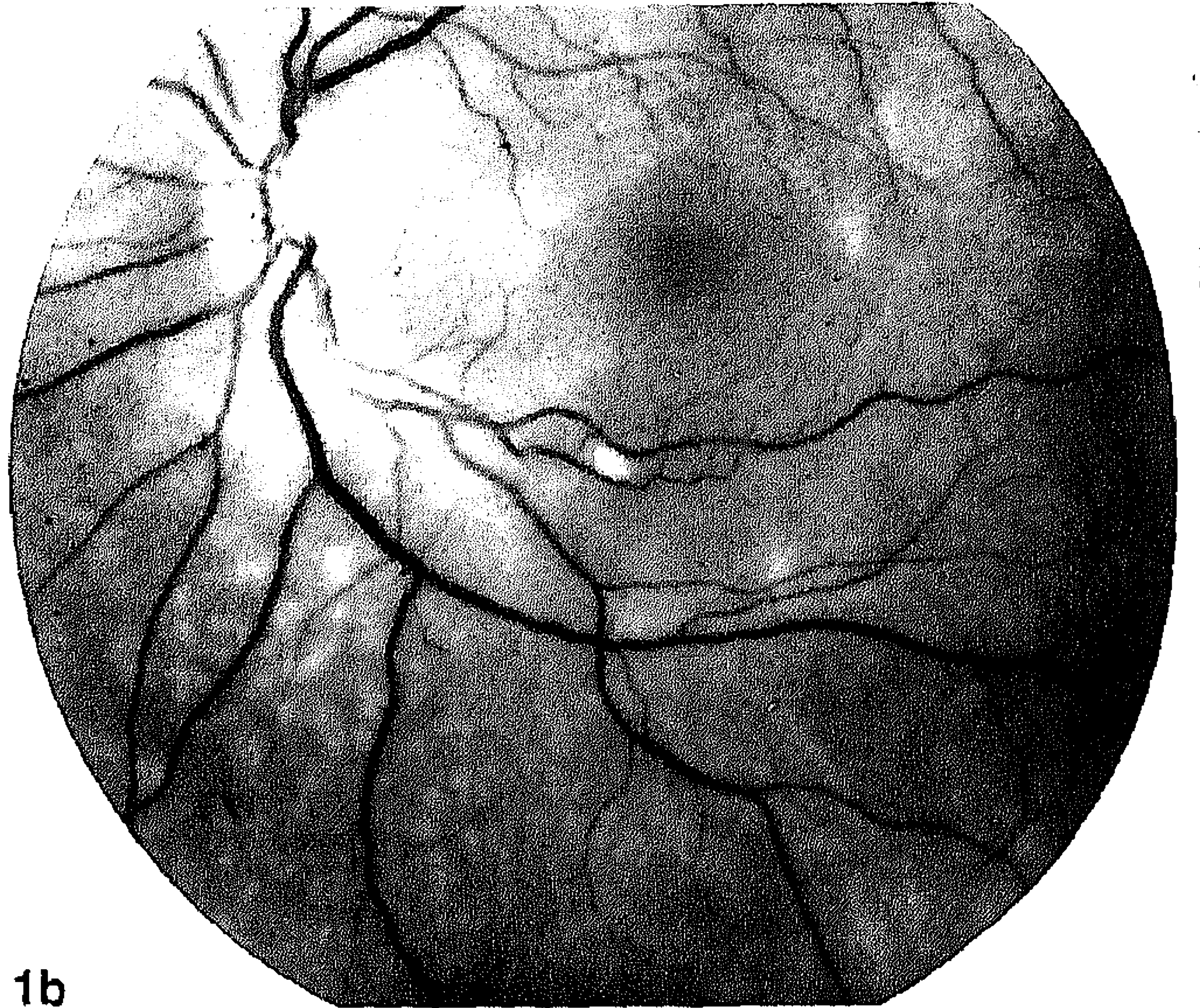
A 67-year-old woman was referred by her internist because of deterioration of visual acuity in both eyes. Previous history revealed breast cancer 30 years earlier. No metastases from this primary tumour had been demonstrated. One year prior to referral, uterus and adnexa had been extirpated because of a moderately differentiated carcinoma of the endometrium. She had been treated with medroxyprogesterone following progressive local lymph

node metastases and metastases to the liver and vagina, originating from endometrial carcinoma. At the time of referral she was in a very poor general condition and bed-ridden.

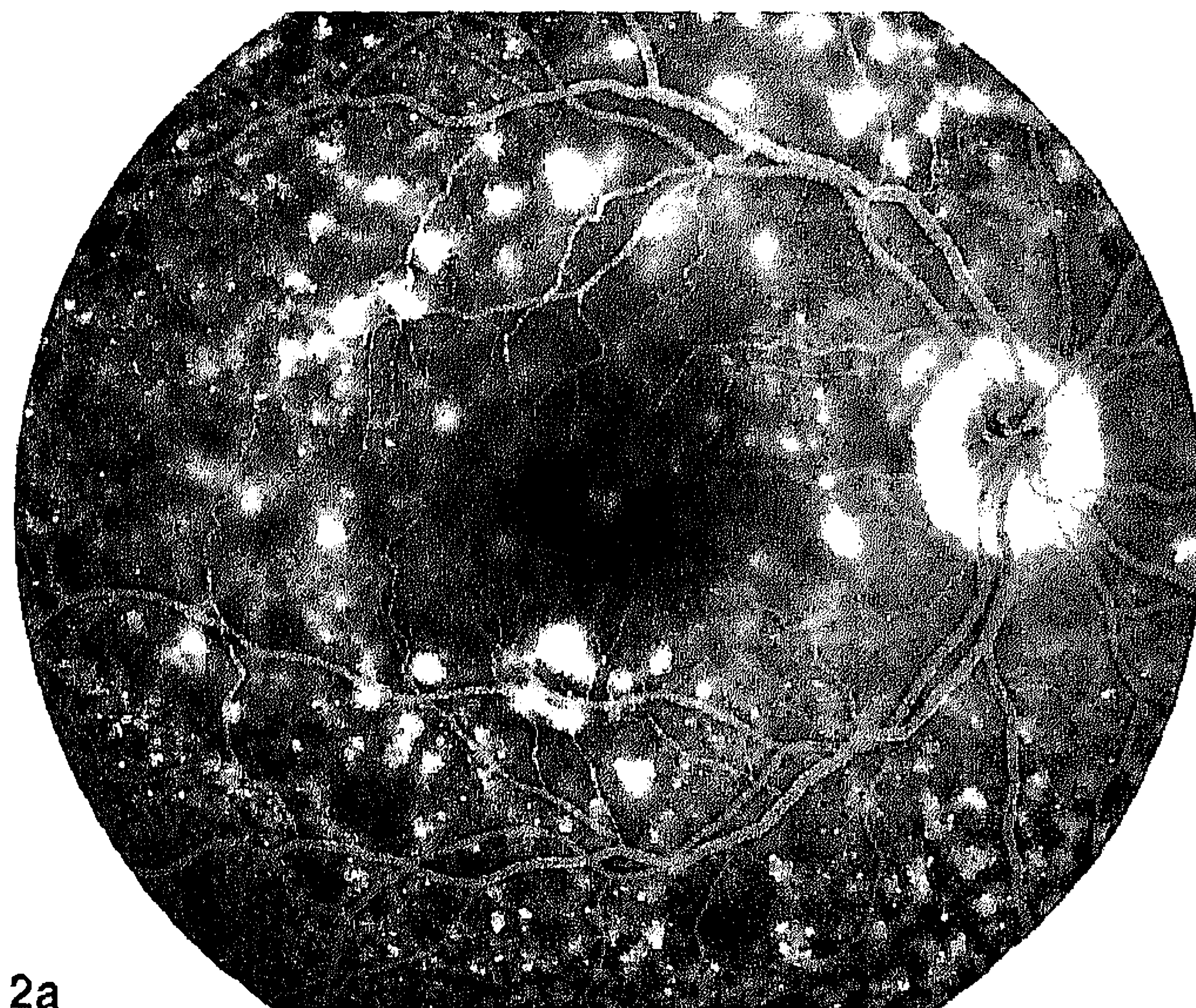
Visual acuity in both eyes was 0.3 with a +5.0 spherical correction in the right eye and +7.0 spherical correction in the left eye. The patient's normal spherical correction was +2.0 in both eyes. At slit-lamp examination both lenses exhibited increased opacities. The intraocular pressure was 15 mmHg in both eyes. Ophthalmoscopy revealed yellowish choroidal alterations surrounding the optic disc, extending along the superior retinal vessels and spreading to the temporal inferior quadrant in the right eye. The left eye revealed discoloration of the choroid inferior to the optic disc and fovea with some retinal exudates. In both eyes a large area of diffuse subretinal fluid in the posterior pole surrounded by leopardskin-like alterations of the retinal pigment epithelium was observed (Fig. 1). Both eyes exhibited inferior exudative retinal detachments. Fluorescein angiography revealed a striking aspect of extensive early patchy staining of the complete fundus posterior to the equator, with subretinal fluid in the posterior pole and hyperfluorescent spots in late phases of the angiogram. The area of choroidal alteration, as observed at ophthalmoscopy, could not be distinguished from the surrounding choroid by means of angiography (Fig. 2). With ultrasonography no obvious thickening of the choroids could be detected in either eye. Serous detach-



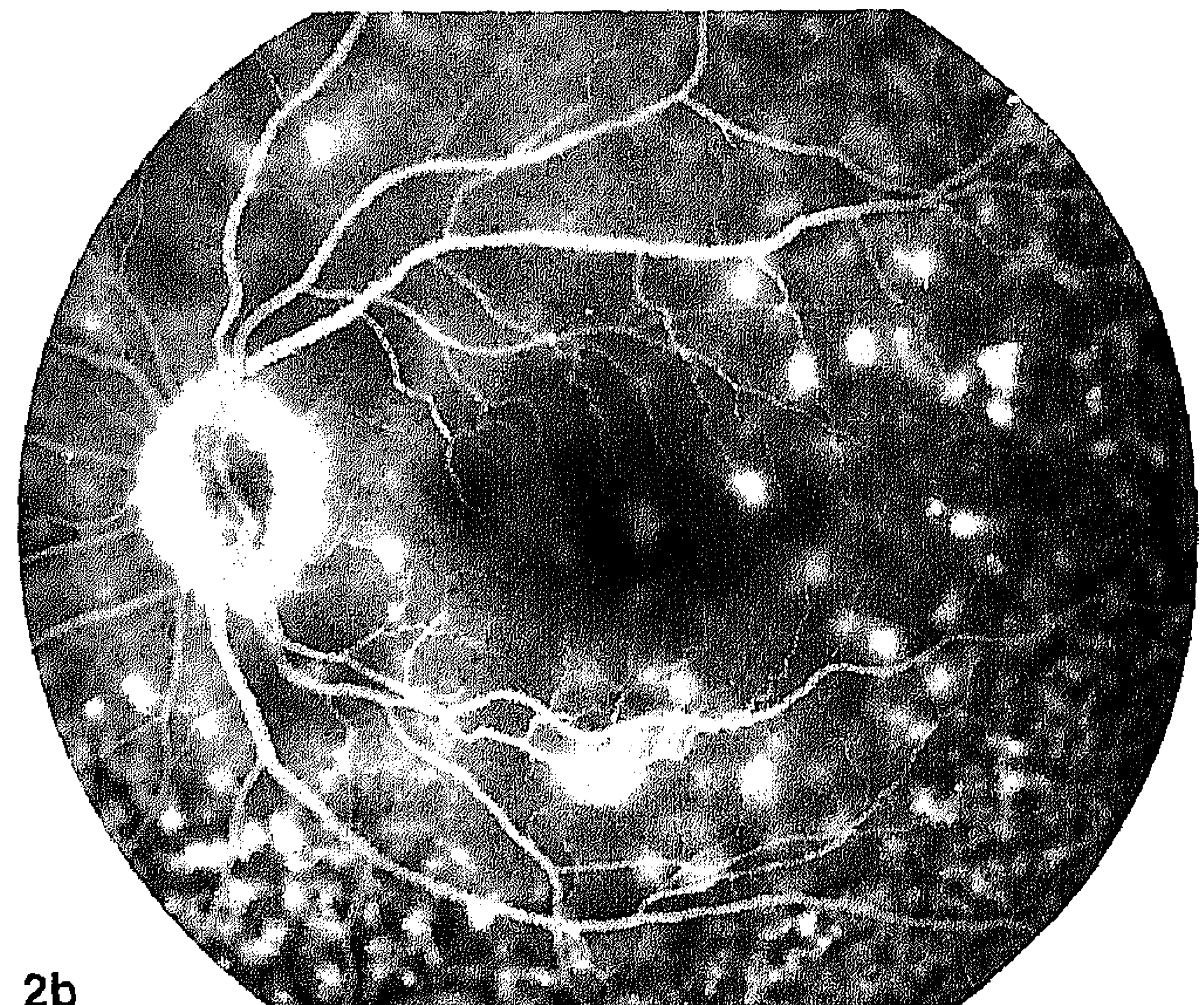
1a



1b



2a



2b

Fig. 1 Fundus photographs of the right (a) and left (b) eyes, showing choroidal infiltration surrounding the optic disc in the right eye and inferior to the optic disc and fovea in the left eye

Fig. 2 Fluorescein angiography of the right eye (a, late venous phase) and left eye (b, venous phase), showing extensive patchy staining posterior to the equator, subretinal fluid at the posterior pole and hyperfluorescent spots

ments of the retina in the macular area and exudative retinal detachments inferior were evident.

Because of the poor condition of the patient no further examination could be performed. On grounds of her poor visual acuity and hypermetropisation she was presented for radiotherapy. Using the linear accelerator (6 MeV) a total dose of 30.0 Gy in 10 daily fractions was administered via two lateral beams to both eyes. However, a drop in visual acuity in both eyes to hand movements, due to further increase of subretinal fluid leading to bullous retinal detachments, could not be prevented. The clinical condition of the patient deteriorated rapidly and she died 4 months after first ocular examination. Consent for post-mortem examination was not obtained.

Discussion

Patients with carcinoma-associated retinopathy often present with progressive visual loss, loss of colour vision and night blindness. Electrophysiology reveals marked attenuation of the electroretinogram in almost all cases. Arteriolar narrowing has been described. Rarely, changes of the retinal pigment epithelium are found [4, 5]. Antibodies reacting with retinal tissue have been identified in patients with cancer-associated retinopathy [3, 5].

Most patients with cancer-associated retinopathy suffer from small-cell lung cancer [5]. However, the cases of two patients with cancer-associated retinopathy suffering from the very rare small-cell endometrial carcinoma have been published. Crofts et al. [2] in 1988 described a 64-year-old patient with a unilateral de-

crease in visual acuity. Fundus examination showed mild attenuation of retinal arterioles and nonspecific mottling of the retinal pigment epithelium in the mid-periphery. Permission for autopsy was refused. Campo et al. [1] in 1992 presented the case of a 72-year-old woman with acute progressive loss of visual acuity and signs of bilateral attenuation of the retinal vessels. Pathologic findings included loss of inner and outer segments of photoreceptors in the macular region with absence of the outer nuclear layer. In other areas of the retina, disruption of the retinal pigment epithelium corresponding with loss of photoreceptors was observed.

We believe that the findings in our patient are consistent with cancer-associated retinopathy. She suffered

from breast cancer 30 years prior to her ocular complaints but was cured. More recently she was treated for a very rare metastasised small-cell endometrial carcinoma. She presented with a severe drop in visual acuity in both eyes. Compared to the cases published by Crofts et al. [2] and Campo et al. [1], alterations of the retinal pigment epithelium were far more widespread, and were especially striking in the fluorescence angiogram. Exceptional are the areas of subretinal fluid in the posterior poles and exudative retinal detachments inferior in both eyes. We believe we have presented a patient with a rare variety of cancer-associated retinopathy in small-cell endometrial carcinoma.

References

1. Campo E, Brunier MN, Merino MJ (1992) Small cell carcinoma of the endometrium with associated ocular paraneoplastic syndrome. *Cancer* 69: 2283–2288
2. Crofts JW, Bachynski BN, Odel JG (1988) Visual paraneoplastic syndrome associated with undifferentiated endometrial carcinoma. *Can J Ophthalmol* 23: 128–132
3. Grunwald GB, Klein R, Simmonds MA, Kornguth SE (1985) Autoimmune basis for visual paraneoplastic syndrome in patients with small-cell lung carcinoma. *Lancet* 658–661
4. Sawyer RA, Selhorst JB, Zimmerman LE, Hoyt WF (1976) Blindness caused by photoreceptor degeneration as a remote effect of cancer. *Am J Ophthalmol* 81: 606–613
5. Thirkill CE, Keltner JL, Tyler NK, Roth AM (1993) Antibody reactions with retina and cancer-associated antigens in 10 patients with cancer-associated retinopathy. *Arch Ophthalmol* 111: 931–937