

PDF hosted at the Radboud Repository of the Radboud University Nijmegen

The following full text is a publisher's version.

For additional information about this publication click this link.

<http://hdl.handle.net/2066/25063>

Please be advised that this information was generated on 2017-12-05 and may be subject to change.

The Place of Renal Scintigraphy in the Diagnosis of Renal Artery Stenosis

Fifteen Years of Clinical Experience

Brigit C. van Jaarsveld, MD; Pieta Krijnen, MSc; Frans H. M. Derkx, MD, PhD; H. Yoe Oei, MD, PhD; Cornelis T. Postma, MD, PhD; Maarten A. D. H. Schalekamp, MD, PhD

Background: Renal scintigraphy with radiolabeled pentetic acid (diethylenetriamine pentaacetic acid [DTPA]) or, more recently, mertiatide (mercaptoacetyltriglycine [MAG₃]), with or without captopril challenge, is widely recommended as a diagnostic test for renal artery stenosis.

Objectives: To address (1) whether the diagnostic accuracy has been improved by the use of captopril and the introduction of mertiatide and (2) whether a renal scan that shows abnormalities is a useful criterion to select patients for renal arteriography.

Patients and Methods: A standard diagnostic protocol, using both scintigraphy and arteriography, was followed in 505 consecutive high-risk hypertensive patients who were evaluated for renovascular hypertension at the University Hospital Dijkzigt, Rotterdam, the Netherlands, from 1978 to 1992.

Results: Renal artery stenosis ($\geq 50\%$) was present in 263 patients. When the single-kidney fractional uptake was used as a diagnostic criterion, a specificity of 0.90 was obtained at a cutoff value of 35% for the worst kidney in scintigraphy using pentetic acid without captopril challenge (n=225) and at a cutoff value of 37% after captopril challenge (n=280). This was associated with

sensitivity levels of 0.65 and 0.68, respectively. The difference between the uptake of pentetic acid with and without captopril challenge in the 85 patients who were studied under both circumstances was no more accurate as a predictor of renal artery stenosis. In the 93 patients who were studied with mertiatide as well as with pentetic acid, both after captopril challenge, the diagnostic accuracy was no better with mertiatide than with pentetic acid; mertiatide failed to offer any advantage not only when the single-kidney fractional uptake was used as a criterion, but also with the use of other scintigraphic parameters (eg, time to peak, time to pyelum, overall shape of renographic curve, and kidney size).

Conclusions: The diagnostic accuracy of renal scintigraphy has not been improved by the introduction of mertiatide or by the use of captopril. The usefulness of scintigraphy as a diagnostic test for the presence of renal artery stenosis remains questionable. The physician will always confront either a substantial number of arteriograms that do not show abnormalities when renal scintigraphy is omitted as a screening step or a substantial number of missed diagnoses when a renal scan that shows abnormalities is used as a prerequisite for arteriography.

Arch Intern Med. 1997;157:1226-1234

From the Departments of Internal Medicine I (Drs van Jaarsveld, Derkx, and Schalekamp), Clinical Decision Analysis (Ms Krijnen), and Nuclear Medicine (Dr Oei), University Hospital Dijkzigt, Rotterdam, and the Department of Internal Medicine, University Hospital, Nijmegen (Dr Postma), the Netherlands.

THE PLACE of renal scintigraphy in the diagnosis of renovascular hypertension has been hotly debated. Scintigraphy is thought to be the most reliable noninvasive procedure currently available for predicting the presence of a clinically significant renal artery stenosis.¹⁻¹⁰ A renal scan that shows abnormalities is therefore used as the basis for selecting hypertensive patients who will require further diagnostic workup with renal arteriography. Clinical experience, however, shows that the predictive value of renal scintigraphy is highly variable, and it depends on the selection of patients, on the criteria by which the renal scans are analyzed, and on the radiopharmaceuti-

cal that is used.^{8,11-13} In addition, many clinicians believe that in a patient with severe drug-resistant hypertension, particularly when this condition is associated with signs of generalized atherosclerosis, arteriography is warranted irrespective of whether the renal scan shows abnormalities.

During the past 15 years, all patients who were evaluated for renovascular hypertension at our hypertension center underwent both renal scintigraphy and arteriography. Most of these patients had been referred because of severe hypertension that was difficult to treat; some were referred because their hypertension was associated with generalized atherosclerosis or with an abdominal bruit. Our stan-

PATIENTS AND METHODS

This study comprised 505 consecutive high-risk hypertensive patients who were referred to the University Hospital Dijkzigt, Rotterdam, the Netherlands, from 1978 to 1992 for evaluation of possible renovascular hypertension. All patients underwent renal scintigraphy and arteriography according to a standard protocol. The reasons for referral were 1 or more of the following conditions: (1) refractory hypertension (diastolic blood pressure ≥ 95 mm Hg while receiving 3 antihypertensive drugs); (2) severe hypertension (diastolic blood pressure ≥ 110 mm Hg that was associated with signs of generalized atherosclerotic disease [coronary heart disease and/or intermittent claudication]); (3) severe hypertension before reaching the age of 40 years; (4) the presence of an abdominal bruit; or (5) a rise in the serum creatinine level of $20 \mu\text{mol/L}$ or greater (≥ 0.23 mg/dL) during treatment with an ACE inhibitor. The majority of patients had refractory hypertension. None of the patients exhibited evidence of endocrine or renal parenchymal disease. The results of urinalysis and the levels of serum electrolytes, thyrotropin (thyroid-stimulating hormone), and plasma catecholamines were normal; the plasma cortisol level showed adequate overnight suppression after dexamethasone. The serum creatinine level was greater than $106 \mu\text{mol/L}$ (>1.2 mg/dL) in 239 patients and greater than $221 \mu\text{mol/L}$ (>2.5 mg/dL) in 27 patients.

Our analysis encompassed the following 4 study groups (**Figure 1**): group 1, scintigraphy using pentetic acid without captopril ($n=182$); group 2, scintigraphy using pentetic acid both without captopril and following a challenge with 50 mg of captopril at 2 to 8 weeks later ($n=85$); group 3, scintigraphy using pentetic acid after a challenge with 50 mg of captopril ($n=145$); and group 4, scintigraphy using pentetic acid and mertiatide, performed 2 to 8 weeks apart, both after captopril challenge ($n=93$).

SCINTIGRAPHIC PROCEDURES AND DATA ANALYSIS

In patients who were receiving long-term ACE inhibitor treatment, the ACE inhibitor was withheld for at least 24 hours before scintigraphy was performed. Patients who underwent scintigraphy with captopril challenge received 50 mg of captopril orally at 1 hour before the examination. To ensure adequate absorption of captopril, patients were required to fast during the 4 hours preceding scintigraphy. Sufficient hydration was guaranteed by the oral administration of 0.5 L of tap water. Blood pressure was measured with an automatic device (Accutorr 1A and 3, Datascope, Datascope Corp, Montvale, NJ) before administration of captopril and every 5 to 10 minutes for 2 hours after administration of captopril.

Scintigraphy was performed with the patient in a supine position, and the detector was placed posteriorly. After intravenous administration of $^{99\text{m}}\text{Tc}$ -pentetic acid or

$^{99\text{m}}\text{Tc}$ -mertiatide, data were collected in 10-second frames during a 20-minute period, and sequential analog images were obtained every minute. Regions of interest were delineated by the computer, and an area for background correction was placed between the kidneys.¹⁴ The single-kidney contribution to the total renal uptake of the radionuclide, measured during the second minute after injection, was expressed as a percentage of the net total of 2-kidney counts (single-kidney fractional uptake). The kidney with the lowest uptake was considered to be the kidney that was most likely to be affected.

In the patients who were studied with both pentetic acid and mertiatide renography, the following criteria other than the single-kidney fractional uptake of radionuclide were also analyzed^{6,14-16}: (1) visual assessment of kidney size (normal or small); (2) time until activity appeared in the renal pelvis, determined by visual evaluation of the 1-minute sequential images by the nuclear radiologist (time to pyelum); (3) time-to-peak activity (T_{max} [ie, the time until the maximal amplitude of the renogram was reached]); (4) the overall pattern of the renographic curve; and (5) interpretation by the nuclear radiologist (suspect or not suspect). The receiver operating characteristic (ROC) curves were generated for various parameters of scintigraphy.¹⁷

Arteriography was performed via the femoral approach. In the vast majority of patients, aortography with the digital subtraction technique resulted in adequate visualization of the renal arteries and their main branches. In cases of doubt about the patency of the renal artery, a selective ostial injection of a radiocontrast medium was given. A stenosis was considered to be significant when the diameter of the arterial lumen was reduced by 50% or more. In patients with bilateral renal artery stenosis, the kidney with the most severe stenosis on the arteriogram was referred to as the affected kidney. In the same session in which arteriography was performed, the effective renal plasma flow and glomerular filtration rate (GFR) were determined with the continuous infusion method using iodohippurate sodium I 131 (Hippuran I 131) and thalamate iodine I 125 and measuring radioactivity in plasma at the steady state.¹⁸

STATISTICAL ANALYSES

Data are presented as mean \pm SD or as the medians and ranges, unless stated otherwise. Comparisons of variables with a binomial distribution were made using the χ^2 test. Comparisons of variables with a normal distribution were made using the Student *t* test and 1-way analysis of variance, and comparisons of variables with a skewed distribution were made using the Mann-Whitney *U* test and the Kruskal-Wallis test. Differences in diagnostic performance between scintigraphy using pentetic acid with and without captopril challenge and between scintigraphy using pentetic acid and mertiatide were assessed by comparing the areas under the ROC curves.¹⁹ Two-tailed *P* values less than .05 were considered to indicate statistical significance.

standard practice of always performing arteriography after scintigraphy remained constant during this 15-year period, although the methods that were used to prepare patients for scintigraphy and the scintigraphic procedures were modified in accordance with prevailing recommen-

dations. From 1978 to 1983, technetium Tc 99m-labeled pentetic acid (diethylenetriamine pentaacetic acid [DTPA]) was used for renal scintigraphy. From 1983 to 1990, the angiotensin-converting enzyme (ACE) inhibitor captopril was administered to enhance the diagnos-

tic accuracy of scintigraphy with pentetic acid.^{1,2} From 1990 to 1992, ^{99m}Tc-pentetic acid, which is a marker of glomerular filtration, was gradually replaced by technetium Tc 99m-labeled mertiatide (mercaptoacetyltriglycine [^{99m}Tc-MAG₃]), which is a marker of renal blood flow.¹²

Because renal arteriography was always performed after renal scintigraphy in our center, it was possible for us to address the following questions: (1) Have the sensitivity and specificity of renal scintigraphy been improved by the use of captopril? (2) Have the sensitivity and specificity of scintigraphy been improved by the use of mertiatide instead of pentetic acid? (3) Does our experience confirm that a renal scan with abnormalities is a useful criterion for selecting patients for arteriography?

RESULTS

RENAL ARTERIOGRAPHY

Of the total of 505 consecutive patients evaluated for renovascular hypertension, renal artery stenosis was shown on the arteriograms of 263. The remaining patients were considered to have essential hypertension. The prevalence of renal artery stenosis in the 4 study groups varied from

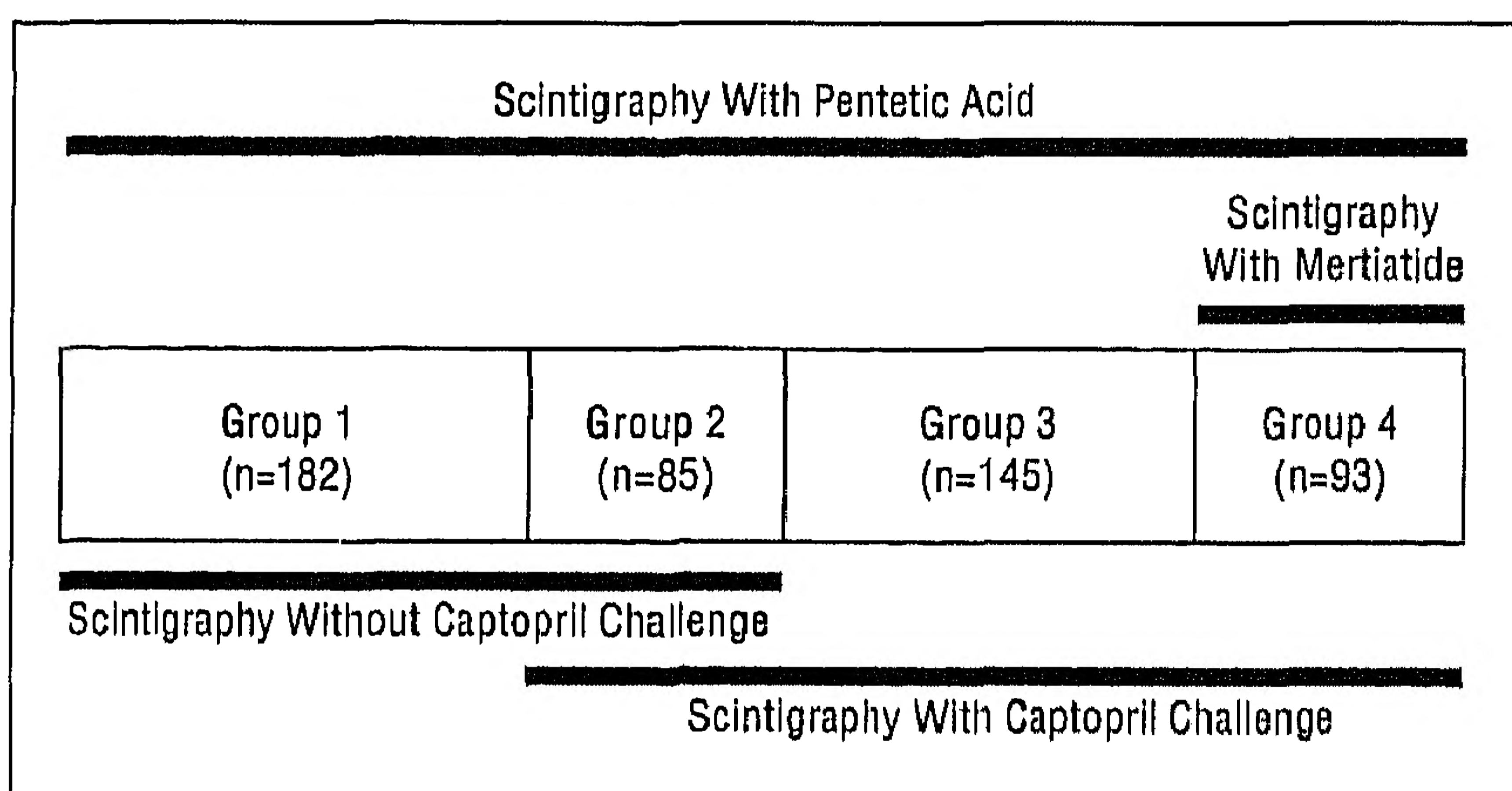


Figure 1. Study groups divided according to scintigraphic procedure.

42% to 55% (**Table 1**). In the overwhelming majority of patients with renal artery stenosis (86%), the stenosis was attributable to atherosclerosis, which was right-sided in 66 patients, left-sided in 81, and bilateral in the remaining 78. Bilateral fibromuscular dysplasia was observed in 16 patients and unilateral dysplasia in 22 patients, 19 of whom showed right-sided localization. There were minor differences in blood pressure, the serum creatinine level, GFR, and body mass index (defined as the weight in kilograms divided by the height in meters squared) among the 4 study groups, but these differences were not important enough to warrant inclusion in our analysis.

In **Table 2**, the key clinical characteristics of the patients with renal artery stenosis are compared with those of the subjects with essential hypertension. As expected, the patients with renal artery stenosis were older, had higher serum creatinine levels, a lower renal plasma flow, and a lower GFR. The somewhat higher body mass index in the patients with essential hypertension can be explained by the high prevalence of obesity in patients with severe drug-resistant essential hypertension.²⁰ The systolic blood pressure was higher in patients with renal artery stenosis, while the diastolic blood pressure was equal in both groups.

The number of serious complications caused by arteriography was small. Renal function impairment (serum creatinine level >221 μmol/L [>2.5 mg/dL]), which was reversible, was seen in 8 patients. One patient had a hematoma at the puncture site that required surgical decompression. One patient suffered from cholesterol crystal embolization, with livedo reticularis in both legs.

EFFECT OF CAPTOPRIL ON THE RENAL SCAN

Between-Patient Comparison

Results obtained in the subjects who underwent scintigraphy using pentetic acid without captopril challenge were compared with those in the subjects who underwent scin-

Table 1. Characteristics of Hypertensive Patients Who Underwent Renal Scintigraphy and Arteriography*

Characteristic	Pentetic Acid				P
	Without Captopril, Group 1 (n=182)	Without Captopril and Then With 50 mg of Captopril 2 to 8 wk Later, Group 2 (n=85)	After 50 mg of Captopril, Group 3 (n=145)	With Mertiatide, Group 4 (n=93)	
Males, %	59	65	62	56	.64
Age, y	51.3±15.1	52.0±12.7	53.9±12.8	52.5±12.8	.39
Body mass index, kg/m ²	24.2±4.2	24.8±3.3	24.7±3.5	26.0±5.2	.007
Median serum creatinine level, μmol/L (mg/dL); range	105 (1.19); 62-631 (0.70-7.14)	101 (1.14); 60-269 (0.68-3.04)	120 (1.36); 37-338 (0.42-3.82)	94 (1.06); 62-309 (0.70-3.50)	.005
Serum creatinine level >221 μmol/L (>2.5 mg/dL), No. of patients	15	2	7	3	.14
Blood pressure at referral, mm Hg					
Systolic	190±33	196±26	210±30	212±39	<.001
Diastolic	113±16	115±15	124±19	119±18	<.001
Effective renal plasma flow, mL/min	319±145	335±123	312±126	349±131	.28
Glomerular filtration rate, mL/min	85±25	90±21	79±24	84±43	.04
Patients with renal artery stenosis, %	54	55	54	42	.19

*Data are given as mean ± SD, unless indicated otherwise.

tigraphy using pentetic acid after captopril challenge. This analysis included groups 1, 3, and 4, as well as the patients in group 2 who were randomly allocated to group 1 or 3.

In patients with essential hypertension, the single-kidney fractional uptake of pentetic acid was slightly but significantly lower on the left side than on the right side during scintigraphy without captopril challenge. The fractional uptake of the kidney with the lowest contribution to the total renal uptake was not altered by captopril challenge (**Table 3**). In patients with renal artery stenosis, the single-kidney fractional uptake on the affected side was reduced compared with that in subjects with essential hypertension. The asymmetry between the 2 kidneys was therefore increased in patients with renal artery stenosis, but the asymmetry was not affected by captopril challenge (Table 3).

The ROC curves were generated for the kidney with the lowest uptake, and the ROC curve for scintigraphy using pentetic acid without captopril challenge was compared with the ROC curve for scintigraphy after captopril challenge (**Figure 2**). There was no difference between the areas under the 2 curves 0.84 ± 0.03 vs 0.84 ± 0.02 , respectively). Because a high specificity is required for the diagnosis of renal artery stenosis, the op-

timal cutoff point for a positive test was determined as the value that corresponded with a specificity of 0.90. For the whole group, a specificity of 0.90 was obtained at a cutoff value of 35% (single-kidney fractional uptake $\leq 35\%$ was considered suspect for renal artery stenosis) without captopril challenge and at a cutoff value of 37% with captopril challenge (**Table 4**). This was associated with a sensitivity of 0.65 and 0.68, respectively. Data were also analyzed separately for unilateral and bilateral stenosis because, in bilateral stenosis, a decrease in the fractional uptake on the less-affected side after captopril challenge might have obscured the asymmetry between the 2 kidneys. The sensitivity was indeed somewhat better for unilateral stenosis than for bilateral stenosis, but captopril had little effect on the diagnostic accuracy of scintigraphy with pentetic acid in either group.

Within-Patient Comparison

This analysis was performed in the group of patients who underwent scintigraphy using pentetic acid both without and after captopril challenge (group 2). The kidney with the lowest uptake during scintigraphy using pentetic acid without captopril challenge was compared with the same kidney after captopril challenge. The effect of captopril was analyzed by subtracting the single-kidney fractional uptake of pentetic acid after captopril challenge from the uptake without captopril challenge. The results are shown in **Figure 3**.

In 4 patients, the kidney with the lowest uptake contributed 10% or less to the total renal uptake during scintigraphy using pentetic acid without captopril challenge. As expected, captopril did not change the fractional uptake by these kidneys. These patients were therefore excluded from the analysis presented in Figure 3. The optimal cutoff point for a positive test, corresponding to a specificity of 0.90, was a value of 5% for the difference in the fractional uptake between scintigraphy using pentetic acid without captopril challenge and scintigraphy using pentetic acid after captopril challenge, and this was associated with a sensitivity of 0.64. Thus, dual scintigraphy with pentetic acid, in which 1 renal scan was obtained after captopril challenge and 1 without, did not offer any advantage over single scintigraphy using pentetic acid either with captopril challenge or without.

Table 2. Characteristics of Patients With Essential Hypertension and Renal Artery Stenosis*

Characteristic	Essential Hypertension (n=242)	Renal Artery Stenosis (n=263)	P
Males, %	57	64	.10
Age, y	49.4±12.8	55.1±13.9	<.001
Body mass index, kg/m ²	26.0±3.9	23.7±4.0	<.001
Median serum creatinine level, μmol/L (mg/dL); range	91 (1.03); 37-423 (0.42-4.79)	121 (1.37); 60-631 (0.68-7.14)	<.001
Blood pressure at referral, mm Hg			
Systolic	194±35	202±30	.02
Diastolic	117±19	116±16	.73
Effective renal plasma flow, mL/min	381±135	272±110	<.001
Glomerular filtration rate, mL/min	93±28	76±24	<.001

*Data are given as mean±SD, unless indicated otherwise.

Table 3. Between-Patient Comparison of Single-Kidney Fractional Uptake in Scintigraphy Using Pentetic Acid With and Without Captopril Challenge*

Type of Scintigraphy	Essential Hypertension, % Contribution			Renal Artery Stenosis, % Contribution		
	R Kidney	L Kidney	Kidney With Lowest Uptake	Affected Kidney	Contralateral Kidney	Kidney With Lowest Uptake
Without captopril challenge (n=225)	53.6±9.1†	46.4±9.1	43.1±6.9	25.1±17.0‡	74.9±17.0	24.6±16.4§
After captopril challenge (n=280)	50.9±8.1	49.1±8.1	44.0±5.5	27.8±16.2‡	72.2±16.2	27.6±16.0§

*Data are given as mean±SD. The contribution of the kidney with the lowest uptake without captopril challenge was not significantly different from the contribution after captopril challenge (P=.28 for essential hypertension; P=.14 for renal artery stenosis).

†P<.001 for difference relative to left kidney.

‡P<.001 for difference relative to contralateral kidney.

§P<.001 for difference relative to essential hypertension.

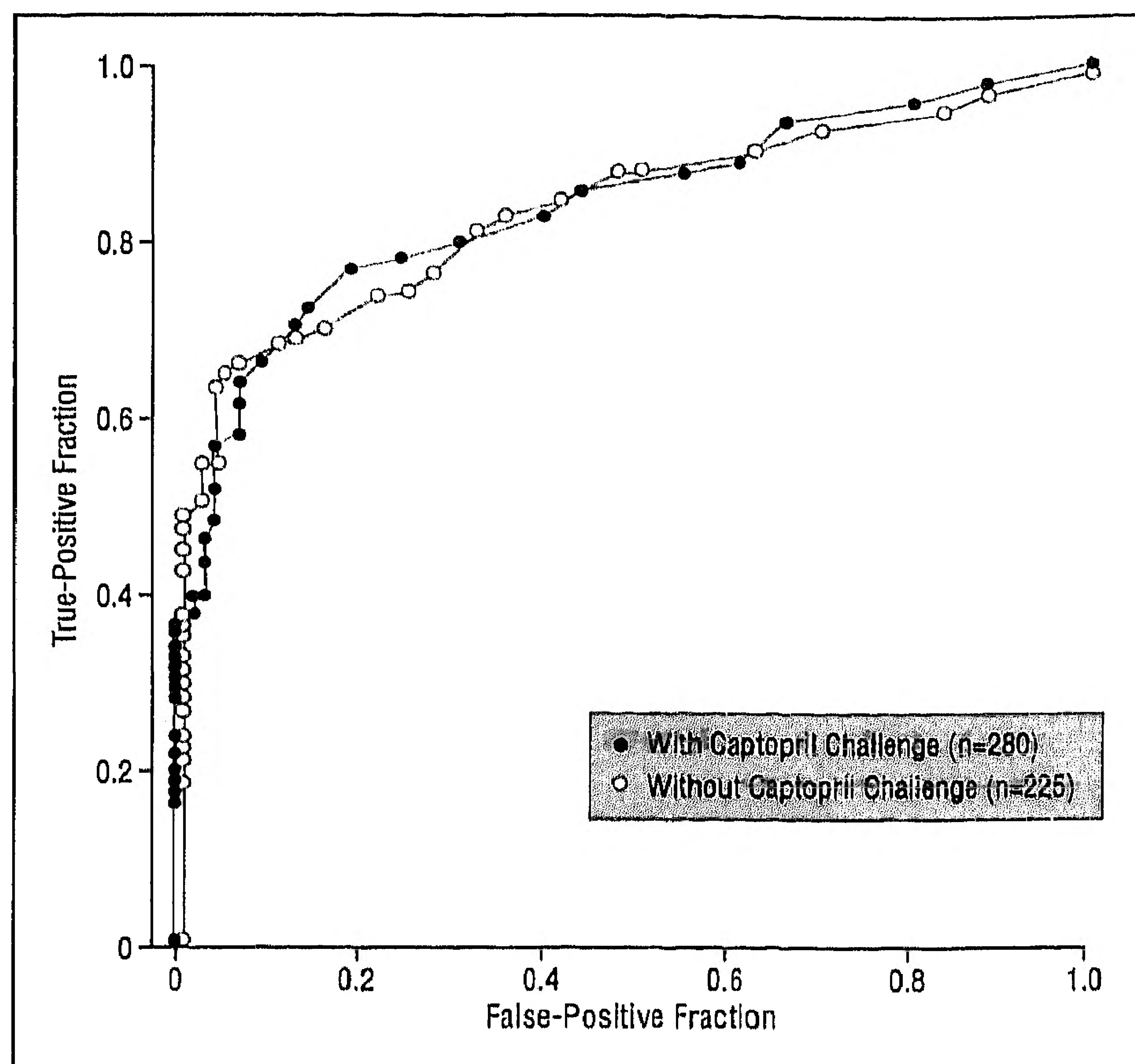


Figure 2. The receiver operating characteristic curves for the single-kidney fractional uptake in scintigraphy using pentetic acid with and without captopril challenge.

It has been well documented that the number of false-negative tests in scintigraphy with pentetic acid can be reduced by the use of captopril.^{3,8,21,22} In our series, this was the case in 12 of the 29 patients with unilateral stenosis and in 4 of the 17 patients with bilateral stenosis. However, in 3 patients with unilateral stenosis and in 3 patients with bilateral stenosis, the test remained negative after captopril challenge. Moreover, in some patients with essential hypertension, the test became positive after captopril challenge or was positive both with and without captopril challenge. Thus, although the use of captopril can improve the diagnostic accuracy of scintigraphy with pentetic acid in individual cases, this is not a uniform finding; in fact, captopril may increase the number of false-positive tests.

SCINTIGRAPHY WITH MERTIATIDE₃ VS PENTETIC ACID

Between-Patient Comparison

The scintigraphy with mertiatide was always performed after captopril challenge. Results of the scintigraphy with mertiatide were therefore compared with those of scintigraphy with pentetic acid after captopril challenge. The analysis included groups 2, 3, and 4.

A striking difference between the renal scans with mertiatide and pentetic acid was the diminished asymmetry between the 2 kidneys that was observed on the scans with mertiatide in patients with renal artery stenosis (**Table 5**). Again, the ROC curves were generated for the kidney with the lowest uptake. A specificity of 0.90 was obtained at a cutoff value of 35% for the single-kidney fractional uptake both with mertiatide and pentetic acid scintigraphy. This specificity was associated with a sensitivity of 0.42 for mertiatide and 0.69 for pentetic acid. Thus, when the single-kidney fractional uptake was

Table 4. Between-Patient Comparison of Scintigraphy Using Pentetic Acid With and Without Captopril Challenge*

Comparison	Captopril Challenge	Sensitivity	Specificity	Cutoff Value for SKFU, %
EHT vs RAS	No	0.65	0.90	35
	Yes	0.68	0.90	37
EHT vs URAS	No	0.70	0.90	35
	Yes	0.73	0.90	37
EHT vs BIRAS	No	0.63	0.90	35
	Yes	0.58	0.90	38

*EHT indicates essential hypertension (n=242); RAS, renal artery stenosis (n=263); URAS, unilateral renal artery stenosis (n=169); BIRAS, bilateral renal artery stenosis (n=94); and SKFU, single-kidney fractional uptake.

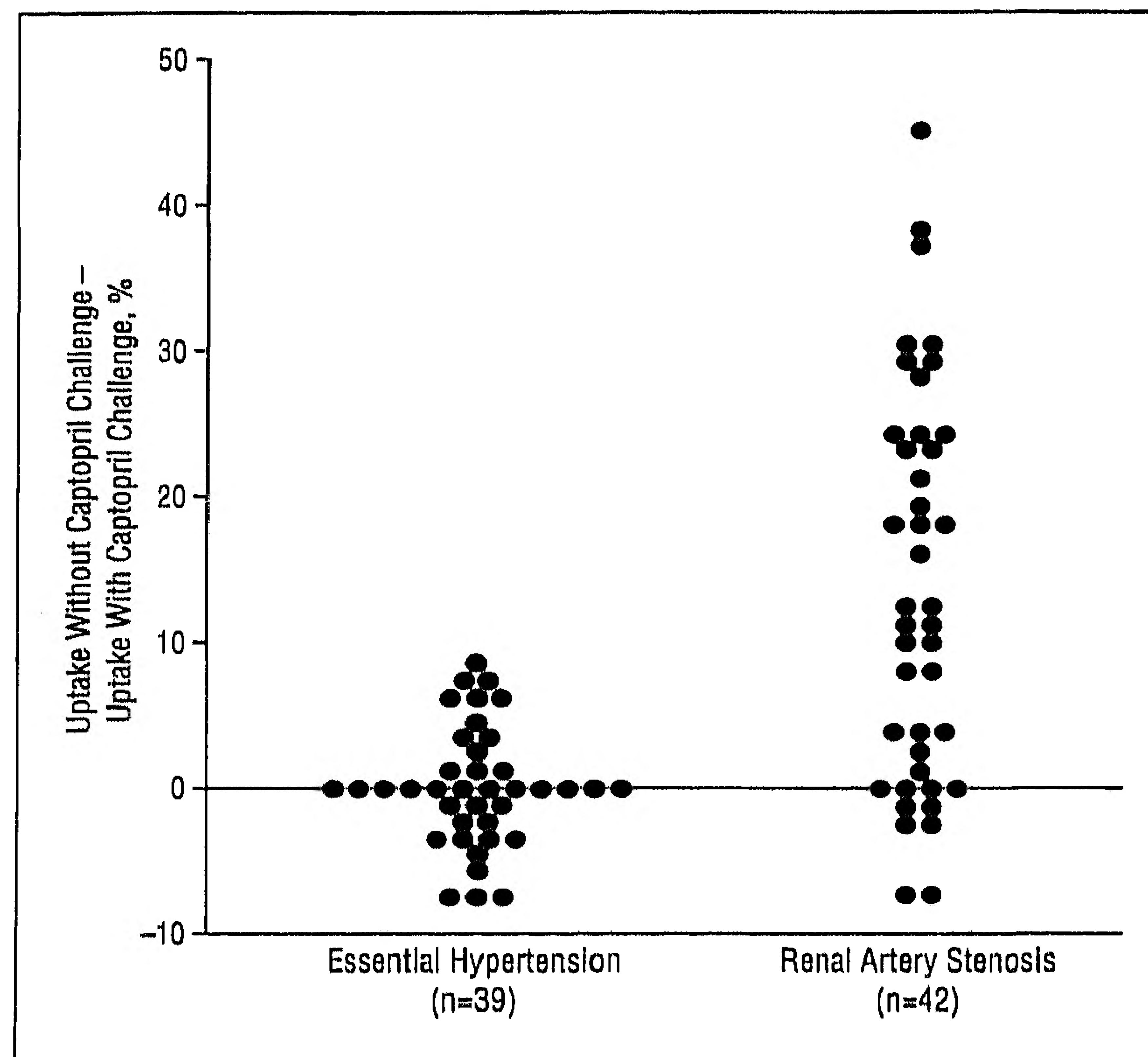


Figure 3. Effect of captopril on the single-kidney fractional uptake in scintigraphy using pentetic acid.

taken as the test criterion, scintigraphy with pentetic acid was superior to that with mertiatide.

Within-Patient Comparison

This analysis was limited to the patients who underwent scintigraphy with mertiatide as well as that with pentetic acid, both after captopril challenge (group 4). A specificity of 0.90 was obtained at a cutoff value of 36% for the single-kidney fractional uptake with scintigraphy using mertiatide and at a cutoff value of 38% with scintigraphy using pentetic acid. This was associated with a sensitivity of 0.42 for mertiatide and 0.61 for pentetic acid. These results are similar to those of the larger between-patient analysis.

In the interpretation of renal scans with mertiatide, parameters other than the single-kidney fractional uptake might be better discriminators for the presence or absence of renal artery stenosis. **Table 6** provides data on the diagnostic accuracy of the single-kidney fractional uptake, as well as other scintigraphic parameters (ie, $[T_{max}]$, time to pyelum, overall pattern of the reno-

Table 5. Between-Patient Comparison of Single-Kidney Fractional Uptake in Scintigraphy With Pentetic Acid and MAG_3 *

Type of Scintigraphy	Essential Hypertension, % Contribution			Renal Artery Stenosis, % Contribution		
	R Kidney	L Kidney	Kidney With Lowest Uptake	Affected Kidney	Contralateral Kidney	Kidney With Lowest Uptake
With pentetic acid after captopril challenge (n=230)	51.4±7.9	48.6±7.9	44.0±5.3	24.4±16.8†	75.6±16.8	24.2±16.5‡
With mertiatide after captopril challenge (n=93)	50.5±9.5	49.5±9.5	43.5±6.9	36.5±12.2†§	63.5±12.2	36.5±12.2‡§

*Data are given as mean±SD.

†P<.001 for difference relative to contralateral kidney.

‡P<.001 for difference relative to essential hypertension.

§P<.001 for difference relative to scintigraphy with pentetic acid.

Table 6. Diagnostic Accuracy of Various Scintigraphic Parameters in Patients Who Underwent Pentetic Acid and Mertiatide Scintigraphy, Both After Captopril Challenge (n=93)*

Parameter	Pentetic Acid Scintigraphy		Mertiatide Scintigraphy	
	Sensitivity	Specificity	Sensitivity	Specificity
Small kidney	0.55	0.76	0.50	0.71
SKFU cutoff value				
44%	0.79	0.54	0.63	0.65
42%	0.68	0.70	0.50	0.73
40%	0.63	0.85	0.47	0.76
38%	0.61	0.87	0.45	0.82
36%	0.53	0.93	0.42	0.89
TTP cutoff value				
≥5 min	0.79	0.58	0.74	0.75
≥6 min	0.68	0.86	0.53	0.89
≥7 min	0.68	0.96	0.50	0.98
≥2-min difference†	0.61	0.98	0.47	0.96
T_{max} cutoff value				
≥5 min	0.76	0.53	0.79	0.44
≥6 min	0.68	0.78	0.66	0.67
≥7 min	0.66	0.80	0.63	0.84
≥2-min difference†	0.61	0.87	0.55	0.86
TTP, ≥6 min or difference in T_{max} ≥2 min	0.71	0.76	0.63	0.80
Pattern of renographic curve, curve type ≥2‡	0.66	0.91	0.53	0.89
Conclusion of the nuclear radiologist	0.66	0.93	0.61	0.96

*SKFU indicates single-kidney fractional uptake; TTP, time to pyelum; and T_{max} , time to peak.

†Absolute difference between the kidneys in TTP or T_{max} .

‡Renographic curve type 2 represents delayed excretion with preserved washout; curves type 0 and 1, the normal excretion pattern or minor abnormalities, respectively; and curve types 3, 4, and 5, delayed excretion rate without washout phase, renal failure pattern with measurable kidney uptake, and renal failure without measurable kidney uptake, respectively (adapted from Fommei et al⁶).

graphic curve, and kidney size) in both mertiatide and pentetic acid scintigraphy. These data show that, indeed, with the use of mertiatide, the T_{max} and time to pyelum are better criteria than the single-kidney fractional uptake; however, with pentetic acid, there was little dif-

ference in the diagnostic accuracy of these parameters. Nevertheless, if the test result was based on the T_{max} and time to pyelum rather than the single-kidney fractional uptake, scintigraphy with mertiatide was still not superior to that with pentetic acid.

COMMENT

STUDY STRENGTHS AND LIMITATIONS

Renal scintigraphy is widely used in the diagnostic workup of renovascular hypertension. This report summarizes our experience with the technique from 1978 to 1992. During this period, 2 major modifications were introduced in many clinical centers, including ours (ie, the use of the ACE inhibitor captopril to enhance the difference between the affected and nonaffected kidney, and the use of the new radiopharmaceutical, ^{99m}Tc-mertiatide instead of ^{99m}Tc-pentetic acid.

The numbers of hypertensive patients with and without renal artery stenosis who were included in our analysis of the effect of captopril on the renal scan with pentetic acid far exceeded those reported in most previously published studies. The European multicenter study by Fommei et al⁶ is the only study that we know of that included a comparable number of patients. To our knowledge, the comparison of scintigraphy using mertiatide with scintigraphy using pentetic acid in our study represents the first systematic within-patient analysis in a substantial number of patients, in contrast to other studies that have been reported to date and that have dealt with only small numbers of patients.^{15,21,23} Clinical characteristics of the patients in our study are comparable with those in other studies.^{1,5,20}

Because our analysis is retrospective, confounding factors (particularly changes over time in the selection of patients and in the evaluation of renal scans) could not be as well controlled as in a prospective study. This difficulty was in part overcome by (1) studying a large series of consecutive patients in whom both arteriography and scintigraphy were systematically performed, (2) comparing the different scintigraphic procedures in the same patient within a short time interval, and (3) using objective criteria for evaluating the scintiscans.

This report addresses the use of renal scintigraphy as a screening procedure, prior to arteriography, to di-

agnose the presence of renal artery stenosis. Renal artery stenosis does not equal renovascular hypertension. Essential hypertension is common, and in some patients with renal artery stenosis, the stenosis may not be responsible for the hypertension.

So-called 2-kidney 1-clip Goldblatt hypertension in animals, which serves as the experimental model of human renovascular hypertension, is generally held to proceed in 2, sometimes 3, phases.²⁴ In the early first phase, the rise in blood pressure is largely, if not completely, caused by the rise in the levels of circulating renin and angiotensin II. In the second phase, the blood pressure remains high, although the levels of renin and angiotensin II return toward normal. This may be due, at least partly, to the fact that a slightly elevated angiotensin II level, when chronically present, reinforces its own pressor action. In this phase, the secretion of renin from the clipped kidney is still stimulated, and the function of this kidney is highly dependent on angiotensin II. This, in the human equivalent, is illustrated by the increased renal venous renin level on the affected side and the suppressed renin level contralaterally (increased renal vein-renin ratio), by the increased response of peripheral venous renin to the administration of captopril (positive captopril-renin test), and by the effects of this drug on the renal handling of pentetic acid and mertiatide (abnormal scan with captopril). In both the first and second phases of 2-kidney 1-clip Goldblatt hypertension, relief of the stenosis will lead to relief of the hypertension. This is no longer the case in the third and last phase, possibly because of structural changes in the contralateral kidney.

Renovascular hypertension in humans is often defined as being characterized not only by the presence of renal artery stenosis but also by the cure of the hypertension after repair of the stenosis. However, some patients may be in an advanced stage, analogous to the third phase of 2-kidney 1-clip Goldblatt hypertension, and are therefore not cured by the use of balloon angioplasty or reconstructive surgery. Persistence of the hypertension may also reflect technical failure or recurrence of the stenosis after angioplasty. The most important objection to the use of the blood pressure response to balloon angioplasty or reconstructive surgery as a basis for defining renovascular hypertension is that it is a diagnosis a posteriori and therefore not helpful clinically.

In this report, renal artery stenosis was defined as a reduction of 50% or more of the arterial lumen diameter on the arteriogram. Based on the experimental studies of 2-kidney 1-clip Goldblatt hypertension, it may be suggested that a more severe stenosis (ie, $\geq 60\%$ or $\geq 70\%$) of the renal artery might be a better definition. However, to our knowledge, this has never been formally tested in clinical studies. Moreover, accurate assessment of the degree of stenosis is difficult in the absence of 3-dimensional images, particularly when the lesions are irregular and eccentric.²⁵ Most important, the radiologist's interpretation of renal arteriograms shows considerable interobserver variability. When experienced radiologists are asked to distinguish among no stenosis, less than 50% stenosis, 50% to 75% stenosis, 76% to 99% stenosis, and occlusion, their interpretations of the arteriograms show poor agreement (κ values, 0.33-0.48).²⁶ With

the use of broader categories (eg, $<50\%$ vs $\geq 50\%$, or $<60\%$ vs $\geq 60\%$), the agreement between different radiologists is better, but it is still far from complete.^{27,28} In practice, therefore, it is difficult to distinguish between 50% and 60% stenosis with the techniques of arteriography that are routinely used in most hospitals. The 50% stenosis criterion that we used in this report is also widely used in the literature.^{16,25-27,29-32}

This report does not assess the usefulness of renal scintigraphy to predict the outcome of balloon angioplasty or reconstructive surgery. A retrospective study, such as ours is not suitable for such an assessment, because of the lack of systematic follow-up data on blood pressure after the intervention, the lack of a standardized protocol for antihypertensive drug treatment, and the difficulty to define "improvement" after intervention.³³

EFFECTS OF CAPTOPRIL ON SCINTIGRAPHY WITH PENTETIC ACID

The importance of the renin-angiotensin system for maintaining the GFR, when renal perfusion is compromised by artery stenosis, has been demonstrated in animal studies and is also illustrated by clinical observations. The GFR is maintained through angiotensin II-mediated efferent arteriolar constriction. Impairment of renal function after blockade of angiotensin II formation by ACE inhibitor has been documented in patients with artery stenosis of a solitary functioning kidney and in bilateral stenosis. In patients with unilateral stenosis, the percent renal extraction of arterially delivered ¹²⁵I-labeled thalamate, which is a measure of the filtration fraction, is reduced by captopril, and much more so on the affected than the unaffected side.¹⁸ Captopril also affects the scans with pentetic acid of a kidney with artery stenosis. The renographic curve of such a kidney is characterized by a less steep uptake phase, a later peak, and a flatter downslope in the excretion phase compared with that of the unaffected kidney. These abnormalities are often reinforced by captopril or become manifest after captopril challenge.¹⁻³

The single-kidney contribution to the total renal accumulation of pentetic acid during the uptake phase after injection is commonly used as a diagnostic criterion (single-kidney fractional uptake).^{1,5,6,22,34-40} Like other investigators, we observed a decrease in the single-kidney fractional uptake after captopril challenge on the affected side in patients with renal artery stenosis, so that a normal fractional uptake without captopril became abnormal after captopril challenge. However, this was not a uniform finding. In some patients, the single-kidney fractional uptake on the affected side was normal both with and without captopril. Moreover, in some patients with essential hypertension, the normal fractional uptake without captopril became abnormal after captopril challenge. On average, with the single-kidney fractional uptake as the diagnostic criterion, the accuracy of scintigraphy with pentetic acid was not improved by captopril challenge in our series.

Other criteria, T_{max} , time to pyelum, the overall pattern of the renographic curve, and kidney size, appeared to offer no advantages over the single-kidney fractional uptake. In the European multicenter study of the

effects of captopril on the renal scan with pentetic acid, the sensitivity (at a specificity of approximately 0.90) was 0.61 without captopril challenge and 0.70 after captopril challenge with the single-kidney fractional uptake as the criterion.⁶ For the T_{max} , the sensitivity in that study was only 0.39 without captopril and 0.77 after captopril challenge. The European study also showed that the change in the single-kidney fractional uptake caused by captopril challenge was not a more accurate parameter for predicting renal artery stenosis. The findings of our study are in agreement with these results.

MERTIATIDE VS PENTETIC ACID

A noteworthy finding in the present study is that the single-kidney fractional uptake on the affected side was higher with mertiatide than with pentetic acid in patients with renal artery stenosis, so that the difference in uptake between the affected kidney and contralateral kidney was smaller with mertiatide than with pentetic acid. This may be related to the use of captopril in our comparative analysis; mertiatide is cleared by the kidney mainly by tubular secretion, whereas pentetic acid is cleared by glomerular filtration. The renal clearance of mertiatide is a measure of renal blood flow, whereas the renal clearance of pentetic acid is a measure of glomerular filtration. In the kidney with artery stenosis, captopril has a proportionally larger effect on the GFR than on renal blood flow; in fact, flow may even increase after captopril challenge. These differential effects on filtration and flow are reflected in the decrease in the percent renal extraction of arterially delivered ^{125}I -thalamate, which equals the filtration fraction.¹⁸ Thus, captopril may cause a greater fall in the single-kidney fractional uptake with pentetic acid than with mertiatide. We are not aware of any study in which this issue has been systematically addressed. A practical consequence of the smaller difference in uptake between the affected kidney and the contralateral kidney with mertiatide than with pentetic acid is the lower accuracy of scintigraphy with mertiatide when the single-kidney fractional uptake is used as a diagnostic criterion.

Like other investigators, we found the T_{max} in scintigraphy with mertiatide to be a better criterion than the single-kidney fractional uptake. However, our results show that the use of this criterion in scintigraphy with mertiatide still did not lead to a higher diagnostic accuracy than could be obtained with scintigraphy with pentetic acid. Our comparison between mertiatide and pentetic acid was limited to patients who were studied after captopril challenge. In view of our observations on the effects of captopril on the renal scan with pentetic acid, it seems unlikely that the diagnostic accuracy with mertiatide would be superior to that with pentetic acid in patients who were not challenged with captopril.

Better images are produced with mertiatide than with pentetic acid in patients with impaired renal function. According to the Working Party Group on Determining the Radionuclide of Choice,⁴¹ the use of pentetic acid is not recommended in patients with a serum creatinine level greater than $442 \mu\text{mol/L}$ ($>5.0 \text{ mg/dL}$), and pentetic acid should be used with care if the serum creatinine level is greater than $221 \mu\text{mol/L}$ ($>2.5 \text{ mg/dL}$). The number of

such patients in our study was too small to address this point.

DIAGNOSTIC VALUE OF RENAL SCINTIGRAPHY

The prevalence of renal artery stenosis among the general population of hypertensive patients is low, ranging from 1% to 5%.³² Because renal arteriography is invasive and not without risk, renal scintigraphy has been advocated as a screening procedure to select patients for arteriography. To avoid an unacceptably high number of arteriograms with no abnormalities, the diagnostic specificity of renal scintigraphy must be high. In the present analysis, we chose test results that corresponded with a specificity of 0.90 as cutoff points for a positive test. At this level of specificity, the sensitivity of scintigraphy with pentetic acid ranged from only 0.61 to 0.68, depending on the renographic parameters (ie, single-kidney fractional uptake, T_{max} , time to pyelum, overall shape of renographic curve) that were used. The diagnostic accuracy of scintigraphy using mertiatide with captopril challenge was no better.

Given a test sensitivity of 0.68 and a specificity of 0.90 and assuming a 3% prevalence of renal artery stenosis among the total population of hypertensive patients, then to detect 20 cases in a population of 1000, only 117 subjects need to undergo arteriography if a renal scan with abnormalities is used as a selection criterion for arteriography, whereas 667 subjects will undergo arteriography if scintigraphy is omitted. However, if a renal scan with abnormalities is used as a selection criterion for arteriography, 10 cases of renal artery stenosis will be missed. Obviously, in a population with such a low prevalence, one has little choice but to perform scintigraphy, since it is not practical to perform arteriography in such large numbers of subjects.

Two strategies can be followed as an alternative to scintigraphy. One is the introduction of well-defined and sensible clinical criteria to identify high-risk patients. Practical criteria would need to be strict enough to reduce the number of arteriograms to an acceptable level, but not so rigid as to miss too many cases. The other is the development of less invasive techniques to visualize the renal arteries as a replacement for arteriography (eg, magnetic resonance angiography, spiral computed tomography, or duplex ultrasonography). The question of whether much harm is being done by withholding balloon dilation or surgical revascularization from a patient who will otherwise need lifelong intensive antihypertensive drug treatment also remains to be answered. Recent reports suggest that a renal scan that shows abnormalities may be associated with a higher chance of a favorable outcome of nonmedical intervention procedures, but it is not certain whether a renal scan that does not show abnormalities is a strong enough reason to refrain from such interventions.^{6,34,36,38} A prospective study addressing precisely these issues is now being carried out in the Netherlands.⁴² In this multicenter study, strictly controlled standard drug regimens are being used to define refractory hypertension, a standardized protocol for the diagnostic workup is being followed, and the effects of balloon dilation and drug therapy are being compared.

Currently, scintigraphy is still the most effective diagnostic procedure to reduce the number of arteriograms without abnormalities to a level that is acceptable in terms of burden to the patient and cost. Therefore, when dealing with a population of patients with a low prevalence of renal artery stenosis, it is good policy to perform scintigraphy before deciding to proceed with arteriography. On the other hand, when the prevalence of renal artery stenosis is high, it is reasonable to omit scintigraphy and proceed directly with arteriography. In practice, the omission of renal scintigraphy as a screening step will always result in a substantial number of arteriograms that do not show abnormalities, whereas the use of a renal scan that does show abnormalities as a selection criterion for arteriography will always result in a substantial number of missed diagnoses.

Accepted for publication December 17, 1996.

Reprints: Maarten A. D. H. Schalekamp, MD, PhD, Department of Internal Medicine I, H364, University Hospital Dijkzigt, Dr Molewaterplein 40, 3015 GD Rotterdam, the Netherlands.

REFERENCES

- Setaro JF, Saddler MC, Chen CC, et al. Simplified captopril renography in diagnosis and treatment of renal artery stenosis. *Hypertension*. 1991;18:289-298.
- Davidson R, Wilcox CS. Diagnostic usefulness of renal scanning after angiotensin converting enzyme inhibitors. *Hypertension*. 1991;18:299-303.
- Nally JV Jr, Black HR. State-of-the-art review: captopril renography: pathophysiological considerations and clinical observations. *Semin Nucl Med*. 1992;12:85-97.
- Mann SJ, Pickering TG. Detection of renovascular hypertension: state of the art: 1992. *Ann Intern Med*. 1992;117:845-853.
- Elliott WJ, Martin WB, Murphy MB. Comparison of two noninvasive screening tests for renovascular hypertension. *Arch Intern Med*. 1993;153:755-764.
- Fommei E, Ghione S, Hilson AJW, et al. Captopril radionuclide test in renovascular hypertension: a European multicentre study. *Eur J Nucl Med*. 1993;20:617-623.
- Middleton ML, Bongiovanni JA, Blaufox MD. Evaluation of renovascular hypertension. *Curr Opin Nephrol Hypertens*. 1993;2:940-948.
- Prigent A. The diagnosis of renovascular hypertension: the role of captopril renal scintigraphy and related issues. *Eur J Nucl Med*. 1993;20:625-644.
- Derkx FHM, Schalekamp MADH. Renal artery stenosis and hypertension. *Lancet*. 1994;344:237-239.
- Ram CVS, Clagett GP, Radford LR. Renovascular hypertension. *Semin Nephrol*. 1995;15:152-174.
- Black HR, Bourgoignie JJ, Pickering T, et al. Report of the Working Party Group for patient selection and preparation. *Am J Hypertens*. 1991;4:745S-746S.
- Blaufox MD. Captopril renography: considerations in the selection of radiopharmaceuticals, provocative agents, and hypertensive subjects. *Am J Hypertens*. 1991;4:675S-677S.
- Fine EJ, Blaufox MD, on behalf of the Einstein/Cornell Collaborative Hypertension Group. The Einstein/Cornell Collaborative Protocol to assess efficacy and methodology in captopril scintigraphy: early results in patients with essential hypertension. *Am J Hypertens*. 1991;4:716S-720S.
- Oei HY, Hoogeveen EK, Kooy PPM, et al. Sensitivity and specificity of captopril renography in detecting renal artery stenosis based on visual evaluation of sequential images performed with ^{99m}Tc-MAG₃. In: O'Reilly PH, Taylor A, Nally JV, eds. *Radionuclides in Nephro-urology*. Philadelphia, Pa: Field & Wood; 1992:43-50.
- Al-Nahhas AA, Jafri RA, Britton KE, et al. Clinical experience with ^{99m}Tc-MAG₃, mercaptoacetyltriglycine, and a comparison with ^{99m}Tc-DTPA. *Eur J Nucl Med*. 1988;14:453-462.
- Dondi M. Captopril renal scintigraphy with ^{99m}Tc-mercaptoacetyltriglycine (^{99m}Tc-MAG₃) for detecting renal artery stenosis. *Am J Hypertens*. 1991;4:737S-740S.
- Metz CE. Basic principles of ROC analysis. *Semin Nucl Med*. 1978;8:283-298.
- Wenting GJ, Tan-Tjong HL, Derkx FHM, de Bruyn JHB, Man in 'tVeld AJ, Schalekamp MADH. Split renal function after captopril in unilateral renal artery stenosis. *BMJ*. 1984;288:886-890.
- Hanley JA, McNeill BJ. A method of comparing the areas under receiver operating characteristic curves derived from the same cases. *Radiology*. 1983;148:839-843.
- Simon N, Franklin SS, Bleifer KM, et al. Clinical characteristics of renovascular hypertension. *JAMA*. 1972;220:1209-1218.
- Oei HY, Geyskes GG, Dorhout Mees EJ, Puylaert CBAJ. The significance of captopril renography in renovascular hypertension. *Contrib Nephrol*. 1987;56:95-103.
- Chen ChC, Hoffer PB, Vahjen G, et al. Patients at high risk for renal artery stenosis: a simple method of renal scintigraphic analysis with Tc-99m DTPA and captopril. *Radiology*. 1990;176:365-370.
- Taylor A, Martin LG. The utility of ^{99m}Tc-mercaptoacetyltriglycine in captopril renography. *Am J Hypertens*. 1991;4:731S-736S.
- Robertson JIS, Morton JJ, Tillman DM, Lever AF. The pathophysiology of renovascular hypertension. *J Hypertens*. 1986;4:S95-S103.
- Reidy J. Contrast arteriography. In: Novick AC, Scoble J, Hamilton G, eds. *Renal Vascular Disease*. Philadelphia, Pa: WB Saunders Co; 1996:77-90.
- Plouin PF, Darné B, Chatellier G, et al. Restenosis after a first percutaneous transluminal renal angioplasty. *Hypertension*. 1993;21:89-96.
- de Vries AR, Engels PHC, Overtoom TT, Saltzherr TP, Geyskes BG. Interobserver variability in assessing renal artery stenosis by digital subtraction angiography. *Diagn Imag Clin Med*. 1984;53:277-281.
- Hoffmann U, Edwards JM, Carter S, et al. Role of duplex scanning for the detection of atherosclerotic renal artery disease. *Kidney Int*. 1991;39:1232-1239.
- Bookstein JJ, Abrams HL, Buenger RE, et al. Radiologic aspects of renovascular hypertension, I: aims and methods of the Radiology Study Group. *JAMA*. 1972;220:1218-1224.
- Losinno F, Zuccalà A, Busato F, Zucchelli P. Renal artery angioplasty for renovascular hypertension and preservation of renal function: long-term angiographic and clinical follow-up. *Am J Radiol*. 1994;162:853-857.
- Ven van de PJG, Beutler JJ, Kaatee R, et al. Transluminal vascular stent for ostial atherosclerotic renal artery stenosis. *Lancet*. 1995;346:672-674.
- Albers FJ, Svetkey LP. Screening and diagnosis in renovascular hypertension. In: Novick AC, Scoble J, Hamilton G, eds. *Renal Vascular Disease*. Philadelphia, Pa: WB Saunders Co; 1996:205-223.
- Ramsay LE, Waller PC. Blood pressure response to percutaneous transluminal angioplasty for renovascular hypertension: an overview of published series. *BMJ*. 1990;300:569-572.
- Postma CT, van Oijen AHAM, Barentsz JO, et al. The value of tests predicting renovascular hypertension in patients with renal artery stenosis treated by angioplasty. *Arch Intern Med*. 1991;151:1531-1535.
- Svetkey LP, Wilkinson R, Dunnick NR, et al. Captopril renography in the diagnosis of renovascular disease. *Am J Hypertens*. 1991;4:711S-715S.
- Dondi M, Fanti S, De Fabritiis A, et al. Prognostic value of captopril renal scintigraphy in renovascular hypertension. *J Nucl Med*. 1992;33:2040-2044.
- McLean AG, Hilson AJW, Scoble JE, et al. Screening for renovascular disease with captopril-enhanced renography. *Nephrol Dial Transplant*. 1992;7:211-215.
- Pedersen EB, Jensen FT, Madsen B, Eiskjaer H, Nielsen JT, Rehling M. Angiotensin converting enzyme inhibitor renography in the diagnosis of renovascular hypertension: studies before and after angioplasty. *Nephrol Dial Transplant*. 1992;7:1178-1184.
- Derkx FHM, van Jaarsveld BC, Oei HY, et al. Does captopril improve the diagnostic value of ^{99m}Tc-diethylenetriaminepentaacetic acid renography for renal artery stenosis? *J Hypertens*. 1993;11:S200-S201.
- Itoh K, Tsukamoto E, Nagao K, Nakada K, Kanegae K, Furudate M. Captopril renoscintigraphy with Tc-99m DTPA in patients with suspected renovascular hypertension prospective and retrospective evaluation. *Clin Nucl Med*. 1993;18:463-471.
- Blaufox MD, Dubovsky EV, Hilson AJW, Taylor A, de Zeeuw R. Report of the Working Party Group on Determining the Radionuclide of Choice. *Am J Hypertens*. 1991;4:747S-748S.
- van Jaarsveld BC, Derkx FHM, Krijnen P, et al. 'Hypertension resistant to two drug treatment' is a useful criterion to select patients for angiography: the 'Dutch Renal Artery Stenosis Intervention Cooperative' (DRASTIC) Study. *Contrib Nephrol*. 1996;119:54-58.