

## PDF hosted at the Radboud Repository of the Radboud University Nijmegen

The following full text is a publisher's version.

For additional information about this publication click this link.

<http://hdl.handle.net/2066/24943>

Please be advised that this information was generated on 2017-12-05 and may be subject to change.

# Superior Orbital Fissure Syndrome Caused by Intraorbital Spread of a Cutaneous Squamous Cell Carcinoma and Not Detected on Computed Tomography and Magnetic Resonance Imaging

Robert J. W. de Keizer,\* George W. Padberg†  
and Didi de Wolff-Rouendaal\*

*Departments of \*Ophthalmology and †Neurology, University Hospital, Leiden, The Netherlands*

---

**Abstract:** Intraneural and perineural spread of a squamous cell carcinoma of the frontal region via the orbit to the cranial cavity is a rare cause of a superior orbital fissure syndrome. This mode of tumor spread, for which a previously excised invasive malignant tumor is responsible, is rarely reported. The absence of an intraorbital mass and the fact that computed tomography (CT) and magnetic resonance imaging (MRI) are normal make the diagnosis extremely difficult. We describe a 76-year-old patient in whom both intraneural and perineural tumor growth deep into the orbit caused acute ocular motility disturbances, visual impairment, and ocular dysfunction with subsequent cerebral and vascular dysfunction. Surgery, radiotherapy, and orbital exenteration did not prevent spread of the tumor toward vital intracranial and intracerebral structures. Even the advanced diagnostic modalities of CT and MRI failed to reveal the cause of the pathologic process in our patient. In such a case, one should look carefully for both intraneural and perineural tumor invasion on previous histologic material and, if positive, treat the patient with radical surgery on purely clinical grounds as early as possible. *Jpn J Ophthalmol* 1997;41:104-110 © 1997 Japanese Ophthalmological Society

**Key Words:** Computed tomography, cutaneous squamous cell carcinoma, intraorbital tumor spread, magnetic resonance imaging, superior orbital fissure syndrome.

---

## Introduction

Centripetal growth of malignant skin tumors is sometimes found to be a cause of orbital tumors.<sup>1</sup> Neural spread without a tumor mass<sup>2</sup> in relation to a superior orbital fissure syndrome<sup>1</sup> has only rarely been reported. In 1909, Kummel<sup>3</sup> described a case of a carcinoma of the lower eyelid that had metastasized into the orbit along the infraorbital nerve. In 1976, Moore<sup>4</sup> described two cases with centripetal involvement of the branch of the supraorbital nerve, and in 1982, Trobe<sup>5</sup> reported on occurrence with perineural spread to the cavernous sinus with signs interpreted as tic douloureux. All cases were squa-

mous cell carcinomas of the skin. The cases of Kummel<sup>3</sup> and Moore<sup>4</sup> were seen before computed tomography (CT) and magnetic resonance imaging (MRI) techniques were available; Trobe's<sup>5</sup> case occurred during the first year CT was available. There were no clinical features, and no increased volume of the orbit was reported.

In 1992, Howard et al<sup>1</sup> published a report of 13 patients with orbital extension of a basal cell carcinoma or squamous cell carcinoma; all patients showed moderate or extensive solid-tumor masses in the orbit. Their findings are in agreement with those of oncological and orbital centers familiar with tumor extension into the orbit of local, completely excised, skin carcinomas. These tumors can generally be detected on palpation, by CT, ultrasound scanning, or by MRI.

Our case, however, represents a subacute superior orbital fissure syndrome in which no orbital mass

---

Received: February 26, 1996

Address correspondence and reprint requests to: Robert J. W. de KEIZER, MD, Department of Ophthalmology, University Hospital, P.O. Box 9600, 2300 RC Leiden, The Netherlands

could be detected. In retrospect, it appears that intraneural and perineural tumor invasion, found on previous histologic excision material, might have been responsible for the centripetal spread of the tumor.

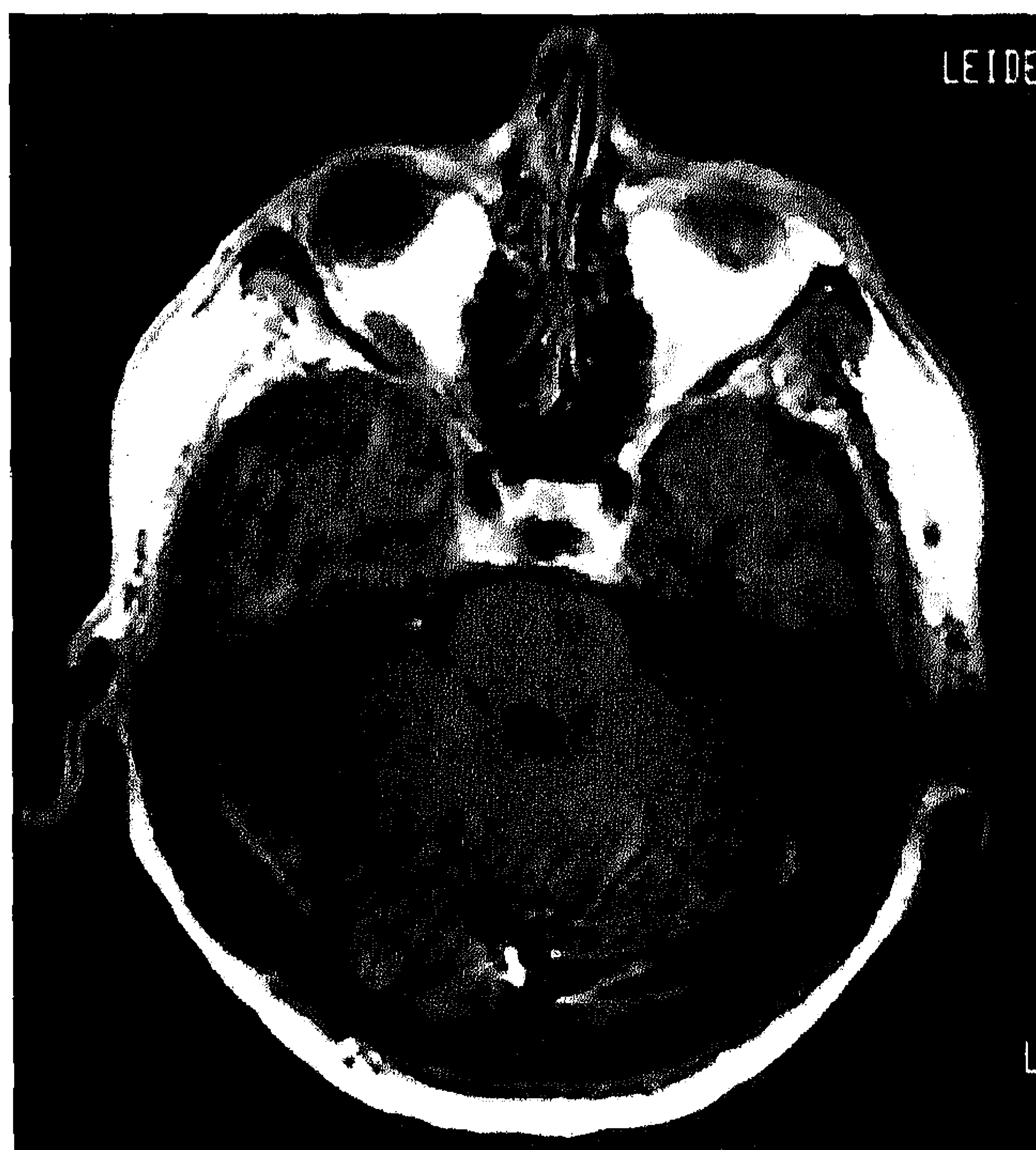
### Case Report

A 76-year-old man with visual loss in the right eye was admitted to our ophthalmic outpatient department in early 1991. He received a course of orbital irradiation for a small recurrence of cutaneous squamous cell carcinoma of the right eyebrow with intraorbital spread to the right trochlear region. In 1986, extracapsular lens extraction with an iridocapsular Binkhorst lens had been performed. Visual acuity was 0.8 + 3.75 cyl - 0.75 × 175° in the right eye and 0.5 + 2.25 cyl - 0.25 × 5° in the left eye, caused by amblyopia. There was moderate esotropia in the left eye.

Since 1961, he had been treated elsewhere for actinic keratosis of multiple sites with excision, local irradiation, and 5-fluorouracil 5% ointment. In 1989, two small skin lesions, diagnosed as squamous cell carcinoma, and a small tumor of the right eyebrow were excised. In May and October 1990, several small, new skin tumors were removed from his left and right forehead. The diagnosis was carcinoma in situ and actinic keratosis. In November 1990, there was a recurrence of the squamous cell carcinoma of the right eyebrow, which apparently had not been completely excised. Local obliteration of blood vessels with both perineural and endoneural tumor growth were reported. In December 1990, excision of the right frontal and eyebrow regions was repeated. A more extensive squamous cell carcinoma of the right eyebrow with intraorbital extension to the trochlear region of the right orbit was found. Histology revealed a morphea-like growth pattern of the squamous cell carcinoma. The patient received 60 Gy to the frontal field in 24 sessions, beginning at 16 MeV, followed by 20 sessions at 12 MeV. A few days after completion of the treatment, he complained of visual impairment and was referred to our orbital center.

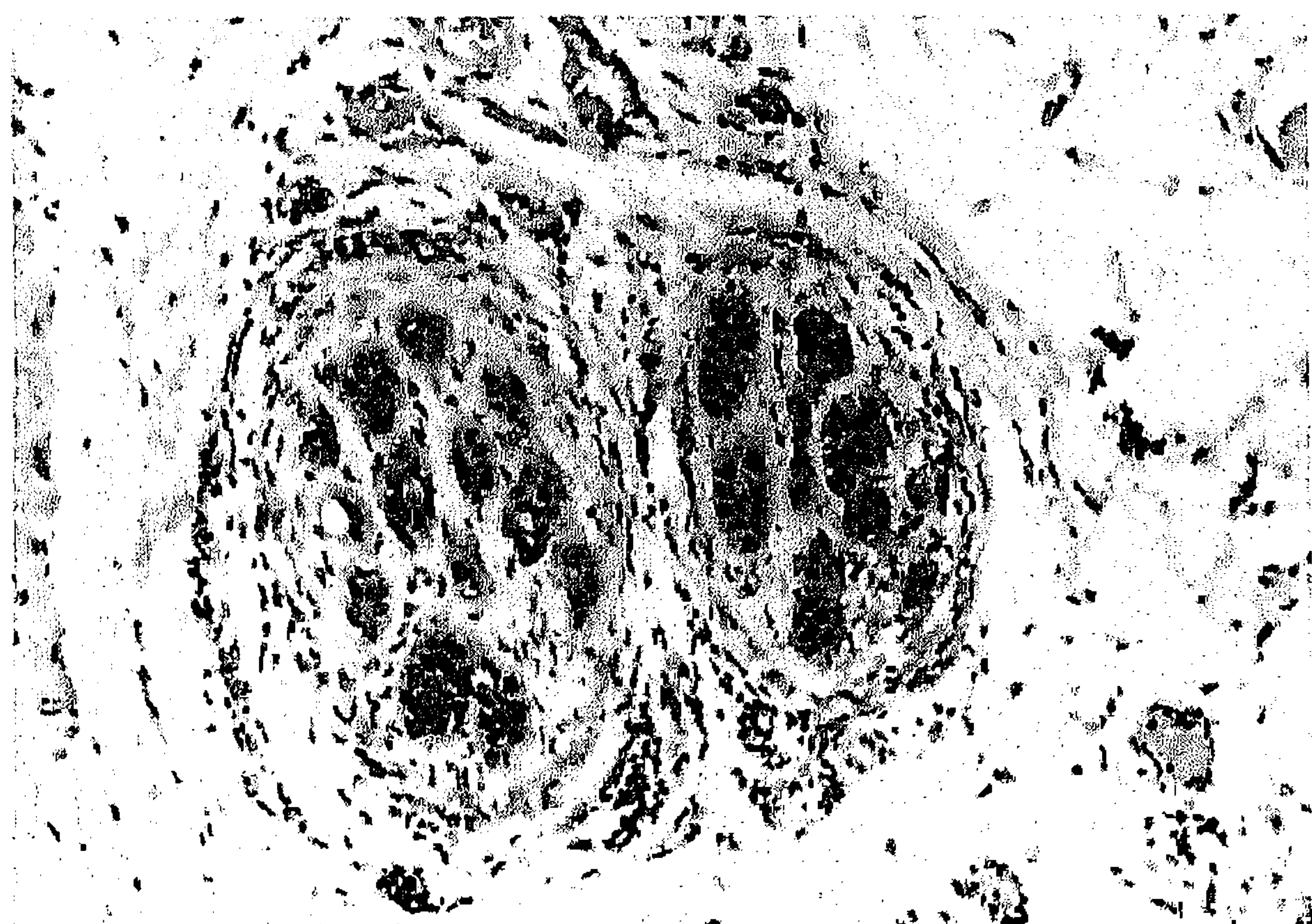
Our examination showed the known esotropia of the left eye and a mild limitation of abduction in the right eye, interpreted as having been "caused by surgery of the trochlear region with preoperative impairment of the oblique superior muscle and effects of cicatrization"; visual acuity, however, was normal (0.8). Two weeks later, he was seen again at a scheduled appointment and reported a "sudden" visual loss. Visual acuity had decreased to finger counting at 5 meters. Ophthalmic examination revealed cor-

neal edema and keratitis, probably caused by irradiation, which improved with artificial tears. Visual acuity improved to 0.2 (with pinhole test, to 0.5); a slight pallor of the optic-nerve head was observed. The Farnsworth-Munsell D-15 test showed a slight red-color impairment in the right eye. Goldman perimetry revealed a contraction in the V<sub>4</sub> isopter of the visual field. Pupillary reactions could not be examined properly because of the iridocapsular lens implant. An orbital apex syndrome was considered. In the following 3 weeks, visual acuity improved to 0.5 and the central visual fields improved as well. In the same period, however, the patient developed paresis of the third, fourth, and sixth cranial nerves with impairment of the first and second division of the fifth cranial nerve; an acute superior orbital fissure or anterior cavernous sinus syndrome was diagnosed. There was no proptosis (Hertel's exophthalmometry 18-18 mm), no mass on palpation, and no bilateral difference in orbital resistance. Ultrasound scanning, CT, MRI (T1 and T2-weighted images), ear-nose-throat examination, and lumbar puncture were normal. To exclude Tolosa-Hunt syndrome or other idiopathic inflammations, oral corticosteroids were given (60 mg daily, gradually tapered off over 3 weeks) without improvement. The patient was also

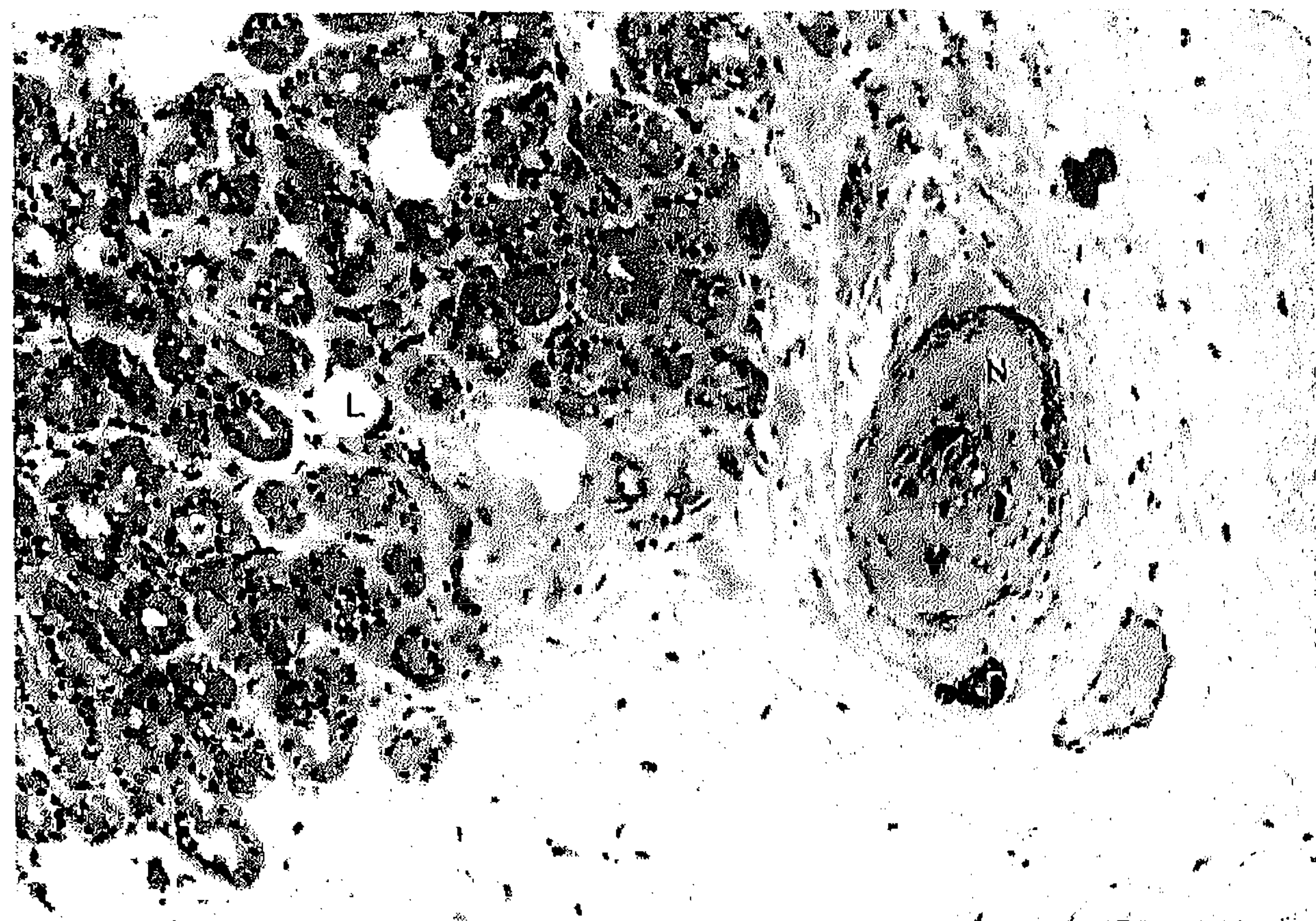


**Figure 1.** Axial magnetic resonance image with gadolinium of an intraconal tumor in right orbit, located at internal side of external rectus muscle.

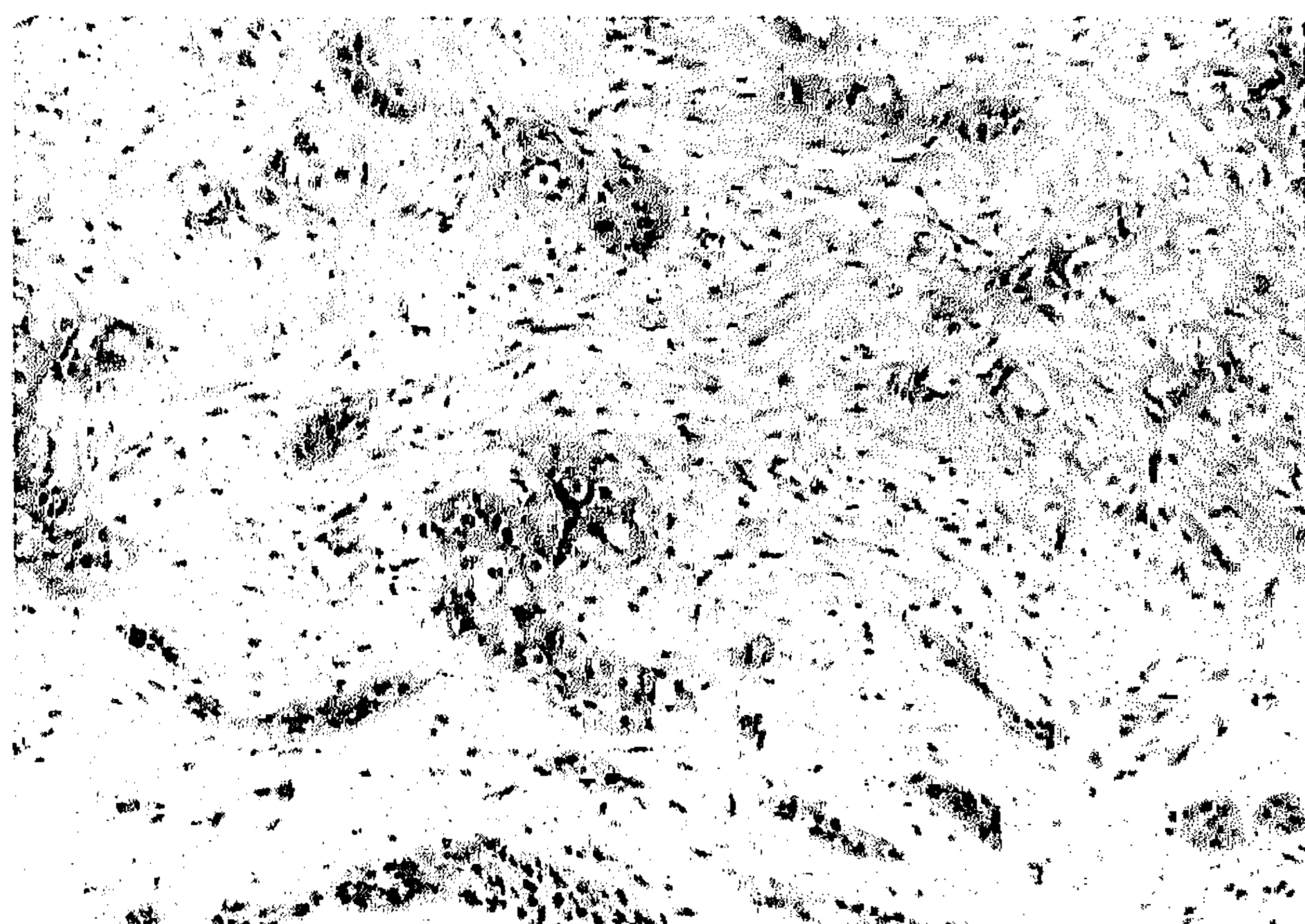




A



B



C

**Figure 2.** (A) Squamous cell carcinoma of skin (1990) invading subcutaneous nerves (original magnification  $\times 51$ ). (B) Orbital biopsy from the lacrimal gland region (L); a small nerve (N) contains tumor cells (original magnification  $\times 205$ ). (C) Orbital biopsy from retrobulbar region; morphea-like spread of tumor cells in fibrous connective tissue (original magnification  $\times 205$ ).

known to have hypertension of 220/110 (150/90 after treatment with beta-blocking agents). Because no tumor extension or any other causes of a superior orbital fissure syndrome, such as an aneurysm or nasopharyngeal carcinoma, could be found, the working diagnosis was vasculopathy induced by radiotherapy.

In June 1991, the central visual fields of the right eye exhibited relative defects in the upper part, which improved within the following weeks. During the same period, the patient reported a slight numbness and weakness of the right portion of the upper lip; a facial nerve problem was suggested, but again CT and MRI with intravenous gadolinium did not reveal any tumor or tumor extension. Neurologic and ophthalmic examinations during the next 6 months were unchanged. Angiography was not done because of the patient's age and hypertension. In November 1991, the visual acuity in the right eye deteriorated rapidly to complete loss of light perception; on funduscopy a slight papilledema was seen. MRI imaging showed a tumor in the right orbit located at the internal side of the external rectus mus-

cle, optic nerve atrophy, and a dilated superior ophthalmic vein (Figure 1). Thin-needle biopsy and cytology revealed a myxoid carcinoma, possibly a carcinoma of the lacrimal gland or a metastasis from a gastric carcinoma. Examinations for cardiac or prostate gland carcinoma were negative.

Lateral orbitotomy on January 6, 1992, showed a malignant cystic tumor filled with a dark liquid. Biopsies revealed an extensive morphea-like squamous cell carcinoma with several large necrotic areas. Although the lacrimal gland appeared normal, malignant cells were found in it and the adjacent nerves, indicating perineural extension of this tumor (Figures 2a,2b,2c). The histologic pattern was compared with that of all previous histologic slides of the skin tumors and confirmed that the orbital tumor was a perineural extension of the previously removed skin carcinomas, which were later interpreted as morphea-like tumor spread. The possibility of intraneural or perineural intracranial extension was predicted. In order to plan postoperative radiotherapy, CT and MRI were repeated. Tumor extension into



the inferior orbital fissure, cavernous sinus, and base of the skull was identifiable (Figures 3a,3b,3c). Orbital exenteration was performed to obtain better palliative results from radiotherapy of the orbit and skull base. Unfortunately, the tumor had already invaded the temporal muscle.

Two weeks after orbital exenteration, the patient's condition deteriorated very rapidly. The clinical neurologic diagnosis was mesencephalon infarction caused by age, surgery, and hypertension; tumor extension into the cerebral nerves and vessels could not be ruled out. The patient became obtunded, then comatose, and died. At autopsy, gross examination revealed that the orbital, cavernous sinus, and sellar regions were full of tumor tissue, but the cerebrum itself and its surrounding nerves appeared completely normal. Microscopic sections showed extension of the tumor from the orbital fissures and the optic canal to the base of the skull with perineural, intraneural, and perivascular tumor growth. This severe and extensive tumor infiltration of intracerebral blood vessels had caused vascular occlusion and secondary infarctions in both white and gray cerebral tissues (Figures 4a,4b).

## Discussion

In most cases, a superior orbital fissure syndrome or anterior cavernous sinus syndrome is caused by metastasis, a giant aneurysm, and/or idiopathic inflammation.<sup>6</sup> Signs and symptoms of acute total ophthalmoplegia are motility disturbances arising within a very short period of time, from paralysis of the third, fourth, and sixth cranial nerves together with involvement of the sensory ophthalmic nerve. Occasionally, a mild proptosis, decreased visual acuity, and autonomic pupillary impairment are present. CT and MRI can detect the tumor or giant aneurysm, and are especially useful for identifying extension of nasopharyngeal tumors into the orbit. When these non-invasive methods give negative results, phlebography and angiography should be used to exclude Tolosa-Hunt syndrome. Prominent signs of tumor extension into the pterygoid palatine fossa or into the cavernous sinus are facial pain and impairment of the inferior orbital nerve. The metastatic process usually progresses slowly from infiltration and expansion of one nerve into the cavernous sinus and finally to involvement of adjacent nerves.<sup>7</sup>

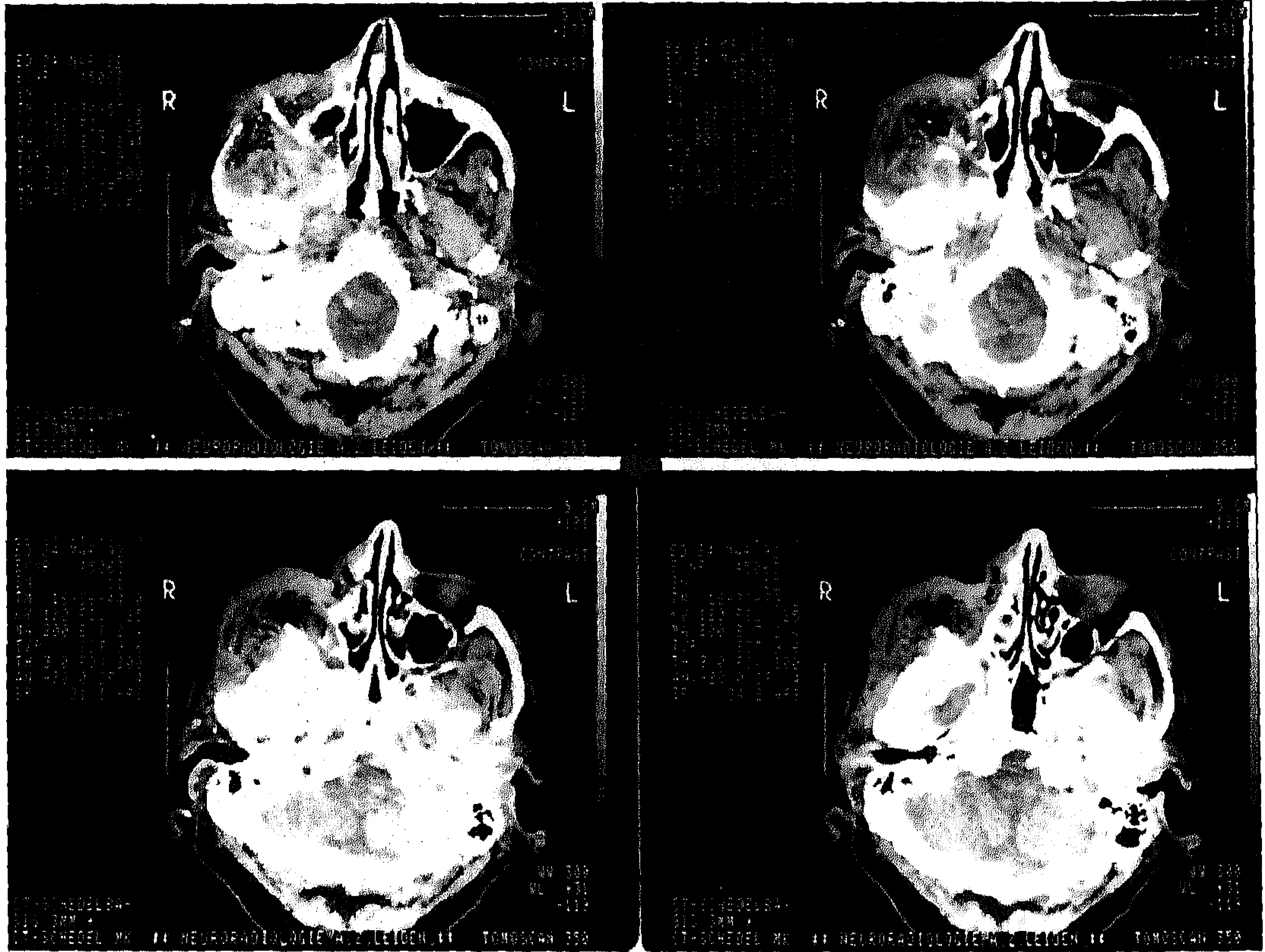
Carcinomas of the periorbital region may also be the source of these slowly progressive syndromes. The periorcular region, particularly, is a common site

for basal cell and squamous cell carcinomas. These skin carcinomas must be treated with extensive radical surgery and/or radiotherapy to prevent extension into the orbit.<sup>1,8</sup> If tumor extension into the orbit develops, orbital exenteration is the only method of cure. At some orbital centers, superficial extension is treated with radiotherapy.<sup>4,9</sup> To identify the extension and estimate the tumor volume, CT and MRI must be used.

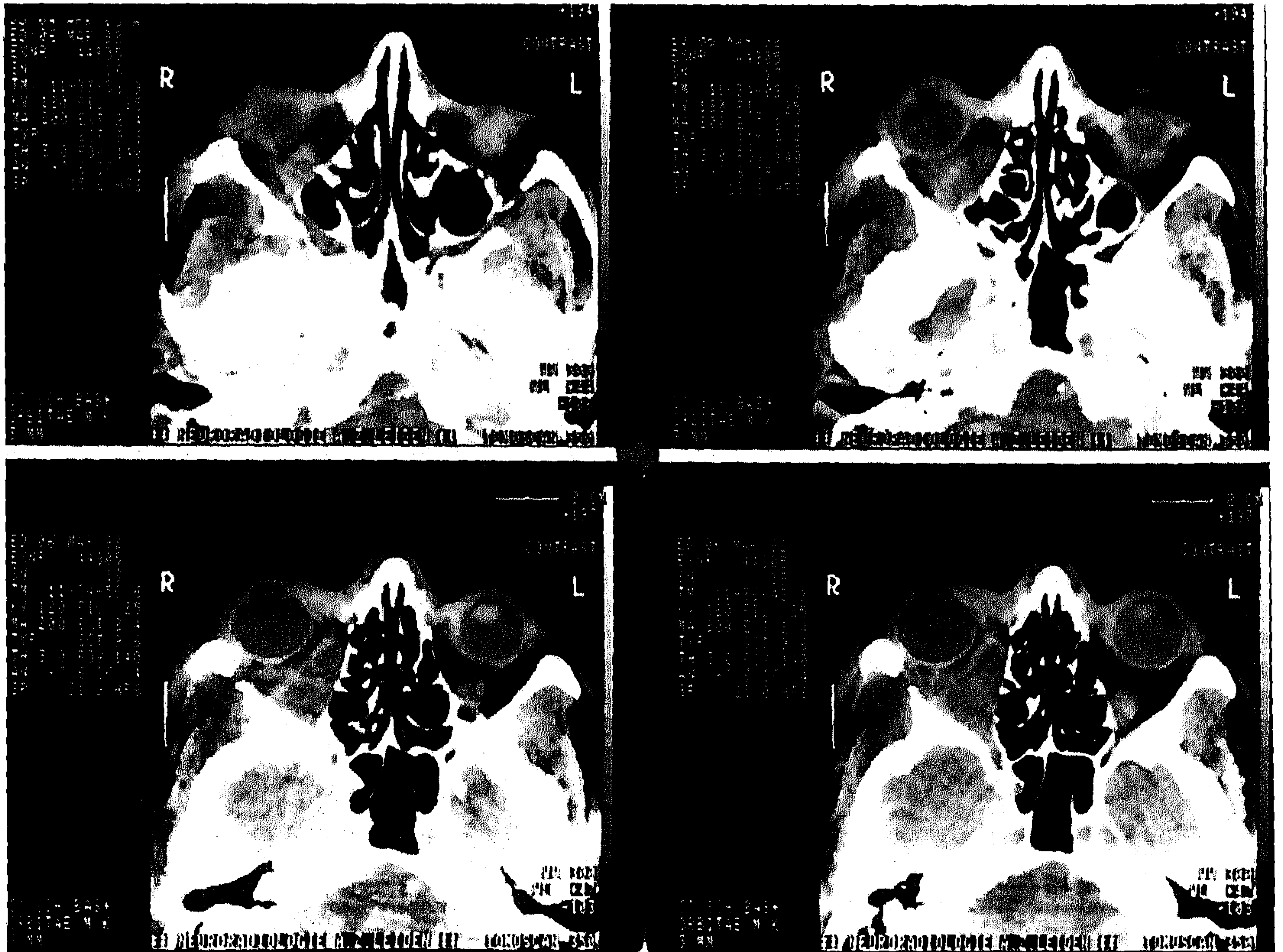
Our patient, with superficial extension of a squamous cell carcinoma into the trochlear region of the right orbit, rapidly developed all the signs of an acute orbital fissure syndrome while receiving radiotherapy. In this acute phase of visual impairment and motility disturbances, and during the following 6 months, no increase in orbital volume and no proptosis was found. Repeated CT scans and MRI were normal until the very late stages of the disease. The examinations disclosed no evidence of expanding lesions, such as aneurysm, lymphoma, or nasopharyngeal tumor. Orbital phlebography was impossible because of previous surgery of the forehead; the Tolosa-Hunt syndrome or an idiopathic orbital inflammation were excluded by use of oral corticosteroids.

Remote tumor invasion with simultaneous involvement of all nerves seemed unlikely, especially during the irradiation course. A vascular complication of the irradiation seemed to be the only reasonable cause of the symptoms demonstrated. Extension of a squamous cell carcinoma of the forehead and trochlear region may be considered to be a cause of ophthalmoplegia when a tumor mass is found. In our patient, however, the tumor mass did not develop until 6 months later and the diagnosis of carcinoma was confirmed by thin-needle puncture and cytology. These biopsy specimens first established the correct diagnosis of an extended squamous cell carcinoma with a large, local, diffuse morphea-like spread, and also demonstrated intraneural malignant cells in the lacrimal gland. As Moore<sup>4</sup> mentioned in 1976, regional nerves are a significant but often neglected or overlooked pathway for centripetal spread of a malignant tumor into the intracranial cavity. In 1862, Neumann<sup>10</sup> first described metastasis of a squamous cell carcinoma of the lower lip along mental and inferior alveolar nerves. The cases reported are rare and occurred before CT and MRI were available. Only Trobe<sup>5</sup> described one case in 1982 with signs and symptoms caused by perineural spread, but with normal findings on CT, angiography, and lumbar puncture. Csaky and Custer<sup>8</sup> published reports of two cases of orbital invasion and perineural spread of a squamous cell carcinoma of



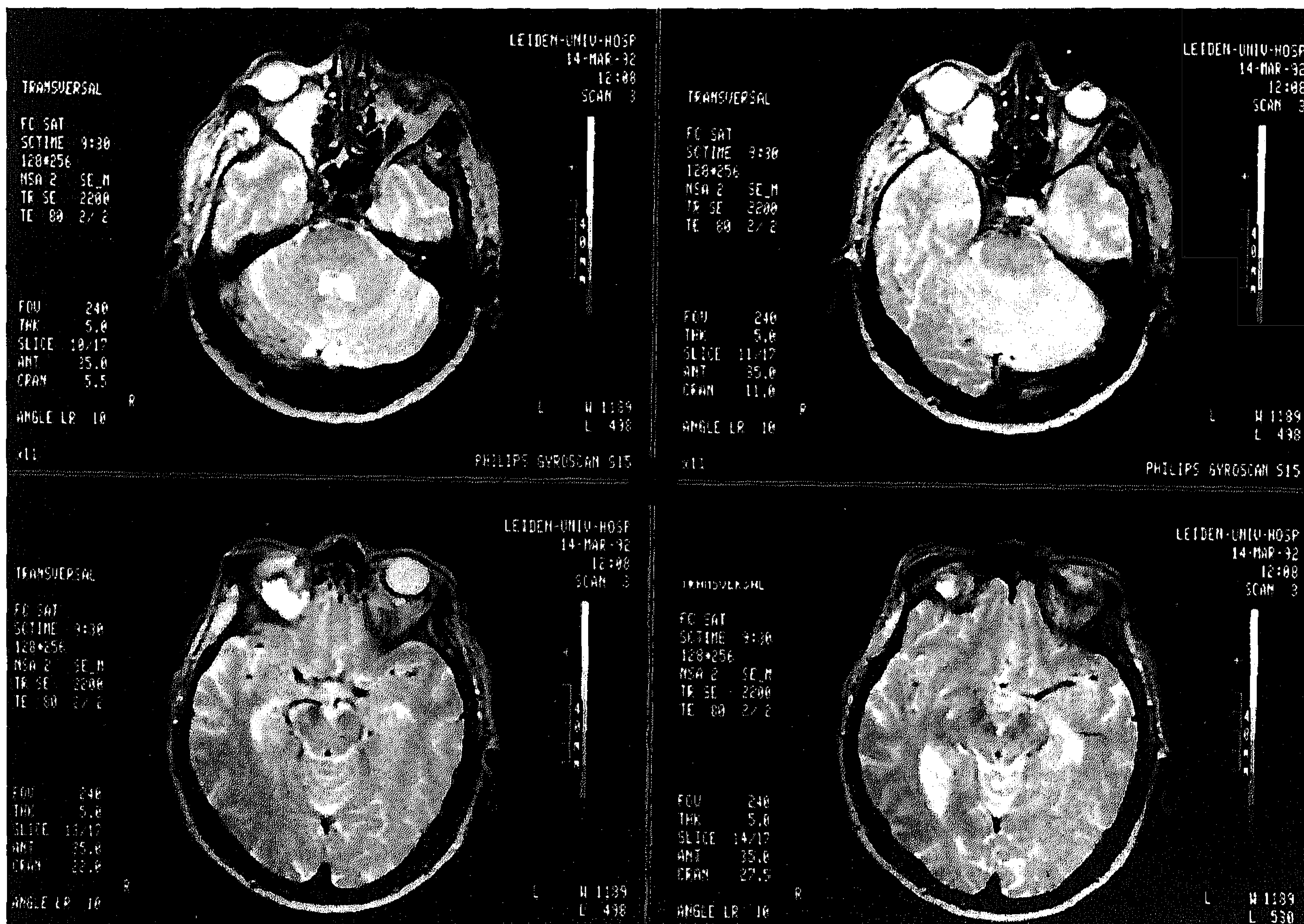


A



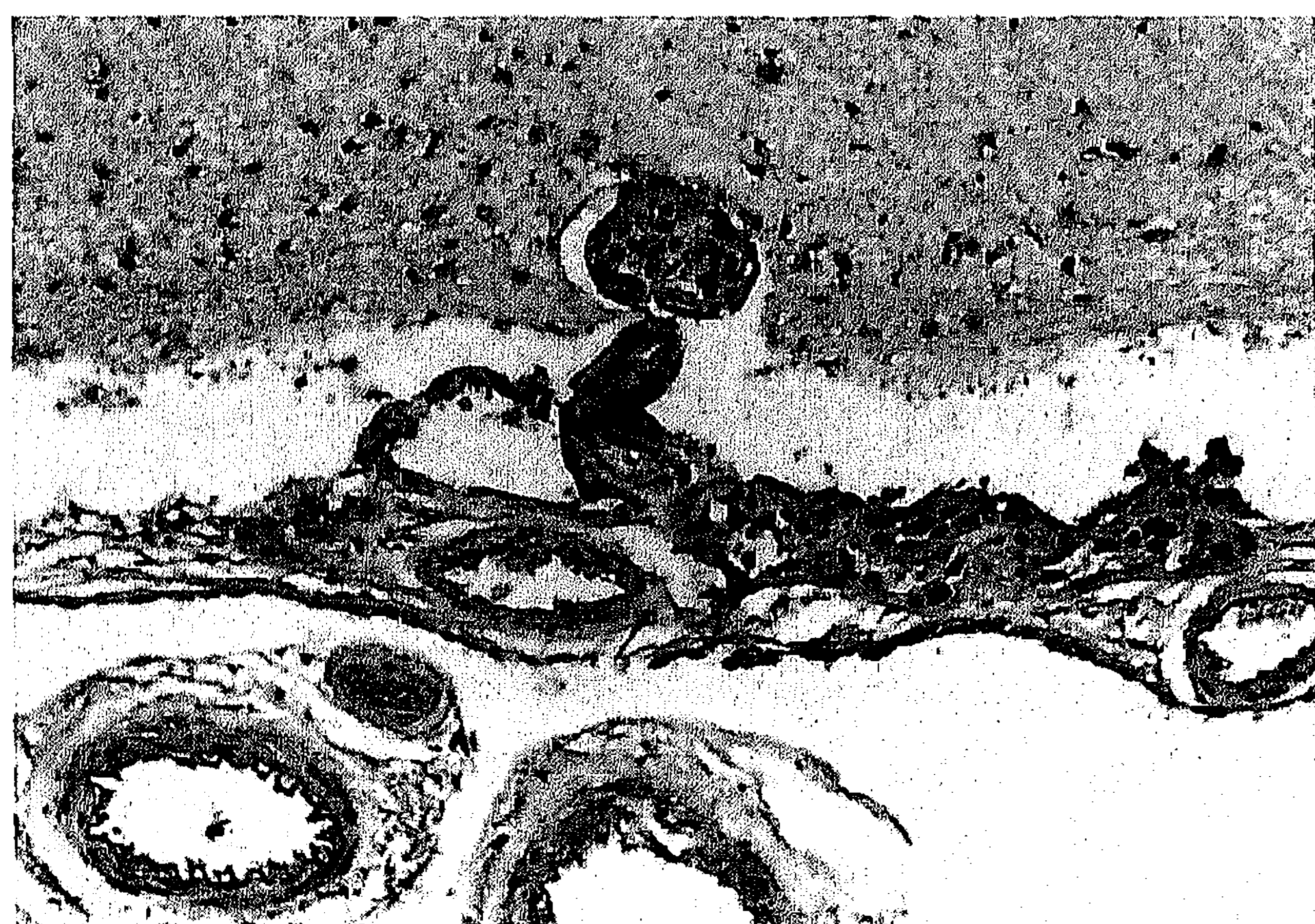B





C

**Figure 3.** (A) Axial computed tomogram with contrast. Extensive tumor growth in terygium palatum fossa and skull base. (B) Axial computed tomogram of right orbit and temporal fossa with lateral bone defect caused by Krönlein orbital surgery. (C) Magnetic resonance image, T2-weighted. Bright enhancement of the tumor in right orbit.



A



B

**Figure 4.** (A) Strands of tumor cells in pia mater of hippocampus region with perivascular invasion to cerebral cortex (original magnification  $\times 205$ ). (B) Necrosis of white subcortical cerebral tissue in area where multiple small blood vessels are occluded by perivascular tumor tissue (original magnification  $\times 82$ ).



the forehead, but with clinical signs and positive scan findings of increased tumor volume. In their case reports, however, neural metastasis was found before increased tumor volume.

Our case has clearly demonstrated that modern imaging techniques can fail to detect intraneural and perineural tumor extension, which can then result in an acute orbital fissure syndrome due to spread of the primary tumor over a long distance. The tumor mass in the orbit grew, produced clinical signs and symptoms, and became visible with CT and MRI. This phenomenon also occurred in the intracerebral area in which the infarction, but not the tumor spread, was seen on MRI. Even on autopsy, the cerebrum appeared normal on gross examination; only microscopic examination of the brain and meninges established the correct diagnosis.

When the original histologic material of the squamous cell carcinoma of the skin was reviewed, perineural malignant cells were discovered; they had not been found at the time the patient was receiving treatment. Even if this had been known, tumor extension into the superior orbital fissure might not have been recognized. At that time, only a local tumor mass, 3 cm remote from the orbital fissure, was found and irradiated. This indicates that malignant invasion into the orbital apex and cavernous sinus along the supratrochlear and lacrimal nerves had started before radiotherapy was begun. It might have been missed, however, even if a CT scan had been made prior to the radiotherapy.

Theoretically, CT at bone window setting is capable of providing an image of slightly enlarged small foramina at the base of the skull, so a search for this kind of tumor invasion in the orbit is possible. In the orbit, however, all fissures are narrow and slitlike, so in reality, it is impossible to detect such pathology with this technique.

We have concluded that previous biopsy specimens from all morphea-like skin tumors must be reviewed carefully for perivascular and perineural tumor cells close to, as well as remote from, the tumor. If they are found, early extensive radical surgical excision or orbital exenteration offers the only possibility of preventing intracranial extension. If intracranial extension is suggested clinically, a bulk resection and radiotherapy should be considered at an early stage, even if only for palliative objectives.

## References

1. Howard GR, Nerad JA, Carter KD, Whitaker DC. Clinical characteristics associated with orbital invasion of cutaneous basal cell and squamous cell tumors of the eyelid. *Am J Ophthalmol* 1992;113:123-33.
2. Ballantyne AJ, McCarten AB, Ibanez ML. The extension of cancer of the head and neck through peripheral nerves. *Am J Surg* 1963;106:651-67.
3. Kummel C. Zur Verbreitung des Krebses in den Lymphscheiden der Nerven der Orbita. *Arch Augenheilk* 1909;62:289.
4. Moore E, Hoyt WF, North JB. Painful ophthalmoplegia following treated squamous carcinoma of the forehead. Orbital apex involvement from centripetal spread via the supraorbital nerve. *Med J Aust* 1976;1:657-59.
5. Trobe JD, Hood I, Parsons JT, Quisling RC. Intracranial spread of squamous carcinoma along the trigeminal nerve. *Arch Ophthalmol* 1982;100:608-11.
6. De Keizer RJW. Orbital and periorbital pain caused by cavernous sinus and superior orbital fissure lesions. *Orbit* 1993;12:229-36.
7. Unsold R, Safran AB, Safran E, Hoyt WF. Metastatic infiltration of nerves in the cavernous sinus. *Arch Neurol* 1993;37:59-61.
8. Czaky KG, Custer P. Perineural invasion of the orbit by squamous cell carcinoma. *Ophthalmic Surg* 1990;21:218-20.
9. Van Peperzeel HA. Radiotherapy of tumors of the orbit and ocular adnexa. In: Oosterhuis JA, ed. *Ophthalmic Tumours*. Dordrecht: Dr. W. Junk. 1985: 285-91.
10. Neumann E. Secundare cancrioid Infiltration des nervus Mentalis bei einem Fall von Lippincroid. *Arch Path Anat* 1862; 24:201.