

PDF hosted at the Radboud Repository of the Radboud University Nijmegen

The version of the following full text has not yet been defined or was untraceable and may differ from the publisher's version.

For additional information about this publication click this link.

<http://hdl.handle.net/2066/24582>

Please be advised that this information was generated on 2017-12-05 and may be subject to change.

Oral contraceptives in the treatment of Darier–White disease – a case report and review of the literature

J.H.OOSTENBRINK, E.B.COHEN, P.M.STEIJLEN* AND P.C.M. VAN DE KERKHOF*

Department of Dermatology, Spaarneziekenhuis Heemstede and *Department of Dermatology, University Hospital Nijmegen, the Netherlands

Accepted for publication 19 December 1996

Summary

In this review we illustrated the case of a woman who had perimenstrual exacerbations of Darier–White disease. The disease improved markedly with the use of continuously administered oral contraceptives. This striking improvement without side-effects supports the use of oral contraceptives in women with Darier–White disease, although its role should be investigated further using controlled studies in more patients.

Darier–White disease (keratosis follicularis) is a rare dermatosis which is characterized by the presence of keratotic papules and plaques, predominantly on the skin of the chest, back, scalp and flexures.¹ Estimates of prevalence range from 1 in 100 000 in Scandinavia to 1 in 55 000 in England.² Men and women are equally affected. The disease is dominantly inherited, and recently the gene for Darier's disease has been localized to chromosome 12.^{3,4} The disease usually begins between the ages of 6 and 20 years, with a peak onset between the ages of 11 and 15 years.² The course of the disease is chronic and in most cases slowly progressive.⁵ The activity of the disease is influenced by several factors. Many patients (71%) state that heat or sweating exacerbate the disease.^{1–3} Retinoids are known to be beneficial in the treatment of several disorders of keratinization, including Darier's disease.^{6–9} Cattano has shown that hyperkeratotic papules in Darier's disease desquamate seven times more slowly than normal surrounding skin.^{10,11} The rationale for using retinoic acid includes the promotion of exfoliation. Although oral aromatic retinoids help in most patients, side-effects seriously restrict the long-term use of this treatment.

Sex hormones also seem to influence the activity, with many women reporting changes during menstruation,

pregnancy and menopause.^{2,12,13} The fact that the disease often starts at puberty supports this hypothesis.² The disease during pregnancy was described as improving by Epsy *et al.*¹³ In Burge's series 10 of 52 patients improved while 26 did not notice any alteration and six patients became worse during pregnancy.² Telang *et al.* mention one case of a woman with Darier's disease which became worse during pregnancy.¹² Burge and Wilkinson reported that most women were unable to link activity of the disease to their menstrual cycle, although 10 women (14%) noticed perimenstrual exacerbations.² Epsy *et al.* reported that all their patients (eight) noticed flares during menstruation, ranging from occasionally (three) to regularly (four) to severe (one).¹³ Epsy *et al.* also treated five patients with oral contraceptives. All five patients improved, one showing a moderate improvement or clearing of the affected areas and four showing almost complete clearing.¹³ Burge and Wilkinson observed that oral contraceptives are sometimes helpful in the management of Darier's disease for women who notice perimenstrual increases in disease activity.² Our case showed marked improvement with oral anticonceptives. The aim of the present communication is to report a case of a woman suffering from a severe manifestation of Darier's disease, who proved to have a remarkable improvement during treatment with oral contraceptives.

Case report

A 37-year-old white woman had been suffering from keratosis follicularis since the age of 11 years. In one other family member the disease was also diagnosed. The skin of the patient was generally rough. Below her breasts and the lower part of her back, the skin showed hyperkeratotic papules (Fig. 1). Her nails were dystrophic. Itching of the skin was a major problem.

At first she was treated with bland emollients. Exacerbations were treated with topical corticosteroids. The skin improved remarkably with topical corticosteroids, but after cessation the skin reverted to its

Correspondence: Prof. Dr P.C.M. van de Kerkhof, 802 Department of Dermatology, University Hospital Nijmegen, PO Box 9101, NL-6500 HB Nijmegen, the Netherlands.

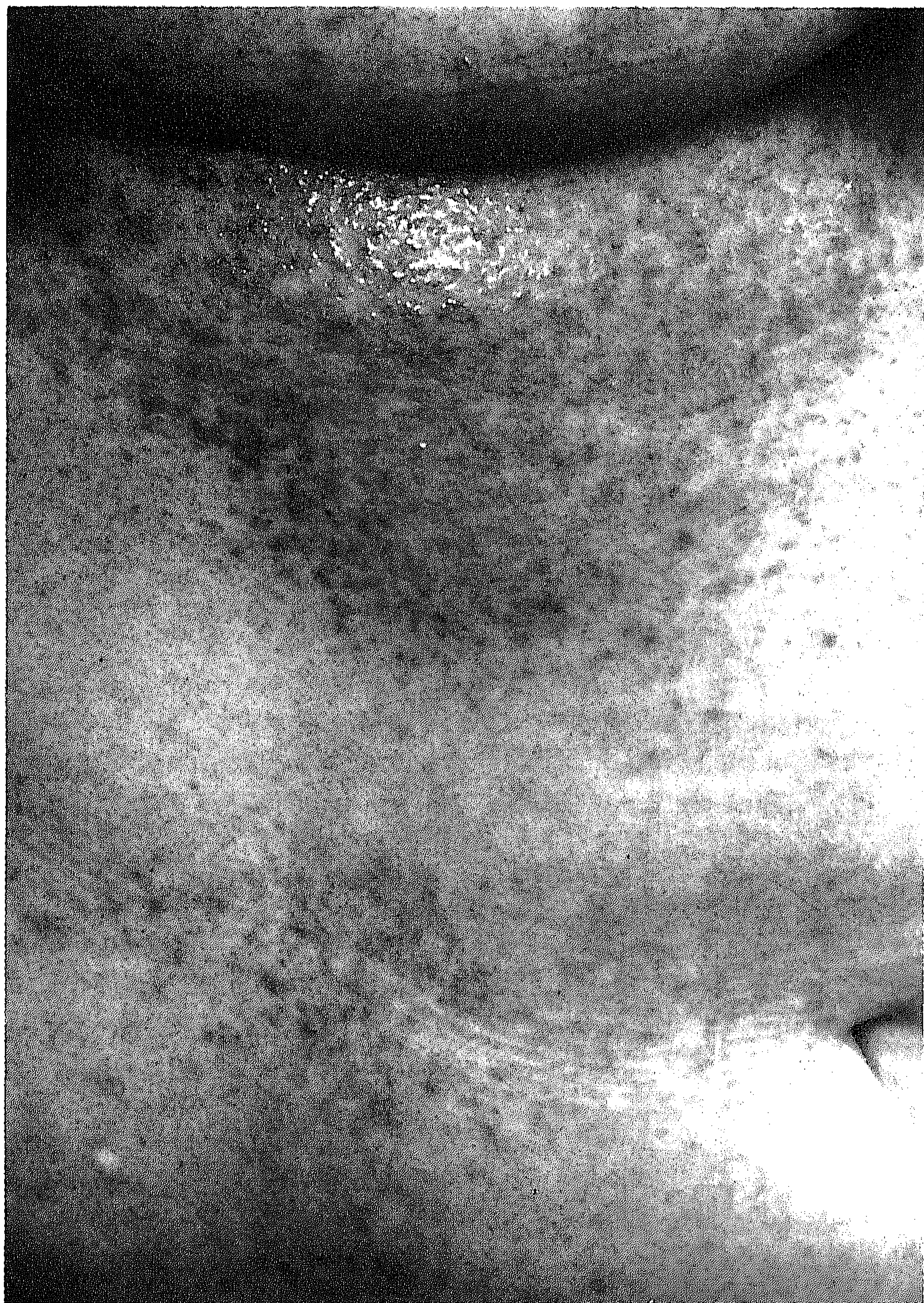


Figure 1. Hyperkeratotic papules of the abdomen.

previous state. Treatment with topical retinoids also was not helpful.

When seen in 1993 she reported that the disease had commenced at the time of her first menstruation and that during the first days of each menstruation, the skin worsened, and became more fragile, red and painful. Therefore, treatment with oral anticonceptives was initiated. She started with Marvelon (desogestrel 150 µg, ethinyloestradiol 30 µg) but as she suffered from vaginal spotting we tried the alternative of Microgynon 50 (levonorgestrel 125 µg, ethinylestradiol 50 µg). Two months after starting this medication the skin improved. The itching had subsided and the skin seemed to be less fragile. Although the skin lesions did not completely clear they were reduced in number and severity, and in particular oozing of the skin was improved. In the first year she used the medication continuously, after which she discontinued treatment during 1 week out of every 3 months. During each withdrawal bleed the activity of the skin disease remained improved. Except for weight gain she did not notice any side-effects of Microgynon 50. She continued to use this

medication and in summertime she also used a sunblock. The improvement of the skin has continued throughout the year now for over 2 years.

Discussion

Our paper demonstrates the major effect of oral contraceptives for long-term therapy of Darier's disease. Our case confirms earlier observations suggesting that sex hormones may modulate the expression of disease severity in Darier's disease.

Although evidence does exist for a causal relation between hormonal factors and Darier's disease, the responsible hormone has not been identified yet. Because the disease begins at puberty, one would suggest the rise of oestrogens or progesterone to be involved. Progesterone may have aggravated the disease by increasing the body temperature. This would explain perimenstrual exacerbations and improvement with oral anticonceptives, as progesterone levels are high before menstruation. With the use of oral contraceptives premenstrual peak levels of progesterone are avoided. However, if either oestrogens or progesterone would be responsible for exacerbations one would expect an increase of the disease during pregnancy and a decrease during the menopause. However, such is not the classical course of Darier's disease.

The use of oral contraceptives changes the serum level of the sex hormone binding globulin. If the blood level of free testosterone becomes lower as a consequence of this, this might have a positive influence of the skin disease.

It is attractive to speculate that a rise of follicle stimulating hormone has an effect on the disease severity. High blood levels of this hormone occur in episodes in which the disease as a rule is worse, such as puberty, and the menopause.² Low blood levels occur when the disease is improved, for example before puberty, during pregnancy and during treatment with oral contraceptives.

Retinoids are effective in Darier's disease.^{7,9} Occasionally, topical corticosteroids and calcipotriol may be effective, as in our patient. Vitamin D₃, retinoids and corticosteroids are ligands of the steroid and thyroid hormone receptor superfamily.¹⁴ It is of interest that sex hormones also belong to the ligands for a receptor for this superfamily. Although different hormones specifically bind to the corresponding receptor, intercommunication between various ligand-receptor interactions is active.¹⁵ Ligand-activated receptors may form heterodimers and as such provide a new communication. Receptor activation may cause upregulation of receptors for other ligands. Ligand-activated receptors may repress activation of other signalling pathways.¹⁶

Darier's disease and many disorders of keratinization respond to ligands of the steroid receptor superfamily. The present case report suggests that studies on the interaction of sex hormones with this signalling process might improve the long-term management of disorders of keratinization.

References

1. Yell JA, Burge SM, Dean D. Cantharidin-induced acantholysis in Darier's disease: does acantholysis initiate dyskeratosis? *Br J Dermatol* 1994; **131**: 40-7.
2. Burge SM, Wilkinson JD, Darier-White disease: a review of the clinical features in 163 patients. *J Am Acad Dermatol* 1992; **27**: 40-50.
3. Parfitt E, Burge S, Craddock N *et al.* The gene for Darier's disease maps between D12S78 and D12S7k9. *Hum Mol Genet* 1994; **3**: 5-38.
4. Craddock N, Dawson E, Burge S *et al.* The gene for Darier's disease maps to chromosome 12Q23-Q241. *Hum Mol Genet* 1993; **2**: 1941-3.
5. Dooren-Greebe RJ van, Kerkhof PCM van de, Happle R. Acitretin monotherapy in Darier's disease. *Br J Dermatol* 1989; **121**: 375-9.
6. Marks R, Finlay AY, Holt PJA. Severe disorders of keratinization: effects of treatment with Tigason (etretinate). *Br J Dermatol* 1981; **103**: 667-73.
7. Burge SM, Wilkinson JD, Miller AJ, Ryan TJ. The efficacy of an aromatic retinoid, Tigason (etretinate), in the treatment of Darier's disease. *Br J Dermatol* 1981; **103**: 675-9.
8. Blanchet Bardon C, Nazzaro V, Rognin C *et al.* Acitretin in the treatment of severe disorders of keratinization. *J Am Acad Dermatol* 1991; **24**: 982-6.
9. Happle R, van de Kerkhof PCM, Traupe H. Retinoids in disorders of keratinization: their use in adults. *Dermatologica* 1987; **175**: 107-24.
10. Moore JA, Schosser RH. Unilateral keratosis follicularis. *Cutis* 1985; **35**: 459-61.
11. Cattano AN. An unusual case of keratosis follicularis. *Arch Dermatol* 1968; **98**: 168.
12. Telang GH, Atillasoy E, Stierstorfer M. Localized keratosis follicularis associated with menotropin treatment and pregnancy. *J Am Acad Dermatol* 1994; **30**: 271-2.
13. Epsy PD, Stone S, Jolly HW. Hormonal dependency in Darier disease. *Cutis* 1976; **17**: 315-20.
14. Evans RM. The steroid and thyroid hormone receptor superfamily. *Science* 1988; **240**: 889-94.
15. Kerkhof PCM van de. Biological activity of vitamin D₃ analogues in the skin, with special reference to antipsoriatic mechanisms. *Br J Dermatol* 1995; **132**: 675-82.
16. van de Stolpe A, Caldenhoven E, Raaijmakers JAM, van der Saag PT, Koenderman L. Glucocorticoid mediated repression of the intercellular adhesion molecule-1 expression in human monocytic and bronchial epithelial cell lines. *Am J Respir Cell Biol* 1993; **8**: 340-7.