



PDF hosted at the Radboud Repository of the Radboud University Nijmegen

The following full text is a publisher's version.

For additional information about this publication click this link.

<http://hdl.handle.net/2066/24462>

Please be advised that this information was generated on 2017-12-05 and may be subject to change.

Mutation in Mitochondrial tRNA^{Leu(UUR)} Gene Associated with Progressive Kidney Disease

JANNA J. JANSEN,* J. ANTONIE MAASSEN,[†] FOKKO J. VAN DER WOUDE,[‡] HENNY A. J. LEMMINK,[§] JODY M. W. VAN DEN OUWELAND,[†] LEEN M. 'T HART,[†] HUBERT J. M. SMEETS,[§] JAN ANTHONIE BRUIJN,^{||} and HERMAN H. P. J. LEMKES*

Departments of *Metabolic Diseases and Endocrinology, [†]Medical Biochemistry, [‡]Nephrology, and [§]Pathology, University Hospital Leiden, Leiden, The Netherlands; and ^{||}Department of Human Genetics, University Hospital Nijmegen, Nijmegen, The Netherlands.

Abstract. Several studies show an association of a guanine for adenine substitution (A → G) at position 3243 in mitochondrial DNA (mtDNA) with a recently recognized diabetic subtype designated maternally inherited diabetes and deafness (MIDD). This mutation shows heterogeneity in its phenotypic expression as is apparent from its association with several other syndromes. Screening for the 3243A → G mutation in mtDNA was performed in those diabetic patients attending the Leiden University Hospital diabetes clinic who had a history of maternally inherited diabetes, sensorineural hearing loss, or both. Four individuals from three unrelated families were identified who suffered from progressive nondiabetic kidney disease in association with diabetes mellitus and hearing loss. The mode of inheritance suggested maternal transmission. The combina-

tion of renal failure and hearing loss had been misdiagnosed as Alport syndrome in three of the four individuals. Therefore, in addition to these three families, another 63 unrelated patients with possible Alport syndrome were selected at random. DNA from peripheral blood and other tissues from members of the three families and from the 63 additional Alport syndrome patients was examined for the presence of the 3243A → G mutation in mtDNA. The mutation was detected in heteroplasmic form in the four patients and their maternal relatives. Also, one of the 63 suspected Alport syndrome patients showed heteroplasmy for the 3243 mutation. These data show the existence of a kidney disease that is characterized by the presence of the A → G mutation at position 3243 in the mtDNA. (J Am Soc Nephrol 8: 1118–1124, 1997)

Previously, we reported the association of maternally inherited diabetes and deafness (MIDD) with a guanine for adenine (A → G) transition at position 3243 in the mitochondrial DNA (mtDNA) (1,2). Subsequently, this mutation was identified in approximately 1% of diabetic populations in both Europe (3,4) and Japan (5,6). Interestingly, the same mutation is also present in most patients with the MELAS syndrome (myopathy, encephalopathy, lactic acidosis, and strokelike episodes) (7), indicating a striking phenotypic heterogeneity in expression of the mutation. The pathophysiological basis of this phenomenon is unknown, but variations in tissue-specific heteroplasmy (mixtures of wild-type and mutant mtDNA at a cellular level) or effects of the nuclear background have been suggested.

We re-evaluated the type of diabetes in those diabetic patients in our outpatient department who had a history of maternally inherited diabetes, sensorineural hearing loss, or both, by screening for the presence of the 3243 mutation in mtDNA. In four female postrenal transplant patients from three unre-

lated families, the mutation was found. Remarkably, three of them had been diagnosed with Alport syndrome, although hematuria had never been present. They developed steroid-induced diabetes after kidney transplantation for end-stage renal failure. This suggests that primary kidney disease with progressive renal failure may represent a third major phenotypic expression of the 3243 mtDNA mutation.

Materials and Methods

Screening for the 3243 mtDNA mutation in those diabetic patients attending the Leiden University Hospital diabetes clinic who had a maternal family history of diabetes, sensorineural hearing loss, or both revealed 15 positive individuals from 14 families. Of these, four positive female patients from three families had a medical history in which kidney disease was predominant and diabetes was only secondary to steroid treatment after renal transplantation. Their clinical characteristics are given below. A detailed family history was recorded (Figure 1). Nine family members of these four probands, all in the maternal lineage and reported to be free of clinical disease, were screened for presence of the mutation, changes in glucose homeostasis, hearing loss, and kidney disease by assessing the ratio of albumin to creatinine in a fasting urine sample (8). A complete medical history was taken, and blood pressure, height, and weight were measured. A urine sediment was examined for the presence of hematuria. After an overnight fast, venous blood samples were collected for assessment of glucose, glycosylated hemoglobin (HbA1c), and creatinine, and an oral 75-g glucose tolerance test was performed.

Received March 3, 1997. Accepted March 22, 1997.

Correspondence to Dr. Janna J. Jansen, University Hospital Leiden, Department of Metabolic Diseases and Endocrinology, Building 1, C4-R, P.O. Box 9600, 2300 RC Leiden, The Netherlands.

1046-6673/0807-1118\$03.00/0

Journal of the American Society of Nephrology

Copyright © 1997 by the American Society of Nephrology

Glycosylated hemoglobin (HbA1c) was determined by an HPLC method. The normal range for this method is 4.3 to 6.3%. Urinary albumin excretion was assessed by methods of a kinetic "rate"-nephelometry system (upper limit of normal of <0.019 g/L). Creatinine was assessed by an autoanalyzer technique (normal ranges, 70 to 133 $\mu\text{mol/L}$ [0.8 to 1.5 mg/dl]).

mtDNA Analysis

Total DNA, isolated from peripheral blood, oral mucosa, fibroblasts, or kidney, was examined for the presence and the degree of heteroplasmy for the mt3243 mutation. This mutation generates an *ApaI* restriction site. The region surrounding the tRNA^{Leu(UUR)} gene mutation was amplified using ³²P-labeled nucleotides and subsequently digested with *ApaI*. DNA fragments were separated by electrophoresis on polyacrylamide gels, and radioactivity in the fragments was quantified by liquid scintillation counting and by quantification on a phosphorimager. To examine the possible relationship between the three pedigrees, mitochondrial polymorphism at positions 195 and 16304 was examined by DNA sequence analysis.

Results

The four probands (A-III-4, A-III-2, B-IV-3, and C-IV-3) are Caucasian women with a comparable history of disease (Table 1). At a mean age of 26 yr (range, 17 to 35 yr), they developed hypertension, proteinuria, and a slow progression of renal failure, in combination with sensorineural hearing loss, the latter most pronounced at high frequencies and necessitating a hearing aid. No hematuria had ever been documented. Nevertheless, the diagnosis of Alport syndrome was assumed in three cases. After a mean period of 7 yr (range, 3 to 9 yr), end-stage renal failure had developed necessitating hemodialysis, and kidney transplantation followed after a mean period

of 4 yr (range, 2 to 6.5 yr). After transplantation and during high doses of prednisone, three of them (A-III-4, A-III-2, and B-IV-3) developed diabetes mellitus. In the other female carrier (C-IV-3), the presence of gestational diabetes was reported approximately 7 yr before transplantation, and non-insulin-dependent diabetes had become manifest 2 yr before transplantation.

Three years before transplantation, subject A-III-2 underwent bilateral nephrectomy, which led to the histological diagnosis of chronic lobular glomerulonephritis. Renal biopsies of patient B-IV-3 and patient C-IV-3 were reported to show focal glomerulosclerosis and chronic glomerulosclerosis with hyalinized glomeruli, respectively. None of these biopsies was available for re-examination.

In addition, because three of the four female patients had been diagnosed as having Alport syndrome, DNA from 63 patients with the clinical diagnosis of Alport syndrome (University Hospital Nijmegen) was screened for the mt 3243 mutation and found to be positive in one case.

Figure 1 shows the pedigrees of the three families. There is no known relation in the maternal lineage between the pedigrees. This is underscored by a different mtDNA haplotype; e.g., pedigree A shows at position 195 a C in homoplasmic form, whereas pedigree B exhibits a T. Similarly, at position 16304, pedigrees A and B have a T and C, respectively.

All nine additional examined maternal relatives were also found to be positive for the mutation. Figure 2 shows the results of mtDNA analysis in three subjects and a healthy control. Proteinuria was found in subject A-IV-7, son of proband A-III-4, and to a lesser extent in the youngest daughter of

Table 1. Characteristics of the examined members of the three families^a

| Subject ^b | Sex | Age | OGTT DM (age at onset; therapy) ^c | Hearing Loss (dB) | Serum-Creatinine ^d ($\mu\text{mol/L}$) | Urinary Albumin to Creatinine (mg/mmol) | Blood Pressure (mmHg) | % Heteroplasmy ^e | |
|----------------------|-----|-----|--|-------------------|---|---|-----------------------|-----------------------------|-------------|
| | | | | | | | | Blood | Oral Mucosa |
| A-III-4 (prob) | F | 56 | DM (38;I) | HA | RTx (38) | | AHT | 12 | 21 |
| A-III-2 (prob) | F | 65 | DM (48;D) | HA | RTx (47) | | AHT | 6 | 15 |
| A-III-3 | F | 61 | N | 80 | 83 | 0.4 | 160/84 | 5 | 17 |
| A-IV-3 | M | 35 | N | 0 | 92 | 0.4 | 130/80 | 4 | 4 |
| A-IV-4 | M | 31 | N | 0 | 96 | 0.5 | 117/67 | 13 | 15 |
| A-IV-5 | F | 28 | N | 0 | 79 | 0.4 | 117/79 | 9 | 16 |
| A-IV-6 | F | 25 | N | 0 | 73 | 1.4 | 110/77 | 17 | 30 |
| A-IV-7 | M | 30 | N | 45 | 79 | 45.5 | 140/90 | 20 | 31 |
| A-IV-8 | F | 28 | N | 30 | 71 | 0.7 | 117/90 | 27 | 35 |
| A-IV-9 | F | 26 | N | 40 | 68 | 3.5 | 120/77 | 17 | 30 |
| B-IV-3 (prob) | F | 34 | DM (25;O) | HA | RTx (25) | | AHT | 34 | 32 |
| C-IV-3 (prob) | F | 41 | DM (34;I) | HA | RTx (36) | | AHT | 18 | 32 |
| C-III-1 | F | 69 | N | 60 | 79 | 1.5 | 126/70 | 4 | 7 |

^a OGTT, oral glucose tolerance test; DM, diabetes mellitus; I, insulin; D, diet; O, oral medication; dB, decibel; prob, proband; F, female; HA, hearing aid; RTx, renal transplantation; AHT, antihypertensive treatment; N, normal outcome of OGTT; M, male.

^b Capital letters indicate family, roman numerals generation, and arabic numerals identification number.

^c Age at diagnosis and mode of therapy are given in parentheses.

^d Age at transplantation is given in parentheses.

^e % heteroplasmy indicates the percentage of total mitochondrial DNA in the tissue examined harboring the mutation.

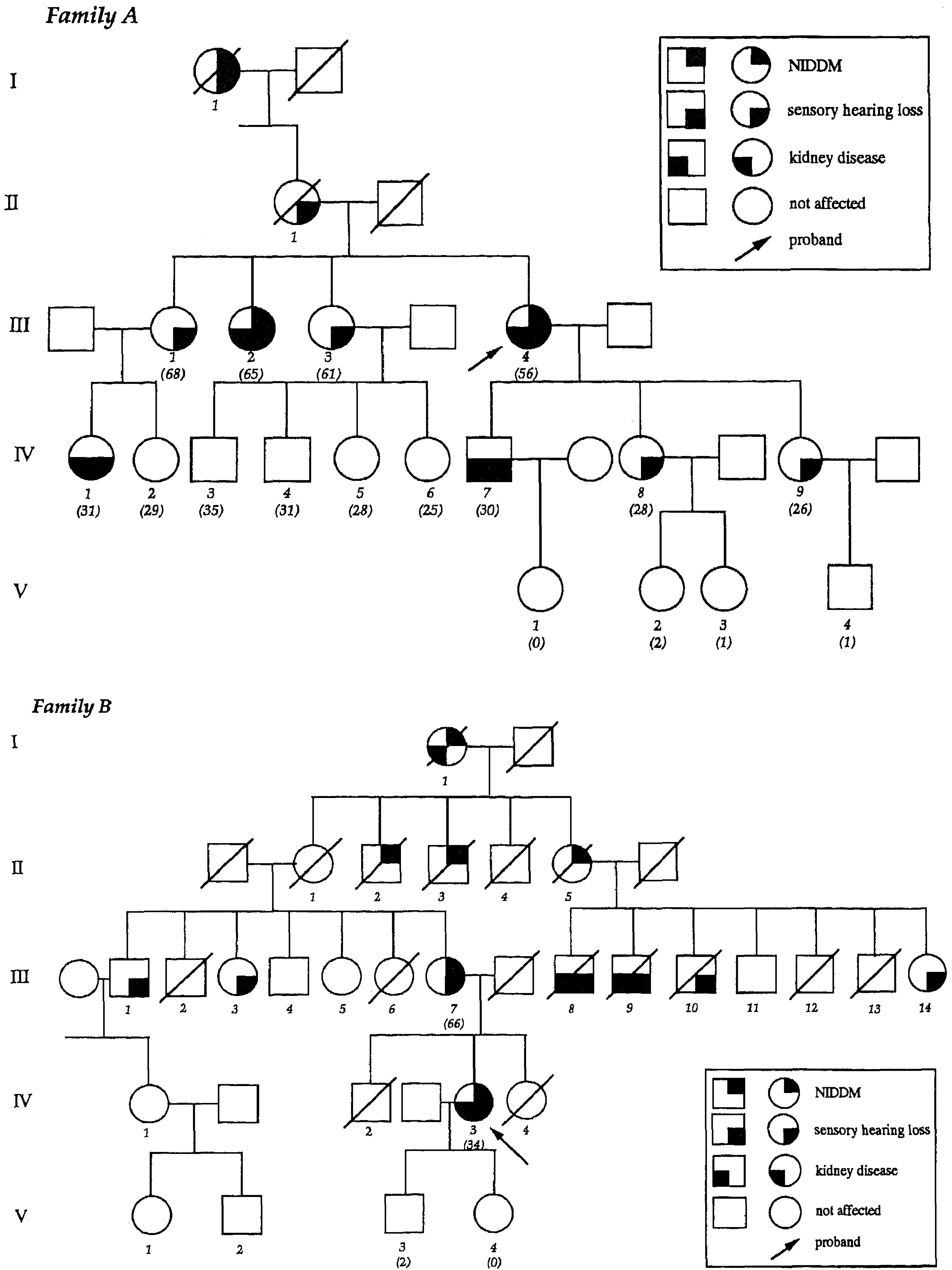


Figure 1. The pedigrees of families A, B, and C. Roman numerals indicate generations. The first line below each symbol represents an identification number. The numerals in parentheses on the second line indicate ages at the time of death or at the time of examination.

Family C

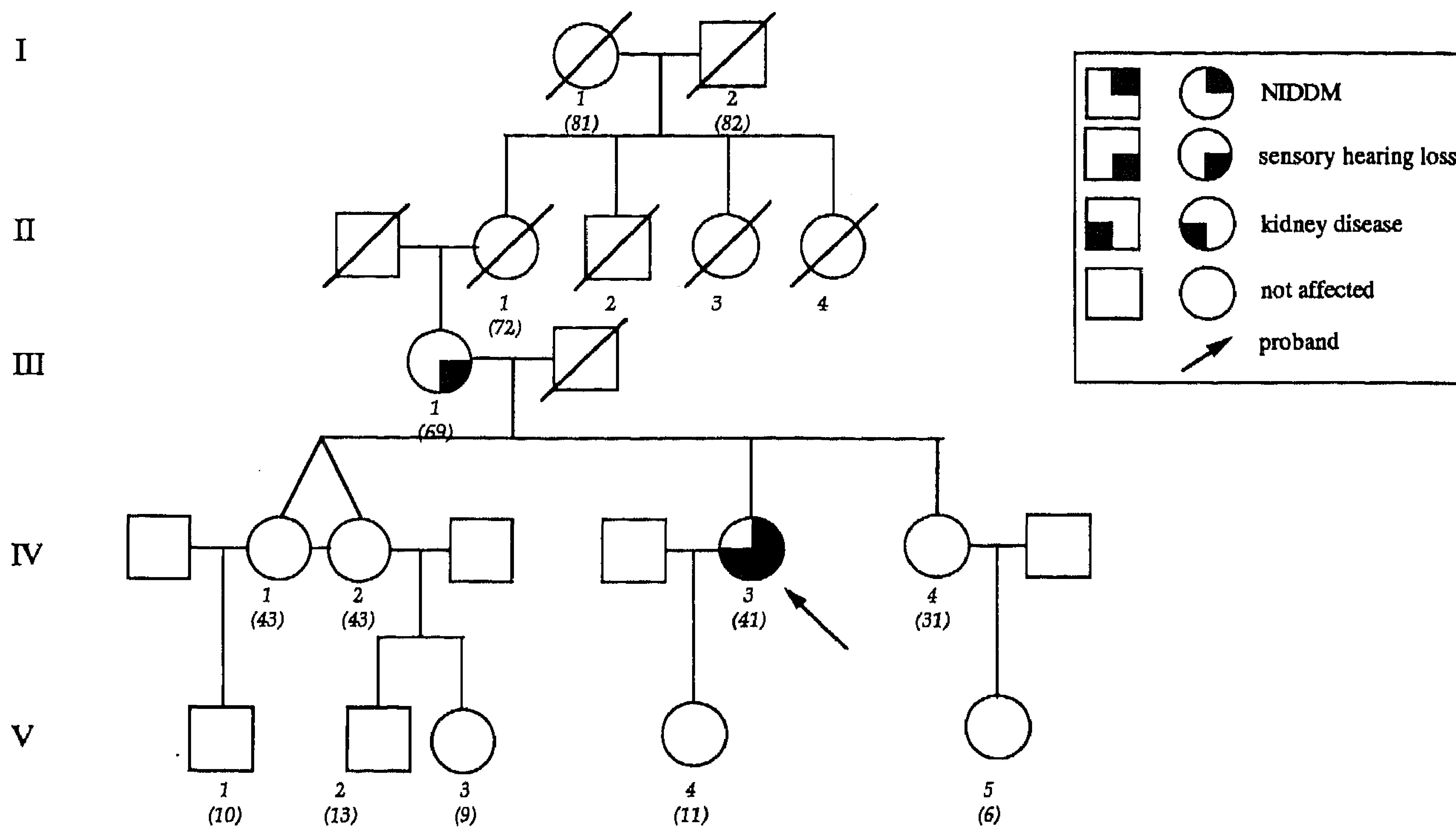


Figure 1c.

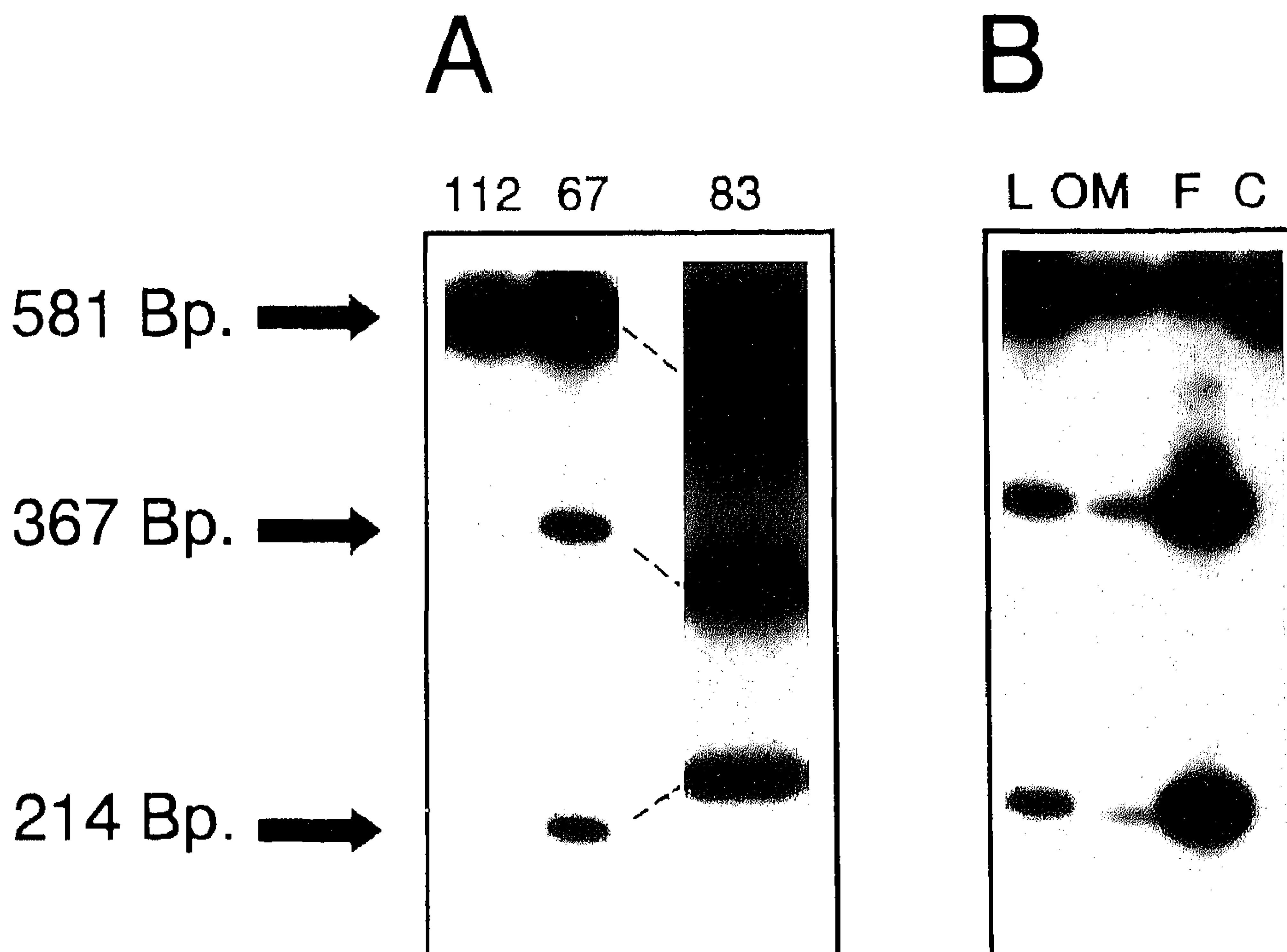


Figure 2. *Apa*I digestion of amplified PCR fragments. (A) Blood (leukocytes). Lane 112, patient A-III-2; lane 67, patient A-III-4; lane 83, patient B-IV-3. (B) Tissue distribution in patient A-III-4. L, leukocyte; OM, oral mucosa; F, fibroblast; C, healthy control.

this proband (A-IV-9) (albumin to creatinine ratio, 45.5 and 3.5 mg/mmol, respectively). No hematuria was observed. In a timed urine sample of subject A-IV-7, total albumin excretion rate was found to be 1.5 g/24 h. For this reason, he underwent

renal biopsy, which showed no pathologic alterations at light microscopy. Immunofluorescence showed only small quantities of IgM in mesangial areas of some glomeruli, and no deposits of IgG, IgA, C3, and C1q. When examined by electron

microscopy, the glomerular basement membrane showed some variation in thickness. The most striking alterations observed concerned the glomerular visceral epithelial cells, which showed extensive obliteration of their foot processes (Figure 3). No electron-dense deposits were found along the glomerular capillary walls or in the mesangial areas. Immunofluorescence studies using an antibody against Goodpasture's antigen showed staining of the glomerular basement membrane on both the kidney of this subject and a healthy control kidney, sug-

gesting that Goodpasture's antigen was present in both. The patient's current creatinine clearance rate was 138 ml/min.

Discussion

Our data show the presence of an A → G transition at position 3243 in mtDNA in four female patients from three pedigrees, three of whom were previously thought to have Alport syndrome. So far, this mutation has been described mainly in association with either MELAS or MIDD. There are

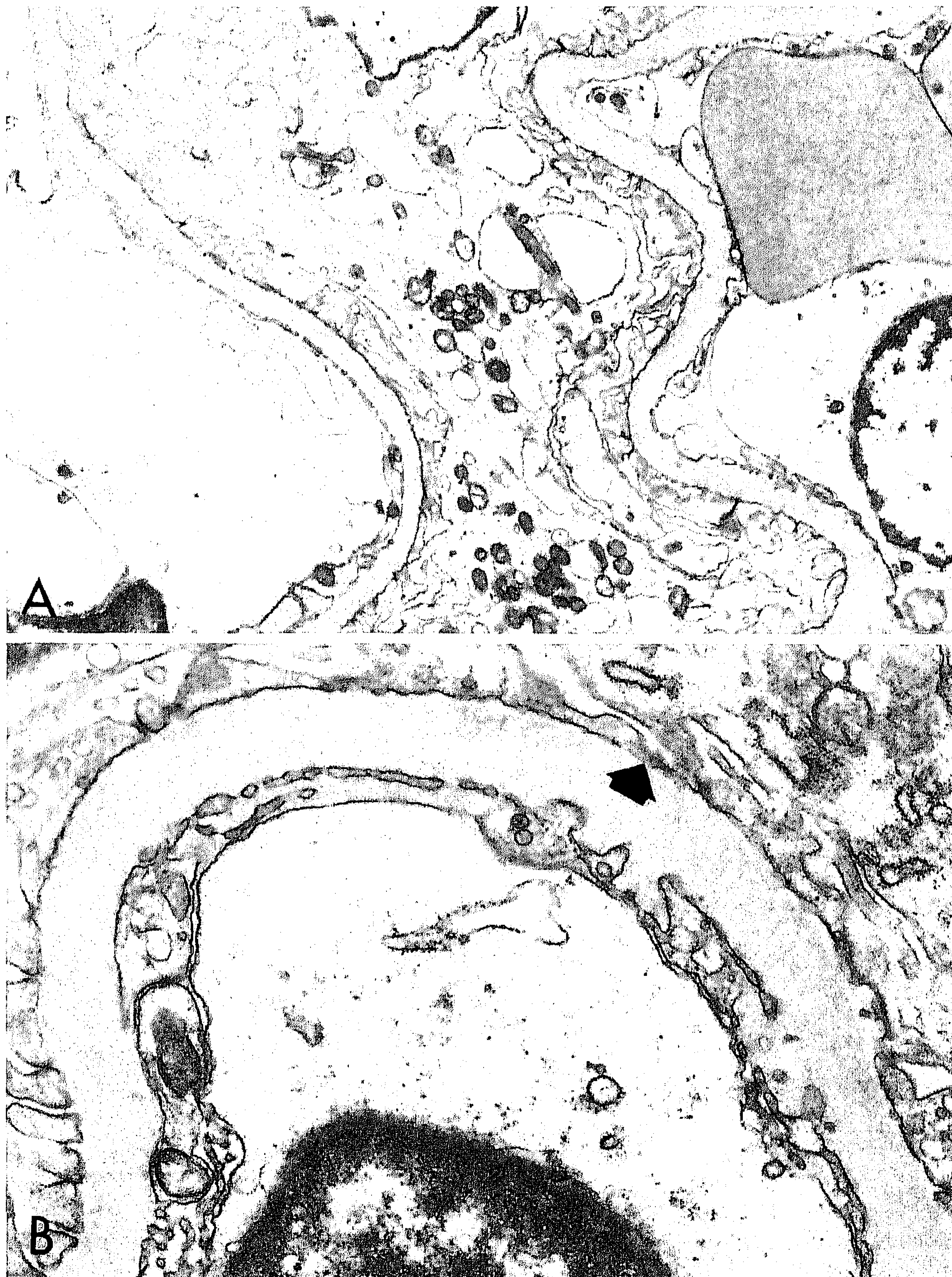


Figure 3. Electron microscopic picture of a glomerular capillary wall in renal biopsy of patient A-IV-7. (A) The glomerular basement membrane varies somewhat in thickness. The most striking alterations observed concern the glomerular visceral epithelial cells, which show extensive obliteration of their foot processes. No electron-dense deposits are found along the glomerular capillary wall and in the mesangial area (Magnification, $\times 7700$). (B) Higher enlargement illustrating extensive effacement of glomerular visceral epithelial cell foot processes (arrow) (Magnification, $\times 23,100$).

two case histories in which the mutation was found in association with kidney disease. Manouvrier *et al.* (9) described a family with hypertrophic cardiomyopathy, diabetes mellitus, renal failure, and sensorineural deafness. Yorifuji *et al.* (10) reported the mutation in a child with growth hormone deficiency, nephropathy, moderate mental retardation, diabetes, and facial dysmorphism. The mutation is virtually absent in the background population without these syndromes. By chance, the finding of three unrelated pedigrees with a kidney disease clinically mimicking Alport syndrome, having the 3243 mutation, is extremely unlikely, and its more-than-sporadic occurrence indicates an association of the mutation with a new syndrome or phenotypical expression. This suggestion was further approached independently by screening 63 suspected Alport syndrome patients, which demonstrated one additional case of the mtDNA mutation.

The patients described in this paper share the characteristics of hereditary progressive renal disease and hearing loss with Alport syndrome, but in retrospect, the absence of hematuria and the severity of kidney disease in women are unusual features. Also, the glomerular capillary wall abnormality in a kidney biopsy from a proteinuric carrier of the mutation differs from the histological abnormalities in Alport syndrome.

It should be recognized that the new syndrome we describe in this article is only a new phenotypical expression in the surprisingly broad clinical spectrum associated with the mtDNA 3243 mutation, which is also true in all mtDNA diseases, as reviewed recently (11). This might be related to the special features of mitochondrial inheritance, including heteroplasmy (mixtures of wild-type and mutant mtDNA at a cellular level) and different levels of heteroplasmy in specific tissues. The mtDNA 3243 mutation, coding for the mt tRNA^{Leu(UUR)}, causes a defect in the mitochondrial synthesis of proteins involved in oxidative phosphorylation and, hence, results in diminished ATP production. An indication for the importance of the oxidative phosphorylation in renal tissue is also given by the description of other mtDNA defects. mtDNA deletions have been found in a few patients with Pearson syndrome (including tubulopathy), Kearns-Sayre syndrome, and in patients with chronic tubulointerstitial nephropathy (12–20).

Although the dominant clinical features of MELAS, MIDD, and the above-described new syndrome are different, these mt 3243 syndromes show some overlap in the concomitant occurrence of mild neuromuscular disease, hearing loss, diabetes, and renal insufficiency.

In clinical practice, in the case of patients with progressive hereditary renal disease and sensorineural hearing loss without the characteristic features of Alport disease, one should consider the presence of this mitochondrial kidney disease. Screening for the mt 3243 mutation in patients with Alport-like clinical manifestations is relatively easy. This might be important in genetic counseling, to eliminate X-linked transmission of the disease, as in classic Alport syndrome. The prevalence of the above-described new syndrome, its pathophysiology and natural history, and the clinical penetrance of renal disease in carriers of the mt 3243 mutation have yet to be established.

References

1. Van den Ouweland JMW, Lemkes HHPJ, Ruitenbeek W, Sandkuyl LA, de Vijlder MF, Struyvenberg PA, van de Kamp JJ, Maassen JA: Mutation in mitochondrial tRNA^{Leu(UUR)} gene in a large pedigree with maternally transmitted type II diabetes mellitus and deafness. *Nat Genet* 1: 368–371, 1992
2. Van den Ouweland JMW, Lemkes HHPJ, Trembath RC, Ross R, Velho G, Cohen D, Froguel P, Maassen JA: Maternally inherited diabetes and deafness is a distinct subtype of diabetes and associates with a single point mutation in the mitochondrial tRNA (leu(UUR)) gene. *Diabetes* 43: 746–751, 1994
3. Vionnet N, Passa P, Froguel P: Prevalence of mitochondrial gene mutations in families with diabetes mellitus. *Lancet* 342: 1429–1430, 1993
4. 't Hart LM, Lemkes HHPJ, Heine RJ, Stolk RP, Feskens EJ: Prevalence of maternally inherited diabetes and deafness in diabetic populations in the Netherlands [Letter]. *Diabetologia* 37: 1169, 1994
5. Kadowaki T, Kadowaki H, Mori Y, Tobe K, Sakuta R, Suzuki Y, Tanabe Y, Sakura H: A subtype of diabetes mellitus associated with a mutation in the mitochondrial gene. *N Engl J Med* 330: 962–968, 1994
6. Katagiri H, Asano T, Ishihara H, Inukai K, Arai M, Yamanouchi T, Tsukada K, Kikuchi M, Kitaoka H, Ohsawa N, Yazaki Y, Oka Y: Mitochondrial diabetes mellitus: Prevalence and clinical characterization of diabetes due to mitochondrial tRNA^{Leu(UUR)} gene mutation in Japanese patients. *Diabetologia* 37: 504–510, 1994
7. Goto Y, Nonaka I, Horai S: A mutation in the tRNA^{Leu(UUR)} gene associated with the MELAS subgroup of mitochondrial encephalomyopathies. *Nature* 348: 651–653, 1990
8. Ginsberg JM, Chang BS, Matarese RA, Garella S: Use of single void urine samples to estimate quantitative proteinuria. *N Engl J Med* 309: 1543–1546, 1983
9. Manouvrier S, Rötig A, Hannebique G, Gheerbrandt JD, Royer-Legrain G, Munnich A, Parent M, Grunfeld JP, Largilliere C, Lombes A, Bonnefont JP: Point mutation of the mitochondrial tRNA^{Leu} gene (A 3243 G) in maternally inherited hypertrophic cardiomyopathy, diabetes mellitus, renal failure, and sensorineural deafness. *J Med Genet* 32: 654–656, 1995
10. Yorifuji T, Kawai M, Momoi T, Sasaki H, Furusho K, Muroi J, Shimizu K, Takahashi Y, Matsumura M, Nambu M, Okuno T: Nephropathy and growth hormone deficiency in a patient with mitochondrial tRNA^{Leu(UUR)} mutation. *J Med Genet* 33: 621–622, 1996
11. Johns DR: Mitochondrial DNA and disease. *N Engl J Med* 333: 638–644, 1995
12. Eviatar L, Shanske S, Gauthier B, Abrams C, Maytal J, Slavin M, Valderrama E, DiMauro S: Kearns-Sayre syndrome presenting as renal tubular acidosis. *Neurology* 40: 1761–1763, 1990
13. Goto Y, Itami N, Kajii N, Tochimaru H, Endo M, Horai S: Renal tubular involvement mimicking Bartter syndrome in a patient with Kearns-Sayre syndrome. *J Pediatr* 116: 904–910, 1990
14. Rötig A, Cormier V, Blanche S, Bonnefont JP, Ledeist F, Romero N, Schmitz J, Rustin P, Fischer A, Saudubay JM, Minnich A: Pearson's marrow-pancreas syndrome: A multisystem mitochondrial disorder in infancy. *J Clin Invest* 86: 1601–1608, 1990
15. McShane MA, Hammans SR, Sweeney M, Holt IJ, Beattie TJ, Brett EM, Harding AE: Pearson syndrome and mitochondrial encephalomyopathy in a patient with a deletion of mtDNA. *Am J Hum Genet* 48: 39–42, 1991
16. Majander A, Suomalainen A, Vettenranta K, Suriola H, Perkkio M, Holmberg C, Pihko H: Congenital hypoplastic anemia, dia-

- betes, and severe renal tubular dysfunction associated with a mitochondrial DNA deletion. *Pediatr Res* 30: 327–330, 1991
17. Rötig A, Bessis JL, Romero N, Cormier V, Saudubay JM, Narcy P, Lenoir G, Rustin P, Munnich A: Maternally inherited duplication of the mitochondrial genome in a syndrome of proximal tubulopathy, diabetes mellitus, and cerebellar ataxia. *Am J Hum Genet* 50: 364–370, 1992
18. Szabolcs MJ, Seigle R, Shanske S, Bonilla E, DiMauro S, D'Agati V: Mitochondrial DNA deletion: A cause of chronic tubulointerstitial nephropathy. *Kidney Int* 45: 1388–1396, 1994
19. Luder A, Barash V: Complex I deficiency with diabetes, Fanconi syndrome and mtDNA deletion. *J Inherited Metab Dis* 17: 298–300, 1994
20. Rötig A, Goutières F, Niaudet P, Rustin P, Chretien D, Guest G, Mikol J, Gubler MC, Munnich A: Deletion of mitochondrial DNA in patient with chronic tubulointerstitial nephritis. *J Pediatr* 126: 597–601, 1995