Radboud Repository

Radboud University Nijmegen

PDF hosted at the Radboud Repository of the Radboud University Nijmegen

The following full text is a publisher's version.

For additional information about this publication click this link.
http://hdl.handle.net/2066/24244

Please be advised that this information was generated on 2017-12-05 and may be subject to change.

Lethal infantile mitochondrial disease with isolated complex I deficiency in fibroblasts but with combined complex I and IV deficiencies in muscle

H.A.C.M. Bentlage, MSc; U. Wendel, MD; H. Schägger, PhD; H.J. ter Laak, PhD; A.J.M. Janssen, BSc; and J.M.F. Trijbels, PhD

Article abstract—A 2-month-old boy died of a lethal infantile mitochondrial disease with severe lactic acidosis and involvement of the CNS. Histochemical analysis of skeletal muscle showed that cytochrome *c* oxidase staining was lacking in all muscle fibers but was present in arterioles. Ragged red fibers were not seen, but some fibers showed excessive staining for succinate dehydrogenase. Biochemical analysis revealed a combined complex I and IV deficiency in skeletal muscle but only a complex I deficiency in his fibroblasts. Two-dimensional native SDS electrophoresis confirmed these enzymatic findings at the protein level. Analysis of mitochondrial translation products in fibroblasts revealed no abnormalities, and analysis of mitochondrial DNA in muscle showed no depletion, large-scale deletions, or frequently occurring point mutations. We conclude that this disease must have been the result of either a nuclear DNA mutation in a gene controlling the expression or assembly of both complex I and the muscle-specific isoform of complex IV or, alternatively, a heteroplasmic point mutation in a mitochondrial tRNA, which codon is used more often by mtDNA encoded subunits of complex I than by mtDNA encoded subunits of complex IV. A different degree of heteroplasmy in skeletal muscle and fibroblasts would then explain the curious heterogeneous tissue expression of defects in this patient.

NEUROLOGY 1996;47:243–248

Mitochondrial encephalomyopathies are a heterogeneous group of disorders in which various tissues are affected, predominantly skeletal muscle and the CNS.[1] The primary cause of disease is thought to be a defect in the mitochondrial energy metabolism. The five enzyme complexes (complexes I to V) of oxidative phosphorylation (OXPHOS) play a crucial role in this ATP-generating system. Each mitochondrion contains its own mitochondrial DNA (mtDNA), which is maternally inherited. The mtDNA encodes seven subunits of NADH:ubiquinone oxidoreductase (complex I), one subunit of ubiquinol:cytochrome *c* oxidoreductase (complex III), three subunits of cytochrome *c* oxidase (COX) (complex IV), two subunits of ATP synthase (complex V), two ribosomal RNAs, and 22 transfer RNAs necessary for mtDNA gene expression.[2] The genes of complexes I, III, IV, and V are located in both the mtDNA and the nuclear DNA (nDNA). Succinate:ubiquinone oxidoreductase (complex II) contains only nDNA encoded subunits. All nDNA encoded subunits are imported into the mitochondria where they are assembled together with the mtDNA encoded subunits. Deficiencies in complex I and complex IV, either alone or combined, are found most frequently.[3-6]

A growing number of mitochondrial encephalomyopathies or other neurologic disorders have been associated with deletions, depletions, or more than 30 point mutations in the mtDNA.[7] These mutations are often found only in a proportion of the mtDNA molecules (heteroplasmy). Also, nDNA mutations affecting OXPHOS are expected to cause these diseases but have not been described so far.

We present a patient who immediately after birth had a severe lactic acidosis. Biochemical analysis revealed a combined deficiency of complex I and IV in muscle tissue but only an isolated complex I deficiency in fibroblasts.

Case report. A boy was born by normal delivery after an uncomplicated 39-week pregnancy. Birth weight was 3,680 g, length was 54.5 cm, and head circumference was 35 cm. His unrelated parents and a 4-year-old sister are in good health.

Within 18 hours after birth, the baby became tachypnoeic and developed an overwhelming lactic acidosis (blood pH 7.02, base excess −25.3 mmol/L, blood lactate 88 to 147 mg/dL [normal <16 mg/dL] and pyruvate 1.13 mg/dL [normal <0.59 mg/dL]). There were no signs of an infection. Plasma amino acid analysis revealed hyperalaninemia. Repeated urine analysis showed variable increased excretion of lactate, ethylmalonate, and 3-hydroxybutyrate. In CSF, lactate was elevated (42 mg/dL; normal 11 to 19 mg/dL).

From the Departments of Pediatrics (Drs. Bentlage, Wendel, Janssen, and Trijbels) and Neurology (Dr. Ter Laak), University Hospital Nijmegen, The Netherlands, and Zentrum der Biologischen Chemie (Dr. Schägger), Universitätsklinikum Frankfurt, Frankfurt am Main, Germany.

Received August 10, 1995. Accepted in final form October 4, 1995.

Address correspondence and reprint requests to Dr. Herman A.C.M. Bentlage, Department of Pediatrics, University Hospital Nijmegen, P.O. Box 9101, 6500 HB Nijmegen, The Netherlands.

Copyright © 1996 by the American Academy of Neurology

Despite continuous buffering, severe acidotic periods recurred. Gradually, a developmental delay, hypertonicity, and occasionally seizures occurred (signs of CNS involvement).

Because of suspicion for a mitochondrial disorder, a surgical muscle biopsy of the quadriceps was performed at age 29 days. During this time, blood lactate was 230 mg/dL and pyruvate was 3.52 mg/dL. Multivitamin therapy was started thereafter. A biopsy of the skin was taken at age 42 days. When the child was 58 days old, his condition suddenly worsened and he died from respiratory and cardiac arrest. Autopsy was not allowed.

Methods. *Histologic and electron microscopic analysis.* Light microscopy, histologic stains, and electron microscopy of the muscle biopsy were done according to standard procedures.

Biochemical analysis of muscle tissue. The oxidation rates of radiolabeled substrates (pyruvate, malate, and succinate), the ATP + creatine phosphate (CrP) production rates from pyruvate and succinate, and the mitochondrial enzyme activities were measured in 600 *g* supernatant of muscle homogenates as described previously.[8] Control specimens were considered those patients, ages 4 to 56 years, in which a mitochondrial defect had been excluded by substrate oxidation rates and individual enzyme measurements comparable with persons having restorative surgery. Complex III activity was measured using decylubiquinol and horse heart cytochrome *c* (both Sigma) as substrates according to Zheng et al.[9] Tween 20 (0.04% v/v) was added to the assay mixture to reduce the nonenzymic reaction. All biochemical values are expressed per mU citrate synthase (CS) to correct for mitochondrial recovery in the 600 *g* supernatant of muscle or in the mitochondria-enriched fraction of fibroblasts (see below).

Fibroblast studies. Human skin fibroblasts were grown in M199 (GIBCO) medium supplemented with 20% (v/v) fetal calf serum. Control specimens were obtained from healthy volunteers. Enzyme activities were measured in mitochondria-enriched fractions, which were prepared as described previously[10] with the following modifications. Approximately 20×10^6 cells were homogenized in 10 mM Tris · HCl (pH 7.6), thereafter adjusted to 0.25 M sucrose and subsequently differentially centrifuged (600 *g* and 14,000 *g*). The formation of lactate and pyruvate from glucose was determined in monolayer grown fibroblasts as described,[11] except that fibroblasts were cultured in M199 medium.

Two-dimensional electrophoresis. The amounts of assembled OXPHOS enzymes in muscle homogenate (20 mg) or frozen fibroblasts (4×10^6 cells) were quantitated by two-dimensional polyacrylamide gel electrophoresis (PAGE) (blue native/Tricine-SDS-PAGE) and subsequent densitometric analysis of Coomassie stained gels.[6]

Mitochondrial protein synthesis. Mitochondrial translation products of fibroblasts from the patient and two control subjects were labeled in near confluent six-well plates (diameter 1 cm) for 2 hours with [^{35}S]methionine (0.4 mCi/mL; 1,200 Ci/mmol) in the presence of emetine, an inhibitor of cytoplasmic protein synthesis, at 100 μg/mL.[12] After the labeling, the cells were washed twice with phosphate-buffered saline (pH 7.4) and detached by treatment with trypsin. Cells were lysed in 10 mM Tris · HCl (pH 7.4) with 0.1% (w/v) SDS. Equal amounts of cell lysates (20 μg per lane) were analyzed on 16.5% minislab gels[13] and prepared for fluorography.[14]

MtDNA analysis. MtDNA was analyzed in total DNA isolated from muscle as reported previously.[15] The mtDNA content in muscle tissue was quantitated by Southern blotting analysis using probes for the total mtDNA and the nuclear 18S rDNA gene. Control specimens were obtained from patients aged 4 to 56 years.

Results. *Histochemistry and electron microscopy.* Morphologic examination of the patients skeletal muscle revealed no ragged red fibers, but the staining for succinate dehydrogenase (SDH) showed a few large fibers with exceptionally high activity (figure 1, A and B). COX activity was absent in all muscle fibers but was present in smooth muscle cells of arterioles (figure 1, C and D). There was no glycogen or lipid accumulation. Electron microscopy revealed no structural abnormalities of the mitochondria.

Biochemical studies. Biochemical investigation in fresh skeletal muscle 600 *g* supernatant revealed that oxidation rates and ATP + CrP production rates with pyruvate, malate, and succinate as substrates were all significantly diminished ($p < 0.05$; table 1). Complex IV activity was most severely decreased (11% of the mean of control subjects; $p < 0.05$). The activities of NADH:Q_1 oxidoreductase (complex I) was decreased 24% of the mean of control subjects and NADH:O_2 oxidoreductase (complexes I + III + IV) were also decreased 27% of the mean of control subjects. Complex III and other enzyme activities were nearly normal (see table 1).

In the patient's fibroblasts, on the contrary, complex IV activity was in the normal range, both in whole cell homogenate and in the mitochondria enriched fraction (table 2). Here, only complex I activity was significantly decreased (39% of the mean of control subjects; $p < 0.05$). An increased lactate-pyruvate ratio after glucose conversion in these cells (42, normal <25) pointed also toward a respiratory chain defect.

Two-dimensional electrophoresis. Analysis of muscle homogenate of the patient showed that both complex I and IV were nearly absent (figure 2). Complex I could not be detected, even by more sensitive silver staining of the gels. Densitometric analysis of Coomassie stained gels revealed that the amount of correctly assembled complex IV was decreased (23% of the mean control subject concentration). Complex I was below the detection limit (i.e., less than 20% of the mean control subject concentration). Complex III and V were present in normal amounts, whereas the complex II amount (visible after silver staining, results not shown) was slightly increased. In fibroblasts of the patient, normal amounts of assembled complexes II, III, IV, and V were detected (results not shown). Complex I is very difficult to detect in fibroblasts, even in control subjects.

Mitochondrial protein synthesis. Metabolic labeling of the patient fibroblasts revealed that all detectable mitochondrial translation products were present in amounts equal to two control subjects (figure 3).

MtDNA analysis. Investigation of mtDNA in the patients muscle revealed no mtDNA depletion, large deletions, or point mutations, which are frequently associated with mitochondrial encephalomyopathy, lactic acidosis, and stroke-like episodes (MELAS, position 3243); myoclonic epilepsy and ragged red fiber disease (position

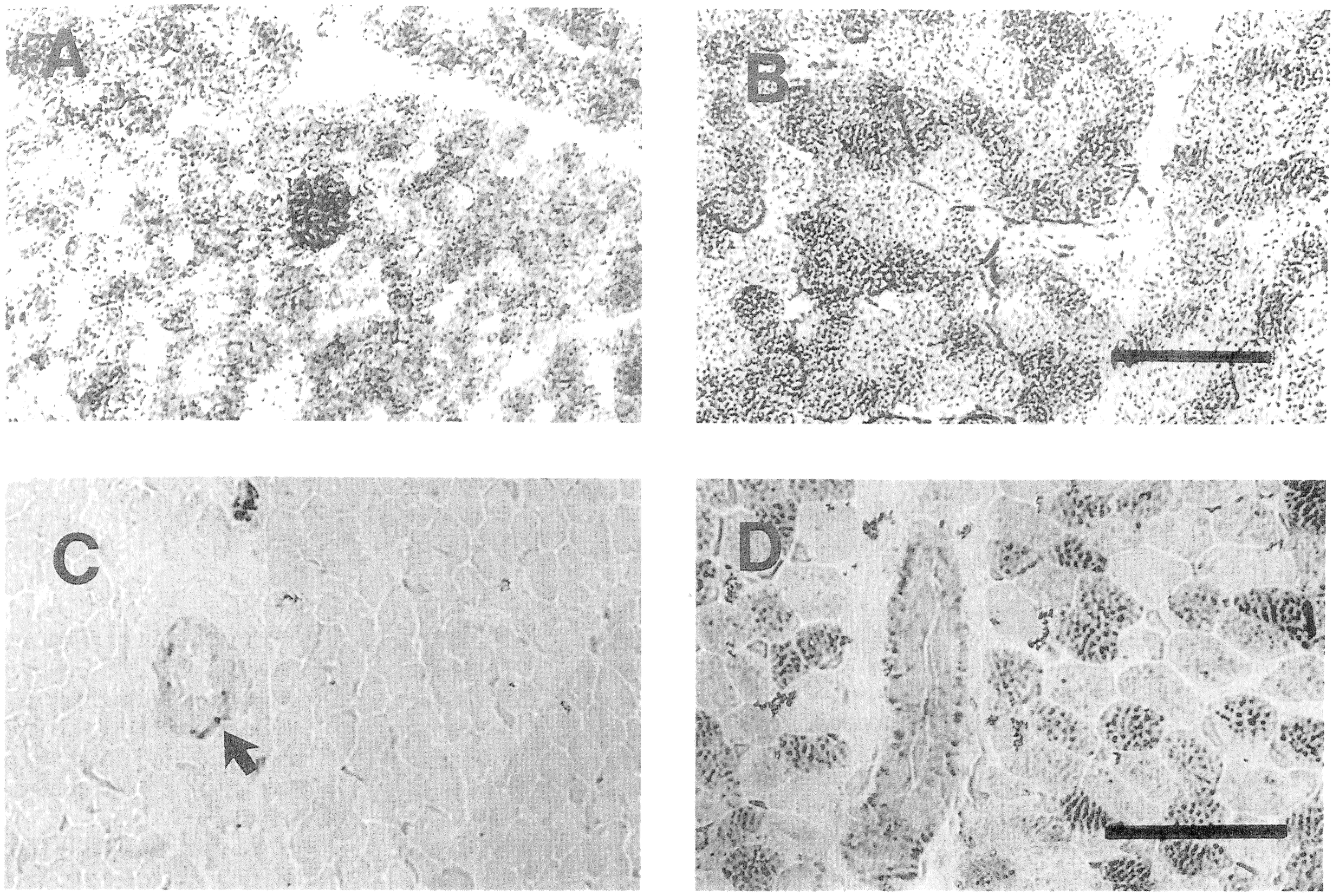

Figure 1. Skeletal muscle sections of the patient (A and C) and an age-matched control subject (B and D) were stained for SDH activity (A and B) and COX activity (C and D). Note the exceptionally high SDH activity in one fiber in A and the complete lack of COX activity in all muscle fibers in C. Smooth muscle cells of arterioles have normal COX activity in C (arrow) and D (the arteriole is longitudinally cut). Bars represent 50 μm.

8344); and neurogenic weakness, ataxia, and retinitis pigmentosa (position 8993).[7]

Discussion. Our patient had a lethal infantile mitochondrial disease (LIMD)[16] with lactic acidosis dominating the clinical presentation. Involvement of CNS pathology became apparent because of developmental delay, hypertonicity, an increased lactate level in CSF, and the occurrence of seizures. Other organs appeared normal.

Extensive biochemical analysis revealed the presence of a severe deficiency of both complex I and IV in skeletal muscle tissue but only of complex I in cultured skin fibroblasts. Other enzyme activities were not significantly decreased. These findings were confirmed by histochemical analysis of COX in muscle sections and by two-dimensional native SDS electrophoresis of all five OXPHOS enzymes in both muscle and fibroblasts.

Age differences between the patient (1 month at the time of muscle biopsy) and the control subjects (range 4 to 56 years, n = 28) are not relevant because the enzyme activities are normalized for CS activity.[17]

There are reports of two similar cases of LIMD with a combined deficiency of complex I and IV in muscle.[18,19] Both patients suffered from muscular hypotonia and tachypnoea but not encephalopathy. The first patient died at 4 months old, and the combined deficiency was found in skeletal muscle, heart, and liver, but no deficiency was found in kidney and brain.[18] Fibroblasts were not investigated. The authors postulated a nuclear DNA mutation in a developmental stage-specific and tissue-specific OXPHOS gene.[18] The second patient died at the age of 53 days because of respiratory failure with lactic acidosis and had a combined defect in complexes I and IV in skeletal muscle mitochondria.[19] We analyzed the respiratory chain enzymes in cultured fibroblasts of the latter patient and found no defect in complex I or IV (H.A.C.M.B., unpublished results). Both reported cases[18,19] showed ragged red fibers in their muscle, whereas these were lacking in our patient. However, the excessive staining for SDH in some fibers could point toward the development of ragged red fibers in our patient. Thus, there are many clinical and biochemical similarities between the two reported cases and the one presented here. By contrast, the two reported cases[18,19] had no apparent CNS involve-

Table 1 Biochemical measurements in fresh skeletal muscle

	Patients	(%)*	Control subjects†	N
Oxidation rate (nmol/hr/mU CS)				
[1-^{14}C]Pyruvate + malate	0.60	(11)	5.52 ± 0.99 (3.61–7.48)	14
[U-^{14}C]Malate + pyruvate + malonate	1.16	(16)	7.18 ± 1.28 (4.68–9.62)	20
ATP + CrP production rate (nmol/hr/mU CS)				
Pyruvate + malate	5.8	(9)	63.9 ± 10.1 (42.1–81.2)	16
Succinate + acetylcarnitine	5.3	(40)	13.1 ± 3.7 (7.2–18.4)	13
Activity (mU/mU CS)				
NADH:Q_1 oxidoreductase	0.036	(24)	0.153 ± 0.061 (0.061–0.276)	21
Succinate:cytochrome *c* oxidoreductase	0.41	(78)	0.56 ± 0.13 (0.31–0.84)	26
Decylubiquinol:cytochrome *c* oxidoreductase	2.78	(62)	4.52 ± 0.99 (2.85–6.61)	16
Cytochrome *c* oxidase	0.19	(11)	1.78 ± 0.61 (0.81–3.13)	28
NADH:O_2 oxidoreductase	0.12	(27)	0.44 ± 0.14 (0.28–0.84)	20
Pyruvate dehydrogenase‡	0.051	(63)	0.081 ± 0.024 (0.034–0.122)	25
CS (mU/mg protein)	67	(64)	104 ± 29 (65–162)	28

* Percent of mean of controls.
† Values are means ± SD, range in parentheses.
‡ In homogenate.
CS = citrate synthase.

Table 2 Enzyme activities in mitochondria-enriched fractions of fibroblasts*

	Patients	(%)†	Control subjects‡	N = 8
NADH:Q_1 oxidoreductase	0.05	(39)	0.13 ± 0.03	0.10–0.20
Succinate:cytochrome *c* oxidoreductase	0.23	(94)	0.24 ± 0.04	0.20–0.31
Decylubiquinol: cytochrome *c* oxidoreductase	1.87	(98)	1.90 ± 0.31	1.56–2.61
Cytochrome *c* oxidase	0.78	(92)	0.85 ± 0.13	0.68–1.05
Cytochrome *c* oxidase§	0.63	(91)	0.69 ± 0.11	0.54–0.89
CS (mU/mg protein)	203	(90)	226 ± 23	189–257

* Expressed in $mU \cdot mU^{-1}$ CS.
† Percent of mean of controls.
‡ Values are means ± SD.
§ In whole cell homogenate.

ment, and we found a normal complex I activity in fibroblasts of the second case.[19]

There are previous reports on heterogeneous tissue expression of OXPHOS defects in mitochondrial encephalomyopathies.[20-22] In some cases, this was associated with mtDNA depletion[21] or the MELAS 3243 mutation.[22] Both mutations were excluded in our patient. We examined fibroblasts of 10 other patients with combined complex I and IV defects in muscle tissue, including some previously reported,[5,20] and found only in one case a complex IV defect. All other fibroblasts did not show a respiratory chain enzyme defect. We demonstrated an isolated complex I deficiency also in fibroblasts of eight other patients, most of them having LIMD. All showed only a complex I deficiency in their muscle tissue (Bentlage, unpublished results). This illustrates the uniqueness of the case presented here.

Robinson et al.[23] reported a complex I deficiency in fibroblasts of four patients with the clinical picture of LIMD. Three patients had signs of CNS involvement such as hypertonia, seizures, and an abnormal EEG. Unfortunately, they did not mention the biochemical investigation of muscle tissue; thus, it is unclear whether these patients also had a combined complex I and IV defect in their muscle.

A unique Chinese hamster mutant lung cell line, Gal 32, also exhibits extremely low activities of both complex I and IV at moderately decreased activities of other respiratory chain complexes.[24] Simultaneous correction of this pleiotropic phenotype in a spontaneous revertant suggested the presence of a single nDNA mutation in Gal 32.[25] Mitochondrial protein synthesis revealed low amounts of mtDNA encoded complex I and IV subunits in this cell line, whereas the amounts of mitochondrial RNAs were increased but of correct size. Therefore, a mutation altering mitochondrial tRNA structure or base modification was assumed.[26] However, our patient had normal biosynthesis of all mitochondrial translation products in his fibroblasts, despite the reduced complex I activity. Thus, the phenotype of our patient probably arose from a different mutation.

In humans, there are tissue-specific isoforms of subunits VIa[27] and VIIa[28] of complex IV, a heart (H) and liver (L) form. In human heart, there are equal amounts of H- and L-forms, whereas in skeletal muscle there is mainly the H-form.[27-30] The L-form is exclusively present in liver, brain, kidney, smooth muscle,[30] and in cultured fibroblasts[31] and myoblasts.[32] During myogenesis[32] and during fetal development,[33] both subunits switch from L-type to H-type in human heart and skeletal muscle. Complex I possibly also has isoforms,[34,35] but there are no data at the molecular level yet. A mutation in one of the H-type subunit isoforms of COX would account for the normal fetal development (L-form) and the heterogeneous tissue expression of the complex IV defect in the presented patient, that is, normal activity in

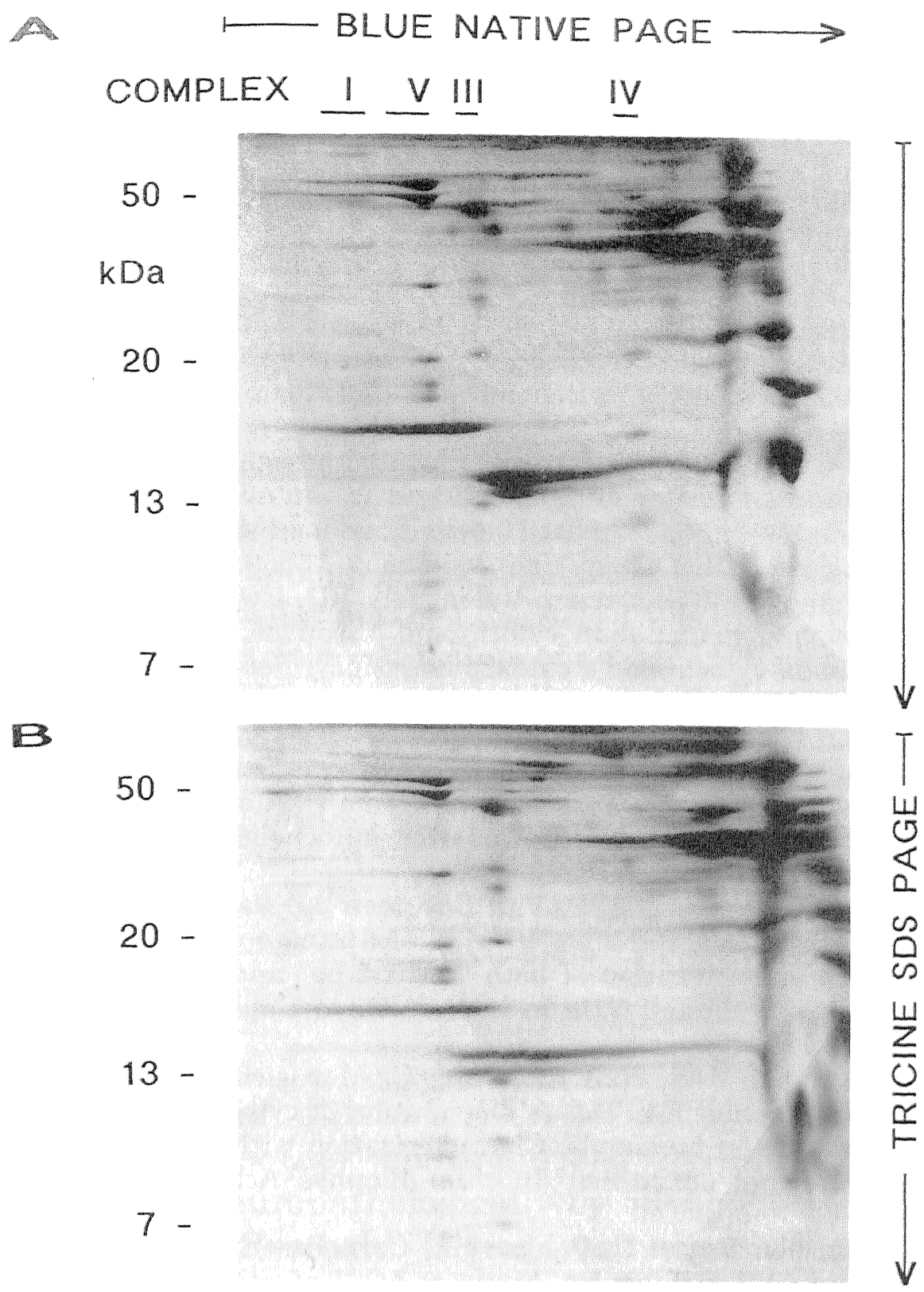

Figure 2. Two-dimensional electrophoresis of OXPHOS complexes in muscle. Twenty-milligram quadriceps muscle from a control subject (A) and the patient (B) were processed for the first dimension (blue native PAGE, horizontal direction). For the second dimension, tricine-SDS-PAGE, 16.5% acrylamide gels were used (vertical direction). The complexes were identified after Coomassie staining by their characteristic polypeptide pattern and quantified by densitometry. Note the complete absence of complex I and near complete absence of complex IV in B.

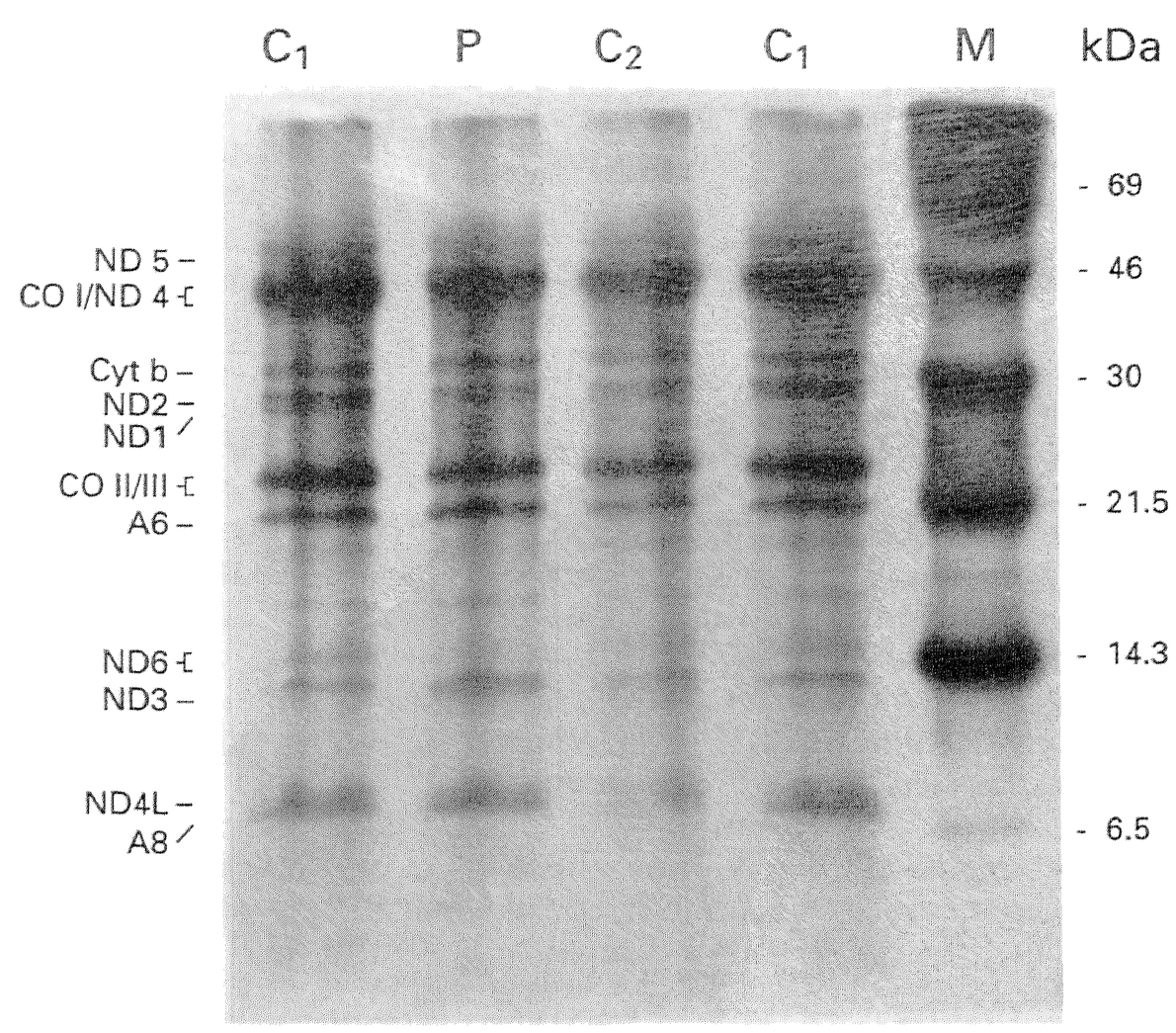

Figure 3. Metabolic labeling of mitochondrial translation products in fibroblasts. Cells of the patient (lane P) and two control subjects (lanes C_1 and C_2) were labeled for 2 hours with [^{35}S]methionine in the presence of emetine. Whole cell lysates were analyzed on a 16.5% tricine-SDS minigel, followed by fluorography. The dried gel was exposed for 4 days. On the right, the migration positions of molecular weight marker proteins (M) are indicated. The 13 subunits encoded in the mtDNA are indicated on the left.

arterioles (mainly smooth muscle) and fibroblasts (both L-form) and a deficiency in skeletal muscle (H-form). However, it does not explain the complex I defect in skeletal muscle and fibroblasts of the patient. A nuclear DNA mutation in a communal gene controlling both the expression or assembly of complex I and of the H-type isoenzyme of complex IV could explain the phenotype in our patient. Analysis of *pet* mutants in yeast identified several of such genes.[36] A candidate gene could be the human homologue of the yeast gene *oxa1*,[37] which is essential for COX assembly in yeast. However, there is no complex I in yeast; thus, the involvement of *oxa1* in complex I expression remains to be established.

Alternatively, the pleiotropic defect and tissue heterogeneity can be explained by a point mutation in a mitochondrial tRNA and a different degree of heteroplasmy in muscle and fibroblasts, similar to patients with the 3243 MELAS mutation.[6,22] Thus, the mutation must be in a mitochondrial tRNA whose codon is used more often by subunits of complex I than of IV and less by subunits of complexes III and V. Fibroblasts and cybrids with near homoplasmic point mutations at position 3260[38] and 3243 of the $tRNA^{Leu(UUR)}$ gene (Bentlage and Attardi, unpublished results) can also exhibit a normal mitochondrial protein synthesis as is the case in our patients fibroblasts.

We are presently developing techniques to test both hypotheses in muscle tissue or fibroblasts of the presented case.

Acknowledgments

We thank Dr. B. van Oost (Department of Human Genetics) for the mtDNA analysis, Dr. W. Ruitenbeek (Department of Pediatrics) for critically reading the manuscript, Dr. F.J.M. Gabreëls (Department of Child Neurology) for advice, and Hoffman-La Roche, Basel, Switzerland for the gift of ubiquinone-1.

References

1. DiMauro A, Moreas CT. Mitochondrial encephalomyopathies. Arch Neurol 1993;50:1197–1208.
2. Anderson S, Bankier AT, Barrell BG, et al. Sequence and organization of the human mitochondrial genome. Nature 1981;290:457–465.
3. Morgan-Hughes JA, Schapira AHV, Cooper JM, Clark JB. Molecular defects of NADH-ubiquinone oxidoreductase (complex I) in mitochondrial diseases. J Bioenerg Biomembr 1988; 20:365–382.
4. DiMauro S, Lombes A, Nakase H, et al. Cytochrome *c* oxidase deficiency. Pediatr Res 1990;28:536–541.
5. Korenke GC, Bentlage HACM, Ruitenbeek W, et al. Isolated

and combined deficiencies of NADH dehydrogenase (complex I) in muscle tissue of children with mitochondrial myopathies. Eur J Pediatr 1990;150:104–107.
6. Bentlage H, de Coo R, ter Laak H, et al. Human diseases with defects in oxidative phosphorylation. I. Decreased amounts of assembled oxidative phosphorylation enzymes in mitochondrial encephalomyopathies. Eur J Biochem 1995;227:909–915.
7. Wallace DC. Mitochondrial DNA mutations in diseases of energy metabolism. J Bioenerg Biomembr 1994;26:241–250.
8. Fischer JC, Ruitenbeek W, Gabreëls FJM, et al. Mitochondrial encephalomyopathy: the first case with an established defect at the level of coenzyme Q. Eur J Pediatr 1986;144:441–444.
9. Zheng X, Shoffner JM, Voljavec AS, Wallace DC. Evaluation of procedures for assaying phosphorylation enzyme activities in mitochondrial myopathy muscle biopsies. Biochim Biophys Acta 1990;1019:1–10.
10. Attardi B, Cravioto B, Attardi G. Membrane-bound ribosomes in HeLa cells. I. Their proportion to total cell ribosomes and their association with messenger RNA. J Mol Biol 1969;44:47–70.
11. Wijburg FA, Feller N, Ruitenbeek W, et al. Detection of respiratory chain dysfunction by measuring lactate and pyruvate production in cultured fibroblasts. J Inherited Metab Dis 1990;13:355–358.
12. Bentlage HACM, Janssen AJM, Chomyn A, et al. Multiple deficiencies of mitochondrial DNA- and nuclear-encoded subunits of respiratory NADH dehydrogenase detected with peptide- and subunit-specific antibodies in mitochondrial myopathies. Biochim Biophys Acta 1995;1234:63–73.
13. Schägger H, Von Jagow G. Tricine-sodium dodecyl sulfate-polyacrylamide gel electrophoresis for the separation of proteins in the range from 1 to 100 kDa. Anal Biochem 1987;166:368–379.
14. Bonner WM, Laskey RA. A film detection method for tritium-labelled proteins and nucleic acids in polyacrylamide gels. Eur J Biochem 1974;46:83–88.
15. De Vries DD, Ruitenbeek W, De Wijs IJ, Trijbels JMF, Van Oost BA. Enzymological versus DNA investigations in mitochondrial (encephalo-)myopathies. J Inherited Metab Dis 1993;16:534–537.
16. Shoffner JM, Wallace DC. Oxidation phosphorylation diseases. In: Scriver CR, Beaudet AL, Sly WS, Valle D, eds. The metabolic and molecular bases of inherited disease. 7th ed. New York: McGraw Hill, 1995:1535–1609.
17. Sperl W, Ruitenbeek W, Sengers RCA, et al. Enzyme activities of the mitochondrial energy generating system in skeletal muscle tissue of preterm and fullterm neonates. Ann Clin Biochem 1992;29:638–645.
18. Zheng X, Shoffner JM, Lott MT, et al. Evidence in a lethal infantile mitochondrial disease for a nuclear mutation affecting respiratory complexes I and IV. Neurology 1989;39:1203–1209.
19. Von Döbeln U, Wibom R, Åhlman H, et al. Fatal neonatal lactic acidosis with respiratory insufficiency due to complex I and IV deficiency. Acta Paediatr 1993;82:1079–1081.
20. Sperl W, Ruitenbeek W, Trijbels JMF, Korenke GC, Sengers RCA. Heterogeneous tissue expression of enzyme defects in mitochondrial myopathies. J Inherited Metab Dis 1990;13:359–362.
21. Telerman-Toppet N, Biarent D, Bouton J-M, et al. Fatal cytochrome *c* oxidase-deficient myopathy of infancy associated with mtDNA depletion. Differential involvement of skeletal muscle and cultured fibroblasts. J Inherited Metab Dis 1992;15:323–326.
22. De Vries DD, De Wijs I, Ruitenbeek W, et al. Extreme variability of clinical symptoms among sibs in a MELAS family correlated with heteroplasmy for the mitochondrial A3243G mutation. J Neurol Sci 1994;124:77–82.
23. Robinson BH, De Meirleir L, Glerum M, Sherwood G, Becker L. Clinical presentation of mitochondrial respiratory chain defects in NADH-coenzyme Q reductase and cytochrome oxidase: clues to pathogenesis of Leigh disease. J Pediatr 1987;110:216–222.
24. Malczewski RM, Whitfield CD. Respiration-defective Chinese hamster cell mutants containing low levels of NADH-ubiquinone reductase and cytochrome *c* oxidase. J Biol Chem 1982;257:8137–8142.
25. Malczewski RM, Whitfield CD. A novel mutation selectively decreases complex I and cytochrome *c* oxidase subunits in Chinese hamster mitochondria. J Biol Chem 1984;259:11103–11113.
26. Whitfield CD, Jefferson LM. Elevated mitochondrial RNA in a Chinese hamster mutant deficient in the mitochondrially encoded subunits of NADH dehydrogenase and cytochrome *c* oxidase. J Biol Chem 1990;265:18852–18859.
27. Kennaway NG, Carrero-Valenzuela RD, Ewart G, et al. Isoforms of mammalian cytochrome *c* oxidase: correlation with human cytochrome *c* oxidase deficiency. Pediatr Res 1990;28:529–535.
28. Van Beeumen JJ, Van Kuilenburg ABP, Van Bun S, Van den Bogert C, Tager JM, Muijsers AO. Demonstration of two isoforms of subunit VIIa of cytochrome *c* oxidase from human skeletal muscle. Implications for mitochondrial myopathies. FEBS Lett 1990;263:213–216.
29. Van Kuilenburg ABP, Van Beeumen JJ, Van der Meer NM, Muijsers AO. Subunits VIIa, b, c of human cytochrome *c* oxidase. Identification of both "heart-type" and "liver-type" isoforms of subunit VIIa in human heart. Eur J Biochem 1992;203:193–199.
30. Taanman J-W, Hall RE, Tang C, Marusich MF, Kennaway NG, Capaldi RA. Tissue distribution of cytochrome *c* oxidase isoforms in mammals. Characterization with monoclonal and polyclonal antibodies. Biochim Biophys Acta 1993;1225:95–100.
31. Van den Bogert C, Dekker HL, Cornelissen JC, Van Kuilenburg ABP, Bolhuis PA, Muijsers AO. Isoforms of cytochrome *c* oxidase in tissues and cell lines of the mouse. Biochim Biophys Acta 1992;1099:118–122.
32. Taanman J-W, Herzberg NH, De Vries H, Bolhuis PA, Van den Bogert C. Steady state transcript levels of cytochrome *c* oxidase genes during human myogenesis indicate subunit switching of subunit VIa and coexpression of subunit VIIa isoforms. Biochim Biophys Acta 1992;1139:155–162.
33. Bonne G, Seibel P, Possekel S, Marsac C, Kadenbach B. Expression of human cytochrome *c* oxidase subunits during fetal development. Eur J Biochem 1993;217:1099–1107.
34. Clay VJ, Ragan CI. Evidence for the existence of tissue specific isoenzymes of mitochondrial NADH dehydrogenase. Biochem Biophys Res Commun 1988;157:1423–1428.
35. Whatmough NJ, Birch-Machin MA, Bindoff LA, et al. Tissue specific defect of complex I of the mitochondrial respiratory chain. Biochem Biophys Res Commun 1989;160:623–627.
36. Grivell LA. Nucleo-mitochondrial interactions in yeast mitochondrial biogenesis. Eur J Biochem 1989;182:477–493.
37. Bonnefoy N, Kermorgant M, Groudinsky O, Minet M, Slonimski PP, Dujardin G. Cloning of a human gene involved in cytochrome oxidase assembly by functional complementation of an *oxa1*⁻ mutation in *Saccharomyces cerevisiae*. Proc Natl Acad Sci USA 1994;91:11978–11982.
38. Mariotti C, Tiranti V, Carrara F, Dallapiccola B, DiDonato S, Zeviani M. Defective respiratory capacity and mitochondrial protein synthesis in transformant cybrids harboring the $tRNA^{Leu(UUR)}$ mutation associated with maternally inherited myopathy and cardiomyopathy. J Clin Invest 1994;93:1102–1107.