

## PDF hosted at the Radboud Repository of the Radboud University Nijmegen

The following full text is a publisher's version.

For additional information about this publication click this link.

<http://hdl.handle.net/2066/24023>

Please be advised that this information was generated on 2017-12-05 and may be subject to change.

# HISTOLOGICAL GRADE HETEROGENEITY IN MULTIFOCAL PROSTATE CANCER. BIOLOGICAL AND CLINICAL IMPLICATIONS

EMIEL TH. RUIJTER\*,†, CHRISTINA A. VAN DE KAA†, JACK A. SCHALKEN\*,°, FRANS M. DEBRUYNE\* AND DIRK J. RUITER†

*Departments of \*Urology and †Pathology, University Hospital Nijmegen, Nijmegen, The Netherlands; Departments of Pathology and Companion Animals°, Veterinarian Faculty, University of Utrecht, The Netherlands*

## SUMMARY

In order to understand the clinical and biological implications of prostate cancer multifocality and heterogeneity, we investigated their occurrence in relation to variables such as tumour volume, local invasion, and biopsy findings. In a series of 61 completely sectioned whole-mount radical prostatectomy specimens with clinical stage T2 prostate cancer, we mapped histological grade heterogeneity and tumour multifocality. We also evaluated 55 prostate biopsy cases to assess the accuracy of pre-operative grading. Among all of the prostates, only 28 per cent had a single tumour and in 16 per cent one histological grade of cancer was evident. Extracapsular invasion was not restricted to the largest tumour in each case, but also occurred in tumours of relatively small volume and low histological grade. Variability of histological grade was directly proportional to tumour volume. Both grade heterogeneity and tumour multifocality of the prostatectomy specimen showed no significant relationship to the grade accuracy of biopsies. Biopsy grading error proved greatest among small, well-differentiated tumours. Whole-mount sectioning of prostatectomy specimens in patients with clinically localized adenocarcinoma demonstrates that grade heterogeneity is most closely related to tumour volume; that the largest (index) tumour lesion may not be representative of the pathological stage; and that grading error in prostate needle biopsies can be only partly explained by grade heterogeneity or tumour multifocality.

**KEY WORDS**—prostate carcinoma; prostatectomy; prostate biopsy; multiple cancers; cancer volume; grade

## INTRODUCTION

Carcinoma of the prostate continues to increase in incidence and prevalence, an increase paralleled by staging and management controversies. This has encouraged basic tumour research to identify possible aetiological factors and potential prognostic markers, since these could have direct clinical implications. Considerably less attention has been paid to the morphological diversity of prostate cancer.

Morphologically, prostate carcinomas are particularly intriguing regarding their propensity to display multiple histological patterns within a single tumour. Although many studies have commented on the presence of grade heterogeneity, the nature and magnitude of this phenomenon have not been precisely documented.<sup>1,2</sup> Most studies analysing heterogeneity of histological grade suffer from examining only the largest lesion or 'index tumour' in each case.<sup>3,4</sup> To investigate the frequency and extent of grade heterogeneity at the inception of prostate cancer, all tumours in a given case should be included in the analysis. The presence of multiple, independent foci of prostatic adenocarcinoma within the same gland is a common finding.<sup>4–6</sup> Studies concentrating on tumour multifocality, however, have not discussed grade heterogeneity in detail.<sup>5</sup> Exactly how tumour multifocality and heterogeneity of histological grade are interrelated is also unclear. Detailed information about their existence and extent could probably influence our thinking about

the natural history of prostatic cancer and could show their potential contributions to diagnostic and prognostic accuracy.<sup>6</sup> Heterogeneity of histological grade, for example, could be important for an individual's prognosis, since tumours that are heterogeneously composed of various grades theoretically have a less predictable clinical behaviour than tumours that are homogeneous in that respect. Moreover, the initial biopsy grade may not reflect that of the resultant prostate specimen, due to sampling error that could result from both grade heterogeneity and multifocality.

In order to gain more insight into the tumour biological and clinical implications of grade heterogeneity and multifocality, a series of 61 radical prostatectomy specimens and most of their respective pre-operative biopsies were analysed. We examined the number of tumour lesions and histological grades. These data were correlated with tumour volume, Gleason score, and capsule penetration.

## PATIENTS AND METHODS

Sixty-one prostatectomy specimens were selected from 77 patients with clinically localized prostate cancer who had been seen during the period of June 1992–December 1994. Patients who had received pre-operative hormone treatment were excluded from this study ( $n=16$ ). All prostatectomies were performed on patients in whom lymph node metastases had not been identified by frozen section diagnosis during the operation. The mean patient age was 64 years (range 49–73 years).

Immediately after surgical resection, prostate specimens were fixed overnight in a solution of 10 per cent

Addressee for correspondence: Jack A. Schalken, Department of Urology, University Hospital Nijmegen, P.O. Box 9101, 6500 HB, Nijmegen, The Netherlands.

Table I—Results of tumour multifocality

Tumours per patient	No. of patients (%)	Mean tumour volume (cm <sup>3</sup> )	No. of tumours with penetration (%)	Mean Gleason score per tumour
1	17 (28%)	2.70	8 (47%)	6.9
2	18 (30%)	1.20	12 (33%)	6.0
3	13 (21%)	0.68	6 (15%)	5.4
4	7 (11%)	0.43	6 (21%)	5.6
5	2 (3%)	0.18	0 (0%)	4.7
6	3 (5%)	0.16	2 (11%)	6.1
7	1 (2%)	0.09	0 (0%)	5.1
Totals	61	0.85	34 (22%)	5.7

neutral-buffered formalin at room temperature. After surface marking with dye, the entire prostate specimen was cut into serial transverse 4 mm thick slices. Following histological processing, 4- $\mu$ m paraffin tissue sections were stained with haematoxylin and eosin.

By careful histological examination, all areas representing adenocarcinoma were outlined on the slides of each specimen and retraced onto a diagrammatic macroscopical representation of all slices in a serial order. From these tumour maps, topographic relationships between multifocal tumours were evaluated. Multifocality of carcinoma was defined as a minimum separation of 4 mm between two malignant foci. The volumes of all independent carcinomas were calculated as the sum of surface areas for a given carcinoma multiplied by the slice thickness in which they were found. A tissue shrinkage correction factor of 10 per cent was used. Volumes were expressed in cubic centimetres (cm<sup>3</sup>). The index tumour for each case was defined as the single tumour of greatest volume. Satellite lesions were defined as tumours with a smaller volume than the index tumour in a given case with multifocal lesions. All tumours were histologically graded according to the Gleason system.<sup>7</sup> Capsule penetration was defined as the presence of malignant cells in the periprostatic fatty tissue.

To evaluate the predictive value of pre-operative tumour grade and volume in biopsy material, the biopsy and prostatectomy specimens were reviewed by the same observers (ETR, CAK). Biopsy material from 55 of the 61 cases had been obtained less than 3 months prior to prostatectomy by a transrectal (ultrasound-guided) prostate needle core biopsy (18 gauge). Four cases were excluded because the diagnosis had been made by a transurethral resection and two others could not be retraced from referring institutions. In the biopsies of each case, the Gleason grades and score were recorded. Tumour volume was estimated as the percentage of the total biopsy volume in 25 per cent increments.

Statistical analysis included the chi-square test for the comparison between two sample percentages and the comparison of a two-sample distribution by means of the Wilcoxon test for unpaired observations. A probability (*P*) values less than 5 per cent was considered as statistically significant.

## RESULTS

### *Tumour multifocality in prostatectomy specimens*

Table I reveals that prostatic carcinoma is most often a multifocal disease. In 61 prostates, we identified 155 separate lesions of adenocarcinoma (mean 2.5 per patient). Only 17 of the 61 prostates (28 per cent) contained a single tumour. There was a clear association between increasing numbers of tumours per case and smaller tumour volumes. The mean tumour volume was 2.7 cm<sup>3</sup> in cases with a single tumour, but this decreased to less than 0.25 cm<sup>3</sup> in cases with more than four tumours.

Separate tumours observed in multifocal disease had a lower Gleason score (mean score 5.7), had less grade heterogeneity (mean 1.5 different grades per tumour), and were smaller (mean 0.6 cm<sup>3</sup>) compared with prostates containing a single tumour (mean score 6.9, 2.1 different grades per tumour, volume 2.7 cm<sup>3</sup>). For tumour volume and grade variety, these differences were statistically significant (*P*<0.01). For the entire specimen, however, the Gleason score, grade heterogeneity, and tumour volume in prostates with a single tumour or multifocal tumours were essentially similar (*P*=NS).

In 82 per cent of the prostates, the index tumour had a similar or higher Gleason sum compared with the satellite tumours in the same specimen. In the remaining 11 prostates, however, the satellite tumours had a higher Gleason sum, four of which had a difference of more than 2 in the sum.

### *Grade heterogeneity in prostatectomy specimens*

The degree of grade heterogeneity in individual tumours is shown in Table II. In only ten prostates (16 per cent) did cancers consist of a single Gleason grade. Considering separate tumours, 90 had a single grade (58 per cent). Almost invariably, these tumours were small (mean volume 0.15 cm<sup>3</sup>), low- to intermediate-grade lesions. Only six high-grade tumours exclusively composed of one histological growth pattern were found (mean volume 0.16 cm<sup>3</sup>).

Figure 1 shows the relationship between grade heterogeneity and tumour volume of separate lesions. From this figure, it is clear that the frequency and extent of

Table II—Results of tumour heterogeneity in prostatectomy specimens

Different histological grades	No. of tumours	Mean tumour volume (cm <sup>3</sup> )	No. of tumours with penetration (%)	Mean Gleason score per tumour
1	90	0.15	9 (10%)	5.5
2	43	1.24	9 (21%)	5.9
3	17	2.64	11 (65%)	6.9
4	5	4.36	5 (100%)	7.8
Totals	155	0.85	34 (22%)	5.7

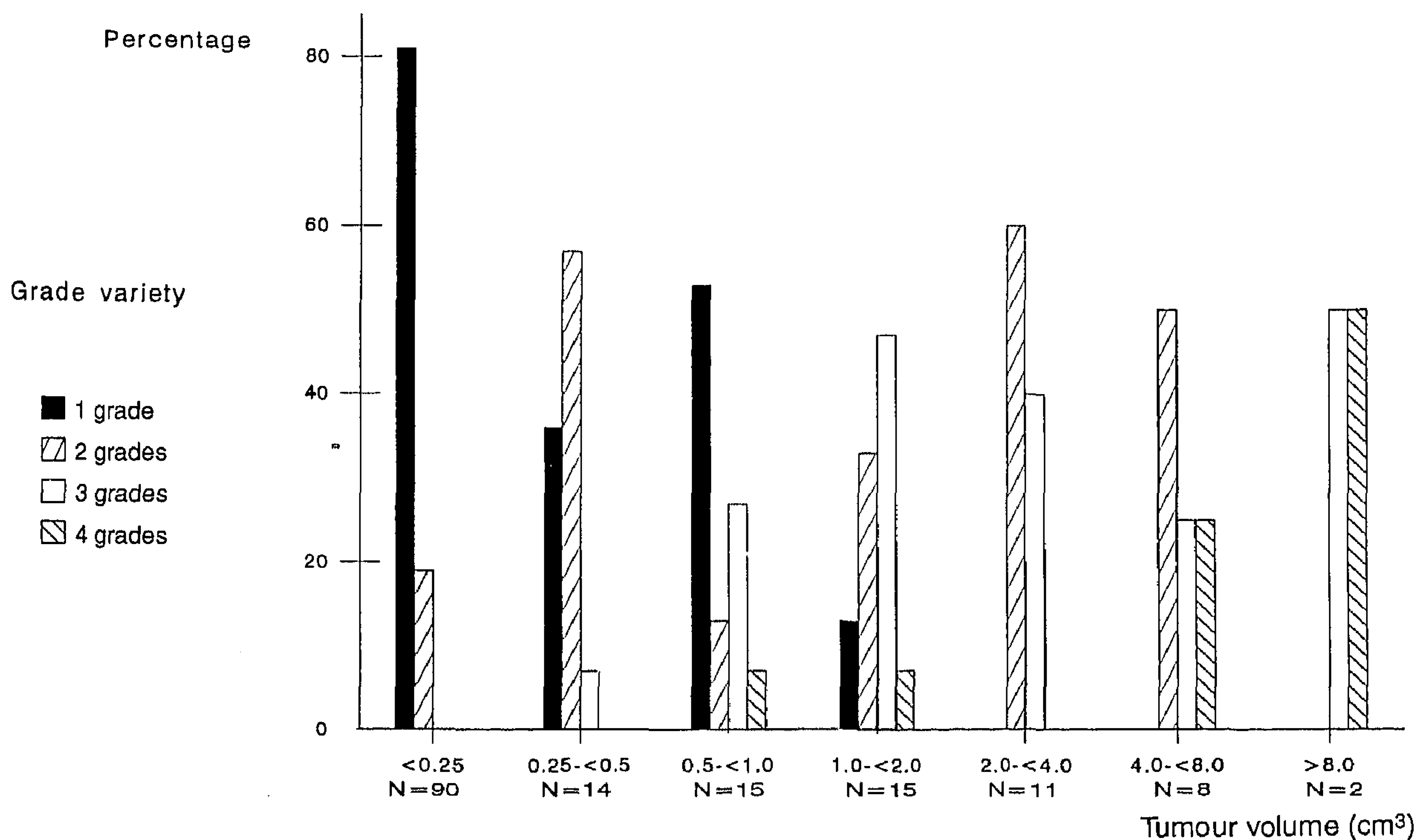


Fig. 1—Histological grade variety of tumours, grouped by tumour volume

grade heterogeneity increase as tumours attain larger volumes. Tumours larger than 2.0 cm<sup>3</sup> in volume, for example, were always composed of different histological grades. Of particular interest, however, is the group of tumours with volumes less than 1.0 cm<sup>3</sup>. It is apparent that considerable heterogeneity was present among these tumours.

#### Extracapsular growth

The total number of 34 penetrating tumours had a larger volume ( $P < 0.01$ ), a higher Gleason score ( $P < 0.01$ ), and more heterogeneity of grade ( $P < 0.01$ ) compared with 121 non-penetrating tumours.

In general, we could demonstrate a clear correlation between tumour volume or grade and frequency of capsular penetration. Nearly all low- to intermediate-grade tumours and tumours with small volumes were confined within the prostate capsule (Table III).

Among the 119 tumours of less than 1.0 cm<sup>3</sup> in volume, however, 13 displayed penetration (11 per cent). In addition, 14 of the 120 low- to intermediate-grade tumours (12 per cent) penetrated the capsule. Notably, the combination of a relatively low tumour volume (<1.0 cm<sup>3</sup>), low histological grade (score <7), and capsule penetration was present in seven tumours.

In multifocal disease, 19 of the 26 penetrating tumours were the index tumour of the specimen. In the remaining seven satellite tumours, two showed extracapsular growth, while the index tumour did not. For these two cases, the features of the satellite tumours determined the pathological stage of the prostatectomy specimen.

#### Prostate biopsies

In 71 per cent of the cases, only a small portion of the biopsy was involved (less than 25 per cent of the biopsy

Table III—Capsular penetration by 155 tumours stratified by histological grade and tumour volume

	Gleason score			Tumour volume (cm <sup>3</sup> )			
	2-4	5-6	7-10	<0.25	0.25-1.0	1.0-2.0	>2.0
Penetration No./total (%)	0/37 (0%)	14/83 (17%)	20/35 (57%)	5/90 (6%)	8/29 (28%)	7/15 (47%)	13/21 (62%)

volume). For 26-50 per cent and 51-100 per cent tumour involvement, the figures were 18 and 11 per cent, respectively. The extent of tumour in biopsies and in prostatectomy specimens of the same patients seemed to correspond. Less than 50 per cent biopsy involvement corresponded to smaller tumour volumes (<2 cm<sup>3</sup>) in the prostatectomy specimens (71 per cent). Similarly, biopsies that contained more than 50 per cent of cancer corresponded to larger tumour volumes (>2 cm<sup>3</sup>) in the prostatectomy specimen (83 per cent). Due to the small sample size, however, these results could not be statistically analysed.

For the Gleason score, there was concordance between the biopsy and the prostatectomy in 50 per cent of the cases. The biopsy grade underestimated the prostatectomy grade in 40 per cent of the cases and overestimated it in 10 per cent of the cases. A correlation within  $\pm 1$  unit was present in 80 per cent, and a correlation within  $\pm 2$  units in 91 per cent of the cases. Biopsy specimens with a well-differentiated cancer (Gleason score 2-4) appeared to have a higher level of grading error than those with moderately and poorly differentiated cancers. For example, there was a grading error in 75 per cent of the biopsies with well-differentiated cancer, but in only 50 per cent in moderately and poorly differentiated cancers. Besides the role of the tumour grade, tumour involvement in biopsies was also related to grade accuracy. Lesser involvement of biopsies (<25 per cent) corresponded to the lowest level of concordance between prostatectomy and biopsy Gleason score (44 per cent). For biopsies with more than 25 per cent tumour involvement, this figure was 63 per cent.

No difference was observed in biopsy grade accuracy between prostates with a single focus or with multifocal disease (50 and 51 per cent accuracy level, respectively;  $P > 0.05$ ). In addition, prostates containing a single histological grade or grade heterogeneity showed almost similar figures for the grade accuracy of biopsy cases (44 and 50 per cent, respectively;  $P > 0.05$ ). Also, as the number of tumours or grades per prostate increased, the grade accuracy of prostate biopsies reflected no significant change.

## DISCUSSION

This detailed morphological analysis reveals several interesting findings concerning the biological progression of prostatic adenocarcinoma. Based on the work of McNeal *et al.*,<sup>2</sup> tumour volume, grade, and aggressive

phenotype are considered to be closely related. If cancers only acquire the capacity to penetrate through the prostate capsule or metastasize as a function of increasing volume, early small tumours might not be expected to behave aggressively. For this reason, in most reports that have described the morphological appearances of prostate cancer, the largest tumour in the specimen has been selected as the index tumour, while the possible role of additional smaller tumours had not been considered.<sup>2</sup> Clearly, our results raise some doubt about the validity of this approach. A quarter of the penetrating tumours in multifocal disease, for example, were not index tumours. More importantly, two of these tumours extended beyond the prostate capsule, influencing the pathological stage, while the largest tumour in the same specimen remained confined to the organ. Furthermore, 18 per cent of the smaller satellite tumours were morphologically more malignant, according to the Gleason score, than the index tumours in the same specimens. Finally, extracapsular invasion also occurred in tumours of relatively low histological grade, or low tumour volume. It is likely, therefore, that the ability of a tumour to become locally invasive is defined not only by its aggressive potential, but also by the topographical relationship between the tumour and the capsule. Tumours that originate near the prostate capsule may have a topographical advantage in becoming locally invasive. From these data we conclude that it is erroneous to assign all small carcinomas and all low Gleason score tumours to a biologically 'latent' group; the relevant clinical and tumour-biological information can be obtained only by evaluating all of the tumours in a given case. This is facilitated by the whole-mount approach, but at least requires submission of the entire prostatectomy specimen.

The biological basis for the multifocality and heterogeneity of prostatic cancer remains controversial. It is plausible that morphological heterogeneity is the result of tumour multifocality. With the passage of time, tumour volume will increase. This inevitably brings multifocal processes of varying grades closer together, finally culminating in the fusion of lesions. As a consequence, the number of independent tumour foci would be reduced and grade heterogeneity and tumour volume increased. We found indirect evidence for this hypothesis. In our study, individual tumours from multifocal disease displayed only minimal grade heterogeneity, but the overall grade heterogeneity of all tumours together was comparable to that found in prostates with single tumours. Direct evidence that growth and fusion are important events for the evolution of grade

heterogeneity may be obtained by examining the topographical distribution of grades within tumours.<sup>3,6</sup> Alternatively, cases with heterogeneity of grade may reflect the evolution of poorly differentiated from more well-differentiated areas.

Since tumours consisting of both low- and high-grade areas were also found among the smallest tumour volumes, we assume that the emergence of poorly differentiated subpopulations can occur early in the progression of prostate cancer. The end result of tumour progression and/or fusion of multiple tumours of varying grades is grade heterogeneity. Once overgrowth of one component arising over another has occurred, the individual contributions of progression versus multifocality are almost impossible to determine.<sup>3,6</sup> One approach to circumvent this problem is a longitudinal analysis of the progression of prostate cancer by the use of sequential biopsies, but these cannot take multicentricity into account.<sup>6</sup> In addition, this study showed that biopsies may not always sample the critical area of a given prostatic carcinoma.

Finally, the availability of both prostatectomy specimens and prostate biopsies made it possible to study the prediction of histological grade using pre-operative biopsies. It is important for the initial biopsy grade to be representative of the prostatic malignancy when appropriate clinical decisions are to be made. Of the 55 prostates in our series, 40 per cent of cases showed a higher grade in the whole-mount specimen. This is in agreement with previously reported results.<sup>8</sup> For overestimation of biopsy grade, previously reported figures differ from 4 to 32 per cent; 10 per cent in this study.<sup>8</sup> Grading differences between prostatic biopsies and prostatectomy specimens have been suggested to be the result of grade heterogeneity<sup>9,10</sup> and tumour multifocality.<sup>6,10</sup> Neither concept, however, has ever been subjected to detailed study. From the results presented here, neither grade heterogeneity nor tumour multifocality in prostatectomy specimens significantly influenced the grade accuracy of biopsy cases. We have deduced that discrepancies between biopsy grade and grade obtained from the radical prostatectomy specimen can probably be explained not only by sampling error, but also by difficulties in appreciating either the tumour grade or its infiltrative nature in the biopsy. The latter was especially difficult with small tumours and with the lower Gleason scores, in which greater grade error was found. For this reason, underestimation of biopsy grade was found more frequently than overestimation.

In conclusion, submission of entire radical prostatectomy specimens in patients with clinically localized adenocarcinoma demonstrates that grade heterogeneity is most closely related to tumour volume; that the largest (index) tumour lesion may not be representative of the pathological stage; and that grading error in prostate needle biopsies is only partly explained by grade heterogeneity or tumour multifocality. This detailed analysis of multifocality and heterogeneity shows that prostate carcinoma is a complex disease. It is unclear, therefore, whether important questions such as the natural history of prostate cancer are solved within the limitations of a morphological analysis. A more sophisticated approach to the analysis of how different tumour grades or locations of tumours in the same prostate are inter-related may be made possible by determination of the molecular and genetic characteristics of separate tumours.

With current technological improvements, it is our hope that such data can be reliably obtained in the near future.

#### ACKNOWLEDGEMENT

We gratefully acknowledge Professor G. J. Miller, pathologist, for providing valuable comments during manuscript preparation.

#### REFERENCES

1. Mostofi FK, Davis CJ, Sesterhenn IA. Pathology of carcinoma of the prostate. *Cancer* 1991; 70(Suppl 1): 235-253.
2. McNeal JE, Villers AA, Redwine EA, Freiha FS, Stamey TA. Histological differentiation, cancer volume and pelvic lymph node metastasis in adenocarcinoma of the prostate. *Cancer* 1990; 66: 1225-1233.
3. Aihara M, Wheeler TM, Ohori M, Scardino PT. Heterogeneity of prostate cancer in radical prostatectomy specimens. *Urology* 1994; 43: 60-66.
4. Greene DR, Wheeler TM. Clinical relevance of the individual prostate cancer focus. *Cancer Invest* 1994; 12: 425-437.
5. Villers A, McNeal JE, Freiha FS, Stamey TA. Multiple cancers in the prostate. Morphologic features of clinically recognized versus incidental tumours. *Cancer* 1992; 70: 2313-2318.
6. Miller GJ, Cygan JM. Morphology of prostate cancer: the effects of multifocality on histologic grade, tumour volume and capsule penetration. *J Urol* 1994; 152: 1709-1713.
7. Gleason DF. Histologic grading and clinical staging of prostate carcinoma. In: Tannenbaum M, ed. *Urological Pathology: The Prostate*. Philadelphia: Lea & Febiger, 1971; 171-198.
8. Bostwick DG. Gleason grading of prostatic needle biopsies. Correlation with grade in 316 matched prostatectomies. *Am J Surg Pathol* 1994; 18: 796-803.
9. Mills SE, Fowler JE. Gleason histologic grading of prostate carcinoma. Correlations between biopsy and prostatectomy specimens. *Cancer* 1986; 57: 346-349.
10. Epstein JE, Steinberg GD. The significance of low-grade prostate cancer on needle biopsy. A radical prostatectomy study of tumour grade, volume and stage of the biopsied and multifocal tumour. *Cancer* 1990; 66: 1927-1932.