

PDF hosted at the Radboud Repository of the Radboud University Nijmegen

The following full text is a publisher's version.

For additional information about this publication click this link.

<http://hdl.handle.net/2066/23914>

Please be advised that this information was generated on 2017-12-05 and may be subject to change.

FOUNTAIN SYNDROME: FURTHER DELINEATION OF THE CLINICAL SYNDROME AND FOLLOW-UP DATA

by G.J.C.M. VAN BUGGENHOUT^{1,2}, C.M.A. VAN RAVENSWAAIJ-ARTS²,
W.O. RENIER³, M.P. VAN DE WIEL⁴, J.C.M. TROMMELEN⁴, E. PIJKELS¹,
B.C.J. HAMEL², J.P. FRYNS¹

Summary: *Fountain syndrome: Further delineation of the clinical syndrome and follow-up data:* We present five patients with the clinical diagnosis of Fountain's syndrome, an autosomal recessive entity with mental retardation, deafness, skeletal abnormalities and coarse face with full lips as cardinal features and review all cases reported so far. We report two new isolated cases, and present follow-up data on three previously reported patients. The clinical features of all these patients are presented to further delineate the clinical picture and the natural course of this rare syndrome. We propose that epilepsy, short stature, large head circumference, broad, plump hands and the remarkable behavior are important accessory findings of this syndrome. The clinical features of this syndrome become more evident with advancing age.

Key words: Autosomal recessive inheritance – Deafness – Fountain syndrome – Generalized seizures – Mental retardation – Skeletal abnormalities.

Résumé: *Le syndrome de Fountain: Caractérisations cliniques et étude longitudinale:* Nous présentons une observation concernant 5 patients avec diagnostic correspondant au syndrome de Fountain. Il s'agit d'une entité reconnaissant une hérédité de type autosomique récessive dont les caractéristiques sont les suivantes: retard mental, surdit , anomalies squelettiques, visage grossier avec l vres  paisses. Nous rapportons ici deux nouveaux cas isol s et une  tude longitudinale concernant 3 cas publi s ant rieurement. Les manifestations cliniques de tous ces patients permettent de d finir plus pr cis ment la pr sentation clinique et l' volution de ce syndrome rare. Nous proposons une symptomatologie suppl mentaire comprenant les manifestations suivantes:  pilepsie, petite taille, p rim tre cr nien augment , mains larges et potel es et comportement particulier. Les manifestations cliniques sont d'autant plus marqu es que l' ge est avanc .

Mots-cl s: Autosomique r cessive – Surdit  – Syndrome de Fountain – Convulsions – Retard mental – Anomalies squelettiques.

INTRODUCTION

Fountain (1) described in 1974 a family with four members with a specific clinical

picture including mental retardation, deafness, skin granulomata and bone abnormalities. Fryns *et al.* (2, 3) reported 3 moderate to severe mentally retarded males (2 brothers and 1 sporadic male patient) with congenital deafness due to an inner ear anomaly, facial plethorism and skeletal anomalies. We describe two new isolated patients and present follow up studies of the three patients described by Fryns *et al.* (3) to delineate the clinical picture and the natural course of this syndrome.

¹ Center for Human Genetics, University of Leuven, Belgium.

² Department of Human Genetics and;

³ Department of Child Neurology, University Hospital Nijmegen, The Netherlands.

⁴ Institution for mentally retarded patients, Huize Assisie, Udenhout, The Netherlands.

CASE REPORTS

Patient 1

The patient, (AA), now 50-years-old and institutionalized from the age of 10 years, is a moderately mentally retarded male. He was the first child of healthy, non-consanguineous parents. The second pregnancy ended in a stillborn girl. His only brother is healthy but has a severe perceptive hearing loss. Pregnancy was uneventful. He was born at term. Birth weight was 3250 g (25th centile). Psychomotor development was delayed. He could sit at the age of 3 years, walked at 4 years and developed speech at 5 years (Fig. 1a). At the age of 10, he weighed 26 kg (10th to 25th centile) with a height of 118 cm (7 cm < 3rd centile) and a head circumference of 52 cm (25th centile). Clinical investigation showed abdominal obesity, lumbosacral lordosis, a thick skin, an undescended right testis, hypotonia of the upper and lower extremities and a large, curved tongue. His total psychological score was 4 years 5 months. At the age of 19 years, severe vision loss due to high grade myopia was diagnosed and corrected with vision aids. When he was 27 years, he weighed 53 kg (1

kg < 10th centile) with a height of 158 cm (4 cm < 3rd centile) and a head circumference of 58 cm (97th centile). He had severe vision problems, high and small palate, absent right testis and weak motor development of both legs. Age 36, severe bilateral hearing loss was confirmed with a loss of 50 to 70 dB on the right and 65 to 80 dB on the left. He suffered since one year from chronic otitis media. Two years later, myopia gravis was found at the left eye with an ulcer of the cornea and glaucoma of the right eye for which he was treated with laser therapy. At the age of 44 he was helped with a hearing device at the left ear. Recently, he became totally blind. He suffered from chronic infections of the upper respiratory tract.

Present investigation showed a very friendly, well nourished, short statured male with a height of 159 cm (3 cm < 3rd centile) and weight of 67.5 kg (50th to 75th centile). He had a turriccephalic skull with a head circumference of 59.5 (0.5 cm > 97th centile) and sparse hair implantation. He had a coarse face with thick eyebrows, downward slanting palpebral fissures, blindness and a chronic conjunctivitis of the left eye (Fig. 1b). His ears were asymmetrical, with a rather sim-

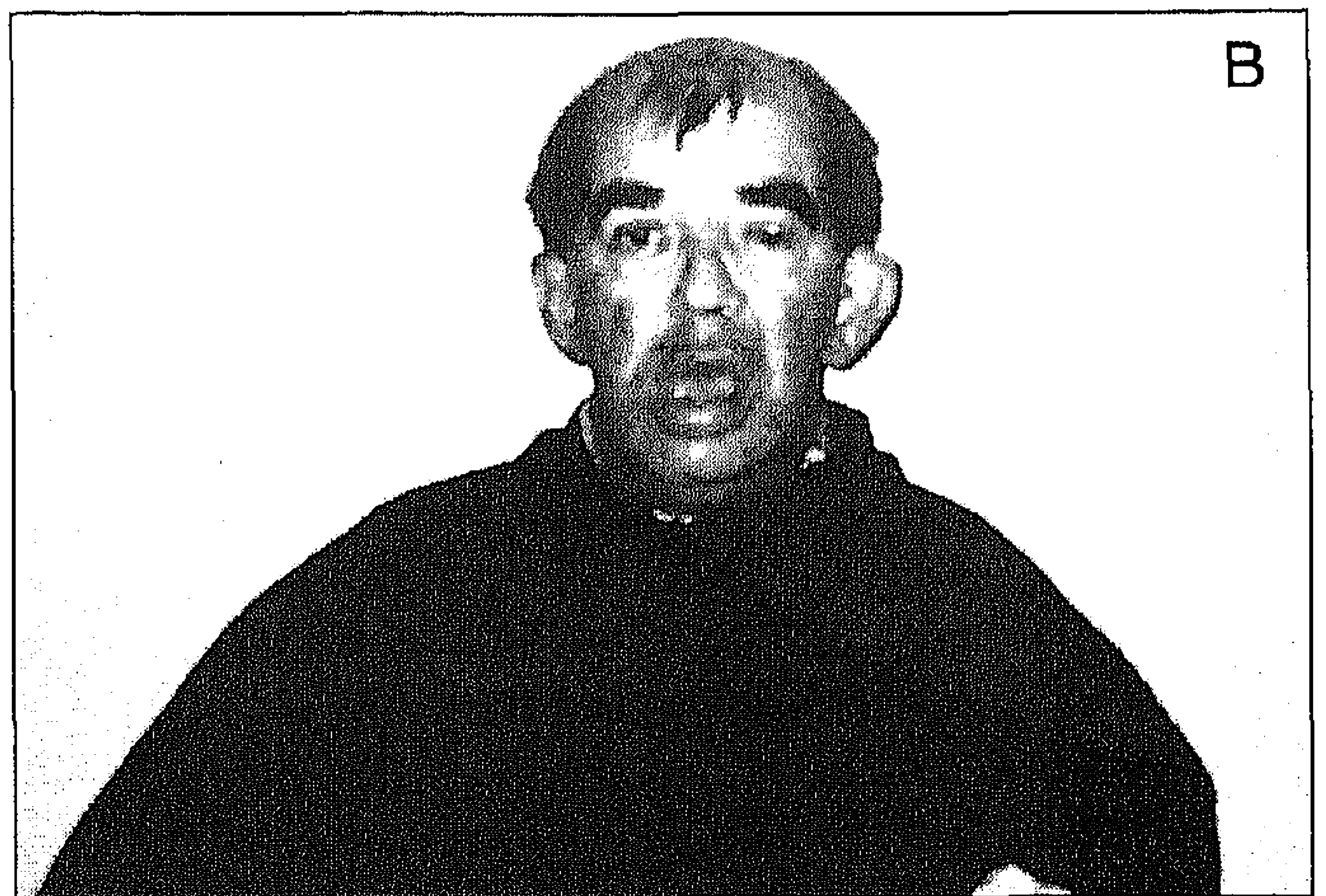
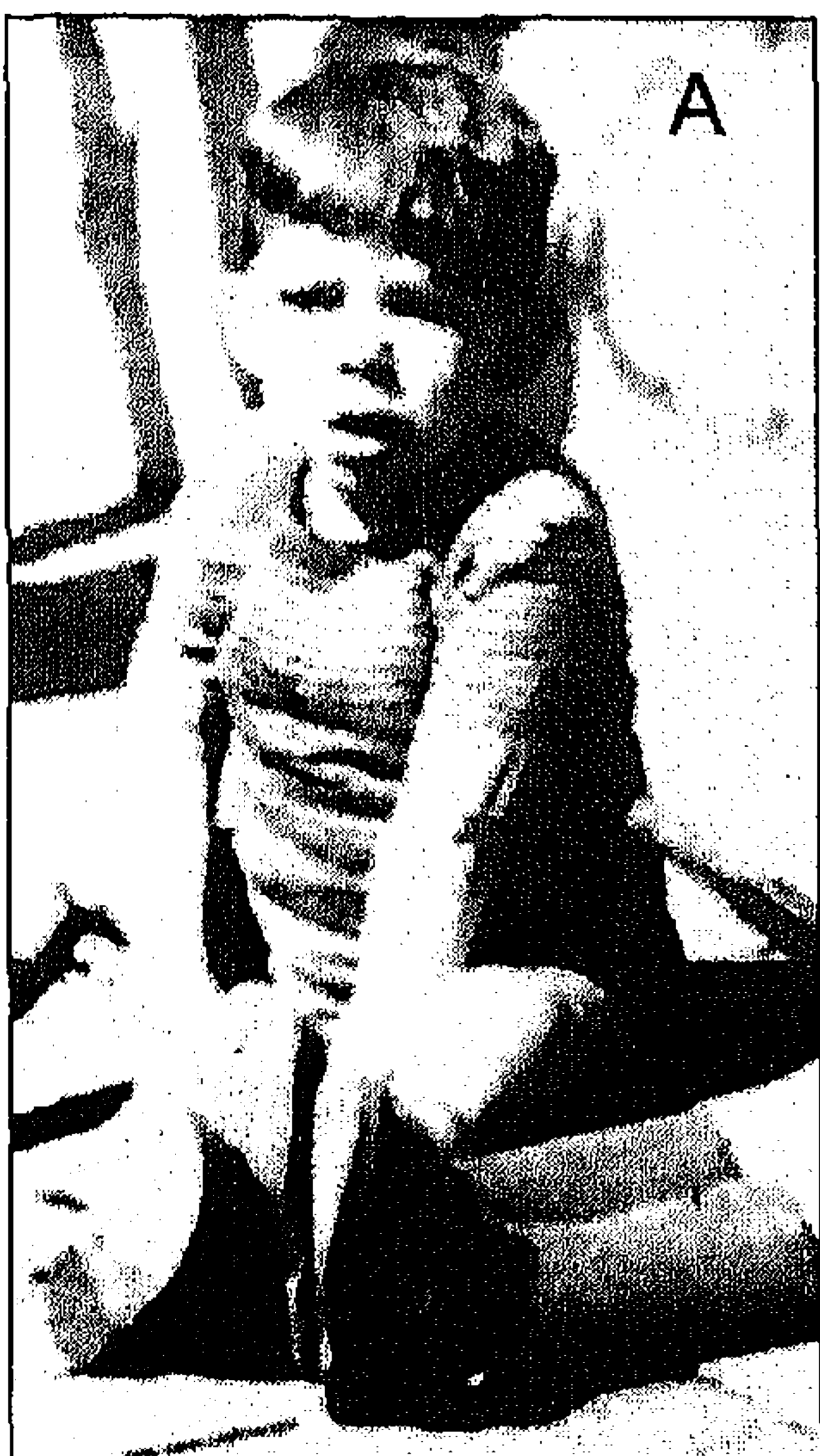

Figure 1: Aggravation of the facial coarseness and full lips in patient 1 (a, b) and patient 2 (c, d, e).

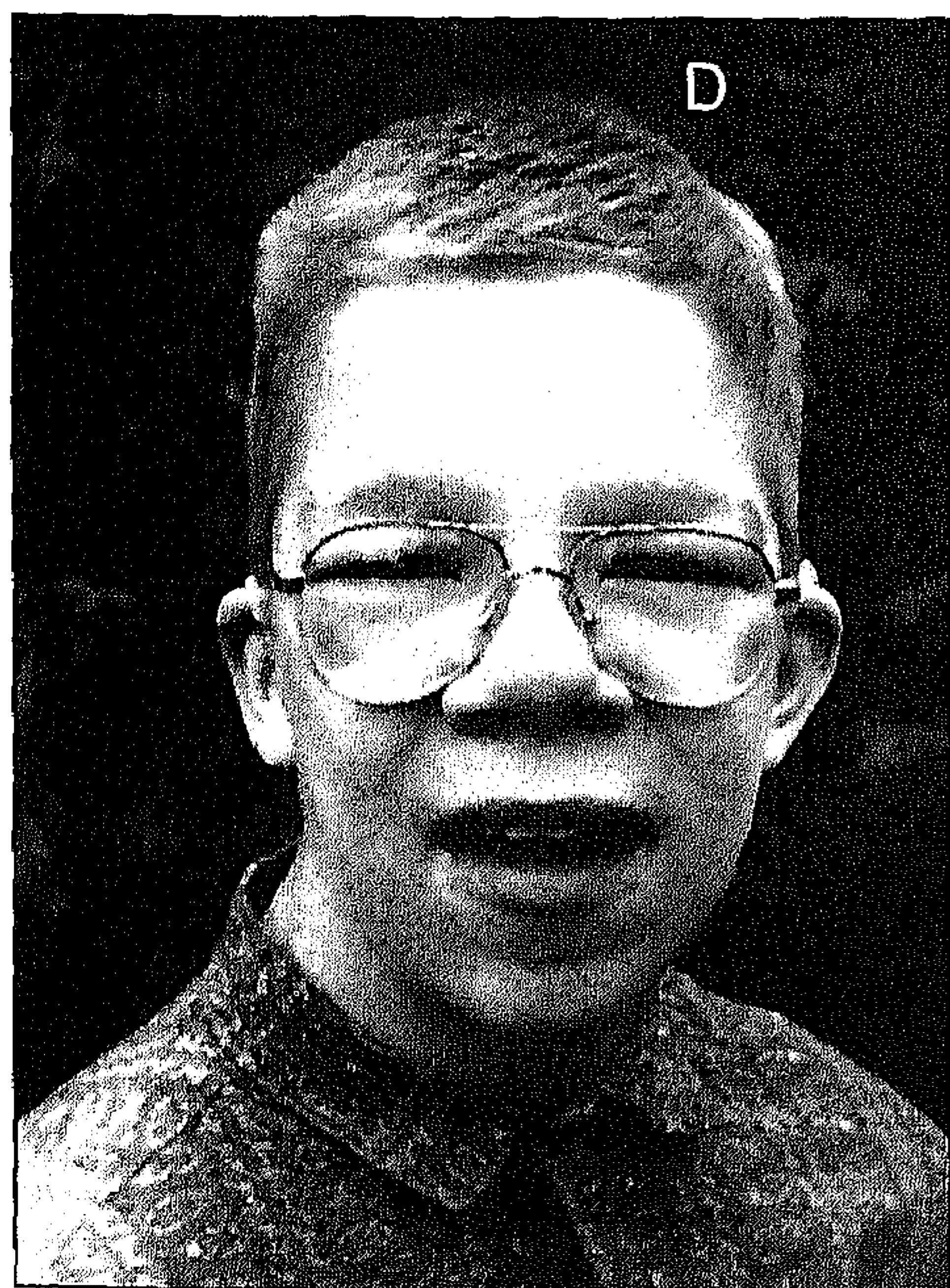
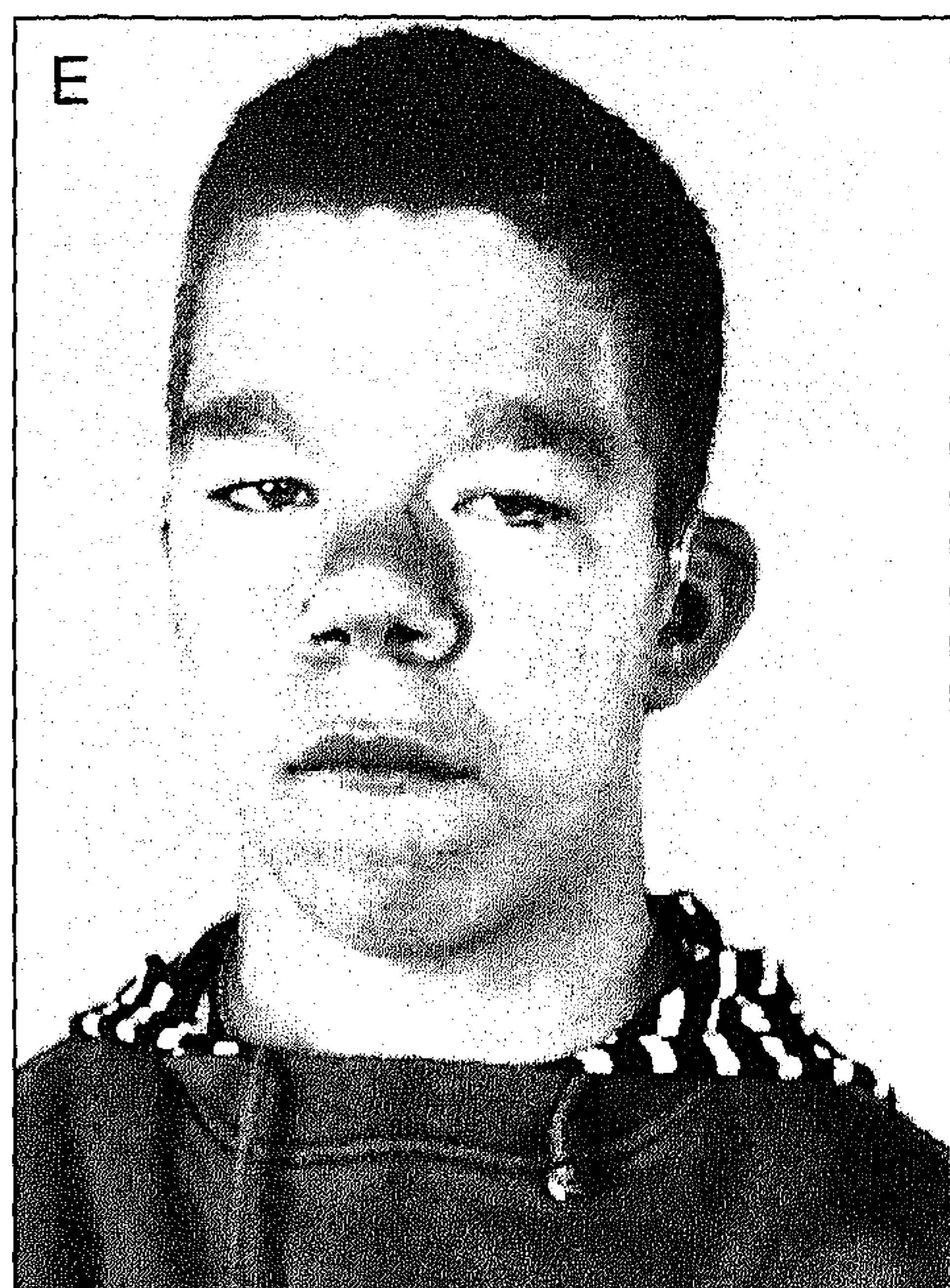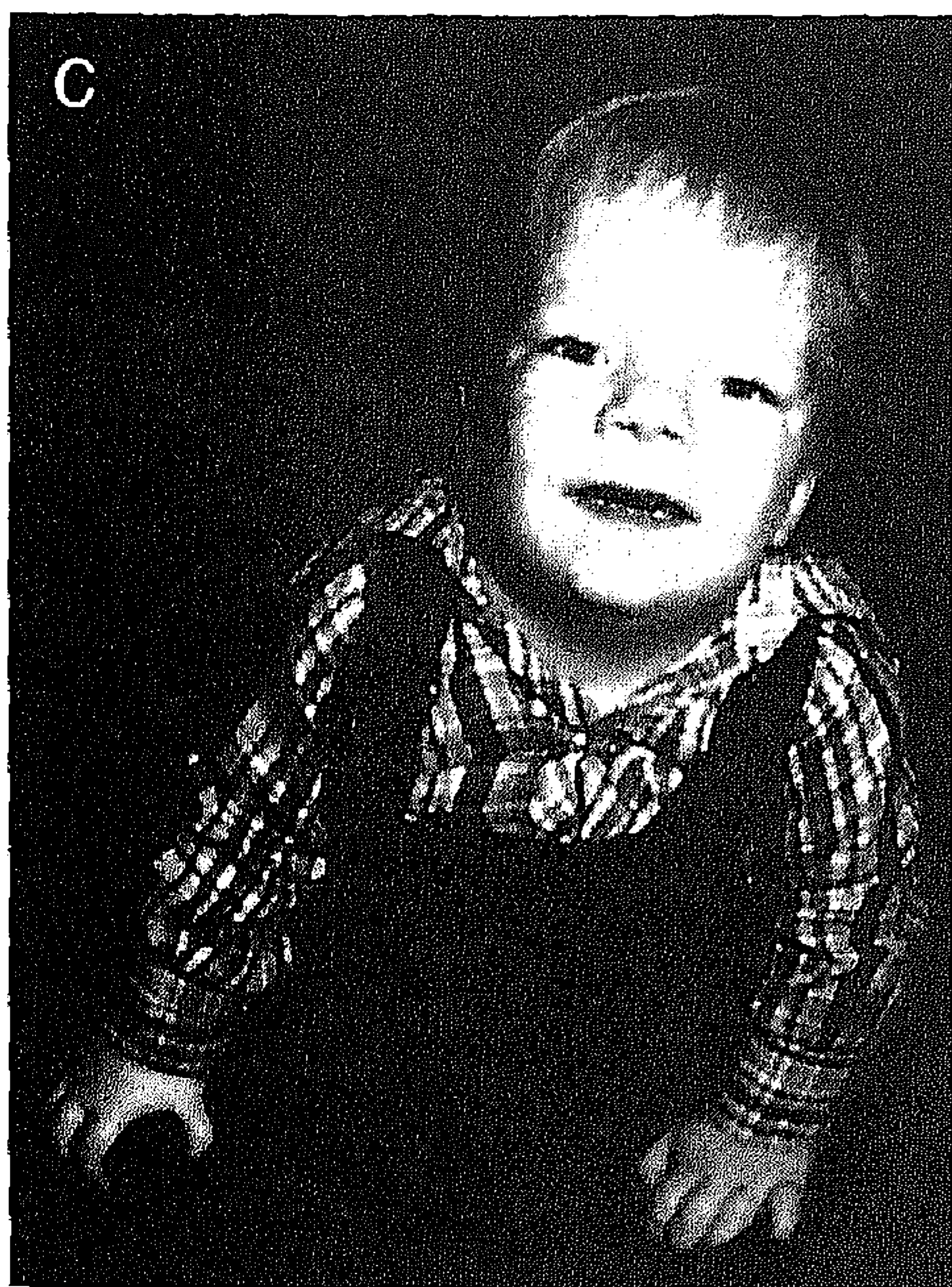


Figure 1: Aggravation of the facial coarseness and full lips in patient 1 (a, b) and patient 2 (c, d, e).

ple structure and hair on the helices, and measured 7 cm (75th to 97th centile) on the right and 7.5 cm (97th centile) on the left. He had a flat midface, large mandible and a large open mouth with thick full lips and a high palate. The skin of the cheeks

was very soft. There was truncal obesity, hypotonia of the abdominal muscles and small testes. Bilateral cubitus valgus was noticed. The hands were broad and large with a total hand length of 20 cm (>97th centile) and relatively short fingers. On the right hand there was a simian crease. X-rays of hands, skull and spine showed general osteoporosis, plump aspect of the hands with tufting of the distal phalanges, and sclerosis of the skull base and platyspondyly. Chromosomal analysis on a peripheral blood lymphocyte culture showed a normal 46,XY male karyotype. DNA studies were performed to exclude the fragile-X syndrome. The result of an extensive screening for inborn errors of metabolism was normal and excluded mannosidosis and aspartylglycosaminuria.

Patient 2

This boy, R.d.J., was the second child born to healthy, non-consanguineous par-

ents. The family history was negative for mental retardation. His mother was 22 and his father 25-years-old at the time of his birth. He was born after an uneventful pregnancy and delivery at a gestational age of 40 weeks, with a birth weight of 3100 g (10th to 25th centile). An omphalocele was detected at birth and surgically corrected on the first postnatal day. The neonatal period was complicated by a sepsis and bacterial arthritis of the left hip resulting in necrosis of the femur head. There were neonatal feeding problems and recurrent infections. The boy was able to walk with support at the age of 18 months and without support at the age of two and a half years (Fig. 1c). There was an extreme delay in language development and a deafness was suspected. At the age of 4 years sensorineural deafness was confirmed by electrocochleography: no response was detectable below 2 kHz. At the age of 5 years nocturnal epileptic attacks developed, that worsened with advancing age (Fig. 1d). Seizures were of generalized tonic-clonic type. Interictal EEG's were normal until the age of 16 years. After that age a slowing of the background activity appeared to correlate with mental regression and increase of seizures during the day. Cerebral CT-scans at the age of 13 and 16 years were normal. At the age of 11 years a bilateral orchidopexia was performed.

Physical examination at the age of 17 years showed a moderately mentally retarded boy with a length of 175 cm (25th centile) and a head circumference of 55.5 cm (50th centile). He had an extremely friendly and optimistic behavior. There was a brachycephaly with a broad forehead. Mild hypertelorism, with an ICD of 3,5 cm (75th to 97th centile) and an OCD of 10,2 cm (97th centile), and ptosis of the eyelids were seen (Fig. 1e). The ears were slightly posteriorly rotated and an ear pit was present bilaterally. The nose was large and had a bulbous tip (septum and alae nasi). The mouth was large with a full lower lip. The palate was extremely high and narrow with hyperplasia of the gums.

There was no oligodontia. Retrognathia and a broad neck were noticed. There was acne. Scoliosis was present and was ascribed to a post-infectious shortening of the left femur. Hand length was 18 cm (50th centile), the palms of the hands were short with palm length of 9,5 cm (10th centile) and the fingers were stubby.

Chromosomal and ophthalmological investigations revealed no abnormalities. Screening for inborn errors of metabolism was normal and excluded mannosidosis and glycosaminuria. In the cerebrospinal fluid (CSF) there was a slight increase of neuron specific enolase (15.7mg/l; Normal: 1.6-14.5 mg/l) and of S-100 (7;1 mg/l; Normal 0.9-5.5 mg/l) compatible with respectively neuronal and glial damage. No HbH bodies were detectable in peripheral blood. Cerebral MRI scan at the age of 17 years showed T2W signal increase in semi-ovale centers bilaterally and normal subcortical U-fiber myelination. An X-ray of the skull showed sclerosis of the basis of the skull. X-rays of the hands confirmed the plump aspect of the hands, tufting was within the normal ranges. The skeletal age was 15 years at a chronological age of 17 years.

Patient 3

The patient, PV, now 43-years-old, is the first child of healthy unrelated parents. His sister is normal and has two normal boys. His brother (patient 4) is mentally retarded and deaf. These two brothers were reported by Fryns *et al.* in 1987 (3). PV was born after an uneventful pregnancy at term with a birth weight of 4150 g (90th centile). At the age of 3 months, he developed hypsarrhythmia with seizures who were difficult to control despite ACTH therapy. Later he developed grand mal epilepsy and focal seizures of the left arm. Deafness was noted at the age of 15 months. Clinical investigation at the age of 29 years showed a mildly retarded male with a height of 170 cm (25th centile), weight of 62 kg (25th to

50th centile) and a head circumference of 55 cm (25th to 50th centile). He had a peculiar round and coarse face and with mild swellings of the subcutaneous tissue of the lips and cheeks. His hands and feet were short and broad with short and broad terminal phalanges. Ophthalmological, biochemical and metabolic investigations were normal. Cytogenetic investigation, including G- and R-banding, showed a normal male karyotype 46,XY. Profound sensorineural hearing loss with rudimentary hearing at the lowest frequencies was noted on an audiometry, the vestibular function of the ear was normal. The pars petrosa of the temporal bones showed anomalies on the turns of the cochlea on an X-ray tomography. An X-ray of the skull showed thickness of the calvaria and X-rays of the hands and feet confirmed the broad and plump aspect of the hands and feet. Since a few years he worked in a sheltered workshop, before he worked as

cm (97th centile). He has a severe hearing loss and there is no speech, but he communicates by using hand movements. He has a very friendly personality. He has long and coarse face, with a high forehead and a flat midface. There is synophrys and the OCD is 10.5 cm (>97th centile) and the ICD 3.3 cm (75th to 97th centile). Lips are full and everted, the skin of the cheeks is soft with loose subcutaneous tissue (Fig. 2a). Hands are broad and plump with a total hand length of 19.5 cm (97th centile) and palm length of 11.5 cm (75th to 97th centile).

Patient 4

This patient, LV, is the younger brother of patient 3. He is a 36 year old severely mentally retarded male. Pregnancy was uneventful. Birthweight was 3900 g (75th to 90th centile). At the



Figure 2:
Facial appearance of the 2 brothers at the present age of 43 years in patient 3 (a) and 36 years in patient 4 (b).

a butcher. At the age of 42 years he was hospitalized several times because of severe epileptic attacks.

Present investigation showed a mildly mentally retarded male in a good general condition. His length is 170 cm (25th to 50th centile), weight of 65 kg (50th to 75th centile) and head circumference of 58.6

age of 3 months he developed infantile spasms which later resulted in generalized convulsions. Psychomotor development was moderately to severely retarded. He could walk at the age of 18 months. Profound hearing loss was diagnosed at that time. Since the age of 5 years he was institutionalized. At the age of 18 years, he

showed mental regression. Physical investigation at 26 years showed a severely mentally retarded male with a height of 172 cm (25th to 50th centile), a weight of 65.5 kg (50th to 75th centile) and a head circumference of 55.5 cm (50th centile). He had a long coarse face with open mouth and full everted lips, high palate, small teeth and mandibular prognatism. The swelling of the subcutaneous facial tissues, especially of the lower lip became more evident between the age of 13 years and 26 years. He had a generalized hypotonia and thoracolumbar scoliosis. Hands and feet were broad and plump. Screening for inborn errors of metabolism was negative. Chromosomal investigation showed a normal male 46,XY karyotype. Audiometry showed severe sensorineural hearing loss with normal vestibular function. X-ray investigation of the hands and feet showed a thickened corticalis without ossification anomalies. X-ray of the skull showed marked thickness of calvaria. Tomography of the pars petrosa of the left temporal bone showed a congenital anomaly of the left inner ear. The cochlea was replaced by

a simple cavity. Ophthalmological investigation was normal.

Present investigation shows a severely mentally retarded male with a height of 172 cm (25th to 50th centile) and a weight of 65.5 kg (50th to 75th centile). He has no speech, but he communicates by using simple hand movements. He has an extreme friendly behavior. He looks microcephalic, however his head circumference is 55.5 cm (50th centile). His face is long and coarse, with a flat midface and a long forehead. There is pro-optosis with an OCD of 11.5 cm (>97th centile) and an ICD of 2.8 cm (25th to 50th centile). He has enormous full everted lips, a high palate and coarse nose (Fig. 2b). Pectus excavatum, lumbar scoliosis and hypotonia of the abdominal muscles are noted. Hands are broad with a lower implantation of the thumbs, and he has flatfeet.

Patient 5

The patient, W.V.L., a 26-year-old severely retarded male, was the second

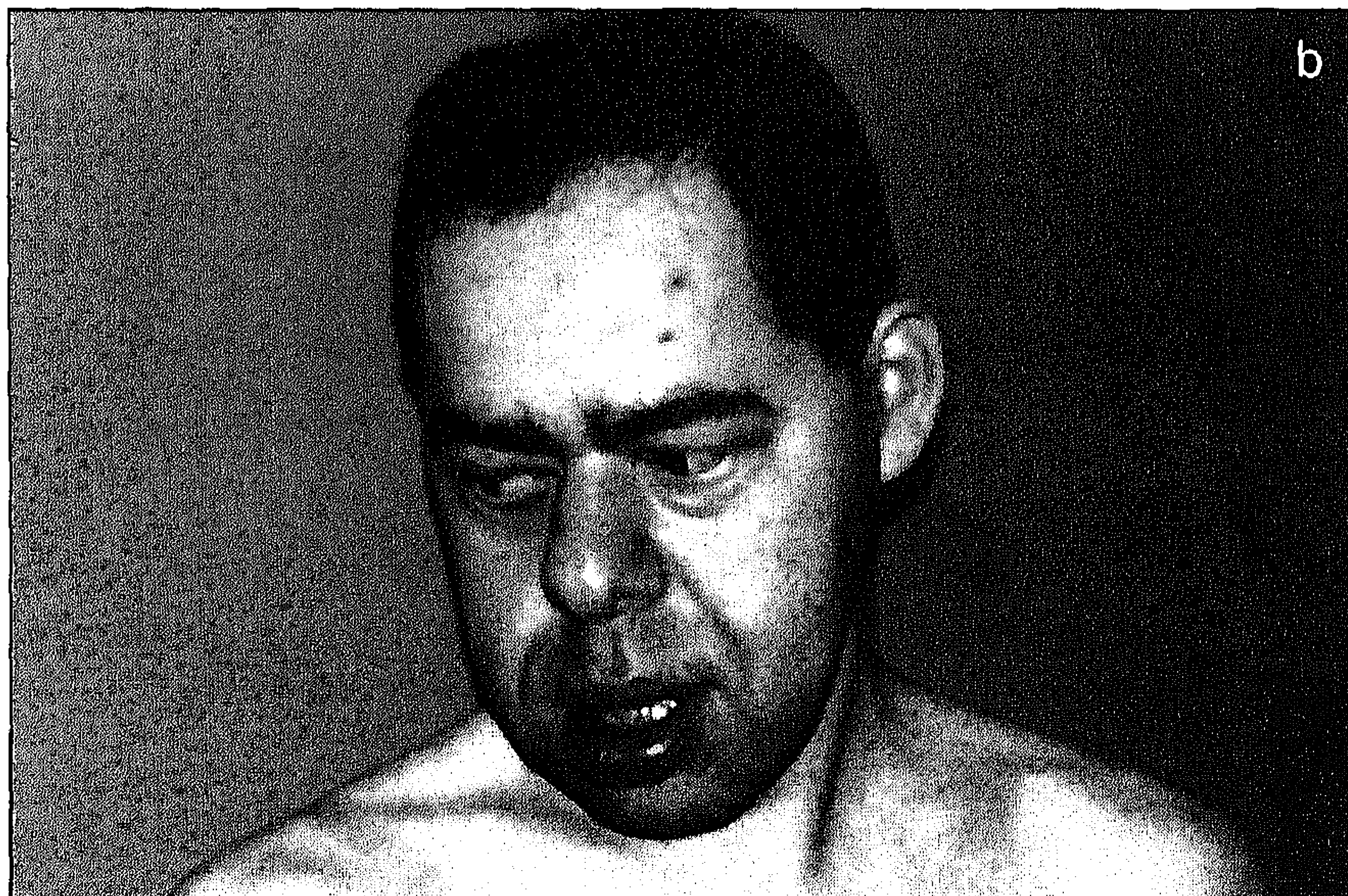

Figure 2: Facial appearance of the 2 brothers at the present age of 43 years in patient 3 (a) and 36 years in patient 4 (b).

born of three children. His two sisters were normal. There was no consanguinity and both parents were in a good health. Pregnancy was uneventful. Birthweight was 2750 g (25th to 50th centile) at the term of 36 weeks. Psychomotor development was severely delayed. When he was 2 years old, a round, plethoric face and short stubby hands and feet were noted. At the age of 4, he was severely retarded and could not walk or speak. His height was 93 cm (3rd centile), weight 15.2 kg (25th centile) and head circumference 51.5 cm (50th to 75th centile). The diagnosis of complete bilateral sensorineural deafness was made at this age. He was institutionalized at the age of 6 years. Physical investigation at the age of 17 years (see Fryns *et al.* (3)) revealed severe mental retardation, deafness, an edematous coarse face with thick everted lips, full cheeks and a depressed nasal bridge. Hands and feet were short and plump and an X-ray confirmed the presence of broad, heavy phalanges and metacarpals with thick cortices but without ossification defect. Length was 143.5 cm (<3rd centile). He had a severe motor impairment and could hardly walk without support. Screening for inborn errors of metabolism was normal and chromosomal investigation showed a normal male karyotype: 46,XY.

Present investigation shows a severely mentally retarded male with a height of 163 cm (1cm > 3rd centile), weight of 67.5 kg (50th to 75th centile) and a head circumference of 58.5 cm (97th centile). The span is 167.5 cm. His behavior is very friendly. There is no speech. He has a coarse face with a normal midface and a large mandible. There is acne. He has small eyelashes with epicanthus (Fig. 3a). He has full lips, especially the lower lip is everted. Hairline is low and his nose is very coarse (Fig. 3b). Thorax is barrelshaped and there is abdominal obesity. There is bilateral camptodactyly of 5th fingers. He walks atactic and the muscles of the lower extremities are hypoplastic.

DISCUSSION

Mental retardation, deaf mutism and skeletal abnormalities were first reported by Fountain in 1974 (1), in a family with 4 affected sibs. The two oldest children, a girl and a boy, had also a gross papular swelling of the skin of the cheeks, upper lip and chin. The fourth child died and had a spina bifida. X-rays of the skull of the 3 oldest children showed a thickened calvarium. The mental retardation and deafness became more clear at the age of 2 to 3 years.

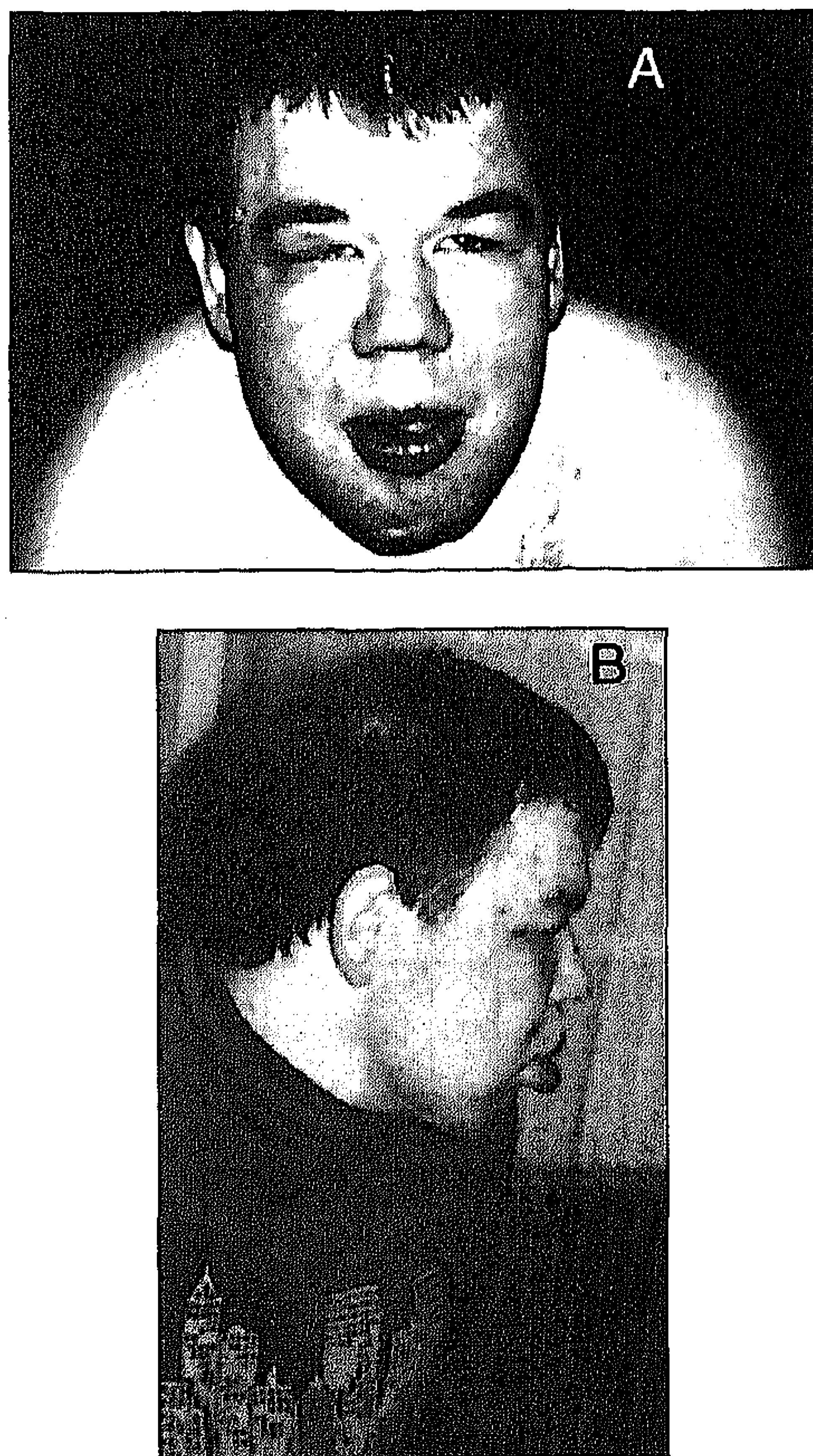


Figure 3: Facial appearance of patient 5 (A,B) at the age of 26 years.

Patients 3,4 and 5 of this report were first published by Fryns *et al.* in 1987 (3). Follow-up data of these three patients are presented in this report. The abnormal

Table I: Features in the Fountain syndrome: review.

Reference	Fountain (1)	Fountain (1)	Fountain (1)	Fountain (1)	Present case 1	Present case 2	Present case 3 (Fryns et al. (3))	Present case 4 (Fryns et al. (3))	Present case 5 (Fryns et al. (3))
Age (yrs)	22	24	21	ND	50	17	43	36	26
Sex	F	M	M	ND	M	M	M	M	M
MR	+	+ (IQ75)	+	+	moderate	moderate	mild	moderate	severe
Epilepsy	ND	ND	ND	ND	-	+	+	+	-
Deafness	+	+	+	ND	+	+	+ sensorineural	+ sensorineural	+
OFC	ND	ND	ND	ND	59.5cm (>P97)	55.5cm (P50)	58.6cm (P97)	55.5cm (P50)	58.5cm (P97)
Face	coarse	coarse	ND	ND	coarse	coarse	coarse/long	coarse/long	coarse
Midface	ND	ND	ND	ND	flat	normal	flat	flat	normal
Eyes	ND	ND	ND	ND	blind/thick eyebrows	ptosis/hyper- telorism	synophrys	pro-optosis	small eyelashes/ epicanthus
Lip/cheek	full/swelling	full/swelling	normal	ND	full/swelling	full	full/swelling	full/swelling	full/swelling
Length	150cm (1cm < P3)	ND	ND	ND	159cm (3cm < P3)	175cm (P25)	170cm (P25-P50)	172cm (P25-P50)	163cm (P3)
Thorax	normal	ND	ND	ND	normal	normal	normal	pectus excavatum	barrel shaped
Hands	ND	ND	ND	ND	broad/relative short fingers	stubby/short hands	broad/short terminal phalanges	broad/plump	short/plump
Feet	ND	ND	ND	ND	normal	normal	normal	normal	short
Behavior	ND	ND	ND	ND	friendly	friendly	friendly	friendly	friendly
X-ray skull	thickening calvarium	thickening calvarium	thickening calvarium	ND	ND	normal MRI: increased signal	thickening calvarium	thickening calvarium	ND
Other	gingival hypertrophia			spina bifida	high palate	ear pits large nose hyperplasia gums scoliosis omphalocele		coarse nose scoliosis	coarse nose, large mandible atactic walk

ND = no data, M = Male, F = Female, MR = Mental retardation, + = feature is present, - = feature is not present, P = centile

facial appearance in all three patients became more evident. Patient 3 suffered from severe epileptic attacks, for which hospitalisation was necessary during the last years. Due to a change in therapy his clinical condition improved. His brother (patient 4) and patient 5 did well and had no specific health problems.

Of the two new patients with Fountain syndrome, described in the present report, patient 1 is a moderately mentally retarded patient and he is the only patient in his family. However, his brother has a severe hearing loss and is helped with hearing aids but he is not mentally retarded and has a normal phenotype. Patient 2 has a delayed psychomotor development and he had severe epileptic insults. He is also the only patient in his family. Table I gives an overview of all reported and present cases.

Of the 5 present patients there were 3 cases with epilepsy (cases 2, 3 and 4), 3 with a rather large head circumference (cases 1, 3 and 5), 2 with thoracal abnormalities (cases 4 and 5) and 2 with scoliosis (cases 2 and 4). All patients had a coarse face, mental retardation, deafness and broad plump hands. Small stature is noticed in 2 patients (cases 1 and 5) and also in the first patient of Fountain (girl). Patient 1 had also a severe myopia leading to blindness. An omphalocele, which was corrected the first postnatal day was noted in patient 2. Noteworthy is the remarkable behavior of all patients who were extremely friendly.

Differential diagnosis includes the Coffin-Lowry syndrome, the alpha-thalassaemia syndrome and the Melkersson-Rosenthal syndrome. The Coffin-Lowry syndrome is characterized by the hypoplastic appearance of the distal phalanges and the dysplasia of the vertebral bodies. In alpha-thalassaemia syndrome hearing is normal and inclusions of hemoglobin in the red blood cells are found. The Melkersson-Rosenthal syndrome is an autosomal dominant disorder without mental retardation and without deafness;

swellings of the gums, cheeks and lips can be seen. Fountain wrote in a subscript of his publication that «a substance, probably aspartylglycosaminuria, has now been isolated». Further data were lacking. Aspartylglycosaminuria was excluded in our patients.

Considering all the patients that have been reported up to now, we conclude that the mode of inheritance of Fountain syndrome most likely is autosomal recessive. Follow-up studies showed that the parents of the sibs, reported by Fountain, came from the same part of London (1). In the two brothers, reported by Fryns *et al.* (2, 3) an X-linked inheritance is possible, although there were no other patients in their family. The other patients were sporadic cases.

The clinical signs in our two new patients match well with the previous reported ones (2). We propose that epilepsy, short stature, large head circumference, broad and plump hands and the friendly behavior are accessory features of this syndrome. Follow-up data suggest that the clinical picture becomes more clear with advancing age with an extreme coarsening of the face and severe hearing impairment. The follow-up in cases 2 and 4 suggests a possible slow decline in mental functioning associated in patient 2 with CSF changes compatible with cerebral degeneration. Follow-up in patient 3 showed an evolution to a difficult to treat epilepsy.

REFERENCES

1. FOUNTAIN R.B.: Familial bone abnormalities, deaf mutism, mental retardation and skin granuloma. *Proc. Roy. Soc. Med.*, 1974, 67, 878-879.
2. FRYNS J.P.: Fountain's syndrome: mental retardation, sensorineural deafness, skeletal abnormalities, and coarse face with full lips. *J. Med. Genet.*, 1989, 26, 722-724.
3. FRYNS J.P., DEREYMAEKER A., HOEFNAGELS M., VAN DEN BERGHE H.:

Mental retardation, deafness, skeletal abnormalities and coarse face with full lips: confirmation of the Fountain syndrome. *Am. J. Med. Genet.*, 1987, 26, 551-555.

Address for correspondence:

Prof. Dr. J.P. Fryns, Center for Human Genetics,
Herestraat 49, B-3000 Leuven, Belgium.