

## PDF hosted at the Radboud Repository of the Radboud University Nijmegen

The following full text is a publisher's version.

For additional information about this publication click this link.

<http://hdl.handle.net/2066/23677>

Please be advised that this information was generated on 2017-12-05 and may be subject to change.

## SHORT COMMUNICATIONS

# Derivative (y)t(Y;1)(q12;q12), +9 in a Patient with Polycythemia Vera During Transition into Myelodysplasia

R. Raymakers, F. Stellink, and A. Geurts van Kessel

**ABSTRACT:** *Cytogenetic analysis of bone marrow cells of a 63-year-old male Caucasian patient with polycythemia vera (PV) who developed anemia, thrombocytopenia, and increased granulocytic immaturity revealed a 47,X,der(Y) t(Y;1)(q12;q12), +9 karyotype. The breakpoint in chromosome 1 appeared to map to q12 and not to q21, as has been described in previous reports without FISH confirmation. In the 4 years before this transition the patient was polycythemic and, accordingly, treated with phlebotomy and three short courses of busulfan. The cytogenetic picture observed has been described before in seven patients: three with PV, three with myelodysplasia, and one with Fanconi anemia. In 5/7 cases, like in our patient, the abnormality was observed during transition of the disease into either myelodysplasia or AML.*

### INTRODUCTION

Several cytogenetic abnormalities have been described in patients with polycythemia vera (PV). These abnormalities are nonrandom, with a most frequent involvement of chromosomes 1, 8, 9, and 20 [1]. Karyotypic changes may correlate with transition of the disease. In this report a case history of a patient with PV is described. The karyotypic abnormalities found during transition of the disease into myelodysplasia correspond exactly with those described previously in three patients with PV, three with myelodysplasia (MDS), and one patient with Fanconi anemia (2-7).

### CASE HISTORY

A Caucasian man, aged 63, presented with anorexia (weight loss of 7 kg), night sweats, cold feet and fingers, and erythema on his legs and feet. Five years before, erysipelas on his right leg was diagnosed; 3 years later erysipelas was seen on both legs. He had stopped smoking many years before. Laboratory examinations showed a hemoglobulin of 12.9 mmol/L, a hematocrit of 0.62 l/L,

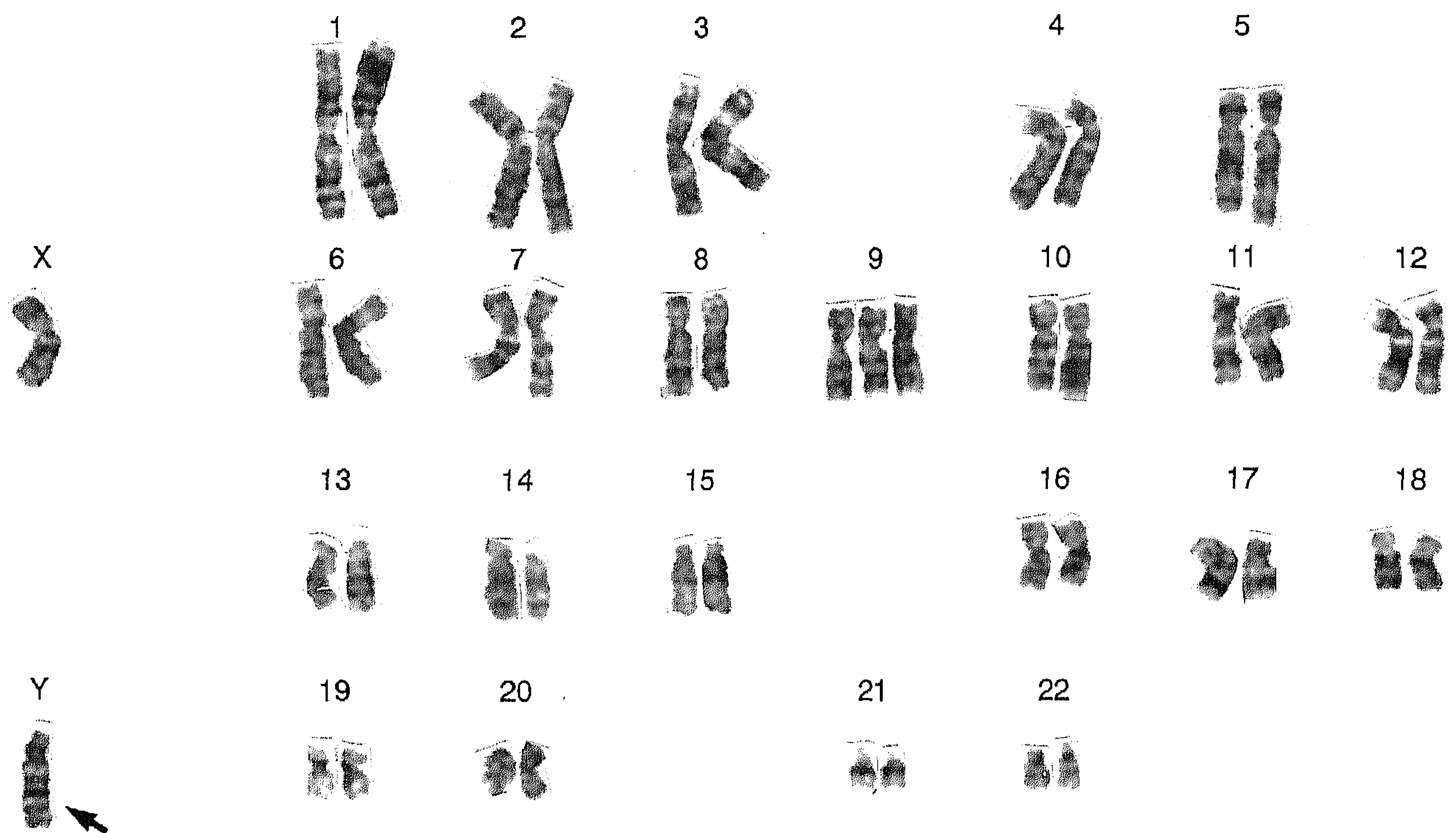
with a low mean cellular volume of 76 fl. There was a leukocytosis of  $17.7 \times 10^9/L$ , with 81% neutrophils, 11% lymphocytes, and a normal thrombocyte count. The spleen was palpable just below the costal margin. A bone marrow aspirate showed a hypercellular marrow with megaloblastic erythropoiesis. He was diagnosed to have primary polycythemia and treated with phlebotomy and acetosal. In the following years the patient frequently complained of bone pains. A bone scintigram showed increased activity in the femora and humeri.

Three years after diagnosis he was referred to our hospital for a second opinion. He had complaints of pain in his legs while walking; standing upright was especially painful. In winter, his feet and fingers were cold. Physical examination showed areas with erythema and noduli on both upper arms and upper legs, with pitting edema on his lower legs. His spleen was palpable 1 cm below the left costal margin. The hemoglobin content was 9.1 mmol/L, hematocrit 0.51 l/L, mean cellular volume 69 fl, leukocytes  $27 \times 10^9/L$ , and thrombocytes  $231 \times 10^9/L$ . Hydroxycobalamin levels were very high, 1200 pmol/L. Leukocyte alkaline phosphatase staining of the leukocytes was increased. Bone marrow smears revealed a normocellular marrow with active hematopoiesis, 1% myeloblasts, and 28% normoblasts. Progenitor cell culture showed hyperplastic and spontaneous growth of CFU-GM and BFUe. A biopsy of the skin lesions was classified as a leukocytoclastic vasculitis. The patient was treated with busulfan for 4 weeks, 4 mg/day, 3 months later for another 2 weeks, 4 mg/day, and

*From the Division of Hematology (R. R.) and Department of Human Genetics (F. S., A. G. v. K.), University Hospital Nijmegen, Nijmegen, The Netherlands.*

*Address reprint requests to: R. Raymakers, Division of Hematology-544, University Hospital Nijmegen, P. O. Box 9101, 6500 HB, Nijmegen, The Netherlands.*

*Received August 3, 1995; accepted October 5, 1995.*



**Figure 1** Karyotype of a patient-derived bone marrow cell. The translocation derivative chromosome der(Y) is marked by an arrow.

3 months later for a third period of busulfan, 4 weeks, 4 mg/day. After the acetosal was stopped and the polycythemia treated effectively, the pain and skin lesions gradually disappeared. Four years after diagnosis anemia and thrombocytopenia developed, while the leukocyte count moved into the normal range. The patient became erythrocyte transfusion dependent.

Laboratory examinations revealed an increased LDH (473 U/L), while the haptoglobin was not decreased (2.01 g/L). In the blood smear one blast-like cell, one promyelocyte, and several rods were seen, but no normoblasts. Bone marrow aspirate smears showed an active and dysplastic myelopoiesis with no increase in blasts. A bone marrow biopsy showed a hypercellular marrow with predominant myelopoiesis with a left shift. The erythropoiesis was megaloblastic and strongly suppressed. Cytogenetic analysis, performed according to standard methods [8], revealed a 47,X,der(Y),t(Y;1)(q12;q12),+9 karyotype (Fig. 1). A whole chromosome paint (pBS1) and chromosome Y and 1 heterochromatin-specific probes (DYZ1 and PUC1.77) were used to confirm the translocation, as reported before [8]. The der(Y) chromosome was positive for both DYZ1 and PUC1.77, thereby confirming the localization of the breakpoints within the corresponding heterochromatic regions of both chromosomes (data not shown).

At present, 1 year after the patient developed anemia, the clinical and laboratory situation is more or less stable.

He is erythrocyte transfusion dependent, requiring 2 units of packed cells/ week. The leukocytes remain stable between  $8-12 \times 10^9/L$ , with myelocytes and rods, but no blasts. The thrombocyte counts vary between 60 and  $90 \times 10^9/L$ .

In summary, a patient with polycythemia vera, treated with phlebotomy and three short courses of busulfan, progressed into myelodysplasia with depressed erythropoiesis and thrombopoiesis. There was no increase of blasts. During the phase of transition, chromosomal analysis revealed a 47,X,der(Y)t(Y;1)(q12;q12),+9 karyotype.

## DISCUSSION

In reviewing the literature, we found seven more patients with the same chromosomal aberration as found in our case. In 3/8 (including our patient) the patients were diagnosed with polycythemia vera. One special case history of a patient with Fanconi anemia was described [4]. In this patient the transient appearance of a clone with the chromosomal aberration was found, not correlating with a distinct phase of the disease. The other three patients all had myelodysplasia: one CMMol with no blasts (this patient was lost to follow-up [2]); one patient with an RAEB, who evolved into AML 4 months after diagnosis [3]; and a third patient with an RA who was known to have neutro- and thrombocytopenia as well as monocytosis for 14 years, and evolved into AML, FAB M2 and died 2 months later

[5]. Remarkably, the 47,X,der(Y)t(Y;1)(q12;q12),+9 aberration was found in nearly all cases during transition of the disease. In 3/4 polycythemia vera patients the aberration correlated with transition into myelodysplasia; in one patient no data on transition were provided [7]. In 2/3 MDS patients the disease evolved into AML [3, 5]. One patient with CMMol was lost to follow-up [2]. Recently, correlations between specific secondary karyotypic abnormalities and previous (chemo)therapy regimens have been described [9]. FISH analysis revealed that the breakpoint in chromosome 1 maps in band q12, thereby revising its previously reported location (q21). More cases with similar karyotypes and disease histories have to be evaluated to establish the relationship between treatment regimens and transition of polycythemia vera into myelodysplasia, as well as establish this chromosomal aberration as a marker for transition independent of previous therapy.

## REFERENCES

1. Mitelman F, Levan G (1981): Clustering of aberrations to specific chromosomes in human neoplasms. IV. A survey of 1,871 cases. *Hereditas* 95:79-139.
2. Hollings PE, Giles LM, Rosman I, Fitzgerald PH (1988): An identical t(Y;1)(q12;q21) in two patients with myelodysplastic syndromes. *Cancer Genet Cytogenet* 34:285-293.
3. Wei DC, Wan TS, Chan LC, Cheng PN (1993): der(Y)t(Y;1) is a nonrandom abnormality in myelodysplastic syndrome (letter). *Cancer Genet Cytogenet* 70:155-156.
4. Thompson PW, Standen GR, Geddes AD (1991): Transient t(Y;1)(q12;q21) in a patient with Fanconi anemia and myelodysplastic syndrome (letter). *Cancer Genet Cytogenet* 52:201-202.
5. Singh S, Wass J, Devaraj J, Young G, Vincent P (1993): Translocation (Y;1)(q12;q21) in acute leukemia. *Cancer Genet Cytogenet* 70:136-139.
6. Testa JR, Kanofsky JR, Rowley JD, Baron JM, Vardiman JW (1981): Karyotypic patterns and their clinical significance in polycythemia vera. *Am J Hematol* 11:29-45.
7. Rowley JD (1975): Abnormalities of chromosome 1 in myeloproliferative disorders. *Cancer* 36:1748-1757.
8. Geurts van Kessel A, Stellink F, van Gaal J, van de Klundert W, Siepman A, Oosten HR (1994): Translocation (12;22)(p13;q12) as sole karyotypic abnormality in a patient with nonlymphocytic leukemia. *Cancer Genet Cytogenet* 72:105-108.
9. Pedersen Bjergaard J, Rowley JD (1994): The balanced and unbalanced chromosome aberrations of acute myeloid leukemia may develop in different ways and may contribute differently to malignant transformation. *Blood* 83:2780-2786.