

PDF hosted at the Radboud Repository of the Radboud University Nijmegen

The following full text is a publisher's version.

For additional information about this publication click this link.

<http://hdl.handle.net/2066/23666>

Please be advised that this information was generated on 2017-12-05 and may be subject to change.

Delay in diagnosis of homocystinuria: retrospective study of consecutive patients

Johan R M Cruysberg, Godfried H J Boers, J M Frans Trijbels, August F Deutman

See editorial
by Isherwood

Abstract

Objective—To assess the causes for delay in the diagnosis of homocystinuria.

Design—Clinical and laboratory data were collected from patients diagnosed as having homocystinuria due to cystathionine synthase deficiency, with special reference to the ages at which the patients had their first major signs of the disease, ectopia lentis was established, and homocystinuria was diagnosed.

Setting—University hospital in the Netherlands.

Subjects—34 patients (18 males) in whom homocystinuria due to cystathionine synthase deficiency was diagnosed in the period 1970–94.

Results—Among 34 consecutively detected homocystinuria patients the mean age at diagnosis of homocystinuria was 24 (range 1–61) years. Despite frequent ocular manifestations, serious complications in the vascular, skeletal, and central nervous systems, and repeated examinations performed in these patients by clinicians of various disciplines, there was a mean delay of 11 (0–43) years between the first major signs of the disease (at mean age 13 (1–40) years) and the ultimate diagnosis of homocystinuria. Even when ectopia lentis was diagnosed (in 26 (76%) patients, mean age 18 (1–50) years), this did not lead to adequate biochemical analysis for homocystinuria at the time of detection, causing a mean diagnostic delay of 8 (0–24) years in these patients.

Conclusions—Three factors should have precipitated the diagnosis of homocystinuria: early recognition that unusual myopia (high, very high, abnormal progressive, or at young age) was caused by subluxation of the ocular lenses; awareness that the occurrence of myopia combined with systemic complications (“myopia plus”) might be due to homocystinuria; and appropriate biochemical investigations carried out in patients with ectopia lentis and in their siblings.

Introduction

Classic homocystinuria is an inborn error of metabolism with autosomal recessive inheritance, characterised by the inability to convert methionine to cysteine due to a deficiency of cystathionine synthase (fig 1).¹ Accumulation of homocysteine in tissues, blood, and urine is the consequence. Four major organ systems may be involved: the eye, the skeleton, the vascular system, and the central nervous system. Complications of the disease develop progressively if therapeutic measures have not been started at an early age.² We have detected a large number of homocystinuria patients in adulthood by systematic biochemical screening of patients with one or more clinical signs of this disease. We analysed the causes of the delay in making the diagnosis of homocystinuria.

Subjects and methods

The study included 34 patients (18 males, 16 females) in whom we established the diagnosis of homocystinuria due to cystathionine synthase deficiency in the period from 1970 to 1994. Records of the patients, who had been referred for various reasons to the institute of ophthalmology or the institute of internal medicine at our hospital, were analysed with respect to the age at which the patients had their first major signs of the disease, the age at which ectopia lentis was established, and the age at which homocystinuria was diagnosed. The time interval between these manifestations and the ultimate diagnosis of homocystinuria was calculated. The causes of delay in making the diagnosis of homocystinuria in these patients were studied from the records.

All patients underwent complete ophthalmological examination before and after maximal dilatation of the pupils, with special attention to the presence of ectopia lentis (subluxation or luxation of ocular lenses) and refractive error. Ophthalmic data before referral, such as prescriptions for spectacles or contact lenses, were collected from clinical records of various ophthalmologists and institutions.

In all patients in this study, homocysteine and methionine concentrations in blood were up to about 20 times the normal upper limit of 19 $\mu\text{mol/l}$, and the residual activity of cystathionine synthase in cultured fibroblasts was maximally 3% of the mean activity of normal subjects.^{3,5} Urine screening with the cyanide-nitroprusside test was used only in the first 16 patients; it was stopped because of false negative results in 38% and a borderline result in an additional 25% of the patients.

Results

In 34 consecutive patients in whom homocystinuria was detected (table 1) the mean age at diagnosis of homocystinuria was 24 (range 1–61) years. In only four (12%) of the 34 patients was the diagnosis of homocystinuria established before the age of 5 years. In 23 (68%) the diagnosis of this congenital metabolic disease was not made until adulthood (range 20–61 years). The diagnosis had been frequently missed at previous examinations by clinicians of various disciplines. Despite repeated physical examinations, the interval between the first major signs of the disease (at a mean age of 13 (1–40) years) and diagnosis of homocystinuria was 11 (0–43) years.

Before the diagnosis was made, 30 (88%) patients already had one or more serious manifestations of homocystinuria. These included occlusion of peripheral arteries, pulmonary embolism, cerebrovascular accident, deep vein thrombosis in the leg, ectopia lentis, acute pupil block glaucoma, scoliosis, marfanoid features, mental retardation, epilepsy, and psychosis. Only the four (12%) patients who were diagnosed by

University Hospital
Nijmegen, PO Box 9101,
6500 HB Nijmegen,
Netherlands

Johan R M Cruysberg,
ophthalmologist
Godfried H J Boers, internist
for metabolic diseases
J M Frans Trijbels, professor
of clinical biochemistry
August F Deutman, professor
of ophthalmology

Correspondence to:
Dr Cruysberg.

BMJ 1996;313:1037–40

Table 1—Manifestations of homocystinuria in 34 consecutive patients

Patient No	Sex	First major signs of the disease; age (years)	Age at diagnosis of ectopia lentis	Condition leading to diagnosis of homocystinuria; age (years)
1	F	High myopia, psychosis, pulmonary embolisms; age 40	49	History of ectopia lentis; age 50
2	F	High myopia, ectopia lentis, mental retardation; age 5	5	Acute glaucoma and history of ectopia lentis; age 20
3	F	Very high myopia and ectopia lentis; age 4	4	History of ectopia lentis; age 20
4	M	Myopia and sister with ectopia lentis (patient 3); age 9		Screening of siblings of patient 3; age 25
5	M	Myopia and seizures; age 4	26	Crural thrombosis and ectopia lentis; age 27
6	F	Very high myopia; age 18	19	Acute glaucoma, ectopia lentis, arterial ischaemia; age 21
7	F	High myopia and carotid artery stenosis; age 26		Screening of siblings of patient 6; age 29
8	M	High myopia, marfanoid features, mental retardation; age 8	16	Cerebrovascular accident and ectopia lentis; age 22
9	F	Very high myopia and marfanoid features; age 14	17	Acute glaucoma, ectopia lentis, cerebrovascular accident; age 20
10	M	Very high myopia and ectopia lentis; age 4	4	Ectopia lentis; age 4
11	M	Brother with ectopia lentis (patient 10); age 3		Screening of siblings of patient 10; age 3
12	F	Myopia and crural thrombosis; age 21	36	Retinal detachment after ectopia lentis; age 53
13	F	High myopia, psychosis, cardiac ischaemia; age 24	50	Screening of siblings of patient 12; age 50
14	F	High myopia in childhood; age 4	7	History of ectopia lentis; age 31
15	M	Myopia and psychomotor retardation; age 1	1	Surgery for marfanoid features; age 15
16	M	Myopia and marfanoid features; age 6	10	Acute glaucoma; age 11
17	M	High myopia and marfanoid features; age 6	6	History of ectopia lentis; age 23
18	F	Psychomotor retardation and marfanoid features; age 7		Marfanoid and mental features; age 9
19	F	Very high myopia; age 22	23	Fetal loss, thrombosis, psychosis; age 46
20	M	Myopia, psychomotor retardation, seizures; age 3	6	Acute glaucoma, crural thrombosis; age 9
21	M	High myopia and marfanoid features; age 6	13	History of ectopia lentis and marfanoid signs; age 29
22	M	High myopia and marfanoid features; age 6	10	History of ectopia lentis and marfanoid signs; age 26
23	F	Myopia and pulmonary embolism; age 18	25	High myopia and ectopia lentis; age 25
24	F	Myopia and psychomotor retardation; age 5	6	History of ectopia lentis; age 7
25	M	Sister with ectopia lentis (patient 23); age 20		Screening of siblings of patient 23; age 20
26	F	High myopia and surgery for scoliosis; age 18	49	History of ectopia lentis and pulmonary thrombosis; age 61
27	F	High myopia and ectopia lentis; age 17	17	History of ectopia lentis; age 19
28	M	Myopia, ectopia lentis, psychomotor retardation; age 3	3	Ectopia lentis; age 3
29	M	Very high myopia; age 30		Very high myopia; age 30
30	M	High myopia and psychomotor retardation; age 5	8	Very high myopia and ectopia lentis; age 8
31	M	Cerebrovascular accident; age 1		Cerebrovascular accident; age 1
32	F	Very high myopia; age 21	31	Cerebrovascular accident; age 31
33	M	Sister with ectopia lentis (patient 32); age 23		Screening of siblings of patient 32; age 23
34	M	Myopia and ectopia lentis; age 35	35	History of ectopia lentis and cardiac infarctions; age 52

Myopia = myopia ≥ 1 dioptre; high myopia = myopia ≥ 5 dioptries; very high myopia: myopia ≥ 10 dioptries.

the screening of siblings for homocystinuria had had no complications.

Ectopia lentis, though diagnosed in 26 (76%) of the 34 homocystinuria patients at a mean age of 18 (1-50) years, did not lead to adequate biochemical analysis for homocystinuria at the time of detection of the ectopia

lentis, thereby causing significant diagnostic delay (mean 8(0-24) years) in these 26 patients.

Although most of the patients had no unusual refractive errors in early childhood, myopia seemed to be the most consistent initial finding in these homocystinuric patients before the first major complications occurred. In 28 (93%) of the 30 patients with major complications, myopia of various degree (≥ 1.0 dioptre) had been documented in prescriptions for spectacles or contact lenses before the time that their first complications occurred. When systemic complications occurred in these patients, we defined such condition as "myopia plus": myopia (≥ 1.0 dioptre) associated with signs of systemic disease (that is, complications of homocystinuria): myopia plus vascular events, myopia plus skeletal abnormalities, or myopia plus central nervous system involvement. Myopia plus was present in 24 (71%) patients. Unusually high myopia (≥ 5.0 dioptries) was present in 24 (71%) patients at the time of diagnosis of homocystinuria; of these, 16 (47%) had very high myopia (≥ 10.0 dioptries). Only two (6%) patients, a 7 year old girl (patient 18) and a 1 year old boy (patient 31), had systemic complications of homocystinuria with absence of myopia. Three patients (cases 11, 18, and 31) were diagnosed very early as having

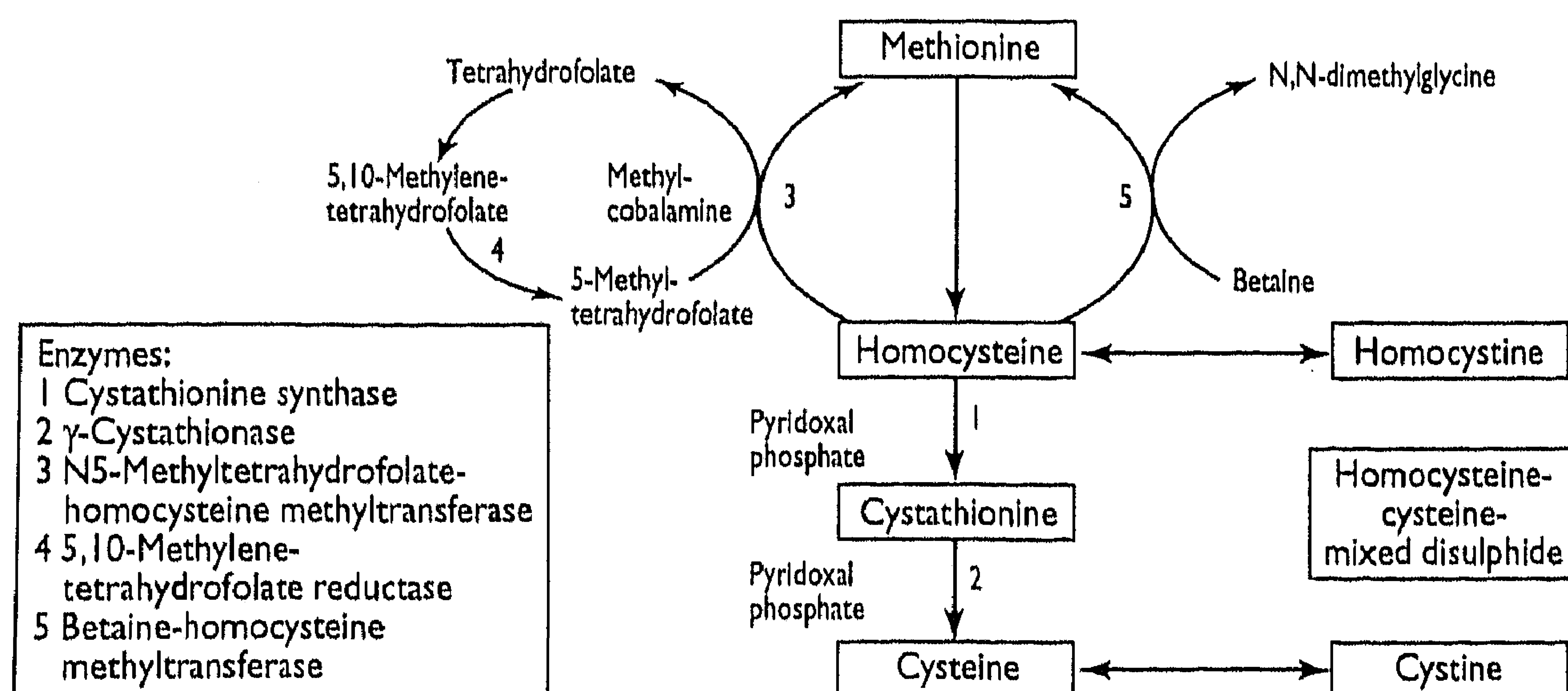


Fig 1—Methionine metabolism in humans

homocystinuria and started pyridoxine treatment before myopia developed; they had no myopia or ectopia lentis in follow up periods of 26, 14, and 5 years respectively. The diagnosis of ectopia lentis was preceded by detection of myopia in all cases.

In most patients there was more than one cause for diagnostic delay. The major causes were, firstly, not recognising that myopia, although unusual in presentation (early, high, very high, or abnormal progressive) was of lenticular origin—that is, the result of subluxation of the lenses (24 patients); secondly, not considering a common cause for the various organ complications and the unusual myopia (myopia plus; 21 patients); thirdly, not performing biochemical investigations for homocystinuria in patients with ectopia lentis because the ectopia lentis was thought to be a purely ocular disorder or attributed to Marfan's syndrome (20 patients); and, fourthly, not screening the family after ectopia lentis or homocystinuria, or both were diagnosed (four patients).

Thirty one patients (91%) responded completely or partially to vitamin B6. Patient 15 was a non-responder and in two patients response was unknown (patient 9 died some days after diagnosis and patient 16 was lost to follow up).

Discussion

From 34 consecutive patients diagnosed as having homozygous homocystinuria it is clear that the diagnosis is often missed even when characteristic clinical signs and complications are present. Serious clinical sequelae such as life threatening thromboembolic events at a young age, mental retardation, and ectopia lentis might be prevented by prompt treatment of patients detected as having homocystinuria.² High doses of vitamin B6 (pyridoxine), which is a cofactor of the deficient enzyme cystathionine synthase, decreases the effects of the disease. Patients who do not respond to vitamin B6 can be treated by folic acid and betaine, which are both substrates for the remethylation of homocysteine to methionine, or by dietary methionine restriction.¹ It is obvious that early diagnosis is crucial for the prognosis of these patients.³ However, in most of our 34 patients homocystinuria was not suspected for a long time, although indications for the diagnosis were clearly present. The mean age of diagnosis in these patients was 24 years. Though they had had many ophthalmological examinations there was a diagnostic delay between the appearance of the first ocular symptoms, such as unusual myopia and ectopia lentis, and the ultimate biochemical diagnosis of homocystinuria.

UNUSUAL MYOPIA

It is understandable that the development of moderate myopia in the second decade of life causes little suspicion that there is a metabolic disease because myopia is a common finding in the normal population. However, myopia in excess of 5 dioptres is extremely rare in children under 5 years⁶ and probably affects under 2% of adults.⁷ In such high myopia, an abnormality of one particular component of ocular refraction of the axial length, the corneal curvature, or the lens is most likely.⁸ Thus, if the ocular fundus of a highly myopic patient shows no clear ophthalmoscopic signs of axial myopia and the corneal curvature is not abnormal, then lenticular myopia due to ectopia lentis should be suspected and searched for. If subluxation of the lens is suspected, but not visible, the presence of an abnormal lens power can be concluded from calculation of the dioptric power of the intraocular lens from refraction, keratometry, and axial length measurements. Other clues for lenticular myopia are abnormally rapid progression of myopia, high myopia in children, progressive myopia in adult life, and high non-corneal astigmatism with subnormal visual acuity. Patients with

Key messages

- The diagnosis of homocystinuria is often missed
- High myopia may be caused by ectopia lentis
- Unusual myopia combined with skeletal, vascular, or central nervous system manifestations may have its origin in homocystinuria
- Patients with ectopia lentis should have appropriate blood examinations for homocystinuria

undiagnosed homocystinuria, or their parents, may be very anxious about the progression of the myopia. They may erroneously be advised to undergo surgical treatment of the refraction anomaly by radial keratotomy or excimer laser keratectomy, instead of receiving treatment for the cause of myopia. Apart from this, an important concern should be that many complications at a young age in clearly myopic patients, such as pulmonary embolism, cerebrovascular accident, excessive height, seizures, or mental retardation, do not always lead to the diagnosis of a causal systemic disease. It is apparent from our study that the association of any of these complications with myopia, which we have called myopia plus, is a valuable clue to the diagnosis of homocystinuria. Several case reports confirm this statement.⁹⁻¹²

ECTOPIA LENTIS

Ectopia lentis occurs in about 85% of homocystinuria patients.^{2 13 14} As correctly noted by Mudd and associates,² data on age of lens dislocation represent the date of detection of ectopia lentis rather than of its actual occurrence. In homocystinuria the age of development of high myopia (≥ 5 dioptres) before the detection of ectopia lentis is a better indication of the start of lens dislocation. Even when ectopia lentis is established it unfortunately does not lead to the correct diagnosis because biochemical investigation is not done. These patients are not suspected of having a systemic disease or are misdiagnosed as having Marfan's syndrome because of the presence of marfanoid features. The importance of differentiating homocystinuria from Marfan's syndrome has been pointed out previously.¹⁴⁻¹⁷ Even after 1962, when homocystinuria was described,¹⁸⁻¹⁹ several papers dealing with Marfan's syndrome either included cases of homocystinuria^{20 21} or did not provide sufficient evidence that homocystinuria had been excluded.²²⁻²⁸ Furthermore, in cases in which ophthalmologists are aware of the necessity to exclude homocystinuria, the correct diagnosis can be missed due to inadequate biochemical investigation. The urinary cyanide-nitroprusside test (Brand test), the screening test recommended by many authors,^{14 20-21} has a fairly high false negative rate in homocystinuria patients, particularly in newborns and mildly affected adults,^{4 12} and can give false positive results in many normal subjects. The modification of the test described by Spaeth and Barber as the silver-nitroprusside test, which excludes the detection of cystinuria, may enhance the specificity, but it does not enhance the sensitivity as these authors claimed.¹³ Homocysteine concentration (preferably measured as total plasma homocysteine¹⁴) and methionine concentration in plasma should be determined, and measurement of cystathionine synthase activity in cultured fibroblasts from a skin biopsy should confirm the diagnosis enzymatically.

In summary, the finding of "unusual" myopia—high myopia, very high myopia, abnormal progressive myopia, myopia at young age, or high myopia without myopic fundus—should warrant the ophthalmologist to search carefully for ectopia lentis. If ectopia lentis can be

established, adequate biochemical investigations for homocystinuria are mandatory. The recognition of myopia in patients with thromboembolism, skeletal anomalies, or central nervous system complications should alert physicians to the possibility that "myopia plus" can have its origin in homocystinuria.

Funding: No additional funding.

Conflict of interest: None.

- Mudd SH, Levy HL, Skovby F. Disorders of transsulfuration. In: Scriver CR, Beaudet AL, Sly WS, Valle D, eds. *The metabolic and molecular bases of inherited disease*. New York: McGraw-Hill, 1995:1279-327.
- Mudd SH, Skovby F, Levy HL, Pettigrew KD, Wilcken B, Pyeritz RE, et al. The natural history of homocystinuria due to cystathionine beta-synthase deficiency. *Am J Hum Genet* 1985;37:1-31.
- Boers GHJ, Smals AGH, Drayer JIM, Trijbels JMF, Leermakers AI, Kloppenborg PWC. Pyridoxine treatment does not prevent homocystinemia after methionine loading in adult homocystinuria patients. *Metabolism* 1983;32:390-7.
- Boers GHJ, Fowler B, Smals AGH, Trijbels JMF, Leermakers AI, Kleijer WJ, et al. Improved identification of heterozygotes for homocystinuria due to cystathionine synthase deficiency by the combination of methionine loading and enzyme determination in cultured fibroblasts. *Hum Genet* 1985;69:164-9.
- Boers GHJ. *Homocystinuria*. Dordrecht and Riverton, WY: Foris, 1986. (Clinical research series 3.)
- Mohindra I, Held R. Refraction in humans from birth to five years. *Doc Ophthalmol Proc Ser* 1981;28:17-29.
- Sorsby A, Sheridan M, Leary GA, Benjamin B. Vision, visual acuity, and ocular refraction of young men. Findings in a sample of 1033 subjects. *BMJ* 1960;i:1394-8.
- Sorsby A, Leary GA, Richards MJ. Correlation ametropia and component ametropia. *Vision Res* 1962;2:309-13.
- Schoonderwaldt HC, Boers GHJ, Cruysberg JRM, Schulte BPM, Slooff JL, Thijssen HOM. Neurologic manifestations of homocystinuria. *Clin Neurol Neurosurg* 1981;83:153-62.
- Johnston SS. Pupil-block glaucoma in homocystinuria. *Br J Ophthalmol* 1968;52:251-6.
- Leuenberger S, Faulborn J, Sturrock G, Gloor B, Baumgartner R. Ein Fall von Homocystinurie mit allgemeinen und okulären Komplikationen. *Klin Mbl Augenheilkd* 1983;182:457-8.
- Garston JB, Gordon RR, Hart CT, Pollit RJ. An unusual case of homocystinuria. *Br J Ophthalmol* 1970;54:248-51.
- Cross HE, Jensen AD. Ocular manifestations in the Marfan syndrome and homocystinuria. *Am J Ophthalmol* 1973;75:405-20.
- Spaeth GL, Barber GW. Homocystinuria—its ocular manifestations. *J Pediatr Ophthalmol* 1966;3:42-8.
- Boers GHJ, Polder TW, Cruysberg JRM, Schoonderwaldt HC, Peetoom JJ, van Ruyven TWJ, et al. Homocystinuria versus Marfan's syndrome: the therapeutic relevance of the differential diagnosis. *Neth J Med* 1984;27:206-12.
- McKusick VA. Homocystinuria. In: McKusick VA, ed. *Heritable disorders of connective tissue*. St Louis: Mosby, 1972:224-81.
- Brenton DP, Dow CJ, James JIP, Ray RL, Wynne-Davies R. Homocystinuria and Marfan's syndrome: a comparison. *J Bone Joint Surg* 1972;54B:277-98.
- Carson NAJ, Neill DW. Metabolic abnormalities detected in a survey of mentally backward individuals in Northern Ireland. *Arch Dis Child* 1962;37:505-13.
- Gerritsen T, Vaughn JG, Waisman HA. The identification of homocystine in the urine. *Biochem Biophys Res Commun* 1962;9:493-6.
- Jarrett WH. Dislocation of the lens. *Arch Ophthalmol* 1967;78:289-96.
- Cernea P, Zbranca E. L'homocystinurie et le syndrome de Marfan. *Ann d'Oculist* 1972;205:167-78.
- Hindle NW, Crawford JS. Dislocation of the lens in Marfan's syndrome. Its effect and treatment. *Can J Ophthalmol* 1969;4:128-35.
- Walsh FB, Hoyt WF. *Clinical Neuro-ophthalmology*. Vol 1. 3rd ed. Baltimore: Williams and Wilkins, 1969:782.
- Peyman GA, Ruichand M, Goldberg MF, Ritaeca D. Management of subluxated and dislocated lenses with the vitrophage. *Br J Ophthalmol* 1979;63:771-8.
- Matthaus W, Krantz H. Erfahrungen mit der Kryoextraktion der Linse aus dem Glaskörper in 123 Fällen. *Ophthalmologica* 1976;173:111-8.
- Matthaus W. Ergebnisse der Kryoextraktion luxierter und stark subluxierter Linsen. *Klin Mbl Augenheilkd* 1984;185:253-8.
- Croxatto JO, Lombardi A, Malbran ES. Inflamed eye in Marfan's syndrome with posteriorly luxated lens. *Ophthalmologica* 1986;193:23-6.
- Cullom RD Jr, Cullom ME. Two neuro-ophthalmic episodes separated in time and space. *Surv Ophthalmol* 1995;40:217-24.
- Blika S, Saunte E, Lunde H, Gjessing LR, Ringvold A. Homocystinuria treated with pyridoxine. *Acta Ophthalmol* 1982;60:894-906.
- Neetens A, De Smet N, Verschuere C, Zelencova L. Homocystinuria and marfanoid appearance. *Bull Soc Belge Ophthalmol* 1980;191:29-37.
- Spaeth GL, Barber GW. Prevalence of homocystinuria among the mentally retarded: evaluation of a specific screening test. *Pediatrics* 1967;40:586-9.
- Murphree AL. Comment: homocystinuria treated with pyridoxine. *Surv Ophthalmol* 1984;28:357.
- Spaeth GL. Screening for homocystinuria. *Surv Ophthalmol* 1984;29:230.
- Applegarth DA, Vallance HD, Seccombe D. Are patients with homocystinuria being missed? *Eur J Pediatr* 1995;154:589.

(Accepted 20 August 1996)

Insulin sensitivity and regular alcohol consumption: large, prospective, cross sectional population study (Bruneck study)

Stefan Kiechl, Johann Willeit, Werner Poewe, Georg Egger, Friedrich Oberhollenzer, Michele Muggeo, Enzo Bonora

Department of Neurology,
University of Innsbruck,
Innsbruck, Anichst 35,
A-6020 Innsbruck, Austria
Stefan Kiechl, lecturer in
neurology
Johann Willeit, associate
professor
Werner Poewe, professor

Department of Internal
Medicine, Bruneck
Hospital, I-39031
Bruneck, Italy
Georg Egger, consultant
cardiologist
Friedrich Oberhollenzer,
head of hospital

Department of
Endocrinology and
Metabolism, Ospedale
Civile Maggiore, I-37126
Verona, Italy
Michele Muggeo, professor
Enzo Bonora, associate
professor

Correspondence to:
Dr Kiechl.

BMJ 1996;313:1040-4

Abstract

Objectives—To assess the relation between regular alcohol consumption and insulin sensitivity, and to estimate the importance of insulin in the association of alcohol with multiple vascular risk factors and cardiovascular disease.

Design—Prospective and cross sectional study of a large randomly selected population sample.

Setting—Part of the Bruneck study 1990-5 (Bolzano province, Italy).

Subjects—820 healthy non-diabetic women and men aged 40-79 years.

Main outcome measure—Concentrations of fasting and post-glucose insulin, cholesterol, apolipoproteins, triglycerides, Lp(a) lipoprotein, glucose, fibrinogen, and antithrombin III; blood pressure; insulin resistance estimated by the homeostasis model assessment.

Results—Fasting insulin concentrations in those who did not drink alcohol and subjects reporting low (1-50 g/day), moderate (51-99 g/day), and heavy (≥ 100 g/day) alcohol intake were 12.4, 10.0, 8.7, and 7.1 mU/l ($P < 0.001$). Likewise, post-glucose insulin concentrations and estimates for insulin resistance assessed by the homeostasis model assessment decreased significantly with increasing amounts of regular alcohol consumption. These trends were independent of sex, body mass index, physical activity, cigarette smoking,

medication, and diet ($P < 0.001$). Regular alcohol intake predicted multiple changes in vascular risk factors over a five year period including increased concentrations of high density lipoprotein cholesterol and apolipoprotein A I; higher blood pressure; and decreased concentration of antithrombin III. These associations were in part attributable to the decrease in insulin concentrations observed among alcohol consumers.

Conclusions—Low to moderate amounts of alcohol, when taken on a regular basis, improve insulin sensitivity. Insulin is a potential intermediate component in the association between alcohol consumption and vascular risk factors (metabolic syndrome).

Introduction

Insulin resistance and hyperinsulinaemia are prominent predictors of risk for the development of diabetes mellitus¹ and may promote atherosclerotic diseases because of the association with multiple vascular risk factors and direct atherogenic effects.²⁻⁴ For preventive purposes precise knowledge of environmental determinants of insulin sensitivity is mandatory. Obesity and insufficient physical activity rank among these factors. With regard to alcohol consumption, a further widespread and potentially modifiable behaviour, epidemiological evidence is sparse and restricted to low