



UNIVERSITY OF LEEDS

This is a repository copy of *Comparative effectiveness of  $^{18}\text{F}$ -FDG PET-CT and contrast-enhanced CT in the diagnosis of suspected large-vessel vasculitis.*

White Rose Research Online URL for this paper:

<http://eprints.whiterose.ac.uk/132952/>

Version: Accepted Version

---

**Article:**

Vaidyanathan, S, Chattopadhyay, A, Mackie, SL et al. (1 more author) (2018) Comparative effectiveness of  $^{18}\text{F}$ -FDG PET-CT and contrast-enhanced CT in the diagnosis of suspected large-vessel vasculitis. *British Journal of Radiology*, 91 (1089). e20180247. ISSN 0007-1285

<https://doi.org/10.1259/bjr.20180247>

---

© 2018 The Authors. Published by the British Institute of Radiology. This is an author produced version of a paper published in *British Journal of Radiology*. Uploaded in accordance with the publisher's self-archiving policy.

**Reuse**

Items deposited in White Rose Research Online are protected by copyright, with all rights reserved unless indicated otherwise. They may be downloaded and/or printed for private study, or other acts as permitted by national copyright laws. The publisher or other rights holders may allow further reproduction and re-use of the full text version. This is indicated by the licence information on the White Rose Research Online record for the item.

**Takedown**

If you consider content in White Rose Research Online to be in breach of UK law, please notify us by emailing [eprints@whiterose.ac.uk](mailto:eprints@whiterose.ac.uk) including the URL of the record and the reason for the withdrawal request.



[eprints@whiterose.ac.uk](mailto:eprints@whiterose.ac.uk)  
<https://eprints.whiterose.ac.uk/>

**Title:** Comparative effectiveness of 18F-FDG PET-CT and contrast-enhanced CT in the diagnosis of suspected large-vessel vasculitis

**Running head:**

FDG PET/CT and CECT in LVV

**Authors:**

<sup>a</sup> Sriram VAIDYANATHAN, *MD* Consultant

<sup>a</sup> Arpita CHATTOPADHYAY, *MChB*, Specialty Registrar

<sup>b</sup> Sarah L MACKIE, *PhD*, Associate Professor and Honorary Consultant

<sup>a</sup> Andrew F SCARSBROOK, *FRCR*, Consultant

**Institution:**

<sup>a</sup> Department of Radiology and Nuclear Medicine, St James's University Hospital, Beckett Street, Leeds, LS9 7TF United Kingdom.

<sup>b</sup> Leeds NIHR Biomedical Research Centre, Leeds Institute for Rheumatic and Musculoskeletal Medicine, University of Leeds.

**Correspondence:**

Dr. Sriram Vaidyanathan

Department of Radiology and Nuclear Medicine

Level 1 Bexley Wing

St. James's University Hospital

Beckett Street, Leeds, LS9 7TF. United Kingdom

Tel: +44 (0) 113 206 8212

Fax: +44 (0) 113 206 8228

Email: [s vaidyanathan@nhs.net](mailto:s vaidyanathan@nhs.net)

**Sources of funding/conflict of interest:** The authors declare that they have no conflict of interest. No funding was obtained for this study.

**Title:** Comparative effectiveness of 18F-FDG PET-CT and contrast-enhanced CT in the  
diagnosis of suspected large-vessel vasculitis

**Running head:**

FDG PET/CT and CECT in LVV

1  
2  
3  
4  
5  
6  
7  
8  
9  
10  
11  
12  
13  
14  
15  
16  
17  
18  
19  
20  
21  
22  
23  
24  
25  
26  
27  
28  
29  
30  
31  
32  
33  
34  
35  
36  
37  
38  
39  
40  
41  
42  
43  
44  
45  
46  
47  
48  
49  
50  
51  
52  
53  
54  
55  
56  
57  
58  
59  
60  
61  
62  
63  
64  
65

# Abstract

## Introduction:

Large-vessel vasculitis (LVV) is a serious illness with potentially life-threatening consequences. <sup>18</sup>F-FDG PET-CT has emerged as a valuable diagnostic tool in suspected LVV, combining the strengths of functional and structural imaging. This study aimed to compare the accuracy of FDG PET-CT and contrast-enhanced CT (CECT) in the evaluation of patients with LVV.

## Materials and Methods:

A retrospective database review for LVV patients undergoing CECT and PET-CT between 2011 to 2016 yielded demographics, scan interval and vasculitis type. Qualitative and quantitative PET-CT analyses included aorta:liver FDG uptake, bespoke FDG uptake distribution scores and vascular maximum standardized uptake values (SUVmax). Quantitative CECT data were assessed wall thickness and mural/lumen ratio. ROC curves were constructed to evaluate comparative diagnostic accuracy and a correlational analysis was conducted between SUVmax and wall-thickness.

## Results:

36 adults (17 LVV, 19 controls) with a mean age (range) 63 (38 – 89) years, of which 17 (47%) were males were included. Time interval between CT and PET was mean (standard deviation (SD)) 1.9 (1.2) months. Both SUVmax and wall-thickness demonstrated a significant difference between LVV and controls, with a mean difference (95% confidence interval (CI)) for SUVmax 1.6 (1.1, 2.0) and wall thickness 1.25 (0.68, 1.83) mm, respectively. These two parameters were significantly correlated ( $P < .0001$ ,  $R = 0.62$ ). The area under the curve (AUC) (95% CI) for SUVmax was 0.95 (0.88-1.00), and for mural thickening was 0.83 (0.66-0.99).

## Conclusions:

1 FDG PET-CT demonstrated excellent accuracy whilst CECT mural thickening showed good  
2 accuracy in the diagnosis of LVV. Both parameters showed a highly significant correlation.  
3  
4 In hospitals without access to FDG PET-CT or in patients unsuitable for PET-CT (e.g.  
5 uncontrolled diabetes) CECT offers a viable alternative for the assessment LVV.  
6  
7

8  
9 **Keywords:**

10 large vessel vasculitis, accuracy, FDG PET-CT, contrast enhanced CT  
11  
12  
13  
14  
15  
16  
17  
18  
19  
20  
21  
22  
23  
24  
25  
26  
27  
28  
29  
30  
31  
32  
33  
34  
35  
36  
37  
38  
39  
40  
41  
42  
43  
44  
45  
46  
47  
48  
49  
50  
51  
52  
53  
54  
55  
56  
57  
58  
59  
60  
61  
62  
63  
64  
65

## Introduction

Large-vessel vasculitis (LVV) is a serious illness with potentially life-threatening consequences including aortic dissection, vessel rupture, blindness and stroke, and diagnosis is often delayed due to non-specific constitutional symptoms. The disease spectrum includes giant cell arteritis (GCA) and Takayasu arteritis (TA). 2-deoxy-2-(18Fluorine) fluoro-D-glucose positron emission tomography-computed tomography (FDG PET-CT) has emerged as a valuable diagnostic tool in patients with suspected LVV, combining the strengths of functional and structural imaging[1].

As a non-specific biomarker of glycolytic metabolism, FDG PET-CT allows earlier detection of LVV, compared to traditional structural imaging, contrast-enhanced CT (CECT) [1, 2, 3]. However, adoption of FDG PET-CT into routine clinical diagnosis of LVV is challenging due to limited scanner availability and higher cost. Moreover, CECT may have a putative role in those unsuitable for FDG PET-CT such as those with uncontrolled diabetes. A cost-effective alternative such as CECT would be highly attractive were it to be shown to be sufficiently accurate. A study by Muto and coworkers from Japan directly compared the accuracy of FDG PET-CT and CECT in patients with LVV[4]. An uncontrolled study by de Boysson and coworkers showed a good concordance between both modalities[5].

We aimed to compare the diagnostic accuracy of FDG PET-CT and CECT in the evaluation of a cohort of patients with suspected LVV. Our purpose was also to validate the use of CECT assessment of vessel mural thickening as a surrogate for metabolic activity in a European population.

# Materials and methods

## Patients

Consecutive adult patients presenting with suspected LVV from December 2011 to March 2016 at a large teaching hospital were identified using an institutional database search. Our control group were patients who were investigated for suspected LVV and who had FDG PET-CT and CECT but eventually were deemed not to have vasculitis by expert clinicians using a combination of clinical evaluation, follow-up, biochemical markers, temporal artery biopsy and imaging studies. Of these patients, only those who underwent both FDG PET-CT and CECT as part of their diagnostic pathway were included. All patients had a minimum of 12-months clinical follow-up. Demographics, interval between CECT and PET-CT, treatment, and type of vasculitis were collated from electronic patient records. The Institutional Review Board issued a waiver for ethics approval and written informed consent for this retrospective anonymous data evaluation.

The final clinical diagnosis of large vessel vasculitis was made by expert rheumatologists based on a combination of clinical findings, biochemical markers, imaging results, exclusion of other plausible diagnoses e.g. paraneoplastic syndromes, and response to standard treatment.

## PET-CT

PET-CT scans were performed on a 64-slice Discovery 690 PET-CT scanner (GE Healthcare, Chalfont St Giles, UK). Serum blood glucose was routinely checked and if > 10 mmol/L, imaging was not performed. Patients fasted for at least 6 hours prior to intravenous injection of <sup>18</sup>F-FDG (dose varied according to patient body weight). 60 minutes after tracer injection PET acquisition from skull vertex to upper thighs was performed. The low-dose, unenhanced CT component of the study was performed using a standardised protocol: 140 kV; 80 mAs;



1 tube rotation time 0.5s per rotation; pitch 6; section thickness 3.75 mm (to match the PET  
2 section thickness). Patients maintained normal shallow respiration during the CT acquisition.  
3  
4 Images were reconstructed using a standard ordered subset expectation maximization  
5 (OSEM) algorithm with CT used for attenuation correction. Both non-attenuation corrected  
6 and attenuation corrected datasets were reconstructed.  
7  
8  
9  
10  
11 All PET-CT studies were re-installed from the institutional PACS archive and analysed using  
12 specialised software (Advantage Windows Version 4.5, GE Healthcare, Chalfont St Giles,  
13 UK). Qualitative and quantitative analyses of PET-CT data were performed including  
14 aorta:liver FDG uptake ratio, bespoke FDG uptake distribution scores and vascular maximum  
15 SUV (SUVmax). Firstly, an uptake score was created based on a technique used by Muto and  
16 coworkers [4]. Essentially, the vascular tree was divided into seven regions and each region  
17 was assigned an ordinal score based on the degree of activity as follows: 0 = no uptake, 1 =  
18 minimal but non-negligible FDG uptake, 2 = clearly increased FDG uptake, and 3 = marked  
19 FDG uptake. A total vascular score ranging from 0 (no vascular FDG uptake in seven  
20 vascular regions) to 21 (vascular FDG uptake = 3 in all seven regions), was calculated for  
21 each patient. Secondly, a bespoke PET score was modified from a study conducted by  
22 Papathanasiou and colleagues from University College of London (modified UCL score) [6].  
23 The score ranged from: 0 = no uptake, 1 = minimal but not negligible uptake, 2 = uptake  
24 more than blood-pool but less than liver uptake, and 3 = uptake higher than liver activity.  
25  
26 Thirdly, an aorta:liver SUVmax ratio was estimated[7]. Analysis of the PET data was  
27 performed by a dual-trained radionuclide radiologist with 5 years of experience in  
28 interpreting FDG PET-CT.  
29  
30  
31  
32  
33  
34  
35  
36  
37  
38  
39  
40  
41  
42  
43  
44  
45  
46  
47  
48  
49  
50  
51  
52  
53  
54  
55

## 56 **CECT**

57  
58  
59  
60  
61  
62  
63  
64  
65

1 Multi-detector CT scans was acquired as per standard protocol on a Siemens Somatom 64  
2 slice scanner (Siemens Healthcare GMBH, Munich , Germany), pitch 1.4, 120kV, 30 s post-  
3  
4 administration of 100 ml of iodinated contrast Niopam 300 (Bracco UK Ltd) and  
5  
6 reconstructed with a 2 mm slice thickness. For the analysis we used a modified approach  
7  
8 derived from the technique of Muto and co-workers to estimate aortic wall-thickness and  
9  
10 mural-lumen ratio[4]. At least three cross-section levels of the descending thoracic aorta were  
11  
12 chosen. At each cross-section, three measurements of the aortic wall thickness were taken (at  
13  
14 12 o'clock, 4 o'clock and 8 o'clock positions), from which an average was then calculated.  
15  
16 At the same position, a horizontal and vertical diameter was taken, and these were averaged  
17  
18 too. This process was repeated at least 3 times down the length of the descending thoracic  
19  
20 aorta, and an average was taken. The CECT analysis was performed by a radiologist with 3  
21  
22 years' experience in CT and checked by a dual-trained consultant radionuclide radiologist  
23  
24 and any disagreements were resolved through consensus.  
25  
26  
27  
28  
29  
30  
31

### 32 **Statistical analysis**

33  
34 Descriptive statistics were used for data from all patients. Continuous variables were  
35  
36 analysed between groups using Student's t-tests. Outcomes were assessed for normality using  
37  
38 the Shapiro-Wilk test and by visual inspection of histograms and Q-Q plots, with  
39  
40 consideration of previous datasets and literature. All patients were included in the analysis,  
41  
42 which were performed on an intention-to-treat basis. We used scatter plots for the visual  
43  
44 examination of between-group variables and to assess spread. Receiver operating  
45  
46 characteristic curves were used to identify appropriate cut-offs between vasculitic and normal  
47  
48 patients, and estimate overall test accuracy using the area under the receiver operating  
49  
50 characteristic (ROC) curve (AUC). We chose to classify the diagnostic accuracy gleaned  
51  
52 from the ROC analysis on a generally accepted classification system based on traditional  
53  
54  
55  
56  
57  
58  
59  
60  
61  
62  
63  
64  
65

1 academic points: 0.90-1 = excellent; 0.80-0.90 = good; 0.70-0.80 = fair; 0.60-0.70 = poor;  
2 and 0.50-0.60 = fail. Statistical significance in all analyses was set at  $P < .05$  (two-tailed). All  
3 statistical analyses were performed using SPSS version 17.0 (Chicago, Illinois, USA) and  
4 vector graphics were created on GraphPad Prism 5.0 for Macintosh (GraphPad Software Inc.,  
5 San Diego, USA).  
6  
7  
8  
9  
10  
11  
12  
13  
14  
15  
16  
17  
18  
19  
20  
21  
22  
23  
24  
25  
26  
27  
28  
29  
30  
31  
32  
33  
34  
35  
36  
37  
38  
39  
40  
41  
42  
43  
44  
45  
46  
47  
48  
49  
50  
51  
52  
53  
54  
55  
56  
57  
58  
59  
60  
61  
62  
63  
64  
65

# Results

## Patient characteristics

The study included 36 adults (17 LVV, 19 controls without LVV), of which 17 (47%) were male. The mean age (range) was 63 (38 – 89) years. The two groups were comparable in terms of baseline characteristics and interval between imaging. The overall time interval between CT and PET-CT was mean (SD) 1.9 (1.2) months. The mean (SD) SUVmax was 3 (1) and mural thickening was 2.37 (1.05) mm. Further details of overall and between-group patient demographics and baseline characteristics are detailed in **Table 1**.

## PET-CT scores

All metabolic parameters including bespoke uptake scores were significantly different ( $P < .0001$ ) between the LVV and control groups (**Figure 1**). The Muto and modified UCL scores demonstrated a significant difference between groups with mean differences (95% CI) as 12.0 (8.7 to 15.3) and 2.1 (1.7 to 2.5), respectively ( $P < .0001$ ) (**Figure 2**). A Muto score cut-off of 3.5 resulted in a sensitivity and specificity of 79% and 94%, respectively. A UCL score cut-off of 1.5 resulted in a sensitivity and specificity of 89% each. The aorta-liver SUVmax ratio proved to be a highly specific measure, with only one patient from the control group with a ratio  $> 1$ . Using an aorta:liver SUVmax ratio  $> 1$  as a cut-off resulted in a sensitivity of 76%, a specificity of 100%, a positive predictive value (PPV) of 100% and a negative predictive value (NPV) of 83% (**Figure 3**).

## CECT scores

Mural thickening and mural-lumen ratios were significantly different between the LVV and control groups with a mean difference (95% CI): 1.26 (0.68 to 1.84) mm, and 0.04 (0.01 to

1  
2  
3  
4  
5  
6  
7  
8  
9  
10  
11  
12  
13  
14  
15  
16  
17  
18  
19  
20  
21  
22  
23  
24  
25  
26  
27  
28  
29  
30  
31  
32  
33  
34  
35  
36  
37  
38  
39  
40  
41  
42  
43  
44  
45  
46  
47  
48  
49  
50  
51  
52  
53  
54  
55  
56  
57  
58  
59  
60  
61  
62  
63  
64  
65

0.11) mm, respectively (**Table 1, Figure 1**). There was, however, a greater overlap of individual CECT derived scores compared to metabolic parameters.

### **ROC curve analysis and correlation between PET-CT and CECT parameters**

The ROC curves demonstrated excellent accuracy for metabolic parameters and good accuracy for the morphological variables (**Figure 4**). The AUC (95% CI) for the modified UCL score was 0.93 (0.82 to 1.00) and for the Muto score was 0.96 (0.92 to 1.00). The AUC for mural thickening was 0.83 (0.66 to 0.99) and for mural-lumen ratio was 0.84 (0.69 to 0.99). There was a significant correlation between SUVmax and wall-thickness with a high effect size ( $P < .0001$ ;  $R = 0.62$ ) (**Figure 5**).

## Discussion

In this study, FDG uptake and wall-thickness demonstrated a highly significant correlation, and a high degree of accuracy in discriminating between LVV and controls. To the best of our knowledge, this is the first report validating the utility and comparability of morphological and metabolic surrogates of disease activity in LVV in a European population.

All metabolic parameters including the bespoke vascular uptake scores were significantly different when comparing the LVV and control groups. These findings are in agreement with previous literature regarding the estimated sensitivity of FDG PET-CT in the diagnosis of LVV. FDG PET has a reported sensitivity of 80 - 92% and specificity of 89 - 100% in patients with LVV, with higher accuracy in GCA than in TA[6,8,9]. Existing American College of Rheumatology 1990 classification criteria for GCA, a composite of clinical, serological and histopathological items, are not suitable for diagnosis of GCA in clinical practice [10,11]. The benefits of FDG PET-CT over these diagnostic criteria include a higher sensitivity and accuracy, and the non-invasive nature of the test. Indeed, recent international guidelines for the non-oncological use of FDG PET-CT in inflammation list primary evaluation of vasculitides as a major indication[12]. Based on a meta-analysis of 12 studies (n=283), the guideline authors estimated the sensitivity and specificity of FDG PET-CT in LVV at 80% and 89%, respectively[12]. European League Against Rheumatism (EULAR) guidelines on LVV recommend FDG PET as an alternative to MRI for establishing the diagnosis but reiterate that lack of availability and formal validation is a limitation to the widespread endorsement in day-to-day practice[13]. In their absence, conventional angiography was recommended but this is unlikely to pick up early disease. A recent joint guideline by the European Association of Nuclear Medicine and the Society for Nuclear Medicine and Molecular Imaging concluded that based on available data, FDG PET-CT and

1 CT angiography may have an important role in the diagnosis of LVV but that additional  
2 randomised studies are needed to support this[14]. This highlights once again the evolving  
3 nature of evidence in this field.  
4  
5  
6

7  
8  
9 Although the bespoke FDG uptake scores demonstrated a high accuracy in our study, they are  
10 cumbersome to calculate and not practicable in routine clinical practice. Moreover, despite  
11 the high overall accuracy, there was still an overlap between disease and control groups when  
12 it came to individual scores. Indeed, the aorta:liver SUVmax ratio proved to be the simplest  
13 and most robust metabolic parameter with a 100% specificity and 100% NPV, and a higher  
14 overall accuracy than the bespoke scores. In day-to-day clinical practice, simple parameters  
15 are easier to interpret, whereas high specificity is important for avoiding false-positives due  
16 to atherosclerosis related FDG activity, particularly in this age group. Our results concur with  
17 Hautzel and co-workers' who showed that using a cut-off of aorta:liver SUVmax >1.0 in  
18 GCA resulted in a sensitivity, specificity, and accuracy of 89%, 95% and 94%[6]. In their  
19 study, the estimated specificity using the aorta:liver ratio was higher when compared to a  
20 meta-analysis (n=283) performed by Besson and co-workers[ 7].  
21  
22  
23  
24  
25  
26  
27  
28  
29  
30  
31  
32  
33  
34  
35  
36  
37  
38  
39  
40

41 CECT parameters showed a good accuracy in estimating the presence of LVV. Wall-  
42 thickness showed an area under the ROC curve of 0.83 (95% CI: 0.66-0.99). Unsurprisingly,  
43 in comparison to FDG PET-CT, this was less accurate most likely due to the metabolic-  
44 morphological diagnostic gap which is a well-recognised phenomenon in the literature. These  
45 findings agree with de Boysson and coworkers which show a lower but good accuracy for  
46 contrast enhanced CT in LVV[5]. Although ours was a controlled study with a final  
47 diagnosis of LVV, our study design also had a degree of incorporation bias: since the  
48 reference standard (clinical diagnosis) incorporated the PET-CT findings, any error in the  
49  
50  
51  
52  
53  
54  
55  
56  
57  
58  
59  
60  
61  
62  
63  
64  
65

PET-CT would have biased the reference standard in the same direction. In other words the correlation between error in PET-CT and error in reference standard could have resulted in an overestimation of PET-CT accuracy and underestimation of CECT accuracy. CECT may be a valuable alternative in patients unsuitable for FDG PET-CT such as uncontrolled diabetes, or in centres without reliable access to PET-CT. Another potential application for CECT could be patients already on glucocorticoid treatment because this is known to adversely affect the accuracy of FDG PET-CT in detecting LVV. For example, a study of 61 patients demonstrated that the diagnostic accuracy of FDG PET-CT was only 65% in patients on active treatment versus 93% in those who were treatment-naive ( $P=0.006$ )[8]. Also, a study by Blockmans et al. failed to show an additional value of serial PET scans post-treatment (at 3 and 6 months), with no further reduction in large-vessel FDG uptake after 3 months of therapy[13]. This is likely due to effects of glucocorticoid therapy on relevant cellular functions such as glucose uptake. In such a scenario, FDG PET would not be useful in titrating long-term therapy as it would be less sensitive to “flares” of inflammation within the vascular wall occurring during ongoing glucocorticoid therapy. It may be postulated that CECT mural thickening may fill this gap, but there are no current studies to validate this hypothesis. Lastly, in our experience there is a relatively steep learning curve for FDG PET-CT in terms of test reliability and validity in diagnosing LVV (personal opinion, no data available).

In our study, morphological and metabolic parameters were significantly correlated ( $P < .0001$ ). This adds weight to the suggestion that CECT morphological parameters could be informative surrogates for LVV detection where PET-CT, the more sensitive test, is unavailable.



1  
2  
3  
4  
5  
6  
7  
8  
9  
10  
11  
12  
13  
14  
15  
16  
17  
18  
19  
20  
21  
22  
23  
24  
25  
26  
27  
28  
29  
30  
31  
32  
33  
34  
35  
36  
37  
38  
39  
40  
41  
42  
43  
44  
45  
46  
47  
48  
49  
50  
51  
52  
53  
54  
55  
56  
57  
58  
59  
60  
61  
62  
63  
64  
65

There are limitations to our study including its retrospective nature and relatively small sample size. However, we tried to obviate the effect of selection bias by including a control group. A degree of incorporation bias may have overestimated PET-CT accuracy and underestimated CECT accuracy. In future, volumetric metabolic parameters may provide a more comprehensive estimate of disease burden at baseline. Assessment of treatment response on CECT and PET warrants further evaluation in a prospective study.

### **Conclusions**

FDG PET-CT demonstrated excellent accuracy whilst CECT mural thickening showed good accuracy for the diagnosis of LVV. Both parameters showed a highly significant correlation. In medical centres without access to FDG PET-CT or in patients unsuitable for PET-CT (e.g. uncontrolled diabetes), CECT may offer a good diagnostic alternative in the assessment of suspected LVV.

## References

1. Vaidyanathan S, Patel CN, Scarsbrook AF, et al. FDG PET/CT in infection and inflammation--current and emerging clinical applications. Clin Radiol 2015; 70(7): 787-800.
2. Cao Q, Chen W. FDG PET Imaging of Large-Vessel Vasculitis. PET Clin 2012; 7(2): 227-232.
3. Treglia G, Mattoli MV, Leccisotti L, et al. Usefulness of whole-body fluorine-18-fluorodeoxyglucose positron emission tomography in patients with large-vessel vasculitis: a systematic review. Clin Rheumatol 2011; 30(10): 1265-1275.
4. Muto G, Yamashita H, Takahashi Y, et al. Large vessel vasculitis in elderly patients: early diagnosis and steroid-response evaluation with FDG-PET/CT and contrast-enhanced CT. Rheumatol Int 2014; 34(11): 1545-1554.
5. de Boysson H, Dumont A, Liozon E, et al. [Giant-cell arteritis: concordance study between aortic CT angiography and FDG-PET/CT in detection of large-vessel involvement.](#) Eur J Nucl Med Mol Imaging. 2017 Dec;44(13):2274-2279.
6. Papathanasiou ND, Du Y, Menezes LJ, et al. 18F-Fludeoxyglucose PET/CT in the evaluation of large-vessel vasculitis: diagnostic performance and correlation with clinical and laboratory parameters. Br J Radiol 2012; 85(1014): e188-94.
7. Hautzel H, Sander O, Heinzl A, et al. Assessment of large-vessel involvement in giant cell arteritis with 18F-FDG PET: introducing an ROC-analysis-based cutoff ratio. J Nucl Med 2008; 49(7): 1107-1113.
8. Besson FL, Parienti JJ, Bienvenu B, et al. Diagnostic performance of (1)(8)F-fluorodeoxyglucose positron emission tomography in giant cell arteritis: a systematic review and meta-analysis. Eur J Nucl Med Mol Imaging 2011; 38(9): 1764-1772.
9. Fuchs M, Briel M, Daikeler T, et al. The impact of 18F-FDG PET on the management of patients with suspected large vessel vasculitis. Eur J Nucl Med Mol Imaging 2012; 39(2):

344-353.

1  
2  
3  
4  
5  
6  
10. Hunder GG, Arend WP, Bloch DA, et al. The American College of Rheumatology 1990  
criteria for the classification of vasculitis. Introduction. *Arth Rheum* 1990; 33(8): 1065-1067

7  
8  
9  
10  
11  
12  
13  
11. Rao JK, Allen NB, Pincus T. Limitations of the 1990 American College of Rheumatology  
classification criteria in the diagnosis of vasculitis. *Ann Intern Med.* 1998 Sep 1;129(5):345-  
52.

14  
15  
16  
17  
18  
12. Jamar F, Buscombe J, Chiti A, et al. EANM/SNMMI guideline for 18F-FDG use in  
inflammation and infection. *J Nucl Med* 2013; 54(4): 647-658.

19  
20  
21  
22  
23  
13. Mukhtyar C, Guillevin L, Cid MC, et al. EULAR recommendations for the management  
of large vessel vasculitis. *AnnRheum Dis* 2009; 68(3): 318-323.

24  
25  
26  
27  
28  
29  
30  
31  
32  
14. Slart RHJA, Glaudemans AWJM, Chareonthaitawee P et al. FDG-PET/CT(A) imaging in  
large vessel vasculitis and polymyalgia rheumatica: joint procedural recommendation of the  
EANM, SNMMI, and the PET Interest Group (PIG), and endorsed by the ASNC. *Eur J Nucl  
Med Mol Imaging.* 2018 Jul;45(7):1250-1269.

33  
34  
35  
36  
37  
38  
39  
40  
41  
42  
43  
44  
45  
46  
47  
48  
49  
50  
51  
52  
53  
54  
55  
56  
57  
58  
59  
60  
61  
62  
63  
64  
65  
15. Blockmans D, De Ceuninck L, Vanderschueren S, et al. Repetitive 18-  
fluorodeoxyglucose positron emission tomography in isolated polymyalgia rheumatica: a  
prospective study in 35 patients. *Rheumatology.* 2007;46(4):672-7.

## Figure and Table Legends

### Figure 1:

Scatter plots of standard metabolic and morphological parameters in vasculitic and normal patients. SUVmax and SUVmax/liver ratio demonstrating a significant mean difference between LVV and controls, and wall-thickness and ratio show significant differences. Each symbol represents one patient. The error bars denote arithmetic mean and 95% confidence intervals.

### Figure 2:

Bespoke vascular FDG uptake scores in vasculitis and normal patients demonstrating significant differences. Each symbol represents once patient. The error bars denote arithmetic mean and 95% confidence intervals.

### Figure 3:

Stacked bar graph demonstrating the proportion of vasculitis patients diagnosed/excluded by using a binary cut-off of the ratio of the SUVmax of aorta and background liver. The high negative predictive value and specificity of the test are apparent by the complete exclusion of disease patients in those with an aorta:liver SUVmax ratio  $<1$  seen in the right-side bar.

### Figure 4:

Receiver operating characteristics curves for metabolic and morphological parameters demonstrating excellent accuracy for the former and good accuracy for the latter. The top two panels represent SUVmax/liver ratio and a bespoke FDG vascular uptake score with area under the curve (AUC) of 0.97 each. The bottom two panels are derived from contrast enhanced CT and demonstrate an AUC of 0.83 for wall-thickness and 0.84 for the mural-lumen ratio. Please refer to the methods section for the derivation of these variables.

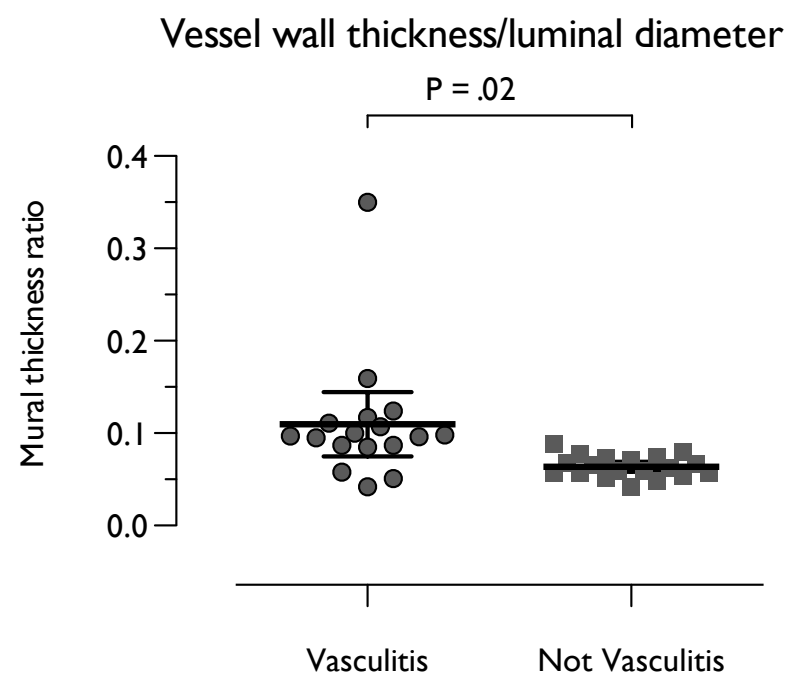
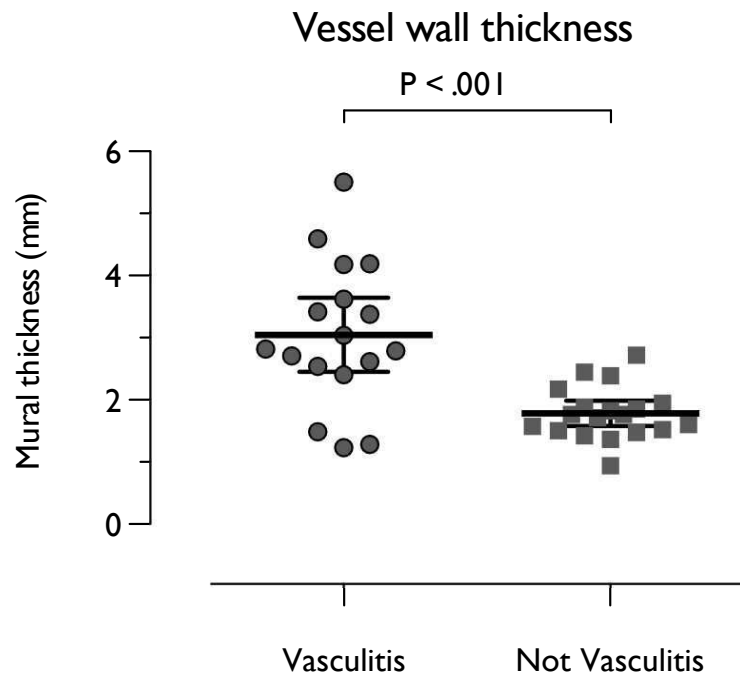
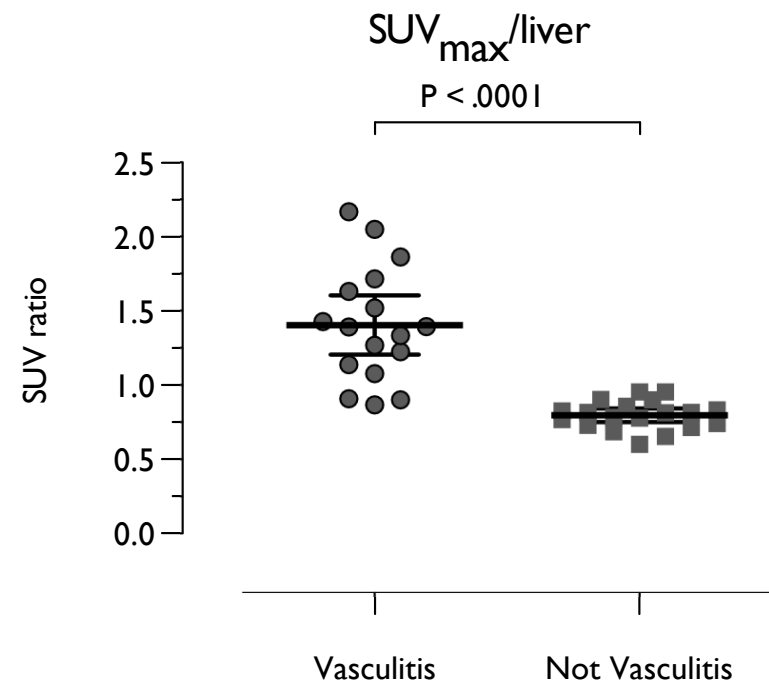
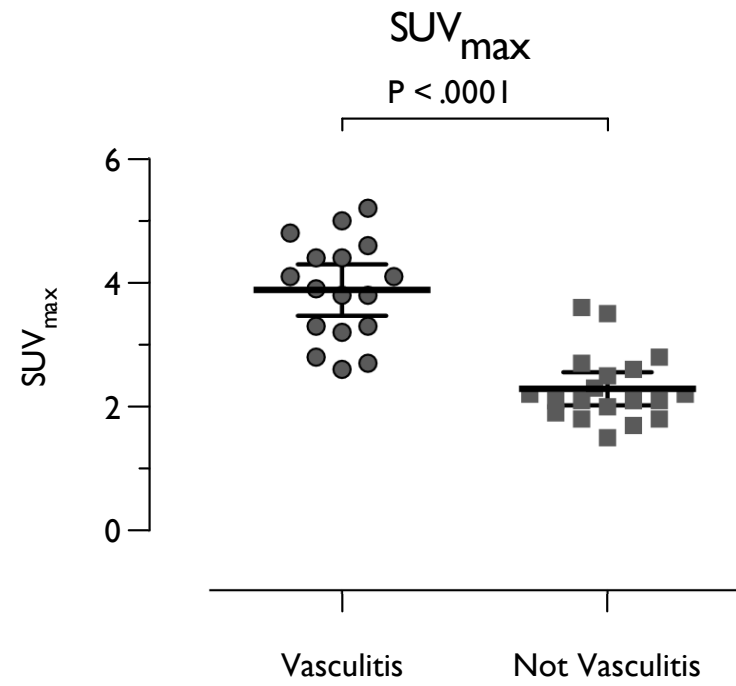
### Figure 5:

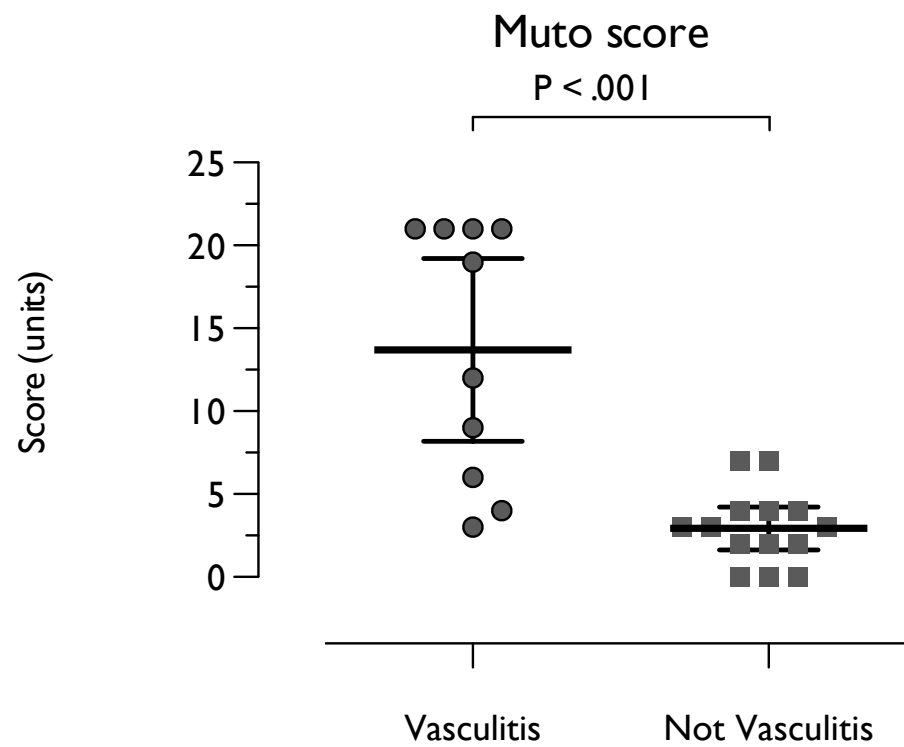
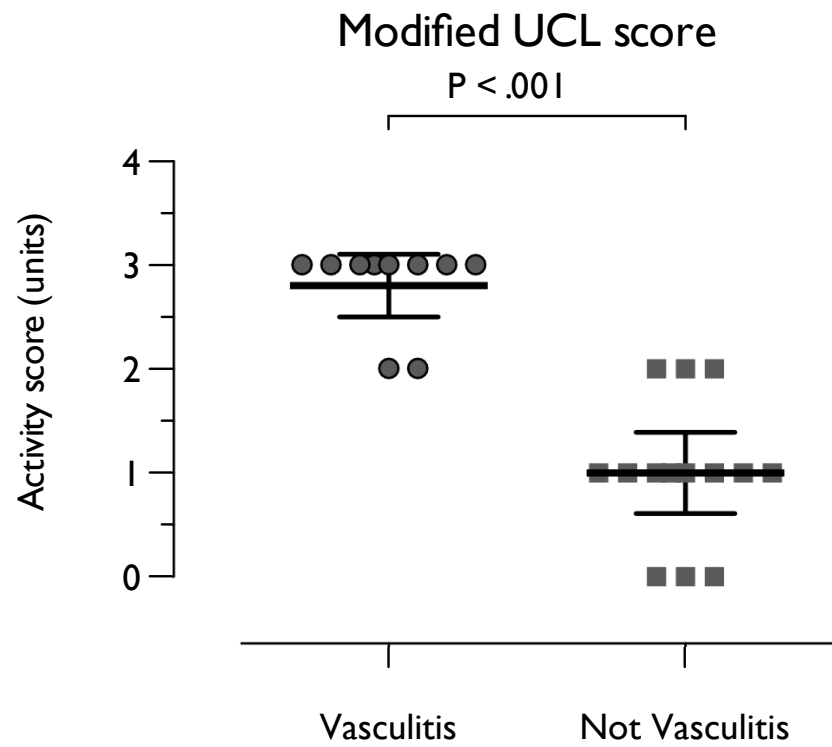
A correlation is demonstrated between SUVmax and wall-thickness indicating a high degree of agreement between FDG PET and CECT parameters.

**Table 1:** Demographic, PET-CT-derived and CT-derived parameters of vasculitis and non-vasculitis patients

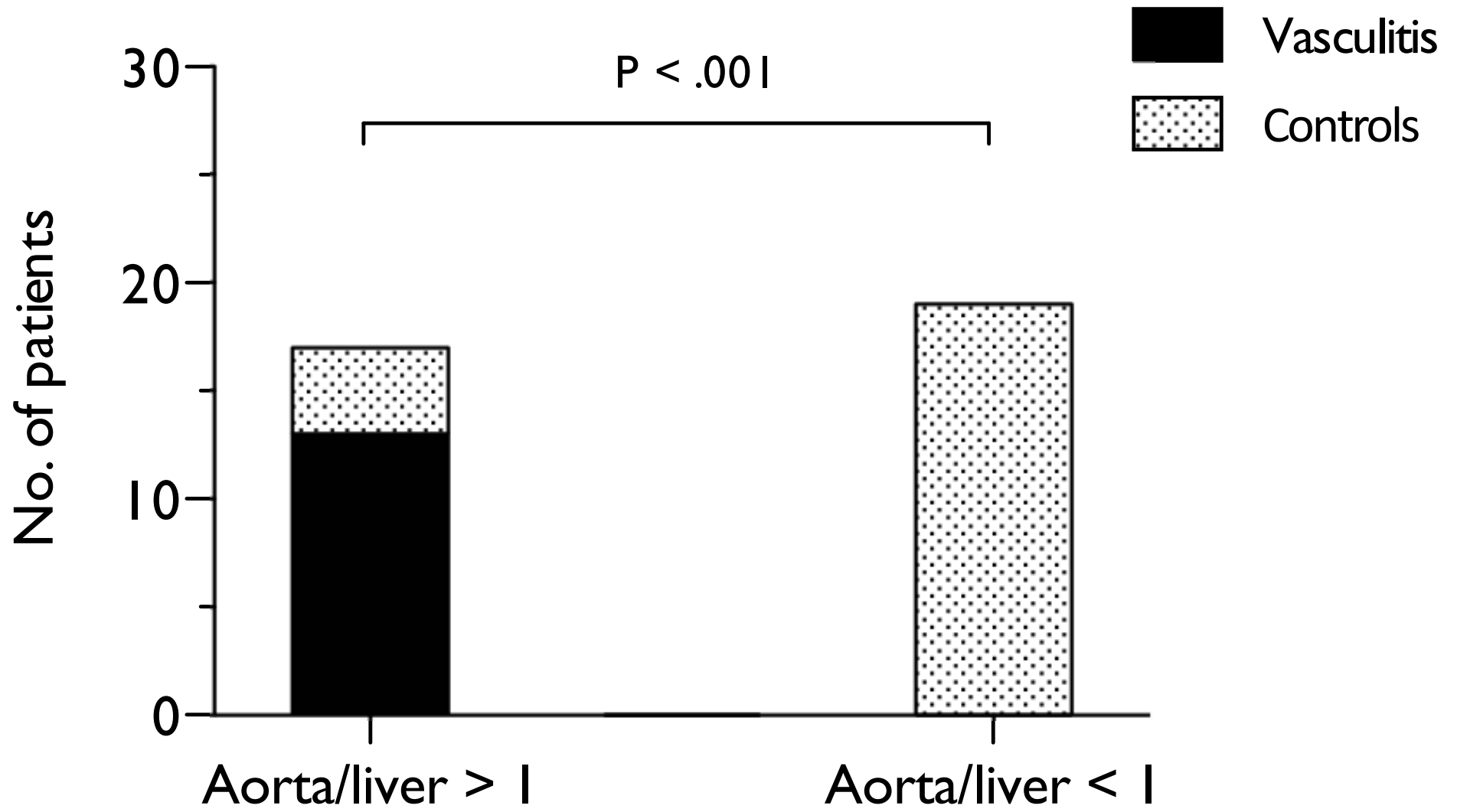
1  
2  
3  
4  
5  
6  
7  
8  
9  
10  
11  
12  
13  
14  
15  
16  
17  
18  
19  
20  
21  
22  
23  
24  
25  
26  
27  
28  
29  
30  
31  
32  
33  
34  
35  
36  
37  
38  
39  
40  
41  
42  
43  
44  
45  
46  
47  
48  
49  
50  
51  
52  
53  
54  
55  
56  
57  
58  
59  
60  
61  
62  
63  
64  
65

Figure





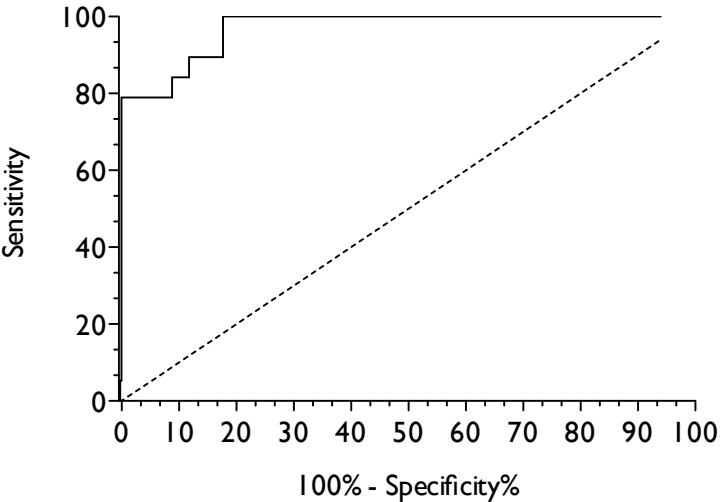
Figure





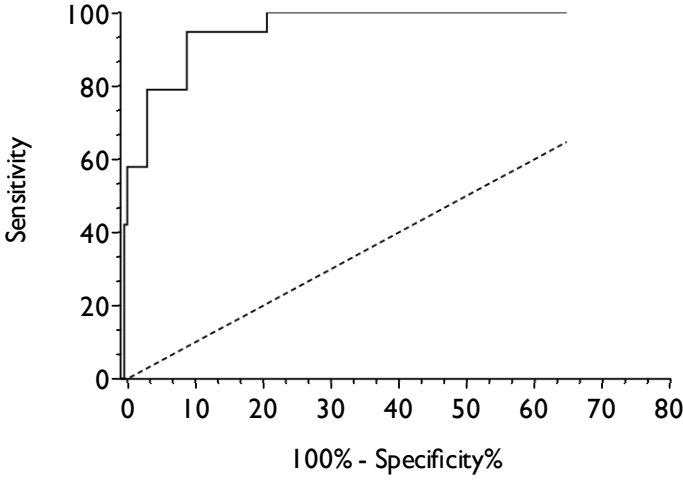
Figure

ROC of SUV<sub>max</sub>/liver



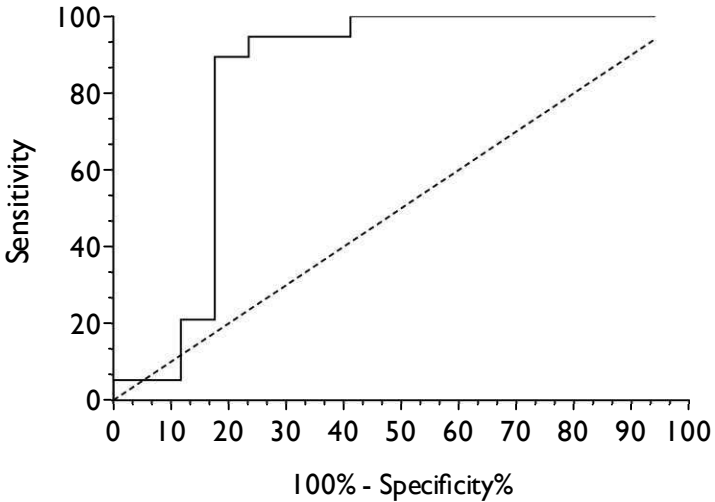
	Results
Area	0.9706
Std. Error	0.02259
95% confidence interval	0.9263 to 1.015
P value	< 0.0001

ROC of Muto score



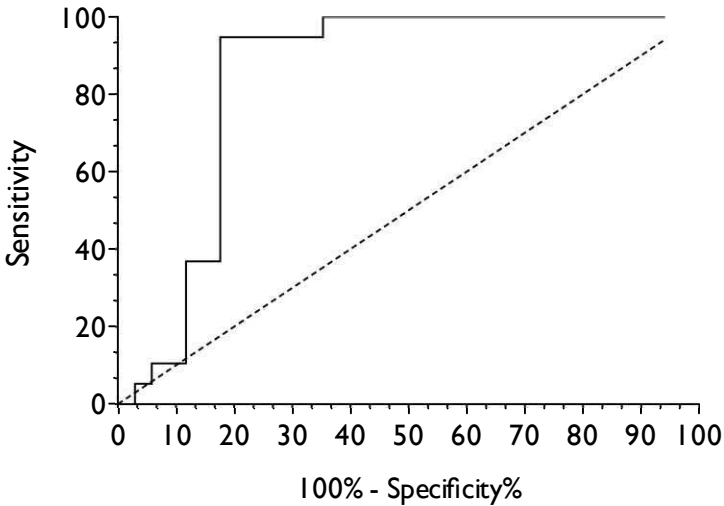
	Results
Area	0.9690
Std. Error	0.02435
95% confidence interval	0.9213 to 1.017
P value	< 0.0001

ROC of wall thickness



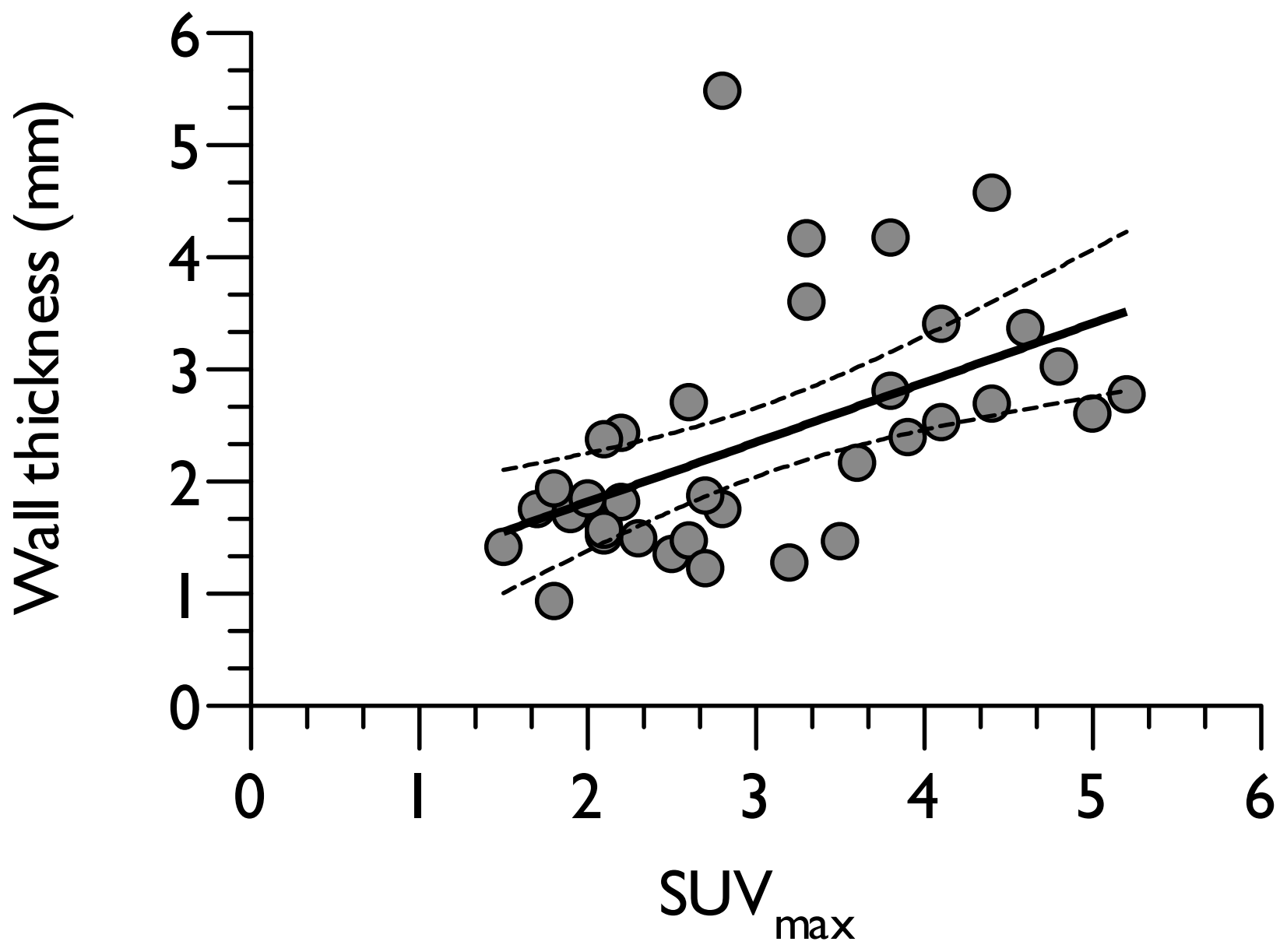
	Results
Area	0.8266
Std. Error	0.08379
95% confidence interval	0.6624 to 0.9909
P value	0.0008348

ROC of wall thickness ratio



	Results
Area	0.8437
Std. Error	0.07946
95% confidence interval	0.6879 to 0.9994
P value	0.0004398

$R = 0.62; P < .0001$



**Table 1:** Demographic, PET-CT-derived and CT-derived parameters of vasculitis and non-vasculitis patients

Variable	All (N = 36)	Vasculitis (N = 17)	Non- vasculitis (N = 19)	<i>P</i> -value for difference*
Age, years, mean (range)	63 (38 – 89)	64 (38 – 89)	63 (42 – 85)	.79
Sex, male, number (%)	17 (47)	5 (29)	12 (71)	.04†
CT to PET time, months, mean (SD)	1.9 (1.2)	2.1 (1.3)	1.7 (1.0)	.42
PET positive Hautzel, number (%)	15 (42)	14 (93)	1 (7)	<.0001§
Modified UCL score, mean (SD)	1.7 (1.2)	2.8 (0.4)	0.7 (0.7)	<.0001§
Muto score, mean (SD)	7.6 (7.7)	13.9 (6.7)	1.9 (2.0)	<.0001§
SUVmax, mean (SD)	3.0 (1.0)	3.9 (0.8)	2.3 (0.5)	<.0001§
SUVmax/MBP, mean (SD)	1.4 (0.5)	1.9 (0.5)	1.1 (0.1)	<.0001§
SUVmax/liver, mean (SD)	1.1 (0.4)	1.4 (0.4)	0.8 (0.1)	<.0001§
Wall thickness, mm, mean (SD)	2.37 (1.05)	3.03 (1.16)	1.77 (0.42)	<.001‡
Aorta diameter, mm, mean (SD)	28.64 (4.44)	29.45 (5.37)	27.93 (3.39)	.31
Wall/Diameter ratio, mean (SD)	0.08 (0.05)	0.11 (0.07)	0.01 (0.00)	.02†
<p>* P values derived from Student's t-test for scale variables and Chi-squared test for categorical variables.  † P &lt; .05  ‡ P &lt; .001  § P &lt; .0001  Abbreviations –PET: positron emission tomography, CT: computed tomography, SD: standard deviation, UCL: University College London score, SUVmax: standardized uptake value maximum; PET positive Hautzel, aorta:liver SUVmax ratio &gt; 1; MBP, mediastinal blood pool. Details of the PET-CT and CT scoring systems are explicated in the methods section.</p>				