

## PDF hosted at the Radboud Repository of the Radboud University Nijmegen

The following full text is a publisher's version.

For additional information about this publication click this link.

<http://hdl.handle.net/2066/23545>

Please be advised that this information was generated on 2017-12-05 and may be subject to change.



# Combined preoperative irradiation and direct postoperative 5-fluorouracil without negative effects on early anastomotic healing in the rat colon

J. Biert<sup>a,\*</sup>, T. Wobbes<sup>a</sup>, J. Hoogenhout<sup>b</sup>, B. de Man<sup>a</sup>, T. Hendriks<sup>a</sup>

<sup>a</sup>Department of Surgery, University Hospital Nijmegen, P.O. Box 9101, 6500 HB Nijmegen, The Netherlands

<sup>b</sup>Department of Radiotherapy, University Hospital Nijmegen, Nijmegen, The Netherlands

Received 14 March 1996; revised 13 September 1996; accepted 19 September 1996

## Abstract

**Background and purpose:** Preoperative irradiation with direct postoperative chemotherapy could benefit patients undergoing surgery for colorectal cancer. This study was designed to examine, in an experimental model, if such treatment is feasible without detrimental effects on early anastomotic healing.

**Material and methods:** A colonic segment was irradiated (25 Gy) in 3 groups ( $n=10$  each) of male Wistar rats. After 5 days, a colonic resection was performed with anastomotic construction; only the distal limb consisted of irradiated bowel. Postoperatively, animals received daily intraperitoneal 5-fluorouracil (5-FU, group I/CH: 17.5 mg/kg; group I/CL: 12.5 mg/kg) or saline (group I). Three additional groups were treated similarly, but with sham-irradiation: CH, CL and C, respectively. All rats were killed 7 days postoperatively. Parameters measured were: weight, serum albumin and protein, and anastomotic bursting pressure, breaking strength and hydroxyproline content.

**Results:** Body weight was diminished significantly in rats receiving chemotherapy. Serum albumin and protein was significantly lower in irradiated groups. At sacrifice, 40% of I/CH rats had functional rectal stenosis. The average bursting pressure ( $P=0.0005$ ) and the average breaking strength ( $P=0.012$ ) were only reduced significantly in the CH group. The anastomotic hydroxyproline content was significantly higher in the I/CH and I/CL groups vs. the control group.

**Conclusion:** High-dose direct postoperative 5-FU leads to reduced anastomotic strength. Although the combination of preoperative irradiation (25 Gy) and direct postoperative high-dose 5-FU does not reduce early anastomotic strength, some stenosis may occur. The combination of preoperative irradiation and low-dose 5-FU has no such effect.

**Keywords:** Rat; Healing; Radiotherapy; Chemotherapy; Anastomosis; Colon

## 1. Introduction

Local recurrence of colorectal cancer and metastatic disease after surgery are common entities; they are due to microscopic disease left after resection, peri-operatively spilled tumor cells or unrecognised metastatic disease at the time of operation. Over the last decades numerous studies have been performed, with limited success to determine the role of adjuvant therapy in improving the results of surgery. Radiotherapy and chemotherapy are commonly used tools for adjuvant treatment, and there exists increasing in combining both modalities [23].

The best interest for radiation treatment seems to be a

high-dose preoperative application [21]. The potential advantages for such a schedule are many. Firstly, irradiation is delivered to a well vascularized tumor which is well oxygenized, providing a better therapeutic effect. Secondly, postoperative intra-abdominal adhesions, resulting in radiation side effects to the fixed small bowel, have not been formed. Thirdly, the operative wound after surgery would require a much larger irradiation field, giving rise to volume effects. Finally, implantation of tumor cells spilled during surgery will be less because they are less viable, and because the tumor is reduced in size.

Postoperative chemotherapy is believed to be effective in the attack on viable cancer cells, resulting in decreased local recurrence, increased disease-free interval and increased survival both clinically [3,25] and experimentally [19]. 5-Fluorouracil (5-FU) is still considered to be the

\*Corresponding author.

most effective single agent in the use against colonic cancer cells [14,16].

Separately, both types of adjuvant therapy have been thought to endanger the healing of bowel anastomoses [8,13,17,20,22,27,28]. Early disturbances of anastomotic healing may lead to leakage, peritonitis and death, thus forming a threat which might limit their use. However, the precise magnitude of these side-effects is still under investigation. Irradiation has long been considered to be detrimental for colon anastomotic repair [13,17,20,22], but recent data from others [1,12,21,29] and also from our own laboratory (Biert, J., Hoogenhout, J., Wobbes, T. and Hendriks, T. High-dose preoperative irradiation without detrimental effect on early anastomotic repair in the rat colon. *Radiat. Res.*, in press) indicate that it can be applied without negative effects on early anastomotic strength or anastomotic integrity. With respect to chemotherapy, it has been shown that in the rat early bowel anastomotic repair is endangered by a high dose of 5-FU, given daily for 1 week from the day of the operation onwards [8,28]. If treatment is limited to the first 3 days, a high dose can be considered safe [11,26], unless 5-FU is used together with other agents [27]. Lower doses of 5-FU are supposedly less dangerous for colon anastomotic repair.

However, the possibilities for combining two treatment modalities may be limited due to amplification of side-effects [4]. So far, the possible interactions of preoperative irradiation and direct postoperative chemotherapy with respect to their effects on early anastomotic healing have not been investigated. Therefore, we examined the effect of combined preoperative irradiation with a dose of 25 Gy and direct postoperative 5-FU, administered intraperitoneally in a high or low dose, on anastomotic healing in the rat colon. The effect of combined treatment was compared to that of either single treatment modality.

## 2. Materials and methods

### 2.1. Animals

Sixty young adult male outbred Wistar/Cpb:WU rats, body weight  $246 \pm 16$  g, were used. They received water and standard laboratory chow (diet AM II, Hope Farms, Woerden, The Netherlands) ad libitum. The rats were randomly divided into 6 groups of 10 animals each. A part of the colon was (sham-)irradiated preoperatively with 25 Gray X-rays; after 5 days, a colonic resection was performed with anastomotic reconstruction. Postoperatively rats received 5-fluorouracil (5-FU) intraperitoneally daily, until sacrifice at day 7 after surgery. Rats in group C served as sham-treated controls (sham-irradiation plus postoperative saline). Groups CH and CL were sham-irradiated and received postoperative high- and low-dose chemotherapy (dose: see below), respectively. Group I was irradiated and received postoperative saline, while groups

I/CH and I/CL were treated by irradiation and postoperative high- and low-dose chemotherapy, respectively.

This study was approved by the Animal Ethics Review Committee of the Faculty of Medicinal Sciences, University of Nijmegen.

### 2.2. Irradiation, dosimetry

Before irradiation the animals were anaesthetized with intraperitoneal sodium pentobarbital. The irradiation procedure was based on techniques developed in a prior experiment (Biert, J., Hoogenhout, J., Wobbes, T. and Hendriks, T. High-dose preoperative irradiation without detrimental effect on early anastomotic repair in the rat colon. *Radiat. Res.*, in press). In order to ascertain that the same tissue area was irradiated in each rat, and to mark this area for subsequent surgery, a laparotomy was performed. The colonic segment to be irradiated, 1–3.2 cm proximal from the rectoperitoneal fold was marked by a serosal stitch at its proximal border. The irradiated area measured  $2.2 \times 0.5$  cm (Fig. 1). The adjacent bowel and other organs were covered with a lead cone and the rest of the body was also shielded with lead (thickness 2.5 mm).

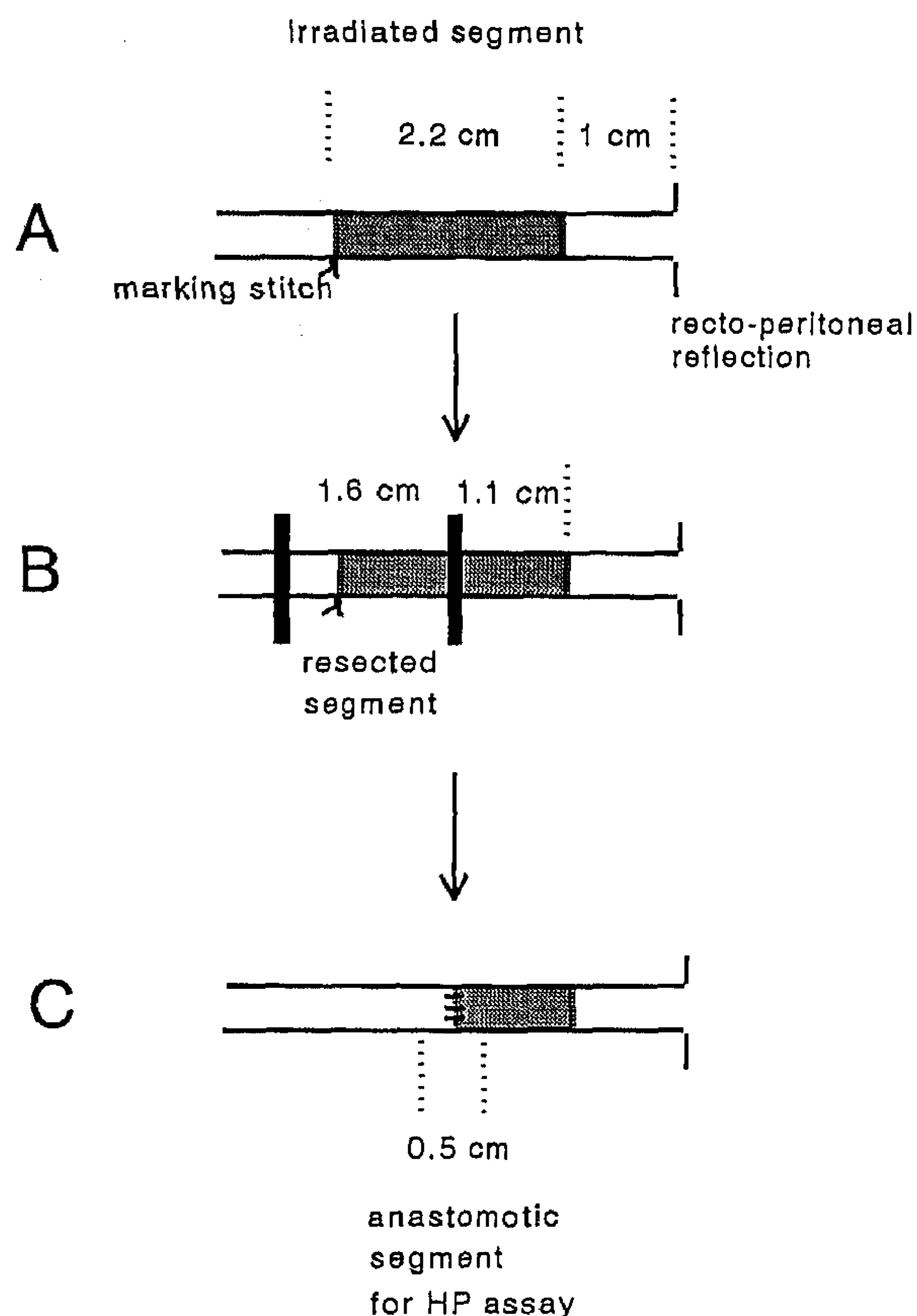


Fig. 1. Schematic representation of experimental procedure. (A) First laparotomy plus irradiation of colonic segment. (B) Second laparotomy plus resection of a 1.6-cm segment, and construction of anastomosis with only the distal limb consisting of irradiated tissue. (C) At sacrifice: sample used for hydroxyproline analysis.

Radiation dosimetry was performed by means of thermoluminescent dosimeters and film densitometry in separate animals. Irradiation was performed with a 250 kV X-ray unit with a 1 mm Cu filter (target/colon distance: 25 cm). The dose rate was 1.29 Gy/min. Thus, all rats in groups I/CH, I/CL and I received a dose of 25 Gy.

### 2.3. Operative procedure, chemotherapy

After 5 days animals were anaesthetized again with intraperitoneal sodium pentobarbital. The median laparotomy wound was opened and a 1.6-cm colonic segment was resected. This segment was identified by the marking stitch left during the initial laparotomy and measured 0.5 cm in proximal and 1.1 cm in distal direction (Fig. 1). Thus, the proximal limb to be used for the anastomosis consisted of non-irradiated tissue, while the first 1.1 cm of the distal limb had been irradiated (groups I/CH, I/CL and I). Continuity was restored by an inverting one-layer end-to-end anastomosis with eight interrupted monofilament sutures (Ethilon 8×0, Ethicon, Norderstedt, Germany) using microsurgical techniques. Fascia and skin were closed with a catgut running suture and staples, respectively.

Chemotherapy was started immediately after operation, and the intraperitoneal way of administration was chosen on the basis of earlier work of our group [26,28]: 5-FU, administered intraperitoneally from the day of operation onwards in a daily dose of 20 mg/kg body weight — which is the maximum tolerated dose — strongly reduced strength and accumulation of collagen in 7 days old intestinal anastomoses in the rat [28]. Based on these findings, groups I/CH and CH (high-dose groups) now received 17.5 mg 5-FU/kg body weight intraperitoneally in saline in a single dose every day until sacrifice. Groups I/CL and CL (low-dose groups) received 12.5 mg FU/kg body weight daily, while in groups I and C the same volume of saline was given every day as in group I/CH (sham medication treatment).

### 2.4. Analytical procedures

The condition of the animals was monitored and weight was measured daily. Seven days after the operation the rats were killed by cardiac puncture. A blood sample was taken for albumin and protein measurement to monitor general nutritional condition. The abdomen was inspected for adhesions, rectal stenosis, abscesses or other abnormalities. The anastomoses were resected en bloc. Healing was assessed by measurement of anastomotic strength and hydroxyproline content [10]. In order to determine anastomotic strength, the anastomotic segment was washed in saline and connected to an infusion pump on one side while the other side was clamped. A manometer was connected by a side line. The bursting pressure was measured by raising the intraluminal pressure by infusion

of a methylene blue/saline solution at a rate of 2 ml/min. The procedure was performed in water for better visualisation of the bursting site. The bursting pressure was defined as the maximal intraluminal pressure the segment resisted, expressed in mmHg. The bursting site was noted. The breaking strength of the segment, as a measure of the resistance to longitudinal forces, was measured immediately after determination of the bursting pressure [27]. The segment was placed in a tensiometer that provided a constantly increasing distraction. The peak force (in g) necessary to induce total disruption of the segment was taken as the breaking strength. The breaking site was noted. After this, adhesions and fat tissue were removed from the segment and a 0.5 cm sample containing both sides of the suture line was collected (Fig. 1) and stored in liquid nitrogen for hydroxyproline assay.

Anastomotic samples, and control segments removed at operation, were weighed, lyophilized, and pulverized. The hydroxyproline content, as a measure for collagen, was measured by HPLC after hydrolysis with 6 N HCl and derivatisation with dabsylchloride.

Differences between the control group and the five experimental groups were tested for significance using a two-tailed Mann-Whitney test. To correct for the fact that multiple comparisons were made, pairwise comparisons were done using a level of significance of  $\alpha' = 2\alpha/k$ , where  $k$  is the total number of pairwise comparisons. Thus, differences between groups were considered significant ( $\alpha = 0.05$ ) at  $P < \alpha'$ , where  $\alpha' = 0.02$ .

## 3. Results

### 3.1. General observations

All animals tolerated chemotherapeutic treatment and/or radiotherapy well. Moderate to severe diarrhea was apparent in all but the C groups. One animal in the I/CH group died on the sixth postoperative day — obduction revealed no abnormalities. One rat in group CL was moribund at the time of sacrifice. Functional rectal stenosis was defined as a 2-times or more enlarged proximal anastomotic limb diameter with faecal impaction, although passage of stool was still possible; this condition was seen in 4 rats in group I/CH and in 1 rat in group I/CL.

Anastomotic abscesses were seen once in groups I/CH, I/CL and CH each.

### 3.2. Body weight

After the first anaesthesia, all rats lost some weight: recovery seemed slower in the irradiated groups (Fig. 2). The second anaesthesia again resulted in weight loss, which was similar in all groups on the first postoperative day. Thereafter, all rats under 5-FU medication lost progressively more weight; the high dose groups most.

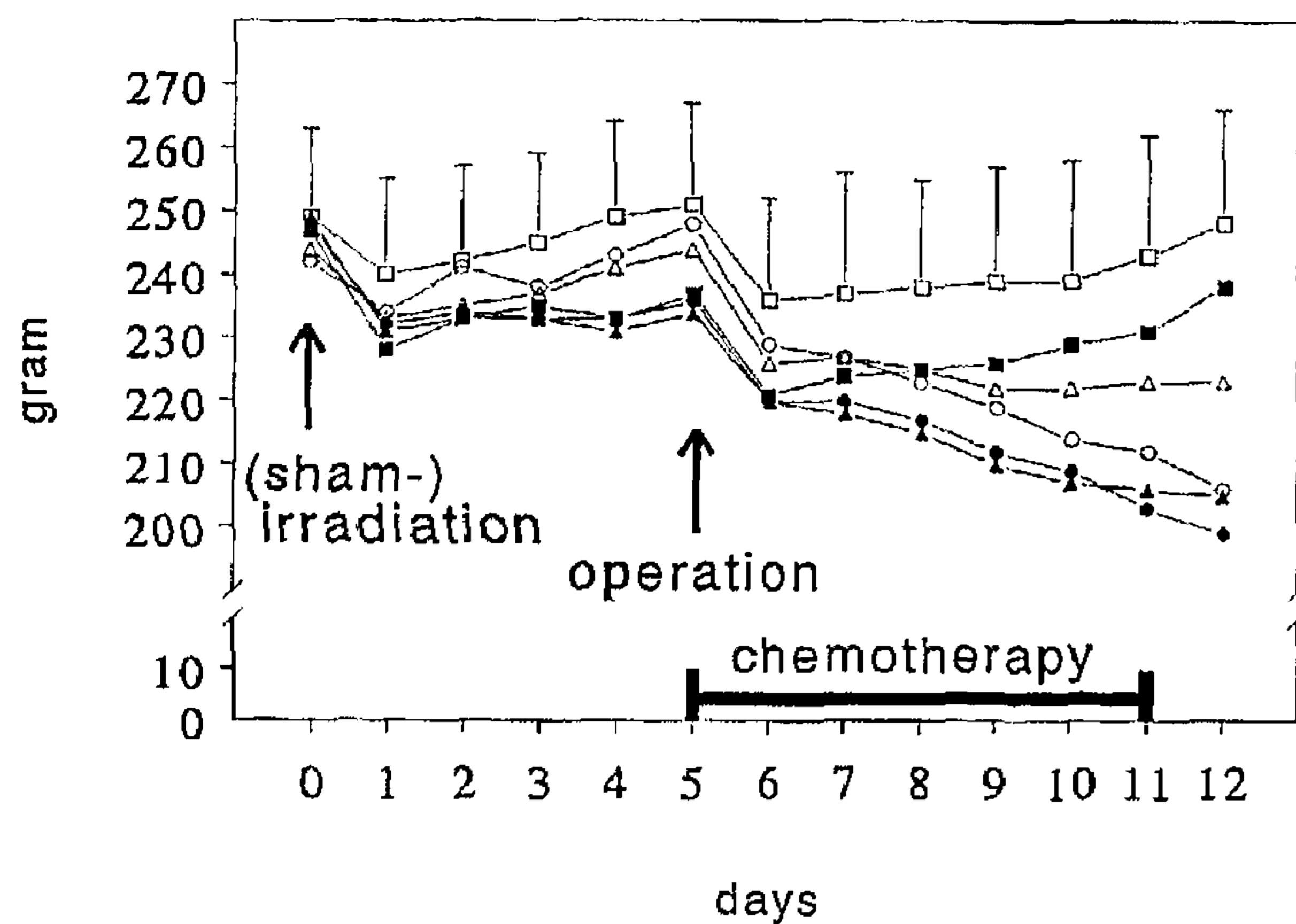


Fig. 2. Body weight as a function of time after (sham-)irradiation. (□) C group ( $\pm$ S.D.); ( $\Delta$ ) CL group; ( $\circ$ ) CH group; ( $\blacksquare$ ) I group; ( $\blacktriangle$ ) I/CL group; ( $\bullet$ ) I/CH group.

Rats treated with sham-medication gained weight again. In comparison with the control group differences were significant in the I/CL group from day 7 onwards, in groups CH and I/CH from day 8 onwards and in the CL group from day 11 onwards. The I group showed no significant differences with the control group.

### 3.3. Serum albumin and protein

Serum albumin and protein measurements are depicted in Table 1. At sacrifice there were significant differences between all irradiated groups and the control group (except for albumin in the I group); this difference appeared progressively more pronounced in groups I/CL and I/CH. The CH group also showed lower values for serum protein.

### 3.4. Anastomotic healing

Individual bursting pressure measurements and bursting sites are depicted in Fig. 3. Seven days after operation the bursting site was almost invariably outside the suture line in both the C and I groups. Treatment with 5-FU led to weakening of the anastomotic bursting pressure, as indi-

Table 1  
Serum albumin and protein at sacrifice

Group	Serum albumin	Serum protein
C	24 $\pm$ 2.8	55 $\pm$ 4.2
CL	25 $\pm$ 1.7	55 $\pm$ 3.8
CH	23 $\pm$ 1.4	50 $\pm$ 3.1*
I	22 $\pm$ 1.2*	51 $\pm$ 2.4*
I/CL	21 $\pm$ 1.0*	50 $\pm$ 2.7*
I/CH	20 $\pm$ 2.2*	47 $\pm$ 3.2*

Data are given as mean $\pm$ S.D., and are expressed in g/l. Differences between experimental groups and the control (C) group were tested for significance using a Mann-Whitney test; \* $P$ <0.02.

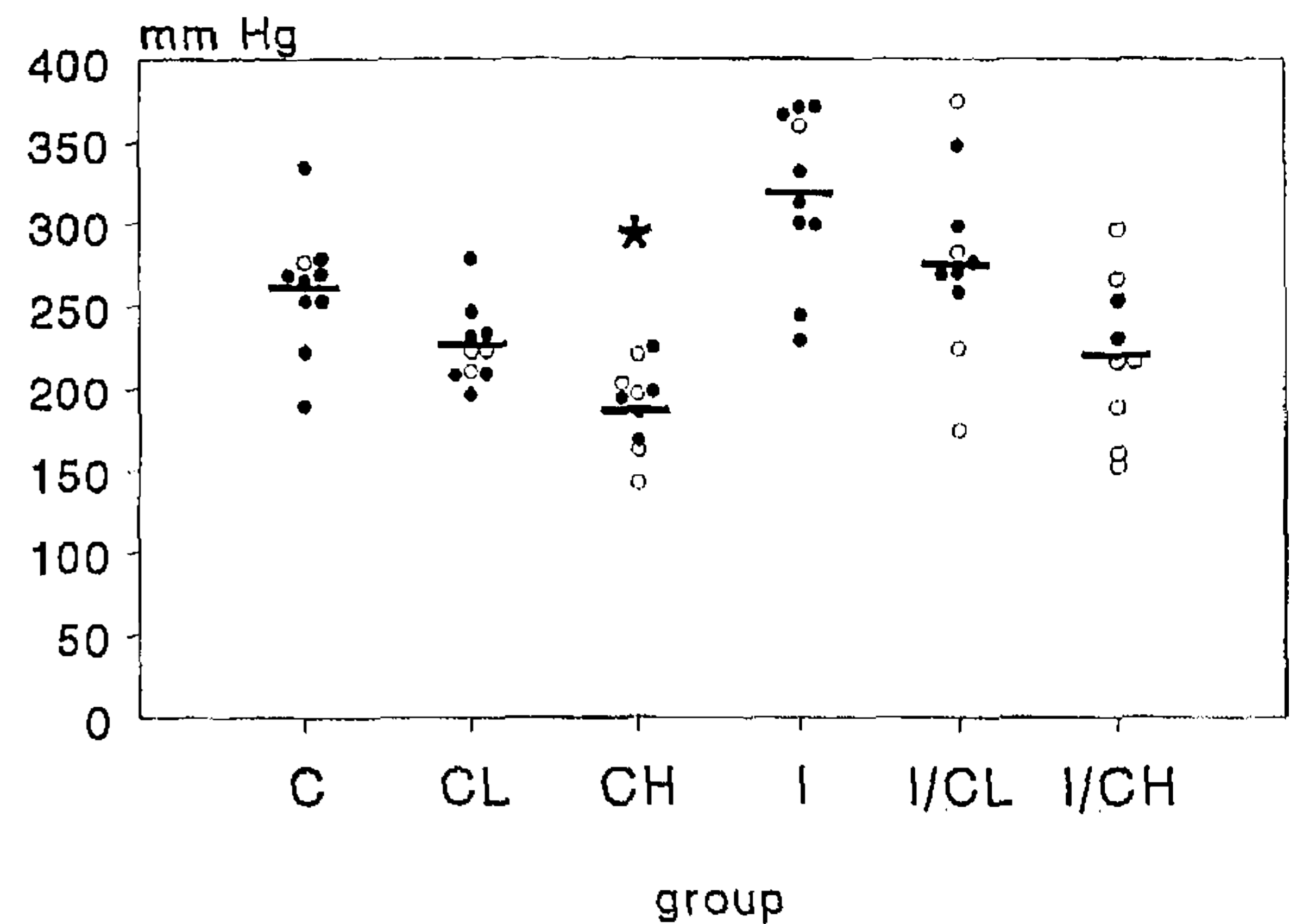


Fig. 3. Anastomotic bursting pressure. Each point represents a measurement in one single animal. ( $\circ$ ) Bursting site within the anastomosis; ( $\bullet$ ) bursting site outside the anastomosis. Statistically significant differences are shown (Mann-Whitney test). \* $P$ =0.0005.

cated by a shift in bursting site to the anastomotic area and reduced mean values in CL and CH ( $P$ =0.0005; Mann-Whitney) groups. Groups which had received the radiation dose all showed higher average bursting pressures than their sham-irradiated counterparts.

Breaking strength measurements are depicted in Table 2. Mean values were higher in the I group as compared to the control group, and lower in all other groups. Statistical significance was reached in the CH group only ( $P$ =0.012; Mann-Whitney). The site of the anastomotic rupture was always located inside the anastomosis, except for 1 rat in the I/CL group and 3 rats in the I group.

Hydroxyproline concentration and content of anastomotic samples are depicted in Table 2. There were no significant differences in hydroxyproline concentration between experimental groups and the control group. The mean hydroxyproline content was increased in all but the CL groups. The difference with the control group reached statistical significance in the I/CH group ( $P$ =0.0003) and the I/CL group ( $P$ =0.0015).

## 4. Discussion

In this study it is shown that high dose preoperative irradiation combined with a low dose of intraperitoneal 5-FU, applied in the immediate postoperative period, does not influence early strength of experimental colonic anastomoses. Although there were no statistical differences concerning anastomotic strength, reservations must be made for the application of a combination of preoperative irradiation with high dose 5-FU. Animals in the I/CH group lost much weight (during the experiment almost 20%). This went together with a significantly decreased serum albumin and protein ( $P$ =0.0003 and  $P$ <0.0001, respectively). The high incidence of functional rectal

**Table 2**  
Breaking strength, hydroxyproline concentration, and hydroxyproline content of anastomotic segments

Group	Breaking strength	Hydroxyproline concentration	Hydroxyproline content
C	217±62	16.4±1.7	331±51
CL	182±54	15.2±1.8	305±75
CH	156±41**	18.3±3.5	403±168
I	254±41	18.3±2	421±96
I/CL	177±65	18.8±4.3	497±120*
I/CH	175±47	14.8±2.9	498±82*

Data are given as average values±S.D., and are expressed in g (breaking strength), µg hydroxyproline/5 mm anastomotic segment (HP concentration), or µg hydroxyproline/mg dry weight (HP content).

Differences between experimental groups and the control (C) group were tested for significance using a Mann-Whitney test; \*\* $P=0.012$ , \* $P\leq 0.0015$ .

stenosis (4 out of 9), with another animal dying for unknown reasons before the end of the experiment, raises doubts about the safety of this combination. The increased anastomotic hydroxyproline (collagen) content in the I/CH and I/CL groups suggests a strong fibrotic reaction, even stronger than the reaction seen after irradiation alone. This fibrosis does not lead to increased early strength as compared to the control group. However, the possibility cannot be excluded that it might be the start of future rectal stenosis.

Clinical and experimental trials concerning surgery for colorectal cancer are increasingly focused on the application of adjuvant therapies [23]. Some clinical studies have dealt with combined effects of radiotherapy and chemotherapy as an adjunct to surgery, although so far a combination of preoperative irradiation and direct postoperative chemotherapy has not been reported yet. Graf describes undisturbed anastomotic wound healing after a 7-day course of 5-FU plus leucovorin intraperitoneally [9].

In a prospective study by Chari, in a group of 43 patients, a combination of 5-fluorouracil, cisplatin and preoperative irradiation with a dose of 45 Gy in fractions was given in a 5-week period prior to resection; this resulted in increased survival, decreased local recurrence and increased disease-free interval [3]. Only five patients underwent a low anterior resection with anastomotic construction. No anastomotic leakage occurred in these patients.

The beneficial effects of the combination of postoperative irradiation with prolonged postoperative chemotherapy on survival and tumor recurrence, especially in patients stage Dukes B or C rectal carcinoma, has also been proven in two prospective randomized trials [5,15]. However, nowadays adjuvant radiation therapy is generally thought to be most effective in the preoperative setting [7,18,21].

Adjuvant intraperitoneal chemotherapy is most useful in the first days after surgery. Since hardly any adhesions have been formed the anastomotic site and surrounding pelvic wall have not yet been sealed off, allowing a wide spread of the drug at the right location [24]. Also, high doses of regional chemotherapy over prolonged (120 h) time periods should translate into a high fraction of cell

kill and a small likelihood of drug resistance [24]. Furthermore, 5-FU administered intraperitoneally is preferably taken up by the visceral peritoneum, resulting in a high concentration in portal venous blood, in this way working possibly more powerful against hepatic implantation of metastatic cells than systemic application [19,24].

The combination of radiotherapy and chemotherapy is being used more and more often to improve results of adjunct therapy to surgery for cancer, as is done in colorectal cancer patients. Application can be sequentially, alternated or simultaneously [2]. When a sequential order is followed, and 5-FU is administered first, synchronisation and radiosensitisation occur. If radiotherapy is given first, more cells become sensitive to 5-FU [2]. In cancer cell lines the effect was more pronounced if irradiation preceded 5-FU [2]. In mice, the same experiment showed that chronology of both adjunct therapy modalities was not important, although simultaneous application gave slightly better results [6].

In the present experiment we used maximally 17.5 mg 5-FU/kg body weight, aiming at the highest dose which would leave colonic repair essentially unaffected [28]. Still, this regimen (the CH group) significantly reduced anastomotic strength, although without concomitant decrease in wound hydroxyproline content. The lower dose of 12.5 mg 5-FU/kg body weight (the CL group) did not significantly reduce wound strength, although the mean values of the strength measurements were lower than in the control group. This effect of 5-FU was independent of prior irradiation treatment: the decline in strength from C to CL and CH groups (Fig. 3, Table 2) was similar to that from I to I/CL and I/CH groups. Thus the detrimental effect of 5-FU was not enhanced by preoperative irradiation.

In conclusion, our data show that the combination of preoperative irradiation and direct postoperative chemotherapy does not lead to detrimental effects on anastomotic strength, although (high-dose) chemotherapy alone significantly reduces anastomotic strength. However, the combined use of preoperative irradiation with high-dose postoperative 5-FU seems questionable because of increased frequency of rectal stenosis.

## References

- [1] Brierley, J.D., Cummings, B.J., Shun Wong, C., Keane, T.J., O'Sullivan, B., Catton, C.N. and Goodman, P. Adenocarcinoma of the rectum treated by radical external radiation therapy. *Int. J. Radiat. Oncol. Biol. Phys.* 28: 255–259, 1994.
- [2] Carpentier, Y., Demange, L., Loirette, M., Hivet, J. and Desoize, B. Chronology of combined chemotherapy (5-FU) and radiotherapy. I. In vitro study. *Anticancer Res.* 13: 2177–2180, 1993.
- [3] Chari, R.S., Tyler, D.S., Anscher, M.S., Russell, L., Clary, B.M., Hathorn, J. and Seigler, H.F. Preoperative radiation and chemotherapy in the treatment of adenocarcinoma of the rectum. *Ann. Surg.* 221: 778–787, 1995.
- [4] Clark, B.G., Souhami, L., Roman, T.N., Evans, M.D.C. and Pla, C. Rectal complications in patients with carcinoma of the cervix treated with concomitant cisplatin and external beam irradiation with high dose rate brachytherapy: a dosimetric analysis. *Int. J. Radiat. Oncol. Biol. Phys.* 28: 1243–1250, 1994.
- [5] O'Connell, M.J., Martenson, J.A., Wieand, H.S., Krook, J.E., MacDonald, J.S., Haller, D.G., Mayaer, R.J., Gunderson, L.L. and Rich, T.A. Improving adjuvant therapy for rectal cancer by combining protracted-infusion fluorouracil with radiation therapy after curative surgery. *N. Engl. J. Med.* 331: 502–507, 1994.
- [6] Demange, L., Carpentier, Y., Loirette, M., Hivet, J., Rigaud, C. and Desoize, B. Chronology of combined chemotherapy (5-FU) and radiotherapy. II. In vivo study. *Anticancer Res.* 13: 2181–2186, 1993.
- [7] Frykholm, G.J., Glimelius, B. and Pahlman, L. Preoperative or postoperative irradiation in adenocarcinoma of the rectum: final treatment results of a randomized trial and an evaluation of late secondary effects. *Dis. Colon Rectum* 36: 564–572, 1993.
- [8] Graf, W., Weiber, S., Glimelius, B., Jiborn, H., Pahlman, L. and Zederfeldt, B. Influence of 5-fluorouracil and folinic acid on colonic healing: an experimental study in the rat. *Br. J. Surg.* 79: 825–828, 1992.
- [9] Graf, W., Westlin, J.E., Pahlman, L. and Glimelius, B. Adjuvant intraperitoneal 5-fluorouracil and intravenous leucovorin after colorectal cancer surgery: a randomized phase II placebo-controlled study. *Int. J. Colorect. Dis.* 9: 35–39, 1994.
- [10] Hendriks, T. and Mastboom, W.B.J. Healing of experimental intestine anastomoses: parameters for repair. *Dis. Colon Rectum* 33: 891–901, 1990.
- [11] Hillan, K., Nordlinger, B., Ballet, F., Puts, J.P. and Infante, R. The healing of colonic anastomoses after early intraperitoneal chemotherapy: an experimental study in rats. *J. Surg. Res.* 44: 166–171, 1988.
- [12] Ibi, I., Saito, Y., Sunouchi, K., Sawada, T., Muto, T., Agnifili, A. and De Bernardinis, G. Positive effect of preoperative radiation in the treatment of lower rectal carcinoma. *Coloproctology* 16: 375–384, 1994.
- [13] Ito, H., Meistrich, M.L., Barkley, H.T., Thames, H.D. and Milas, L. Protection of acute and late radiation damage of the gastrointestinal tract by WR-2721. *Int. J. Radiat. Oncol. Biol. Phys.* 12: 211–219, 1986.
- [14] Kemeny, N. Recent advances in the treatment of advanced colorectal cancer. *Cancer* 71: 9–18, 1993.
- [15] Krook, J.E., Moertel, C.G., Gunderson, L.L., Wieand, H.S., Collins, R.T., Beart, R.W., Kubista, T.P., Poon, M.A., Meyers, W.C., Mailliard, J.A., Twito, D.I., Morton, R.F., Veeder, M.H., Witzig, T.E., Cha, S. and Vidyarthi, S.H. Effective surgical adjuvant therapy for high-risk rectal carcinoma. *N. Engl. J. Med.* 324: 709–715, 1991.
- [16] Moertel, C.G. Chemotherapy for colorectal cancer. *N. Engl. J. Med.* 330: 1136–1142, 1994.
- [17] Morgenstern, L., Sanders, G., Wahlstrom, E., Yadegar, J. and Amodeo, P. Effect of preoperative irradiation on healing of low colorectal anastomosis. *Am. J. Surg.* 147: 246–249, 1984.
- [18] MRC. First report of an MRC Working Party: a trial of preoperative radiotherapy in the management of operable rectal cancer. *Br. J. Surg.* 69: 513–519, 1982.
- [19] Nordlinger, B., Panis, Y., Puts, J.P., Herve, J.P., Delelo, R. and Ballet, F. Experimental model of colon cancer: recurrences after surgery alone or associated with intraperitoneal 5-fluorouracil chemotherapy. *Dis. Colon Rectum* 34: 658–663, 1991.
- [20] Ormiston, M.C.E. A study of rat intestinal wound healing in the presence of radiation injury. *Br. J. Surg.* 72: 56–58, 1985.
- [21] Pahlman, L. and Glimelius, B. Pre- or postoperative radiotherapy in rectal and rectosigmoid carcinoma. *Ann. Surg.* 211: 187–195, 1990.
- [22] Schrock, T.H., Deveney, C.W. and Dunphy, J.E. Factors contributing to leakage of colonic anastomoses. *Ann. Surg.* 177: 513–518, 1973.
- [23] Steele Jr, G.D. Combined-modality therapy for rectal carcinoma — the time has come. *N. Engl. J. Med.* 324: 764–766, 1991.
- [24] Sugarbaker, P.H., Graves, T., DeBruijn, E.A., Cunliffe, W.J., Mullins, R.E., Hull, W.E., Oliff, L. and Schlag, P. Early postoperative intraperitoneal chemotherapy as an adjuvant therapy to surgery for peritoneal carcinomatosis from gastrointestinal cancer: pharmacological studies. *Cancer Res.* 50: 5790–5794, 1990.
- [25] Tepper, J.E. Combined radiotherapy and chemotherapy in the treatment of gastrointestinal malignancies. *Semin. Oncol.* 19: 96–101, 1992.
- [26] de Waard, J.W.D., Wobbles, T. and Hendriks, T. Early post-operative 5-fluorouracil does not affect the healing of experimental intestinal anastomoses. *Int. J. Colorectal Dis.* 8: 175–178, 1993.
- [27] de Waard, J.W.D., Wobbles, T., de Man, B.M., van der Linden, C.J. and Hendriks, T. Postoperative levamisole may compromise early healing of experimental anastomoses. *Br. J. Cancer* 72: 456–460, 1995.
- [28] de Waard, J.W.D., Wobbles, T., van der Linden, C.J. and Hendriks, T. Retinol may promote fluorouracil-suppressed healing of experimental intestinal anastomoses. *Arch. Surg.* 130: 959–965, 1995.
- [29] Weiber, S., Jiborn, H. and Zederfeldt, B. Preoperative irradiation and colonic healing. *Eur. J. Surg.* 160: 47–51, 1994.