

PDF hosted at the Radboud Repository of the Radboud University Nijmegen

The following full text is a publisher's version.

For additional information about this publication click this link.

<http://hdl.handle.net/2066/23535>

Please be advised that this information was generated on 2017-12-05 and may be subject to change.

Coexistence of palmoplantar lichen planus and lupus erythematosus with response to treatment using acitretin

E.M.G.J. DE JONG AND P.C.M. VAN DE KERKHOF

Department of Dermatology, University Hospital Nijmegen, PO Box 9101, 6500 HB Nijmegen, the Netherlands

Accepted for publication 4 April 1995

Summary

Lichen planus and lupus erythematosus may occur as an overlap syndrome. Here we report the clinical characteristics of a 49-year-old man with palmoplantar lichen planus and lupus erythematosus. He showed a remarkable clinical response to treatment with acitretin, which resulted in prolonged remission of the disorder.

Lichen planus and lupus erythematosus may coexist in some patients,^{1–5} and have been treated by topical or intralesional corticosteroids, antimalarial drugs and oral corticosteroids, although the results are inconsistent.^{2,5} Common aetiopathological pathways have been suggested,⁶ but the causal relationship is unknown.

The aromatic retinoids, etretinate and acitretin, allow successful treatment of patients with keratinization disorders such as psoriasis, the ichthyoses, and genodermatoses such as Darier's disease.^{7,8} Oral lichen planus improves with oral etretinate (75 mg daily),⁹ and both etretinate and acitretin have been used in patients with recalcitrant discoid chronic or subacute lupus erythematosus.^{10,11} As far as we know, acitretin has not been reported as a treatment for palmoplantar lichen planus or for the lichen planus/lupus erythematosus overlap syndrome. In this report we describe the manifestations of the lichen planus/lupus erythematosus overlap syndrome (in a patient with involvement of the palms and soles) and report the response to treatment with acitretin.

Case report

A 49-year-old man presented with a 6-month history of itchy, non-painful lesions on the back, on the arms, and on the dorsal and palmar aspects of the hands and feet. He had been treated with topical clobetasol propionate for several weeks without success. He gave a past history of coronary artery disease (for which he received isosorbide dinitrate), arthralgia (for which he took ibuprofen), and he had had recurrent episodes of episcleritis. Examination showed well-demarcated erythematous squamous plaques, some showing atrophy and

Wickham's striae, on the back, arms, hands (palmar and dorsal surfaces) and feet (plantar and dorsal surfaces) (Fig. 1). The lesions on the hands and arms showed a violaceous erythema and there was slight hyperpigmentation of the lesions on the back. The palmar eruption was partly erosive with some papular and hyperkeratotic changes. No facial involvement was noted. He was obese but had no signs of joint disease. Routine haematological and biochemical studies were normal (apart from an erythrocyte sedimentation rate of 30 mm/first hour). Antinuclear antibodies and rheumatoid factor were not detected and joint X-rays were normal. A skin biopsy, taken from lesions from the back, showed a partly atrophic epidermis with hydropic degeneration of the basal layer (Fig. 2), with hyperkeratosis, slight parakeratosis and Civatte bodies within the epidermis. In the upper dermis there was a perivascular, mainly lymphocytic, inflammatory infiltrate which showed a perifollicular localization. The granular layer of the epidermis was of variable thickness. Immunofluorescence on the biopsy of lesional skin showed granular immunoglobulin (Ig) M deposition at the dermo-epidermal junction with some C3 deposits at the transition of epidermis to dermis, but no reaction for IgG, IgA or C1q.

The clinical and histological features were of lichen planus and discoid lupus erythematosus and, in view of this, a diagnosis of the lichen planus/lupus erythematosus overlap syndrome was made. In view of the non-response to topical corticosteroids and the extensive involvement, acitretin was commenced at 35 mg daily, in addition to continuance of the topical steroids. The acitretin was increased to 50 mg daily and, after 12 weeks, the lesions had flattened and some clearance was noted. The dose of acitretin was cautiously reduced

Discussion

Lichen planus of the palms and soles is relatively uncommon but when seen is usually characterized by a violaceous hue and the presence of erosions. We are unaware of any previous reports of the concurrence of palmoplantar lichen planus with discoid lupus

erythematosus. Both lichen planus and discoid lupus erythematosus can occur in the same patient.¹⁻⁵ One explanation is that the patient may originally have had lupus erythematosus but subsequently also developed lichen planus because of a Koebner phenomenon. However, the distribution of the lesions is not typical for lupus erythematosus (i.e. it is not in sun-exposed sites), and other mechanisms may be involved. Both



Figure 2. Histological picture of the lesions on the back (periodic acid Schiff reaction: $\times 200$).

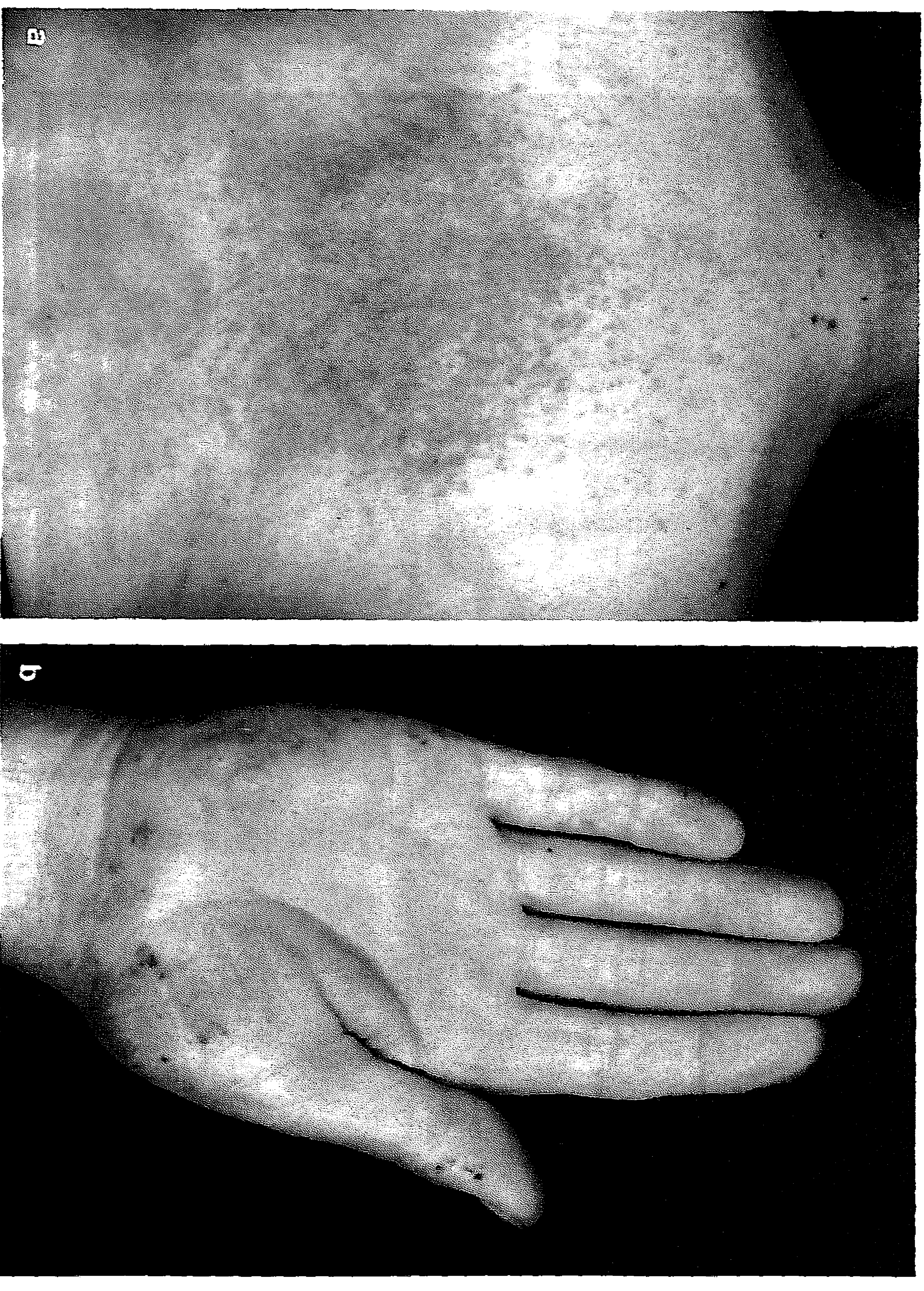


Figure 1. Lesions on the back (a), and on the palm (b), before treatment.

to 17.5 mg daily and the lesions remained in remission (Fig. 3). The treatment with acitretin was well tolerated, the only side-effect being a mild cheilitis, and there were no changes in routine blood or radiological parameters.

erythematous. In our patient, in addition to the palmopantalar lesions, there were changes on the arms and trunk which, both histologically and clinically, showed the features of lichen planus and lupus

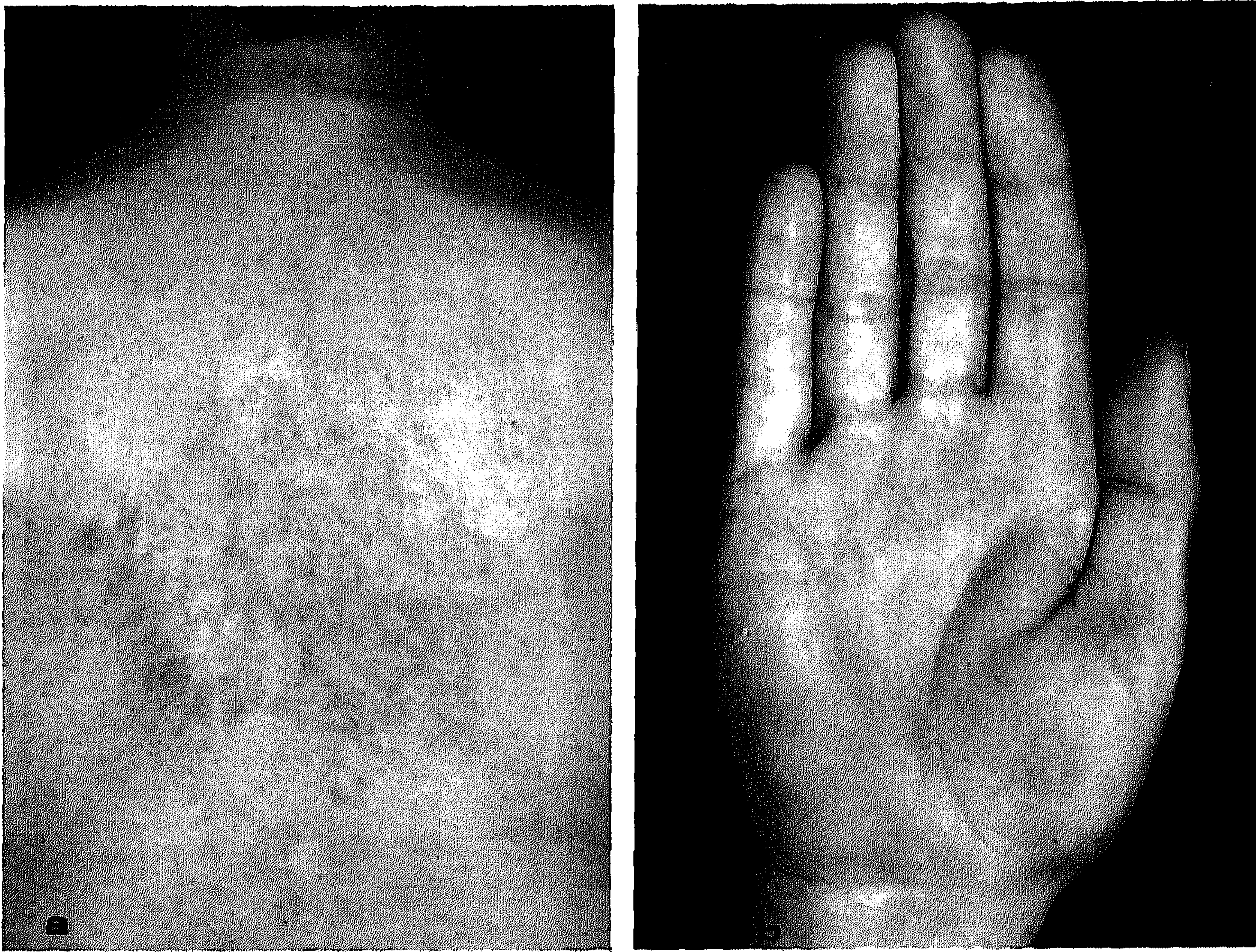


Fig. 3. Back (a) and palm (b), following acitretin therapy.

lupus erythematosus and lichen planus are immunologically mediated and, although it is well accepted that lupus erythematosus is an inflammatory disorder, the pathogenesis is obscure. The lesions of lupus erythematosus may result from immune complex-mediated injury,¹²⁻¹⁵ but might also be the result of a cell-mediated attack on the epidermis comparable with graft-versus-host disease.¹⁶⁻¹⁸ Lichen planus is likewise thought to be immunologically mediated,^{19,20} with a lymphocytic infiltrate penetrating the epidermis being a characteristic feature, and an epidermal antigen which may elicit a T-cell response has been postulated.

Both lichen planus and discoid lupus erythematosus are disorders of keratinization which show hyperproliferation.²¹⁻²³ In discoid lupus erythematosus there is an increase in keratin 16 (associated with hyperproliferation or an activated state of the epidermis), in addition to the normal pattern of keratin 10, which is a marker for early differentiation.²³ In discoid lupus erythematosus, markers of terminal differentiation such as involucrin and filaggrin are increased,²³ and similar studies have recently been performed in lichen planus (P.M.Steijlen and J.Peperkamp, personal communication). In lichen planus lesions, keratins 16 and 6 are prominent in the suprabasal compartment, keratin 10 is reduced, and involucrin is expressed in the whole suprabasal compartment. Hence, some pathogenetic mechanisms seem to be common to both lichen planus and lupus erythematosus, and this is also reflected in the histo-

logical features of an interphase dermatitis seen in both disorders. In addition, both conditions show changes in keratinization, with hyperproliferation in the early phases, and the presence of atrophy when the pilosebaceous unit is involved.

The pathogenetic features of lupus erythematosus and lichen planus mean that retinoids may be an effective treatment. Retinoids can exert an immune modulatory effect, and are known to inhibit gamma-interferon release by natural killer cells, and to block gamma-interferon induced upregulation of HLA-DR in monocytes.^{24,25} Retinoic acid may enhance or inhibit T-cell proliferation, depending on the type of stimulus.²⁶ Retinoids are also described to enhance the contact sensitivity reaction to dinitrochlorobenzene in psoriatic patients,²⁷ increase epidermal production of interleukin 1,²⁸ and interfere with epidermal proliferation and differentiation. In hyperproliferative skin, retinoids are antiproliferative,²⁹ whereas in normal skin they stimulate epidermal cell proliferation.³⁰ Etreinate reduces the synthesis of polyamines, important in regulating cell proliferation,³¹ and retinoids, both *in vitro* and *in vivo*, inhibit transcription of transglutaminase,^{32,33} an enzyme crucial to cross-linking of involucrin which is the main constituent of the corneocyte envelope. Retinoids modulate the expression of keratins 4, 10, 13, 16 and 19.³⁴⁻³⁶ Thus there are several theoretical reasons why retinoids may have an effect in lupus erythematosus and lichen planus.³⁷

We have demonstrated the impressive effect of aci-

tretin in a patient with the lichen planus/lupus erythematosus overlap syndrome. The dose of acitretin was increased from 35 to 50 mg daily and, once benefit was obtained, the dose was decreased with the continuance of benefit and only minimal side-effects of dryness of the skin and mucosae. Acitretin offers a therapeutic alternative to patients with the lichen planus/lupus erythematosus overlap syndrome who are recalcitrant to treatment with topical corticosteroids and antimalarial drugs.

References

- 1 Copeman PWM, Schroeter AL, Kierland RR. An unusual variant of lupus erythematosus or lichen planus. *Br J Dermatol* 1970; 83: 269-72.
- 2 Van der Horst JC, Cirkel PK, Nieboer C. Mixed lichen planus-lupus erythematosus disease: a distinct entity? Clinical, histopathological and immunopathological studies in six patients. *Clin Exp Dermatol* 1983; 8: 631-40.
- 3 Camisa C, Neff JC, Olsen RG. Use of indirect immunofluorescence in the lupus erythematosus/lichen planus overlap syndrome: an additional diagnostic clue. *J Am Acad Dermatol* 1984; 11: 1050-9.
- 4 Romero RW, Nesbitt LT, Reed RJ. Unusual variant of lupus erythematosus or lichen planus. *Arch Dermatol* 1977; 113: 741-8.
- 5 Plotnick H, Burnham TK. Lichen planus and co-existing lupus erythematosus versus lichen planus like lupus erythematosus. *J Am Acad Dermatol* 1986; 14: 931-8.
- 6 Davies MG, Gorkiewicz A, Knight A, Marks R. Is there a relationship between lupus erythematosus and lichen planus? *Br J Dermatol* 1977; 96: 145-54.
- 7 Ellis CN, Voorhees JJ. Etreinate therapy. *J Am Acad Dermatol* 1987; 16: 267-91.
- 8 Happle R, van de Kerkhof PCM, Traupe H. Retinoids in disorders of keratinization: their use in adults. *Dermatologica* 1987; 175 (Suppl. 1): 107-24.
- 9 Hersk K, Mobacken H, Sloberg K, Thilander H. Severe oral lichen planus: treatment with an aromatic retinoid (etretinate). *Br J Dermatol* 1982; 106: 77-80.
- 10 Ruzicka T, Meurer M, Braun-Falco O. Treatment of cutaneous lupus erythematosus with etretinate. *Acta Derm Venereol (Stockh)* 1985; 65: 324-9.
- 11 Ruzicka T, Meurer M, Bieber T. Efficiency of acitretin in the treatment of cutaneous lupus erythematosus. *Arch Dermatol* 1988; 124: 897-902.
- 12 Harrist TJ, Mihm MC. The specificity and clinical usefulness of the lupus band test. *Arthritis Rheum* 1980; 23: 479-90.
- 13 Provost TT. Lupus band test. *Int J Dermatol* 1981; 20: 475-81.
- 14 Gammon WR, Merritt CC, Heuke DC. Complement activating immune deposits in systemic lupus erythematosus skin. *J Invest Dermatol* 1983; 81: 14-20.
- 15 Cripps DJ, Rankin J. Action spectrum of lupus erythematosus and experimental immunofluorescence. *Arch Dermatol* 1973; 107: 563-7.
- 16 Bjerke JR. Subpopulations of mononuclear cells in lesions of psoriasis, lichen planus and discoid erythematosus studied using mononuclear antibodies. *Acta Derm Venereol (Stockh)* 1982; 62: 447.
- 17 Saurat JH. Cutaneous manifestation of graft-versus-host disease. *Int J Dermatol* 1981; 20: 249-56.
- 18 James WD, Odum RB. Graft-v-host disease. *Arch Dermatol* 1983; 19: 683-9.
- 19 Andre J, Laporte M, Delavaut P. Lichen planus: etiopathogenesis. *Acta Stomatol* 1990; 87: 229-31.
- 20 Morkenn VB. Etiology of lichen planus. *Am J Dermatopathol* 1986; 8: 154-6.
- 21 Davies MG, Marks R. Evolution of the lesion of discoid lupus erythematosus: a comparison with lichen planus. *Br J Dermatol* 1977; 97: 313-22.
- 22 de la Brassine MF, Pierard GE. Cell renewal in discoid lupus erythematosus. *J Cutan Pathol* 1976; 3: 175-9.
- 23 de Jong EMGJ, van Erp PEJ, Ruitter DJ, van de Kerkhof PCM. Immunohistochemical detection of proliferation and differentiation in discoid lupus erythematosus. *J Am Acad Dermatol* 1991; 25: 1032-8.
- 24 Abb J, Abb H, Deinhardt F. Effect of retinoic acid on the spontaneous and interferon-induced activity of human natural killer cells. *Int J Cancer* 1982; 30: 107-10.
- 25 Rhodes J, Stokes P. Interferon-induced changes in monocyte membrane. Inhibition by retinol and retinoic acid. *Immunology* 1982; 45: 531-6.
- 26 Abb J, Deinhardt F. Retinoids inhibit the mitogenic activity of tumour-promoting phorbol esters on human lymphocytes. *Int J Cancer* 1981; 25: 267-71.
- 27 Fulton RA, Souteyrand P, Thivolet J. Influence of retinoid Ro 10-9395 on cell-mediated immunity *in vivo*. *Dermatologica* 1982; 165: 568-72.
- 28 Schmitt A, Hauser C, Didierjean L. Systemic administration of etretin increased epidermal interleukin-1 in the rat. *Br J Dermatol* 1987; 116: 615-22.
- 29 Dierlich E, Orfanos CE, Pullmann H, Steigleder GK. Epidermale Zellenproliferation unter oraler Retinoidtherapie bei Psoriasis. Autoradiographische Befunde an befallener und nicht befallener Haut. *Arch Dermatol Res* 1979; 264: 169-77.
- 30 Gillenberg A, Immel C, Orfanos CE. Retinoid Einfluss auf die Zellkinetik gesunder menschlicher Epidermis. *Arch Dermatol Res* 1980; 269: 331-5.
- 31 Lowe NJ, Kaplan R, Breeding J. Etreinate treatment for psoriasis inhibits epidermal ornithine decarboxylase. *J Am Acad Dermatol* 1982; 6: 697-8.
- 32 Ponec M. Retinoid-induced modulation of differentiation, keratin and lipid composition in reconstructed epidermis *in vitro*. *Pharmacol Skin* 1989; 3: 45-51.
- 33 Rosenthal DS, Griffiths CEM, Yuspa SH *et al*. Acute or chronic topical retinoic acid treatment of human skin *in vivo* alters the expression of epidermal transglutaminase, loricrin, involucrin, filaggrin and keratins 6 and 13 but not keratins 1, 10 and 14. *J Invest Dermatol* 1992; 98: 343-50.
- 34 Kopan R, Traska G. Retinoids as important regulators of terminal differentiation: examining keratin expression in individual epidermal cells at various stages of keratinization. *J Cell Biol* 1987; 105: 427-40.
- 35 Eichner R, Kahn M, Capetola J *et al*. Effects of topical retinoids on cytoskeletal proteins: implications for retinoid effects on epidermal differentiation. *J Invest Dermatol* 1992; 98: 154-61.
- 36 Steijlen P, Reifenschweiler DOH, Ramaekers FCS *et al*. Topical treatment of ichthyoses and Darier's disease with 13-cis-retinoic acid. A clinical and immunohistochemical study. *Arch Dermatol Res* 1993; 285: 221-6.
- 37 Orfanos CE. Retinoide: der neue stand. *Hautarzt* 1989; 40: 123-9.