

PDF hosted at the Radboud Repository of the Radboud University Nijmegen

The following full text is a publisher's version.

For additional information about this publication click this link.

<http://hdl.handle.net/2066/23348>

Please be advised that this information was generated on 2017-12-05 and may be subject to change.

Vitreous haemorrhage and other ocular complications of a persistent hyaloid artery

A. GONÇALVES, J.R.M. CRUYSBERG, R.W. DRAAIJER,
P.W. SELLAR, A.L. AANDEKERK and A.F. DEUTMAN
Institute of Ophthalmology, University Hospital Nijmegen, Nijmegen, The Netherlands

Accepted 14 September 1996

Key words: Amblyopia, Cataract, Nystagmus, Persistent hyaloid artery, Strabismus, Vitreous detachment, Vitreous haemorrhage

Abstract. *Purpose:* To report ocular complications of a persistent hyaloid artery. *Methods:* We studied eight patients with persistent hyaloid artery. *Results:* Seven patients showed strabismus and very low visual acuity (≤ 0.12) of one eye. Despite correction of refractive errors, cataract surgery and occlusion therapy for amblyopia, visual acuity had not improved in these cases. Four patients showed nystagmus. Four had progression of unilateral cataract. In two cases, a 24-year-old woman and a 4-months-old boy, a vitreous haemorrhage had occurred due to rupture of a hyaloid artery, in the woman's case probably due to a spontaneous posterior vitreous detachment. *Conclusion:* A persistent hyaloid artery may be associated with strabismus, cataract, amblyopia and nystagmus. Despite amblyopia treatment, the prognosis of visual acuity of the involved eye is unfavourable. A persistent hyaloid artery may cause vitreous haemorrhage.

Introduction

Regression of the embryonic hyaloid vascular system is normally completed at birth or shortly afterwards. A persistent hyaloid artery (PHA) is a fairly common developmental anomaly in the human eye, and is mostly seen in the form of persistent parts of the artery at the disc (Bergmeister's papilla) or on the posterior lens capsule (Mittendorf's dot). Less commonly, the entire hyaloid artery may persist, from the optic disc to the back of the lens. The presence of active blood flow in the postpartum hyaloid system is rare. In consequence, haemorrhage from a hyaloid artery has rarely been reported [1-4].

Case report

In December 1994, a 24-year-old woman (Patient 1; Table) was referred to the Institute of Ophthalmology at the University Hospital Nijmegen, for

Table 1. Clinical findings in eight patients with persistent hyaloid artery (PHA)

Patients:	Patient 1	Patient 2	Patient 3	Patient 4	Patient 5	Patient 6	Patient 7	Patient 8
Sex, age:	F, 24 yrs	F, 18 yrs	F, 16 yrs	M, 15 yrs	F, 14 yrs	M, 8 yrs	M, 8 yrs	M, 6 yrs
PHA-RE:	-	-	Total PHA	Partial PHA	-	Total PHA	Total PHA	-
PHA-LE:	Total PHA	Partial PHA	-	Partial PHA	Partial PHA	-	Partial PHA	Total PHA
Strabismus:	Exotropia LE	Hypertropia LE	Hypertropia RE	Esotropia RE	Hypertropia LE	Esotropia RE	-	Esotropia LE
Nystagmus:	-	-	+	+	+	+	-	-
Cataract:	-	-	+	-	+	+	-	+
Vitreous haem.:	LE, 24 yrs	-	-	RE, 4 mos	-	-	-	-
Surgery (age):	-	Strabismus, 4 yrs	Cataract, 3 yrs	Strabismus, 3 yrs	Cataract, 7 mos	Cataract, 3 yrs	-	-
Refraction:	Myopia LE	High myopia LE	Aphakia RE	High myopia RE	Aphakia LE	Aphakia RE	Hypermetropia	NR
Occlusion th.:	-	+	+	+	+	+	-	+
Visual acuity:	RE: 1.20 LE: 0.12*	RE: 1.00 LE: 0.02*	RE: 0.01* LE: 0.80	RE: 0.02* LE: 0.80*	RE: 0.40 LE: 0.01*	RE: 0.00* LE: 0.50	RE: 0.60* LE: 0.80*	RE: 0.80 LE: 0.02*

*PHA=persistent hyaloid artery; RE=right eye; LE=left eye

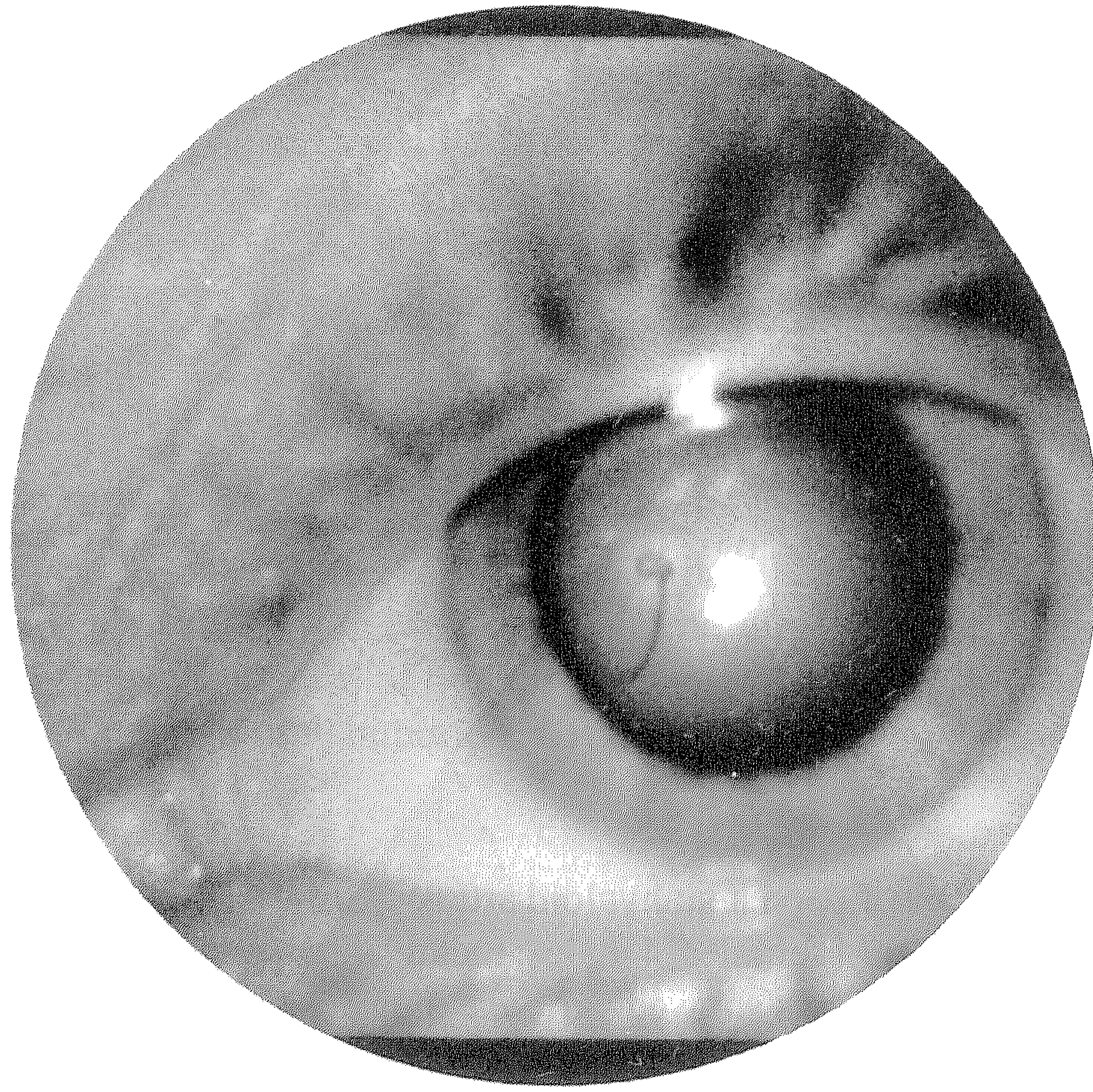


Figure 1. Persistent hyaloid artery in case 1, with a Mittendorf dot and extension into the vitreous.

evaluation of a vitreous haemorrhage in her amblyopic left eye. The vision of her left eye had deteriorated spontaneously one week previously, in the course of an afternoon while at home. At first examination, visual acuity was 1.0 in the right eye and 0.08 in the left eye. The refraction was RE S+0.25=C-0.25 axis 165° and LE S+0.25=C-2.75 axis 56°. There was exotropia of the left eye. Intraocular pressure was 14 mmHg in the right eye and 15 mmHg in the left eye. By biomicroscopy, a persistent hyaloid artery (Figure) could be followed from the posterior lens capsule to very near the optic disc, where, by ophthalmoscopy, the origin of the artery could be seen. The entire artery, including a branch of the artery at the posterior pole of the lens, still contained blood in its lumen. Furthermore, there was a posterior vitreous detachment present and some blood with fibrin deposition inferiorly in the vitreous cavity. There was no sign of vitreoretinal traction or of retinal detachment. The right eye was normal. Fluorescein angiography, at three weeks and again at 5 months after first examination showed no leakage from the hyaloid artery. After clearing of the vitreous haemorrhage, visual acuity improved to 0.12

in the left eye. There was no recurrence of vitreous haemorrhage in the 15 month follow-up period.

Patients and methods

Having seen a case with a vitreous haemorrhage from a persistent hyaloid artery (Patient 1), we decided to review our other PHA-patients (Patients 2 to 8) to see if they really were as harmless as often is assumed. We reviewed the clinical records of eight cases of persistent hyaloid artery who were seen in the Institute of Ophthalmology, University Hospital Nijmegen. Patients with severe congenital ocular malformations, i.e. persistent hyperplastic primary vitreous (PHPV) and microphthalmia, were not included in this study.

Results

Eight clinical cases of persistent hyaloid artery were studied. The Table gives details of the patients (4 females, 4 males; mean {range} age 14 {6-24} years). Seven of the eight patients showed various types of strabismus in association with mainly myopic refractive defects and astigmatism. Four had nystagmus. Four patients were documented with progression of their Mittendorf's dot to a dense cataract. The corrected visual acuity of the involved eye remained very low (≤ 0.12) in seven out of eight patients, despite treatment and occlusion therapy. Vitreous haemorrhages had occurred in two cases (Patients 1 and 4).

Discussion

In the case report (Patient 1), the vitreous haemorrhage occurred due to a rupture of a previously intact persistent hyaloid artery. This was probably the result of a posterior vitreous detachment, which was seen by biomicroscopy. In previous reports, haemorrhages of a hyaloid artery have been explained by various mechanisms, such as rapid eye movements during sleep [1], due to external trauma to the globe [2], or considered to be spontaneous [3,4].

Fluorescein angiographic evaluation of a persistent hyaloid artery has rarely been reported [1,5,6], but remnants of the hyaloid vascular system may show moderate to massive fluorescein leakage [5,6]. In our Patient 1, the persistent hyaloid artery showed no evidence of leakage during fluorescein angiography.

A persistent hyaloid artery normally requires no treatment, but after persistent intravitreal haemorrhage, vitrectomy could perhaps be necessary. Recurrent episodes of bleeding from a persistent hyaloid artery have been reported,

and in these cases photocoagulation of the bleeding artery has been recommended [4].

From review of our cases it can be seen that the consequences of a persistent hyaloid artery include amblyopia, strabismus, and nystagmus. There may be progression of cataract, and less frequently a vitreous haemorrhage may occur. Treatment of PHA-associated amblyopia is often disappointing. The high prevalence of amblyopia can be explained by the association of a persistent hyaloid artery with anisometropia and stimulus deprivation due to unilateral cataract. Strabismus is often a consequent development. Duke-Elder stated that hyaloid remnants (pre-pupillary hyaloid cysts) may also be associated with a considerable degree of amblyopia, but that usually the vision was unimpaired [7]. In the literature we found no direct reference to persistent hyaloid arteries as a cause of amblyopia, but suggest that the association is much more frequent than hitherto recognised.

References

1. Chen TL, Yamg SS. Vitreous hemorrhage from a persistent hyaloid artery. *Retina* 1993; 13: 148-151.
2. Yap EY, Buettner H. Traumatic rupture of a persistent hyaloid artery. *Am J Ophthalmol* 1992; 114: 225-227.
3. Delaney WV Jr. Prepapillary hemorrhage and persistent hyaloid artery. *Am J Ophthalmol* 1980; 90: 419-421.
4. Tolentino FI, Schepens CL, Freeman HM. *Vitreoretinal Disorders (Diagnosis and Management)*. Philadelphia, London, Toronto: Saunders, 1976: 191-193.
5. Gieser DK, Goldberg MF, Apple DJ, Hamming NA, Kottow MH. Persistent hyperplastic primary vitreous in an adult: case report with fluorescein angiographic findings. *J Pediatr Ophthalmol Strabismus* 1978; 15: 213-218.
6. Richard G. *Fluorescein Angiography. Textbook and Atlas*. New York: Thieme Medical Publishers, 1989: 37.
7. Duke-Elder S. Normal and Abnormal Development. Congenital Deformities. In: *System of Ophthalmology*, vol 3, pt 2. St Louis: CV Mosby, 1964: 764-770.

Address for correspondence: J.R.M. Cruysberg, MD, Institute of Ophthalmology, University Hospital Nijmegen, P.O. Box 9101, 6500 HB Nijmegen, The Netherlands
Phone: + 31-24-3615104; Fax: + 31-24-3540522