

PDF hosted at the Radboud Repository of the Radboud University Nijmegen

The following full text is a publisher's version.

For additional information about this publication click this link.

<http://hdl.handle.net/2066/23116>

Please be advised that this information was generated on 2017-12-05 and may be subject to change.

Carel B. Hoyng
August F. Deutman

The development of central areolar choroidal dystrophy

Received: 14 November 1994
Revised version received: 3 April 1995
Accepted: 11 May 1995

Presented during the meeting of the Club
Jules Gonin, Versailles, France,
September 1994

C. B. Hoyng (✉) · A. F. Deutman
Institute of Ophthalmology,
University Hospital Nijmegen,
Postbus 9101, 6500 HB Nijmegen,
The Netherlands
Tel. +31-80-614448,
Fax +31-80-540522

Introduction

Central areolar choroidal dystrophy (CACD) is a hereditary choroidal dystrophy of the posterior pole of the eye. The end-stage of this disease is characterized by the presence of a well-defined area of atrophy of the photoreceptors, retinal pigment epithelium and underlying choriocapillaris in the macular region. In CACD a central scotoma may gradually develop over several years in middle-aged patients. This generally leads to severe visual impairment, to the level of counting fingers. In the majority of cases, this loss of vision will occur before the age of 60.

Sorsby [12] was the first to describe the genetic nature of this condition. To date, only five families have

Abstract ● **Background:** Central areolar choroidal dystrophy (CACD) is a hereditary macular disorder of which the development is poorly understood. ● **Methods:** One hundred and eight members of seven families with CACD underwent ophthalmological examination. If macular alterations were found or suspected, the patients underwent fluorescein angiography, electroretinography (ERG), electrooculography (EOG) and tests of colour vision and visual field. CACD was divided into four stages: I, slight parafoveal changes of the pigment epithelium (RPE); II, RPE mottling encircling the fovea; III, additional atrophy of the choriocapillaris without central involvement; IV, as stage III with central involve-

ment. ● **Results:** In 60 eyes of 30 patients, 8 with stage I, 12 with stage II, 18 with stage III and 22 with stage IV CACD were found. The photopic ERG was subnormal in about half of the cases with stage II-IV. Colour vision tests revealed diminished red sensitivity and pseudoprotonomaly in stages I and II and combined red-green and blue-yellow defect in stages III and IV. Parafoveal reduced sensitivity (stages I and II) and parafoveal and foveal reduced sensitivity (stages III and IV) were found in the visual field tests. ● **Conclusion:** We describe and expand the stages of development of CACD. Early recognition of patients may have a great influence on their subsequent life.

been described in the world literature with members of more than one generation affected [1-3, 6, 8, 10], along with six families where several siblings in one generation are afflicted [1-3, 11, 12]. On the basis of these reports, the inheritance of CACD appears to be either autosomal dominant or recessive. In addition, a number of sporadic cases have been reported [2, 3].

Almost all the patients described were first encountered by the authors in the atrophic end-stage of the disease. Only six patients were encountered with fundus alterations preceding the atrophic end-stage [1-3, 10, 13].

When the chance to examine seven afflicted families occurred, the opportunity was seized to gain and systematize more information about this rare disease.

Material and methods

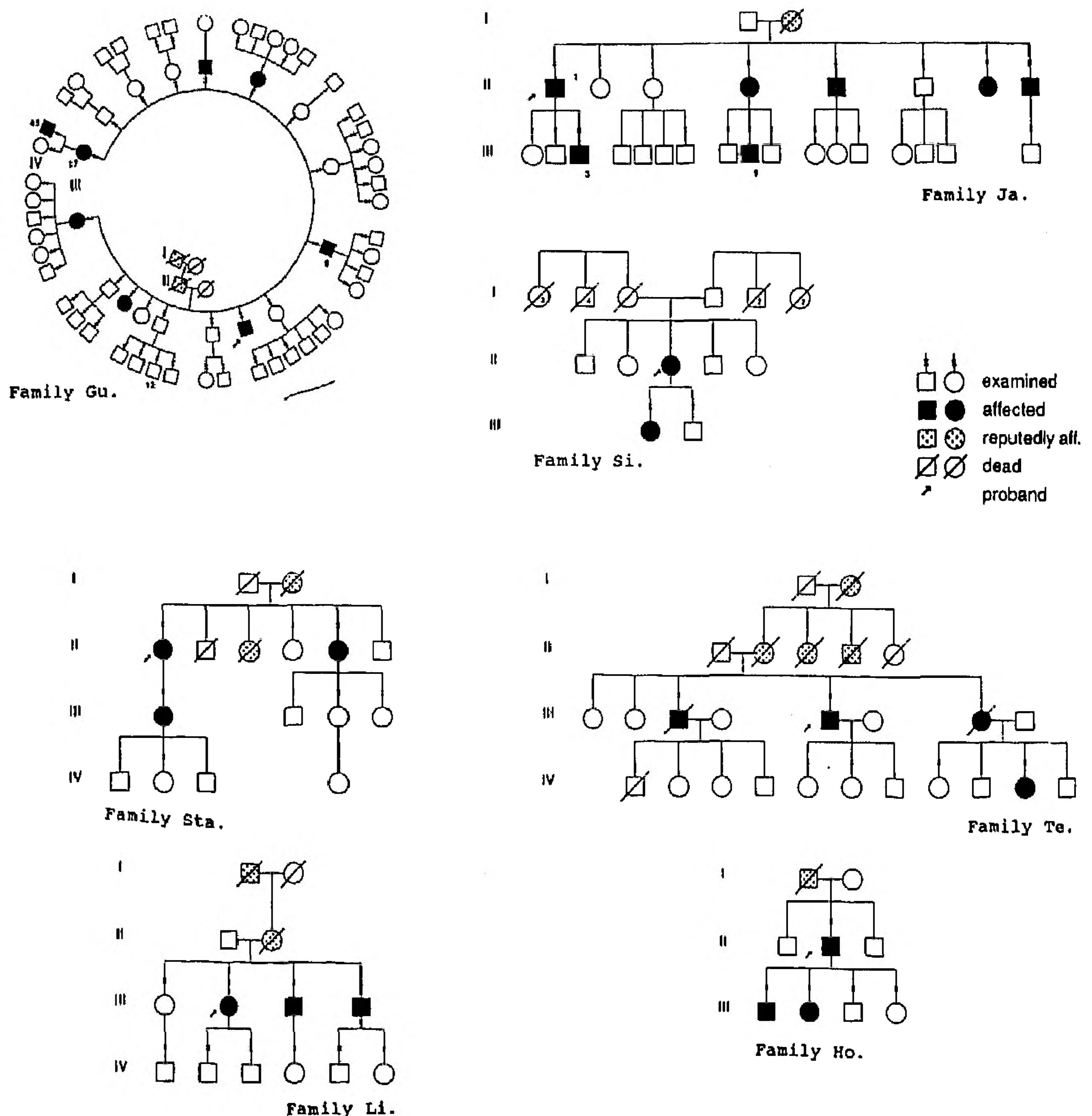
When this investigation into the course of CACD was initiated in 1987, several members of families Gu. and Ja., suffering from advanced CACD, were known in our department. In order to obtain as many cases as possible from these large families, 69 members of the two families were visited in 1988 and 1989. During visits, any visual complaints were noted and visual acuity was determined as accurately as possible. Fundus photographs were made by means of a portable KOWA fundus camera. When fundus alterations were identified or suspected in ophthalmoscopy or after evaluation of the fundus photographs, the patients were asked to visit our clinic for further examination. Because the first results were encouraging, 39 family members of patients from five additional families with a possible autosomal-dominant trait of CACD were also asked to attend our institution for ophthalmic examination. When fundus alterations were visible or suspected in examination with higher magnification, patients were asked to undergo fluorescein angiography. Because of the long duration of the electrophysiological tests and because abnormalities were not suspected in the very early stages of CACD, patients were only asked to undergo these examinations when abnormalities were detected in fluorescein angiography.

The retinal function tests were tested by electroretinography (ERG), electrooculography (EOG), colour vision tests and visual field tests. In the ERG tests, the patient faced a modified sphere of a Goldmann-Weekers adaptometer, lit by two 40-W incandescent lamps in order to furnish a Ganzfeld adaptation. A scleral contact lens equipped with the measuring electrodes had been inserted. A reference electrode was applied to the middle of the forehead,

while the patient was earthed by means of two ear-clip electrodes. A xenon flash was used for stimulation by flashes (flash luminance 6.85 cd.s.m^{-2} photopic and 0.85 cd.s.m^{-2} scotopic). Measurements were recorded at photopic and scotopic (after 12 min of dark adaptation) adaptation levels. Recorded electric potentials were plotted in a diagram against flash intensity. In the cases described in the following sections, the saturation level of the b-wave was noted under photopic circumstances. Recorded electric potentials were classified as abnormal when the a-wave did not exceed $-50 \mu\text{V}$ and the b-wave did not exceed $100 \mu\text{V}$ in the photopic ERG and the b-wave did not exceed $150 \mu\text{V}$ in the scotopic ERG. In EOG the patient faced the same sphere that was used for ERG measurements. Skin electrodes were placed near the canthi interni and externi of the eyes. After pre-adaptation at 100 lx for about 15 min, the sphere was made dark for 12 min and the EOG was recorded at intervals of 2 min during this period. Then the sphere was adjusted to 2 500 lx and measurements were continued every minute for a further 15 min. The dark trough (Dt) was determined as the mean of the values between the 6 min and 12 min, and the light peak (Lp) was determined from the mean of the four maximum values during the light adaptation period. The Arden ratio (Lp/Dt ratio) was calculated, and values below 180 were classified as subnormal.

The Tokyo Medical College test (TMC) and the Farnsworth Panel D-15 test (D-15) or box 4 of the New ColourTest (NCT 6/4) were used for screening colour vision. When the TMC testing result proved normal, the Ishihara test (1970 edition) was performed. When a patient failed the TMC test, the American Optical Hardy Rand and Rittler test (HRR) was used. When the D-15 test result was $-50 \mu\text{V}$, or normal, the desaturated Panel D-15 test (D-8/2) was used; when the D-15 test result was abnormal, box 8

Fig. 1 Pedigrees of the seven families with CACD in two or more generations



of the NCT (NCT 8/4) was used. If possible, the patient was asked to undergo the Farnsworth-Munsell 100 Hue test (100 Hue) and an anomaloscope examination (Nagel Model II or Neitz OT). When colour vision examination proved impossible, the patient was asked to denominate large coloured surfaces red, green, yellow and blue at the patient-preferred distance [9]. Static measurements were performed by means of the Rodenstock Peritest (single and multiple stimuli with 17 luminance steps of 0.2 logU; background luminance 1 cd/m²) and, in a few cases, the Oculus Friedman field analyser.

The pedigrees of the seven families are given in Fig. 1.

To describe the changes and to compare the different findings in our patients, according to observations made by Krill [7] and ourselves [5], we divide the development of CACD into four stages: Stage I: Doubtful or slight parafoveal pigmentary changes seen with contact lens or 60-D lens; fluorescein angiography shows a mottled hyperfluorescence that does not encircle the whole fovea. Stage II: Ophthalmoscopically evident alterations of the parafoveal pigment epithelium; hyperfluorescent spots, sometimes intermingled with hypofluorescent areas, encircle the intact fovea more than 180 degrees in angiography.

Stage III: Same findings as in stage II, but also one or more areas of atrophy of choriocapillaris enhancing the visibility of the choroidal vessels throughout all phases of fluorescein angiography; the fovea seems not affected.

Stage IV: Same findings as in stage III, but now the fovea is also affected by atrophy of the choriocapillaris.

Results

Although patients from several provinces in the south-eastern part of the Netherlands are referred to the academic hospital of Nijmegen, it is striking that, at the time of examination, most affected family members (24 of the 30 described) lived in the province of Limburg. It is also noticeable that in the case of six of the seven families concerned, the eldest traceable family members originated from this province. We could not find evidence that any of the families were related to each other. The geographical distribution of affected family members is shown in Fig. 2.

From the seven families concerned, 30 patients with various stages of CACD were identified. The first two stages of CACD could also be referred to as 'probable CACD'. In our patients who suffered from stage I or II of the disorder, no history or manifestations of systemic diseases, prolonged drug treatment or other ocular diseases could explain the macular alterations adequately. The majority of patients revealed the same stage of CACD in both eyes. Different stages were found in six persons (Gu. III-7, III-9, III-12; Te. IV-10; Li. III-3, III-4).

The number of eyes with CACD, by stage, are shown in Table 1. The gender ratio of the family members was 1:1 (15 males, 15 females). The age distribution of the family members with CACD is given in Table 2, where the total exceeds the number of 30 patients examined because those with two different stages of CACD are counted twice.

Seven male patients mentioned their first visual disturbances as occurring between the ages of 37 and 55

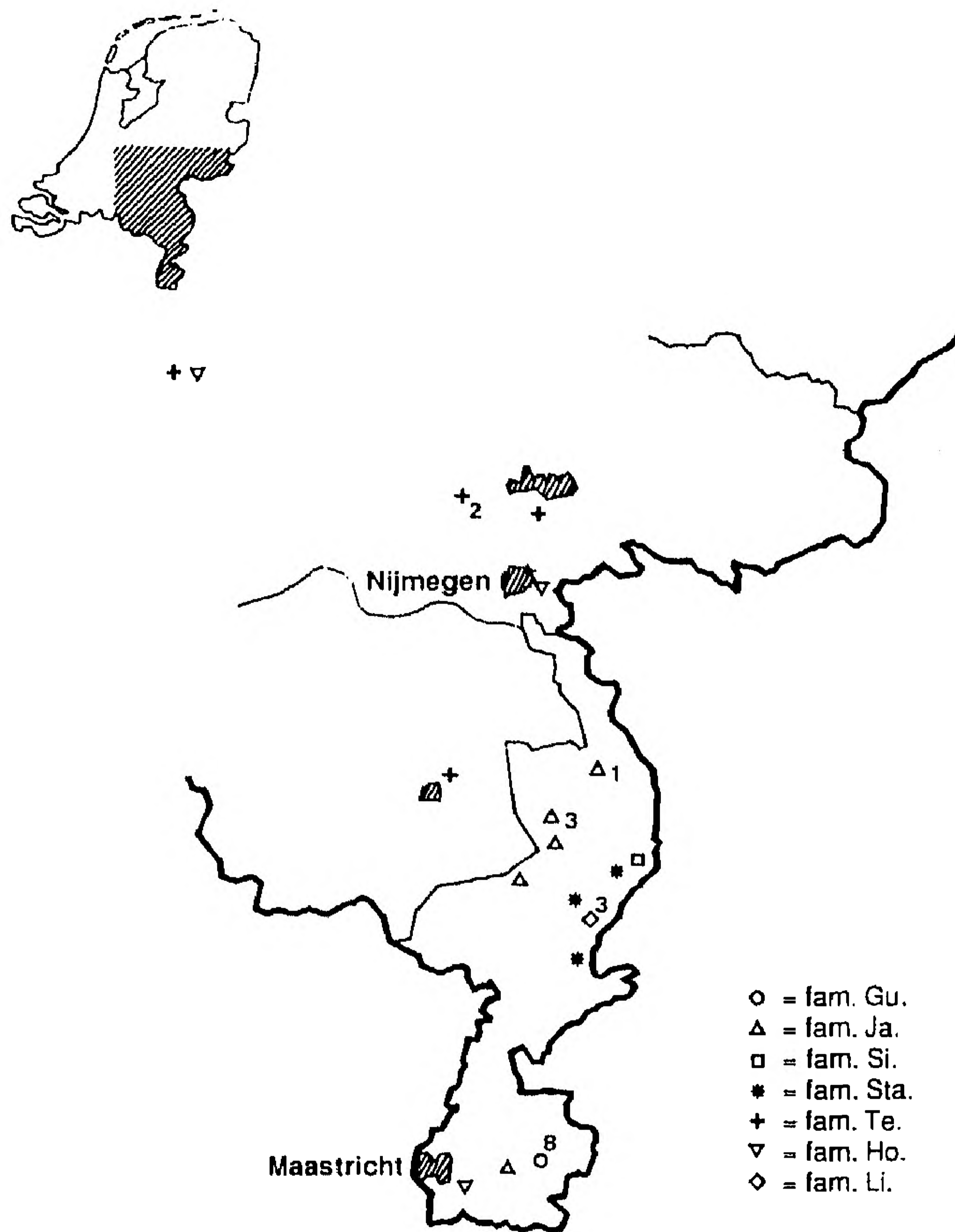


Fig. 2 Distribution of the family members from the seven families

Table 1 Distribution of different stages (number of eyes) of CACD within the families (no. of patients in parentheses)

Family	Stage				Total
	I	II	III	IV	
Gu.	—	4	5	7	16(8)
Ja.	4	—	2	8	14(7)
Si.	2	—	2	—	4(2)
Sta.	2	—	—	4	6(3)
Te.	—	3	3	2	8(4)
Ho.	—	4	2	—	6(3)
Li.	—	1	4	1	6(3)
Total	8	12	18	22	60(30)

Table 2 Age distribution according to the various stages of CACD

Age (years)	Stage			
	I	II	III	IV
20-30	3	3	1	—
30-40	1	1	1	—
40-50	—	2	4	3
50-60	—	—	4	5
60-70	—	1	2	5

Table 3 Visual acuity (eyes) in various stages of CACD (CF counting fingers)

Visual acuity	Stage			
	I	II	III	IV
1.0	8	9	2	—
0.6–0.8	—	3	8	—
0.3–0.5	—	—	5	—
0.1–0.25	—	—	3	6
F (at 3–5 m)	—	—	—	2
CF (at 0.5–2 m)	—	—	—	14

years (mean 46 years). In the ten female patients who mentioned the age of onset, the range was from 25 to 52 years (mean 45.2 years). Eight patients had no visual complaints, and in another eight the age of onset was unknown.

Although the relatively small group of patients makes statistical deductions difficult, there seemed to be no difference in the age of onset between male and female cases.

The visual acuities of the eyes of patients in the family studies and of sporadic cases, according to stage of CACD, are given in Table 3.

In stage I, funduscopy changes were characterized by slight hypopigmentation in the parafoveolar area. A normal foveal reflex was observed. In all patients, slight pigmentary changes were not obvious in indirect ophthalmoscopy. In three patients (Ja. III-3; Si. III-1 OS; Sta. II-1), this hypopigmentation could only be noted by means of a three-mirror contact lens, a 60-D lens or direct ophthalmoscopy. In two patients (Ja. III-9; Si. III-1 OD) these changes were still unclear or remained unobserved using these examination methods, but fluorescein angiography proved the presence of pigmentary alterations (Fig. 3). In stage II, hypopigmentation surrounding the fovea was already obvious in indirect ophthalmoscopy. The diameter of the area of hypopigmentation varied from rather more than one disc diameter (Gu. IV-45; Te. III-5; Te. IV-10) in younger patients to more than two disc diameters in middle-aged patients (Gu. II-17; Ho. III-1, III-2; Li. III-4). Hyperpigmentation, sometimes in a radial configuration, as could be seen in fluorescein angiography (Fig. 4), was not obvious with either of the methods of funduscopy. Although stage III is char-

Table 4 Results of the photopic and scotopic ERG and of the EOG in patients in whom these tests were performed

Stage	Photopic ERG		scotopic ERG	EOG light-rise
	a-wave (μ V)	b-wave (μ V)	b-wave (μ V)	
I (n=4)	-52.5 ± 17.9	142.5 ± 21.7	252.5 ± 32.7	3.17 ± 0.14
II (n=12)	-63.3 ± 15.9	96.3 ± 33.2	211.3 ± 83.0	1.91 ± 0.19
III (n=12)	-46.3 ± 14.0	100.8 ± 37.0	207.1 ± 95.1	2.43 ± 1.43
IV (n=8)	-61.3 ± 16.2	83.8 ± 29.5	230 ± 55.5	2.49 ± 1.27

Table 5 Results of colour vision tests in 40 eyes of 20 patients (DRS diminished red sensitivity)

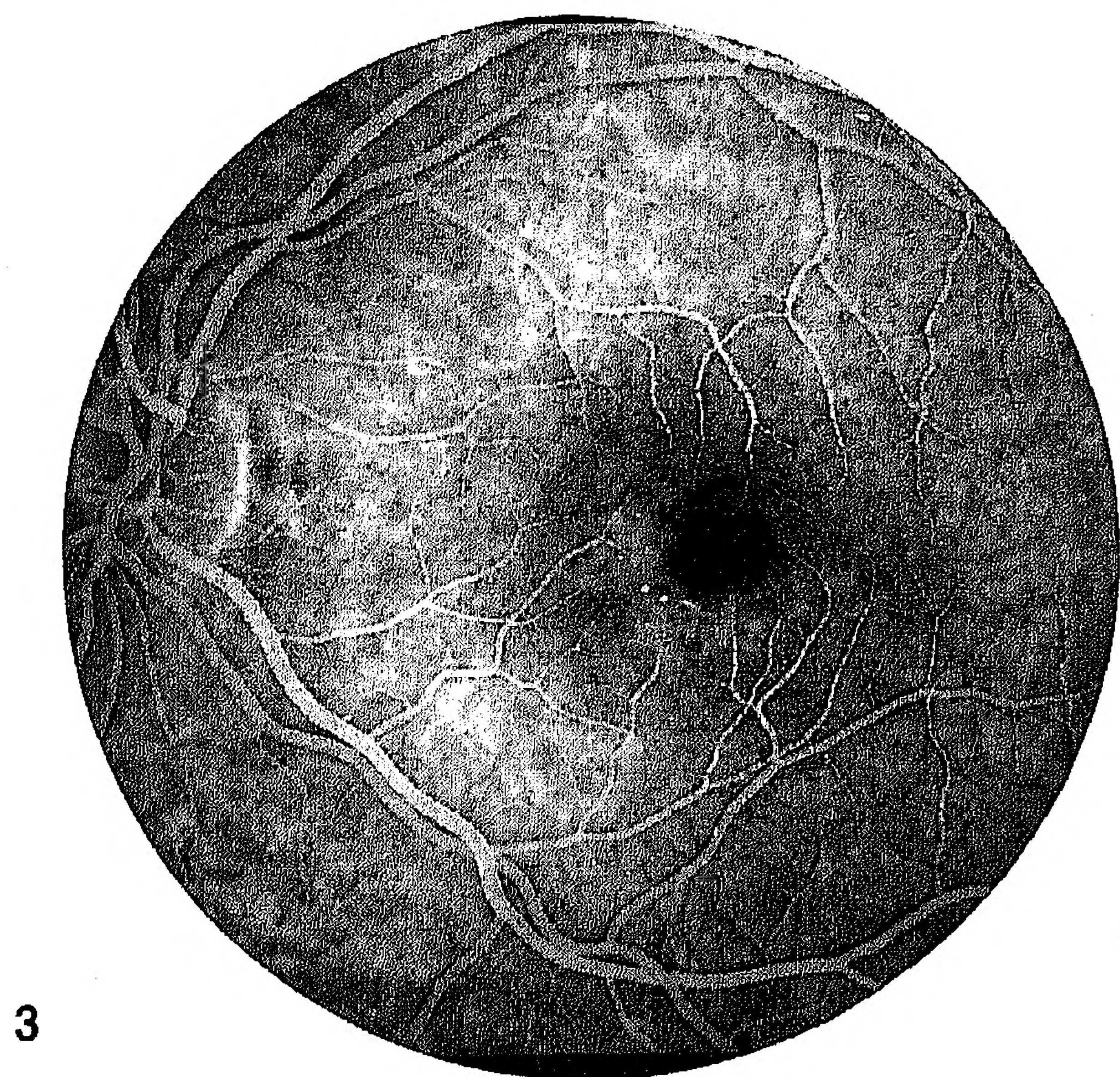
	Stage			
	I	II	III	IV
Normal	2	6	—	—
DRS (incl. pseudoprotanomaly)	2	3	—	—
B–Y defect (incl. DRS)	—	3	4	—
R–G defect (incl. DRS)	—	—	2	—
R–G + B–Y defect (incl. DRS)	—	—	12	6

Table 6 Results of visual field tests in 26 eyes of 13 patients

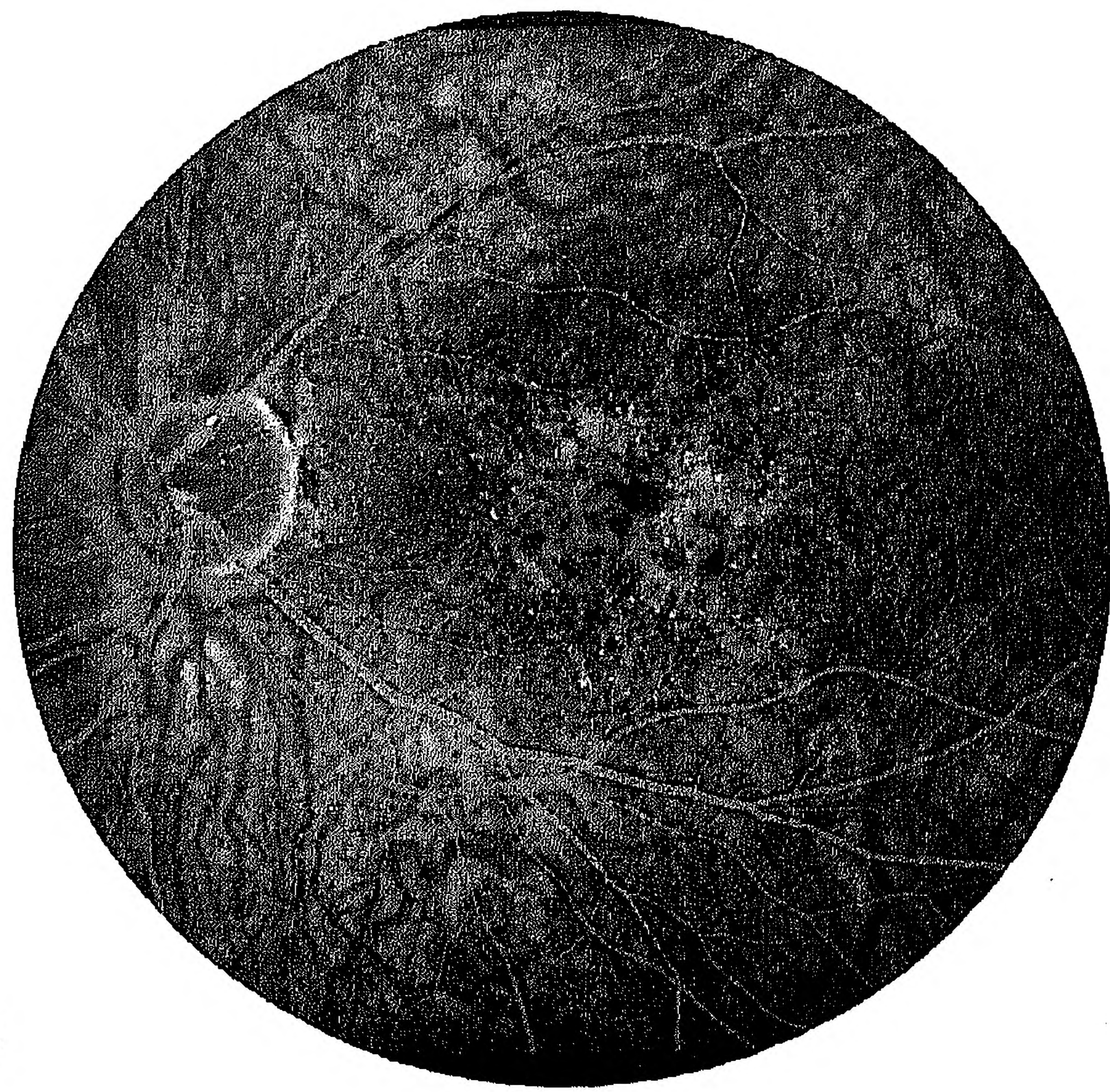	Stage			
	I	II	III	IV
Normal	2	1	2	—
Paracentral reduced sensitivity	2	3	2	—
Central reduced sensitivity	—	2	3	—
Pericentral scotoma	—	—	4	—
Central scotoma	—	—	1	—
Pericentral and central scotoma	—	1	4	1

acterized by one or more areas of atrophy of the choriocapillaris, the phenomenon was not always obvious when either funduscopy technique. In fluorescein angiography, however, these lesions were obvious (Fig. 5). When the atrophy of the choriocapillaris and retinal pigment epithelium was visible in funduscopy, lesions showed a rather golden-yellowish aspect with increased visibility of the underlying choroidal vessels. In all cases with stage IV, the atrophy of pigment epithelium and choriocapillaris was observed in funduscopy and fluorescein angiography (Fig. 6).

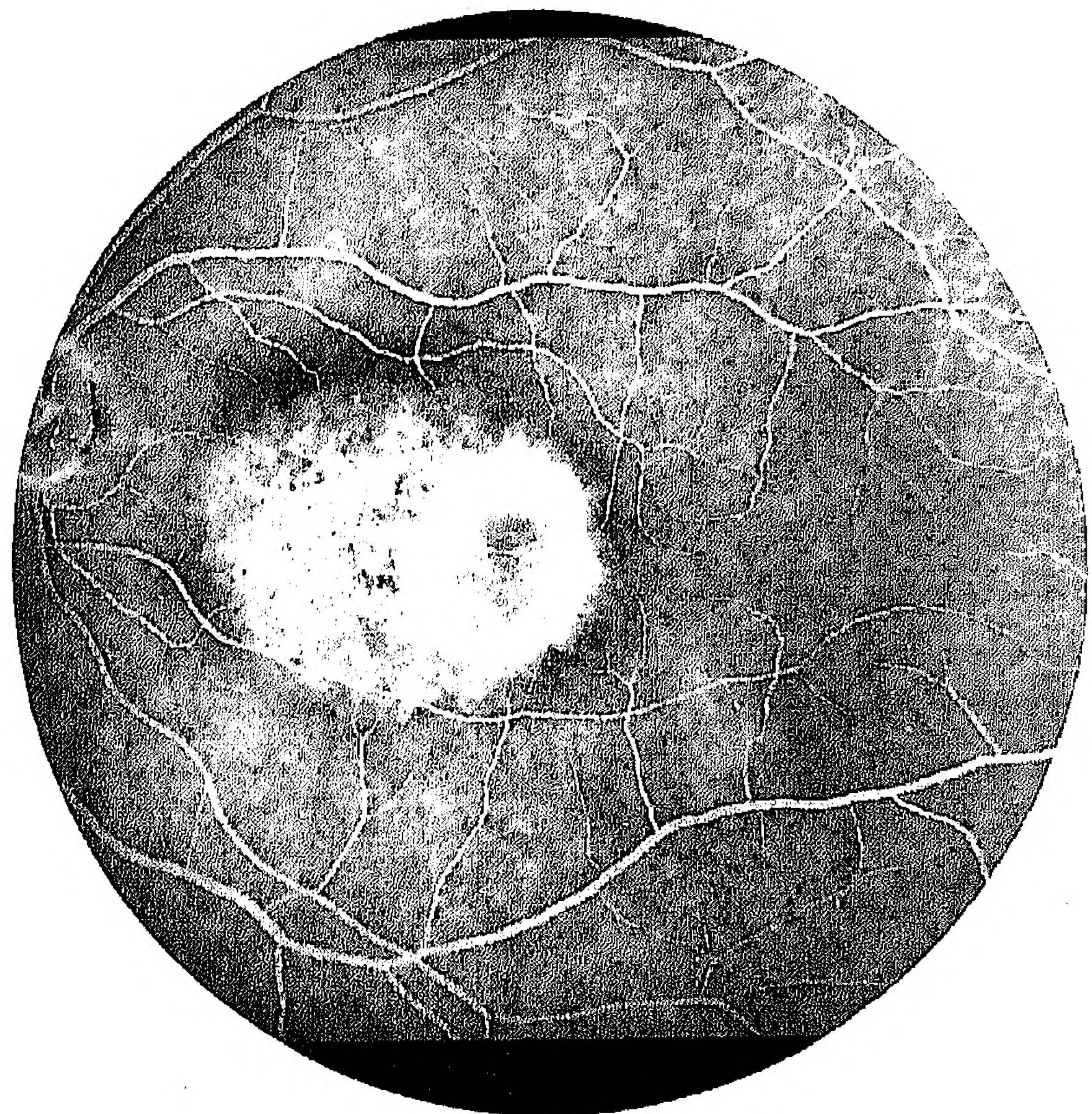
Recorded electric potentials of the photopic and scotopic ERG are listed in Table 4. In stage I CACD these results were normal. Among 12 eyes with stage II, subnormal responses were found in 7 eyes in the photopic ERG and in 2 eyes in the scotopic ERG. In 12 eyes with stage III, subnormal responses were found in 4 and 3 eyes in the photopic and scotopic ERG, respectively. In 8 eyes with stage IV CACD, 4 subnormal responses were recorded in the photopic ERG and no abnormal results were found under scotopic conditions.



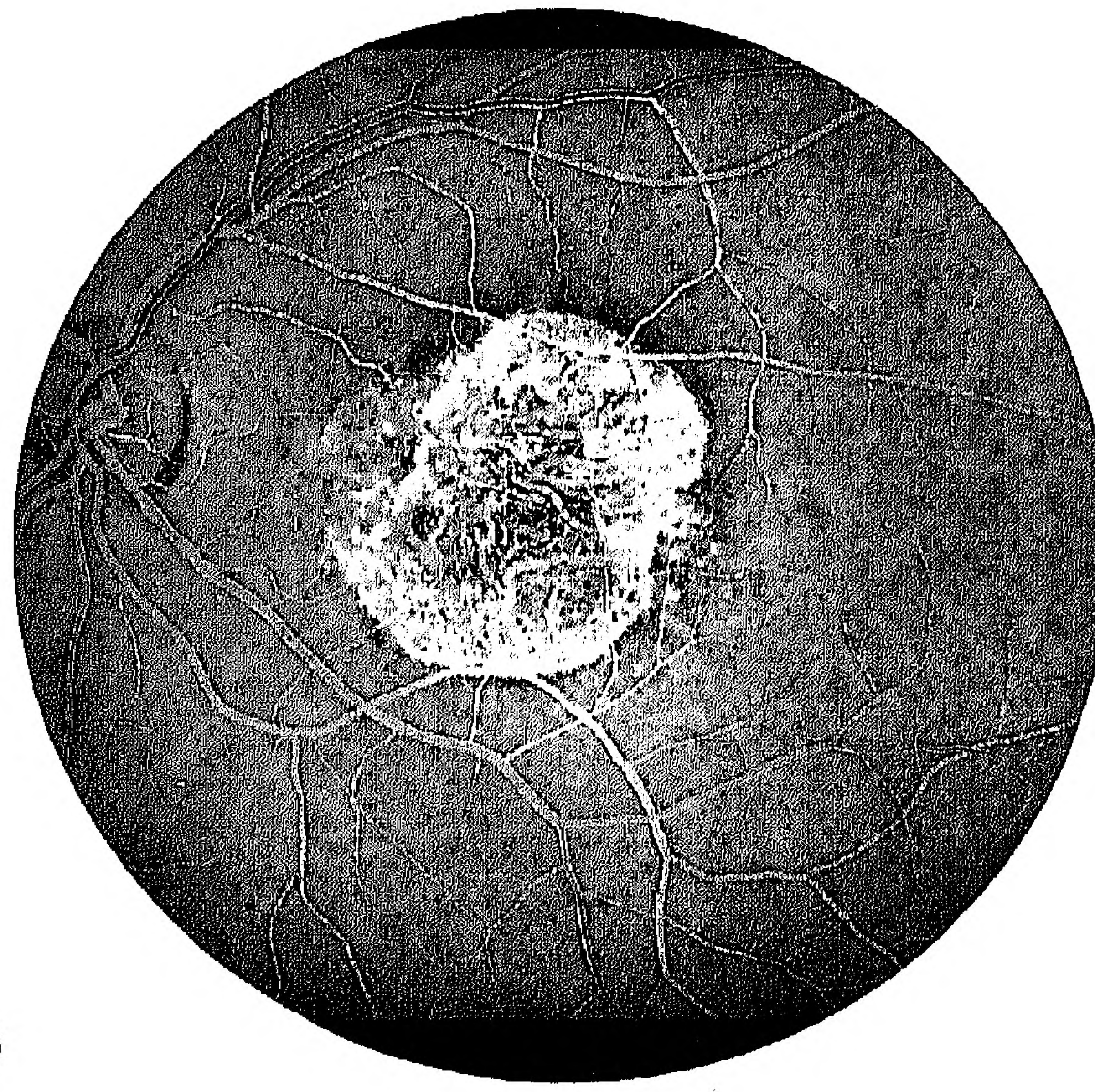
3



4



5



6

Fig. 3 Stage I CACD. Slight hypo- and hyperfluorescent spots are located in the lower quadrants of the parafoveal area

Fig. 4 Stage II CACD. Hyperfluorescent spots encircling the fovea

Fig. 5 Stage III CACD. Demarcated area of atrophy of the pigment epithelium and choriocapillaris just outside the fovea. In the later phase of the angiogram, dye leaks from the border of choriocapillaris atrophy

Fig. 6 Stage IV CACD. Well-delineated area of atrophy of the pigment epithelium and choriocapillaris. The fovea is affected

In 12 eyes with stage II, 13 eyes with stage III and 9 eyes with stage IV CACD, a slightly abnormal Lp/Dt ratio was found in 4, 5 and 2 eyes, respectively.

The results of colour vision testing (Table 5) are arranged in order from defects found in macular damage with foveal fixation (diminished red sensitivity, includ-

ing pseudoprotanomaly; blue-yellow defect, including diminished red sensitivity) to defects found in macular lesions with eccentric fixation (red-green defect or combined red-green and blue-yellow defect, including in both cases diminished red sensitivity).

The results of the static visual field tests are arranged in Table 6 in an order from reduced paracentral or central sensitivity to absolute paracentral and/or central scotomas.

Discussion

Sandvig [10] was the first to report CACD in four generations of one family, and stated that this was conclusive evidence for an autosomal dominant mode of heredity.

Since his publication, only four other families have been reported [1, 4, 6, 8].

In this study, we present the clinical findings for the largest group of patients suffering from CACD ever described. We examined 30 members of seven families in which two or more generations were affected, paying special attention to the stages of CACD preceding the atrophic end-stage.

Because in CACD complaints about loss of vision develop from the age of about 30–50 years, the generations in which visual impairment is to be expected must be scrutinized in order to determine how many members of one sibship are affected. Family Si. will not be discussed further, because none of the relatives of patient Si. II-1 in earlier generations are known to have had a visual handicap. Two deceased siblings of family Sta. will also not be taken into account, because they died young. This leaves 44 siblings in six pedigrees: generation III in family Gu., II in family Ja., II in family Sta., III in family Te., II in family Ho. and II in family Li. In these generations, siblings younger than 55 years of age were examined. They were at 50% risk assuming autosomal dominant inheritance. Since 22 of these 44 (11 males and 11 females) indeed proved affected, these data proved fully compatible with autosomal dominant heredity, with complete penetrance from the age of 50.

Thirty-six members aged between 20 and 40 years, from seven families, were examined. On the basis of autosomal dominant heredity, with 100% penetrance, the expected number of symptomatic cases would be 18. However, nine members were found to be affected. This means that an age-dependent penetrance of approximately 50% was established for the age group of 20–40 years.

CACD revealed itself to be a slowly progressive disease leading to a well-defined area of atrophy of the photoreceptors, pigment epithelium, choriocapillaris and smaller choroidal vessels confined in the posterior pole.

No very young patients with obvious macular changes, as described by Carr [1], were encountered. The first angiographic findings in our patients were small parafoveal window defects. In stage II the hyperfluorescent areas were concentrated around the fovea. Sometimes a radial configuration of hypofluorescent spots imitated a pattern dystrophy. Together with fluorescein angiography, colour vision tests (Table 5) and visual field tests (Table 6) are very helpful in diagnosing CACD in the early stages.

Visual deterioration developed in patients in their mid-40s. Visual acuity in patients with stage III CACD was in general only moderately affected, to a level of 0.8–0.6 (Table 3). Additional choriocapillaris atrophy, arising at this stage, led to paracentral scotomas, experienced as inconvenient by the patients. Recorded electric potentials in the photopic ERG were reduced in about

50% of the patients in stages II and III (Table 4). The red-green defect often found in colour vision tests and a reduced central sensitivity in visual field testing indicate that, although atrophy of the choriocapillaris cannot yet be seen in the fovea, the central photoreceptors are already affected to some extent at this stage. In a very few patients from stage II onwards, the electric potentials in the scotopic ERG and the EOG values were diminished. However, these values were only slightly abnormal. Therefore, we could not confirm Carr's suggestion [1] that this disease is probably more widespread than has been supposed.

On the basis of the findings in this study, the classification of the disease was expanded as follows:

Stage I: Age 20–40 years; visual acuity is normal; parafoveal pigmentary changes may be found in funduscopy, but are evident in fluorescein angiography; ERG and EOG are normal; diminished red sensitivity with pseudoprotanomaly and decreased parafoveal sensitivity may be found in colour vision and visual field tests.

Stage II: Age 20–50 years; sometimes visual complaints occur; parafoveal hypopigmentation evident in funduscopy; mottled hyperfluorescence in fluorescein angiography; photopic ERG may be subnormal; colour vision and visual fields as in stage I.

Stage III: Most patients are over 40 forty years of age; visual acuity is moderately reduced; parafoveal atrophy of the pigment epithelium occurs; atrophy of the choriocapillaris is not seen in funduscopy, but may be evident in fluorescein angiography; photopic and scotopic ERG and EOG values may be slightly subnormal; a blue-yellow colour vision defect is often accompanied by a red-green defect; parafoveal and foveal reduced sensitivity are demonstrated in visual field tests.

Stage IV: Age 40–70 years; visual acuity is generally below 0.1; a demarcated central area of atrophy of pigment epithelium and choriocapillaris is evident in funduscopy and fluorescein angiography; ERG and EOG as in stage III; combined blue-yellow and red-green colour defect; central scotoma in visual field tests.

The question arises of whether the primary defect in CACD is located in the photoreceptor cells, in the pigment epithelium or in the choriocapillaris. The small defects in the parafoveal pigment epithelium, the blue-yellow colour vision defects and the reduced parafoveal sensitivity in the visual field tests found in the early stages of CACD suggest that the primary defect is located at the level of the retinal pigment epithelium. Recently, however, mutations in the retinal degeneration slow (*rds*) gene, which codes for peripherin, a protein predominantly found in the membranes of the outer segments of rods and cones, have been implicated as a cause of macular dystrophy. This autosomal dominant dystrophy, found in three sibships, closely resembles CACD [14].

No therapy is available for CACD, and it seems unlikely that one will be developed in the near future. Neverthe-

less, it is important to detect the early stages of CACD, because this diagnosis can exercise considerable influence on the patient's subsequent life.

Future research should be aimed at the localization and subsequent isolation and examination of the gene or genes responsible for the natural course of CACD.

References

1. Carr RE (1965) Central areolar choroidal dystrophy. *Arch Ophthalmol* 73: 32-35
2. Carr RE, Mittl RN, Noble KG (1975) Choroidal abiotrophies. *Trans Am Acad Ophthalmol Otolaryngol* 79: 796-816
3. Deutman AF (1971) The hereditary dystrophies of the posterior pole of the eye. Thomas, Springfield, Ill, pp 409-425
4. Franceschetti A, Francois J, Babel J (1963) *Les Héredo-dégénérescences chorioretiniennes*, vol II. Masson, Paris, pp 627-646
5. Hoyng CB, Pinckers A, Deutman AF (1990) Early findings in central areolar choroidal dystrophy. *Acta Ophthalmol* 68: 356-360
6. Hutter H, Marquardt R (1989) Zentrale areoläre Aderhaut-Dystrophie. *Klin Monatsbl Augenheilkd* 195: 177-180
7. Krill AE (1977) Hereditary retinal and choroidal diseases, vol II. Harper and Row, Hagerstown, pp 939-961
8. Noble KG (1977) Central areolar choroidal dystrophy. *Am J Ophthalmol* 84: 310-318
9. Pinckers AJLG (1980) Colour vision and age. *Ophthalmologica* 181: 23-30
10. Sandvig K (1955) Familial central areolar choroidal atrophy of autosomal dominant inheritance. *Acta Ophthalmol* 37: 71-78
11. Sandvig K (1959) Central areolar choroidal atrophy. *Acta Ophthalmol* 37: 325-329
12. Sorsby A (1935) Choroidal sclerosis. *Proc R Soc Med* 28: 526-528
13. Sorsby A, Crick RP (1953) Central areolar sclerosis. *Br J Ophthalmol* 37: 129-139
14. Wroblewski JJ, Welss III JA, Eckstein A, Fitzke F, Jubb B, Keen J, Inglehearn C, Bhattacharya S, Arden GB, Jay M, Bird AC (1994) Macular dystrophy associated with mutations at codon 172 in the human retinal degeneration slow gene. *Ophthalmology* 101: 12-22