

PDF hosted at the Radboud Repository of the Radboud University Nijmegen

The following full text is a publisher's version.

For additional information about this publication click this link.

<http://hdl.handle.net/2066/22607>

Please be advised that this information was generated on 2017-12-05 and may be subject to change.

Akinetic mutism with bithalamic infarction. Neurophysiological correlates

Peter H.M.F. van Domburg^{a,*}, Hans J. ten Donkelaar^b, Servaes L.H. Notermans^c

^a Department of Neurology, University Hospital Nijmegen, Reinier Postlaan 4, P.O. Box 9101 6500 HB Nijmegen, The Netherlands

^b Department of Anatomy and Embryology, Faculty of Medical Sciences, University Hospital, Nijmegen, The Netherlands

^c Department of Clinical Neurophysiology, University Hospital, Nijmegen, The Netherlands

Received 5 June 1995; revised 5 December 1995; accepted 19 December 1995

Abstract

A 42-year-old man presented with akinetic mutism, caused by bilateral thalamic infarction, resulting in a temporary amnesic syndrome and, finally, selective downgaze palsy. Electroencephalographic recording in the initial phase showed generalized spike-and-wave discharges, similar to those found in animal studies after lesion or stimulation of specific thalamic nuclei. Analysis of magnetic resonance images (MRI) of the head showed that the centre of ischemic necrosis particularly involved the intralaminar thalamic nuclei and a small part of the rostral mesencephalon. The findings support the previously suggested involvement of cortico-thalamo-mesencephalic circuitry in the initiation of motor responses, and the association of the non-specific thalamic nuclei with the appearance of generalized epileptiform phenomena in cases of reduced vigilance.

Keywords: Thalamus; Thalamopeduncular artery; Spike-and-wave discharges; Akinetic mutism

1. Introduction

The uncommon ischaemic vascular disorders of the thalamus can be classified into four clinical syndromes, depending on the vascular territory involved (Percheron, 1973; Graff-Radford et al., 1985; Bogousslavsky et al., 1988). Obstruction of the so-called thalamopeduncular (perforant or paramedian) artery (PTA, see Fig. 1) results in a bilateral (meso-)thalamic lesion, generally including parts of the nonspecific intralaminar as well as of the dorsomedial nuclei (Castaigne et al., 1981; Bogousslavsky et al., 1988). The clinical symptoms include varying changes of consciousness, supra-nuclear ophthalmoplegia, apathetic behavior and an amnesic syndrome, generally with a rather favourable prognosis (Castaigne et al., 1981; Guberman and Stuss, 1983; Tatemichi et al., 1992).

Clinical experience suggests a linkage of arousal state with the occurrence of epileptiform changes in certain cases. The association of this phenomenon with the suggested thalamic control of neocortical activation, mainly based on animal studies, has been the subject of much

dispute (Steriade and Llinás, 1988; Vanderwolf and Stewart, 1988; Gloor et al., 1990). The clinicoanatomical and electrophysiological findings in our case provide further evidence for this association in man.

2. Case report

A 42-year-old man was admitted to hospital, after he could not be woken up normally in the morning. The preceding time he worked as a public servant and was in good health with normal intelligence. His medical history was inconspicuous and he had no predisposition to epilepsy. On admission he presented with a sleep-like state, with double incontinence, sometimes alternated by short periods of restlessness. His blood pressure was 150/90, and he had normal regular pulsations of carotid arteries, normal body temperature and ECG findings. On neurological examination there were no signs of meningeal irritation, he had narrow pupils that did not react to light and the eyes remaining in mid-position. The reactions to painful stimuli were predominantly stretching of extremities and some facial pain expression. Examination of blood and cerebrospinal fluid (including metabolites of monoamines)

* Corresponding author. Tel: +31 (24) 611111; Fax: +31 (24) 541122.

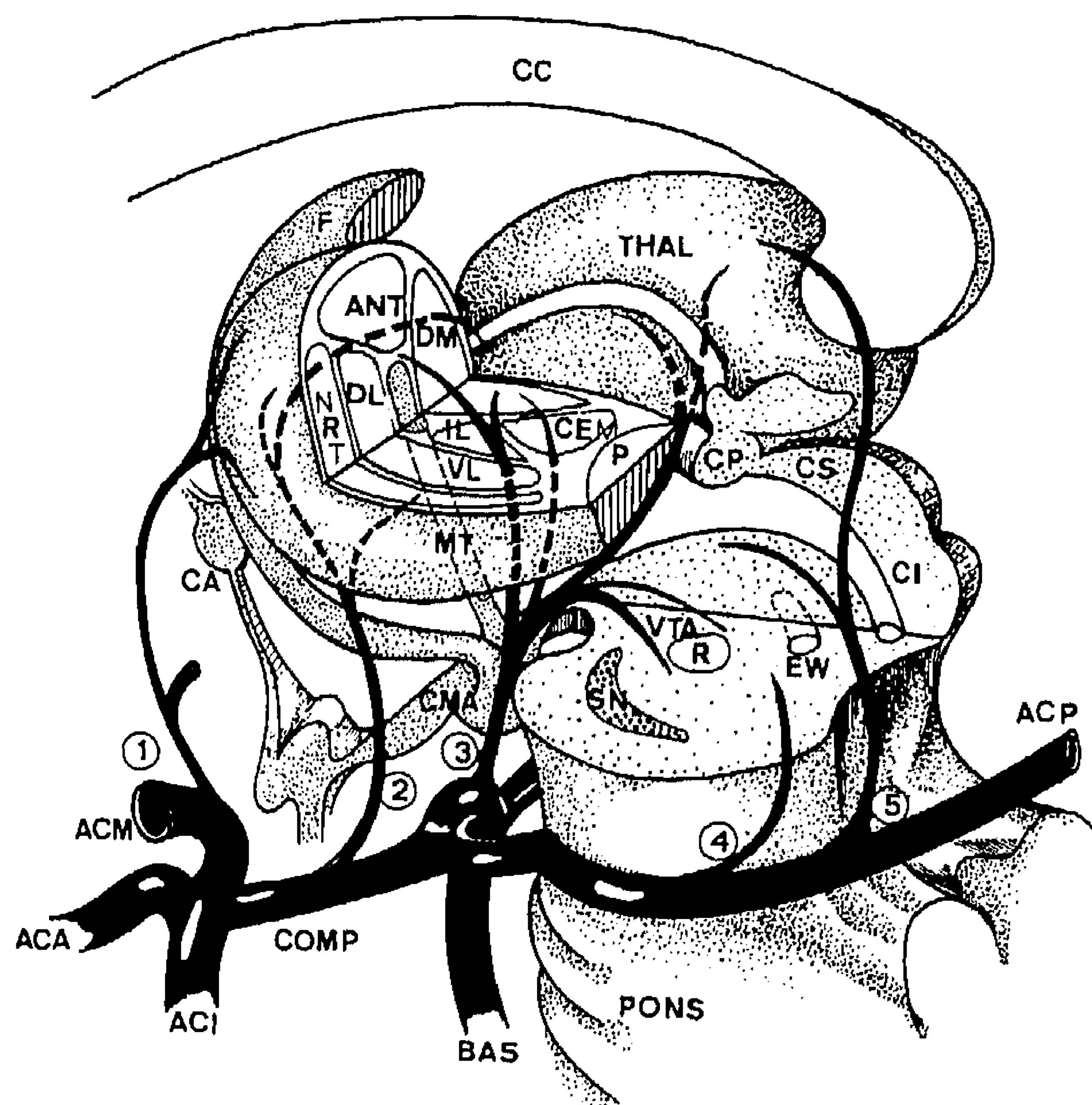


Fig. 1. Schematic representation of the vascular supply of thalamic subdivisions (mainly based on Percheron, 1973 and Schlesinger, 1976). 1 = Anterior choroidal artery; 2 = polar artery (inaccurate: tuberothalamic artery); 3 = thalamopeduncular (thalamo-subthalamic or interpeduncular) artery (TPA); 4 = inferolateral choroidal artery (geniculothalamic artery); 5 = posterolateral choroidal artery; ACA = anterior cerebral artery; ACI = internal carotid artery; ACM = medial cerebral artery; ACP = posterior cerebral artery; ANT = anterior thalamic nucleus; BAS = basilar artery; CA = anterior commissure; C(e)M = centre médian (central medial thalamic nucleus); cc = corpus callosum; CI = colliculus inferior; CMA = corpus mamillare; COMP = posterior communicating artery; CP = posterior commissure; CS = colliculus superior.

showed no abnormalities. From the third day onward there was a gradually restoring gaze: The patient thus seemed to pay attention to his immediate surroundings, yet there was not any response to various stimuli. One week after admission the patient still showed this akinetic and mute state, with a normal sleep-waking-cycle, double incontinence and without particular signs of motor or sensory impairment. A symmetrically ring-shaped paramedian bilateral thalamic lesion with contrast enhanced surrounding (penumbra) was shown on the CT scan (Fig. 2). No source of septic or thrombotic embolization could be found by cranial angiography, but trans-esophageal echocardiogram was not performed. There were normal peak serum levels of homocysteine after a standard methionine loading test.

During the second and third week of recovery spontaneous body movements gradually returned. There was still no adequate response to stimulation, however, and a tendency to automatisms or stereotypic movements: He managed to handle his guitar (he used to play at home), in a manner suggestive of playing, without evidence of conscious participation and continuing the movements when the instrument was taken away. At other times he rubbed his belly aimlessly for a long period without signs of

discomfort. During the third week the mute state changed into a hypokinetic state, with incidental inadequate emotional expressions. He gradually began to talk excessively, though largely unintelligibly, often slurred and indistinctly, sometimes with delusional or annoying expressions. What struck his wife and the nursing staff was a growing lability of affect without evidence of conscious participation. The twenty-third day after the onset of illness he walked away from the ward, without clear purpose, fearing that the nursing staff intended to keep him confined indefinitely. Although disoriented and confused, he gradually began to answer simple questions, such as "where do you live?", correctly although with few words. Yet the cooperation in clinical or neuropsychological tests remained wanting. During the fourth week the conditions of the Raven Progressive Matrices and the Hooper test (visual organization) were partially met with. He appeared incapable to settle a simple block pattern. He showed constructional apraxia and could not retain a simple story. Performance on the Trail Making Test was very poor. During the fifth week semantic paraphasias and word-finding disturbances were recognizable. The amnesic syndrome was reflected in a poor Wechsler Memory Scale (WMS) score of 74 in the fourth week, recovering to estimated premorbid level of 135 at fifteen months. After a clinical revalidation period, he had become independent for daily activities, although very slow, after three quarters of a year. There was still poor performance on the Trail Making Test then, suggesting lack of concentration. Wechsler Adult Intelligence

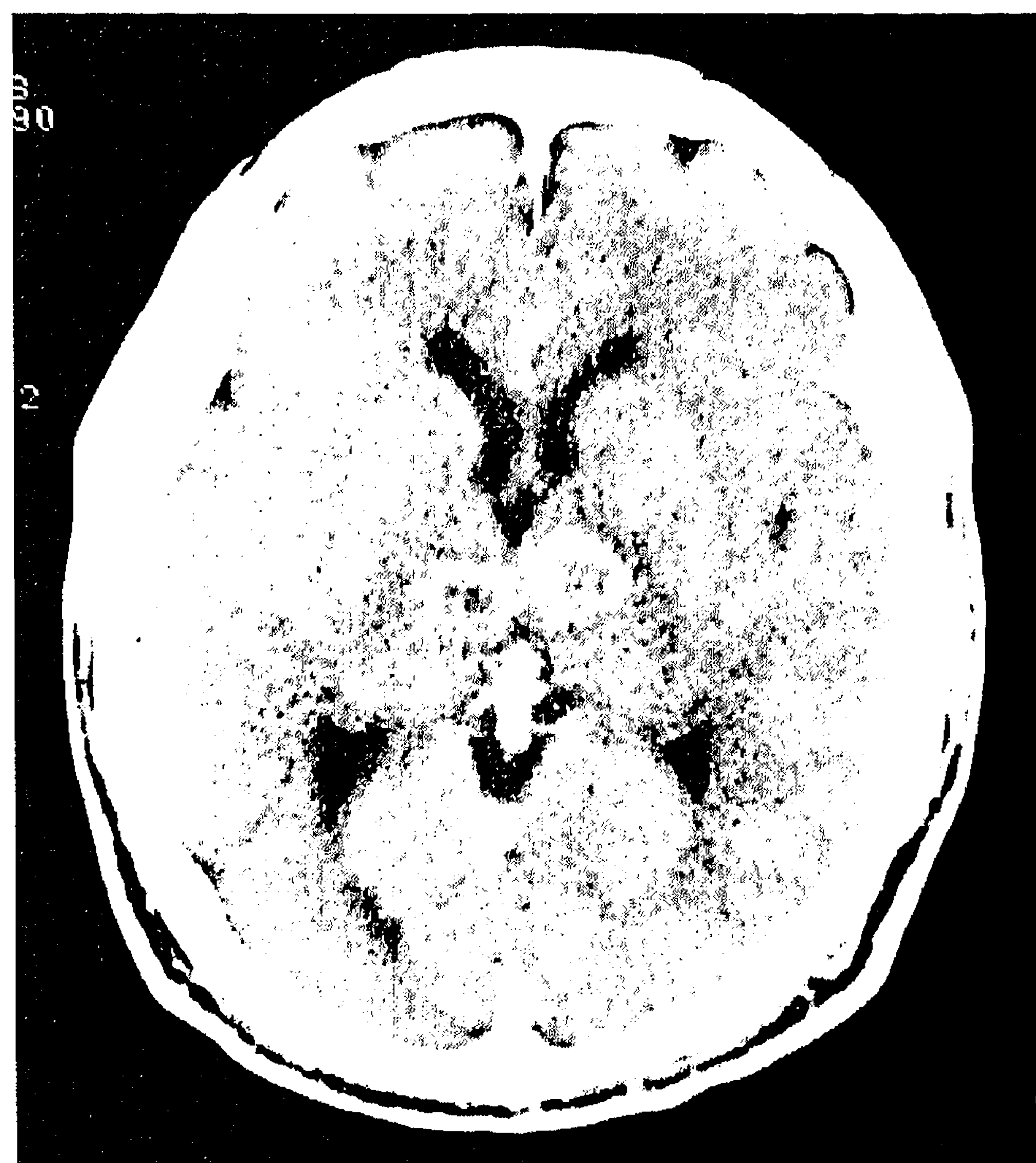


Fig. 2. CT-scan image (transversal section) obtained at the 9th day of admission.

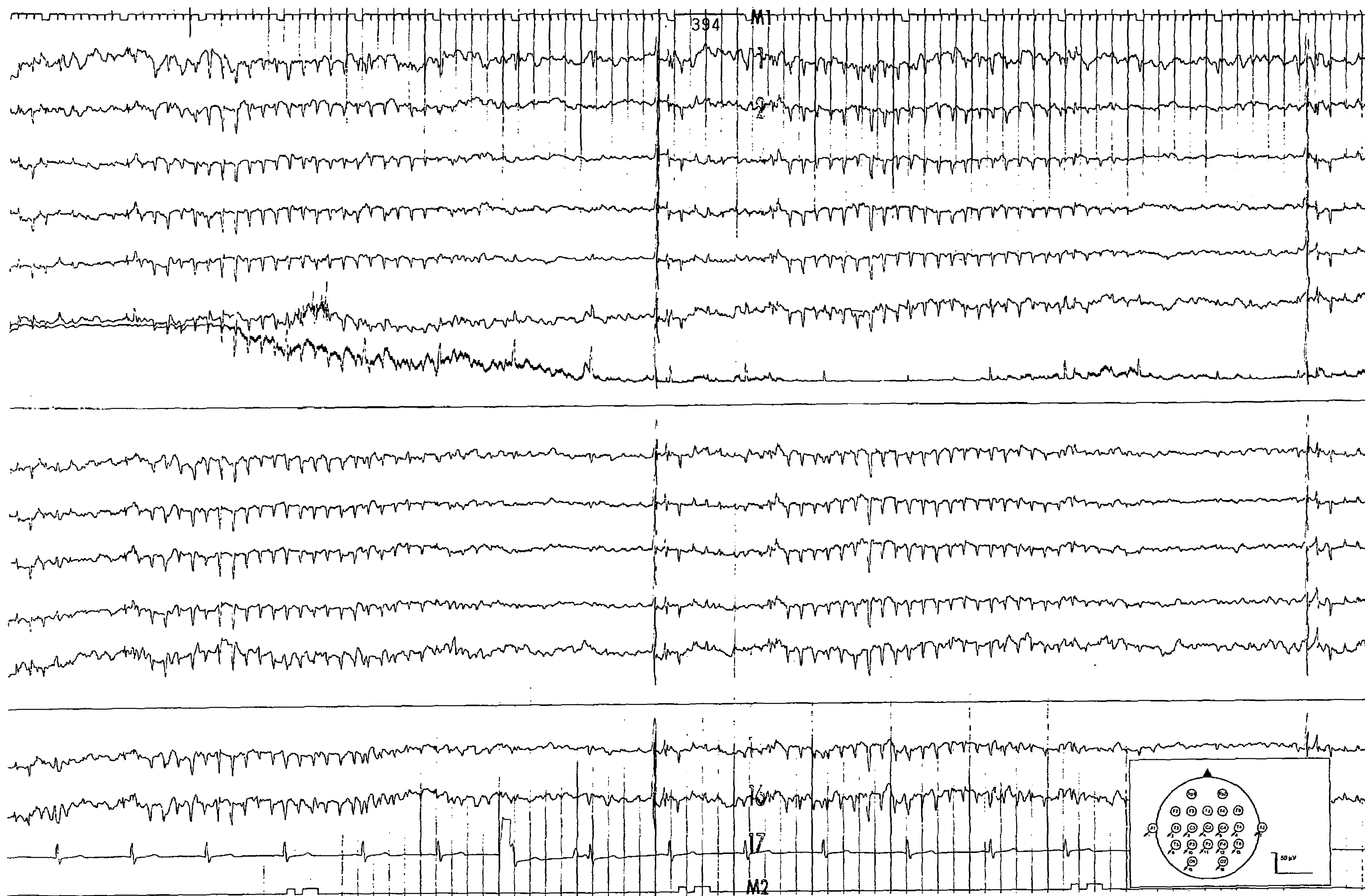


Fig. 3. Section of the EEG registration obtained at the first day of admission. Unipolar indifferent reference. Amplification $50 \mu\text{V}/10 \text{ mm}$, time constant 1.0 s, Hf filter 70 Hz, paper speed 30 mm/s.

Score (WAIS) was reliably calculated 118/94 (for verbal and performance score, respectively) at twelve months and 125 at fifteen months after admission. Selective downgaze palsy, with incapacity to read or write, loss of initiative, absent-mindedness, slightly disturbed balance and difficulty in performing combined tasks or precise movements were the remaining signs. After one year he resumed his former job partially under adapted circumstances. Two years after admission there was only selective downgaze paresis, slight inertia and complete recovery of overall intelligence, learning capability and retention.

2.1. Electrophysiological findings

Electroencephalographic (EEG) recordings were performed at the day of admission (day 1), days 2 and 8 and about 1 month later. The initial registration showed generalized slowing of background activity, loss of differentiation and some varying activity, diffusely spread, in the alpha range (8–9 Hz). A tendency to dys-regulation of irregular delta bursts was most pronounced fronto-centro-temporally. As shown in Fig. 3 there were some repeated bursts of generalized slow-wave and spike-and-wave (SW) discharges of 6/s, interrupted by desynchronisation of about 2 s, at the initial recording. The patient clinically remained in an unchanged akinetic mute state. Follow-up recordings gradually showed recurrence of normal background activity, gradual decline of centrottemporal dysregulation and no further signs of epileptiform activity or hypersynchronization.

Somatosensory evoked potentials (SSEP) of the median and sural nerve, recorded on Neuropack Four mini (Nihon Kohden) apparatus, at day 13, revealed symmetric normally shaped early components, normal peak latencies and inter-peak intervals, but atypically shaped later (cortical) components. These SSEP findings provided further evidence for the more ventrolaterally located sensory relay thalamic nuclei not being involved in an early phase (Graff-Radford et al., 1985; Moriaka et al., 1989).

2.2. Magnetic resonance imaging (MRI) and neuroanatomical localization

A Philips 1,5 tesla MRI scanner was used to obtain 5-mm thick horizontal, coronal and sagittal T1 and T2-weighted inversion recovery MRI cuts. This examination was performed two months after admission in order to establish an eventual necrotic area. The initial hypofunctional penumbra (shown as a contrast enhanced area on CT in Fig. 2) probably has been somewhat more extensive, particularly involving a larger central thalamic region. The (intercommissural) line connecting anterior and posterior commissure (APC) was used as a reference for the stereotaxical demarcation of the hypodense area on MRI cuts (Fig. 4). The centre of the hypodense area in the right thalamus was located at about 10 mm laterally from the

median sagittal plane and between 7 and 15 mm behind the anterior commissure. On the transversal cuts it is identifiable at the level of the APC-line and at the slice 9 mm higher. Using the stereotaxic atlas of Talairach and Tournoux (1988; Figs. 45–46, 82–83 and 117–119) as a reference, the thalamic nuclei involved were identified, including the antero-medial part of the ventral lateral nucleus, the lateral part of the dorsomedial nucleus and intralaminar nuclei, extending ventrally over the *centre médian* (CeM) and parafascicular (Pf) nuclear complex (Fig. 4. A–C). The mamillothalamic tract and some other traversing fibres may have been involved. Similarly the, somewhat smaller, lesion on the left side has its centre at the intralaminar level. At the mesencephalic level a very small hypodense area was located subthalamically in the pretectal ventral tegmental area, as is shown on the sagittal representation.

3. Discussion

Our patient did not seem to have special risk factors for vascular lesions. His rather young age is remarkable and this was also noteworthy for similar cases in other studies. We could trace 75 cases with thalamic paramedian infarction from the literature and counted a mean age of 58 years and, more specifically, 53 (19–81) years when the infarct was bilateral (52 cases). Because of their strategic localization, with otherwise intact cortical function, these lacunar infarcts may result in a particular transient dementia syndrome (Stuss et al., 1988), but generally show a mild outcome (Castaigne et al., 1981; Guberman and Stuss, 1983; Tatemichi et al., 1992). Cases of selective downgaze paralysis, as appeared in our patient (after temporary more extensive disconjugate ophthalmoplegia with narrow pupils), are rarely seen, and reflect the involvement of a small rostral mesencephalic midline area, supplied by small TPA branches (Halmagyi et al., 1978; Trojanowski and LaFontaine, 1981; Büttner-Ennever et al., 1982).

Apart from short coma, the particular changes of consciousness, reported in the initial stage of cases with bilateral (meso-)thalamic infarction included hypersomnia (Graff-Radford et al., 1985), pseudo-hypersomnia or pre-sleep behavior (Guilleminault et al., 1993), and akinetic mutism (Segarra, 1970; Castaigne et al., 1981). The clinical picture in our patient, particularly during the first week, meets the criteria of akinetic mutism, as originally drafted by Cairns (Cairns et al., 1941): ‘a condition in which the patient appears to be awake and may follow the examiner with his eyes, but spontaneous motor and verbal responses are lacking; he is doubly incontinent and responds incompletely to noxious stimuli, although not paralysed’. Apart from small lesions of the posterior diencephalon and adjacent midbrain, interrupting the paramedian reticular formation (MRF), akinetic mutism may be caused by large, bilateral, basal medial frontal lobe lesions, involving the

orbital cortex, septal area and cingulate gyri (Plum and Posner, 1982; Kurtz et al., 1988; Németh, 1988). The concept of a diffuse cortical dysfunction from reduced 'non-specific' MRF-thalamocortical activation, is mainly based on older literature (Cairns, 1952; Klee, 1961; Segarra, 1970), and may seem to be corroborated by PET-scan (Levasseur et al., 1992) and EEG studies (Németh, 1988).

The clinical impression, characteristically shown in our patient, is that of an early reappearance of arousal, suggested by permanently open eyes, normal blinking and recovering gaze, yet without evidence of adequate psychomotor response. There was neither a tendency to take a sleep posture (Guilleminault et al., 1993), nor could the patient be pulled out of his hypokinetic and mute state

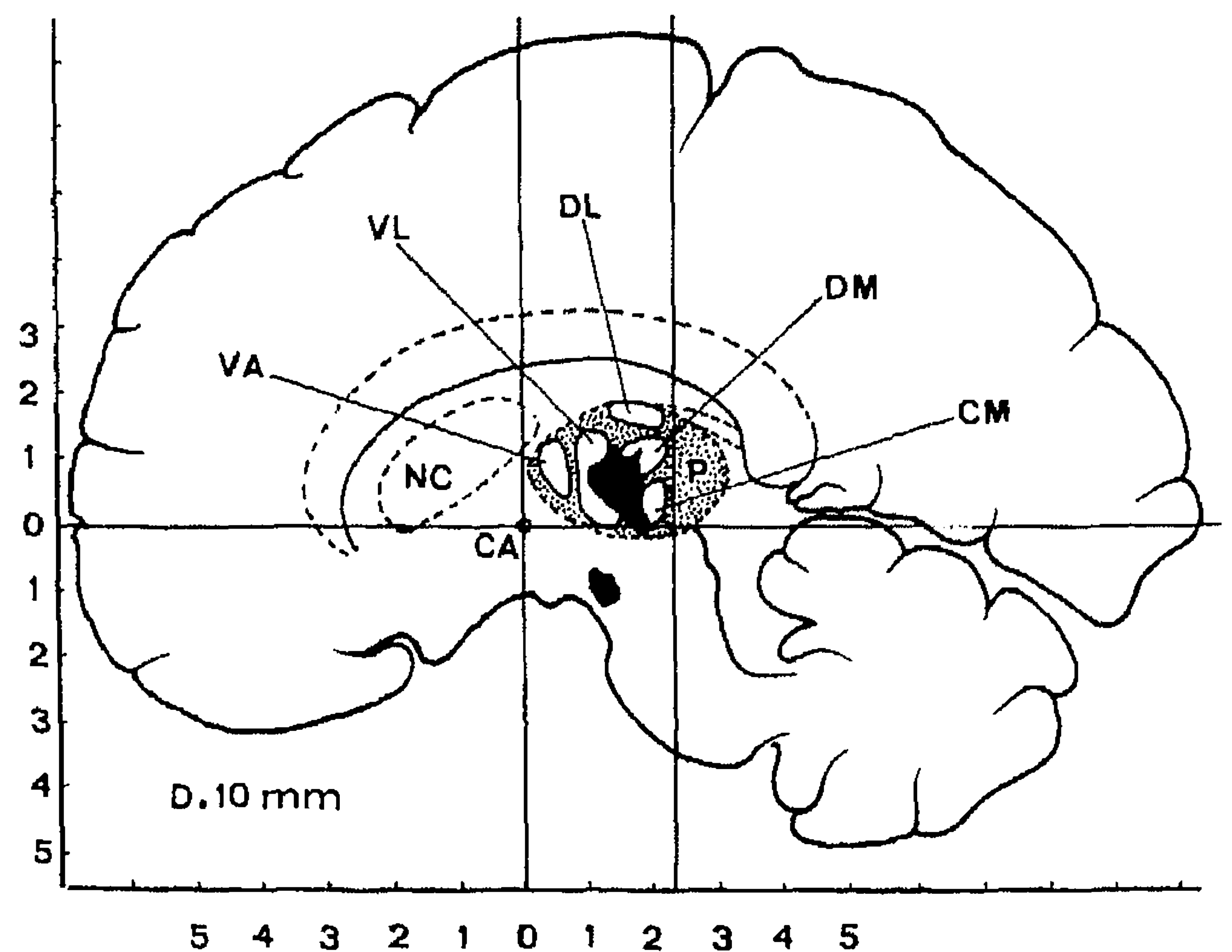
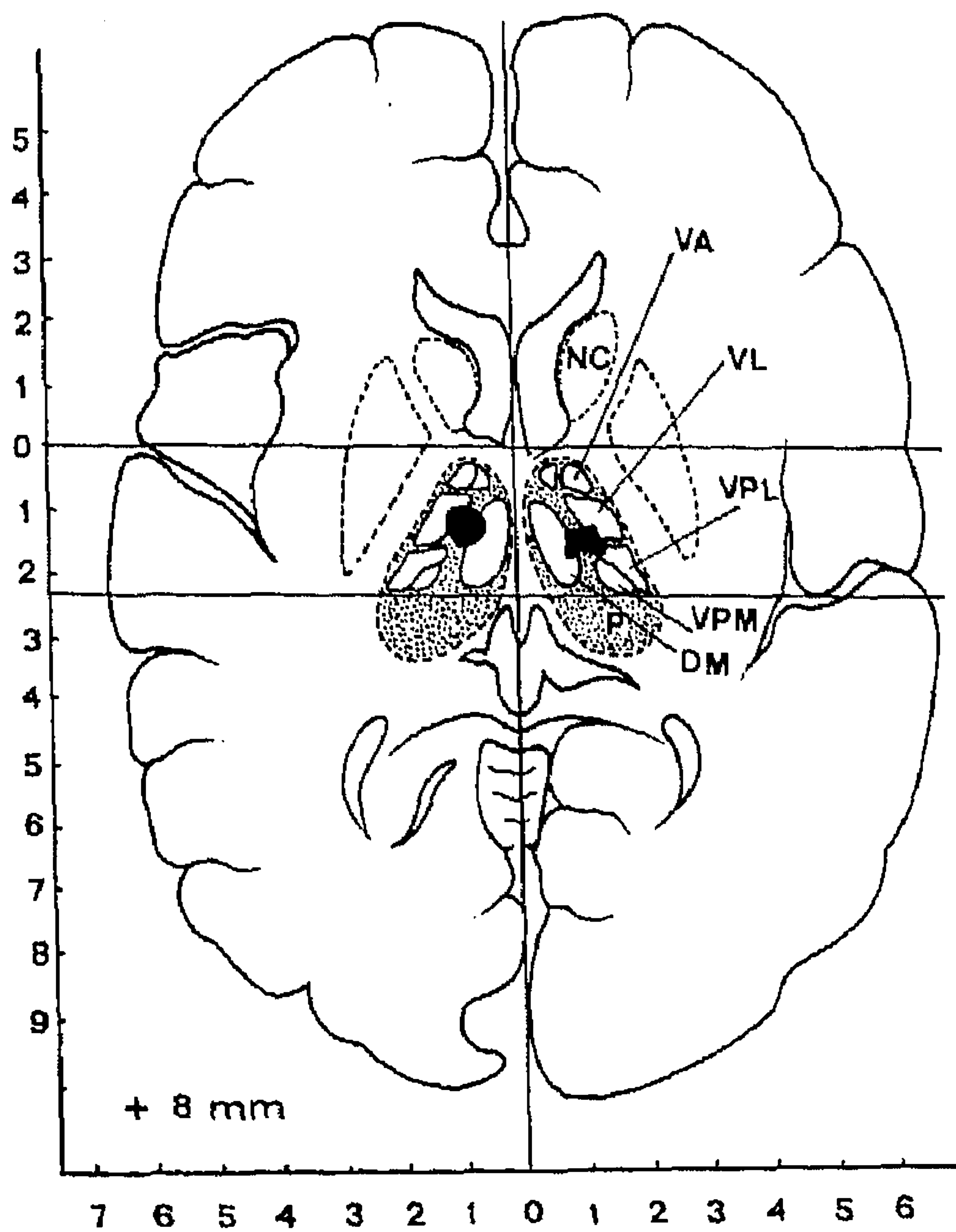
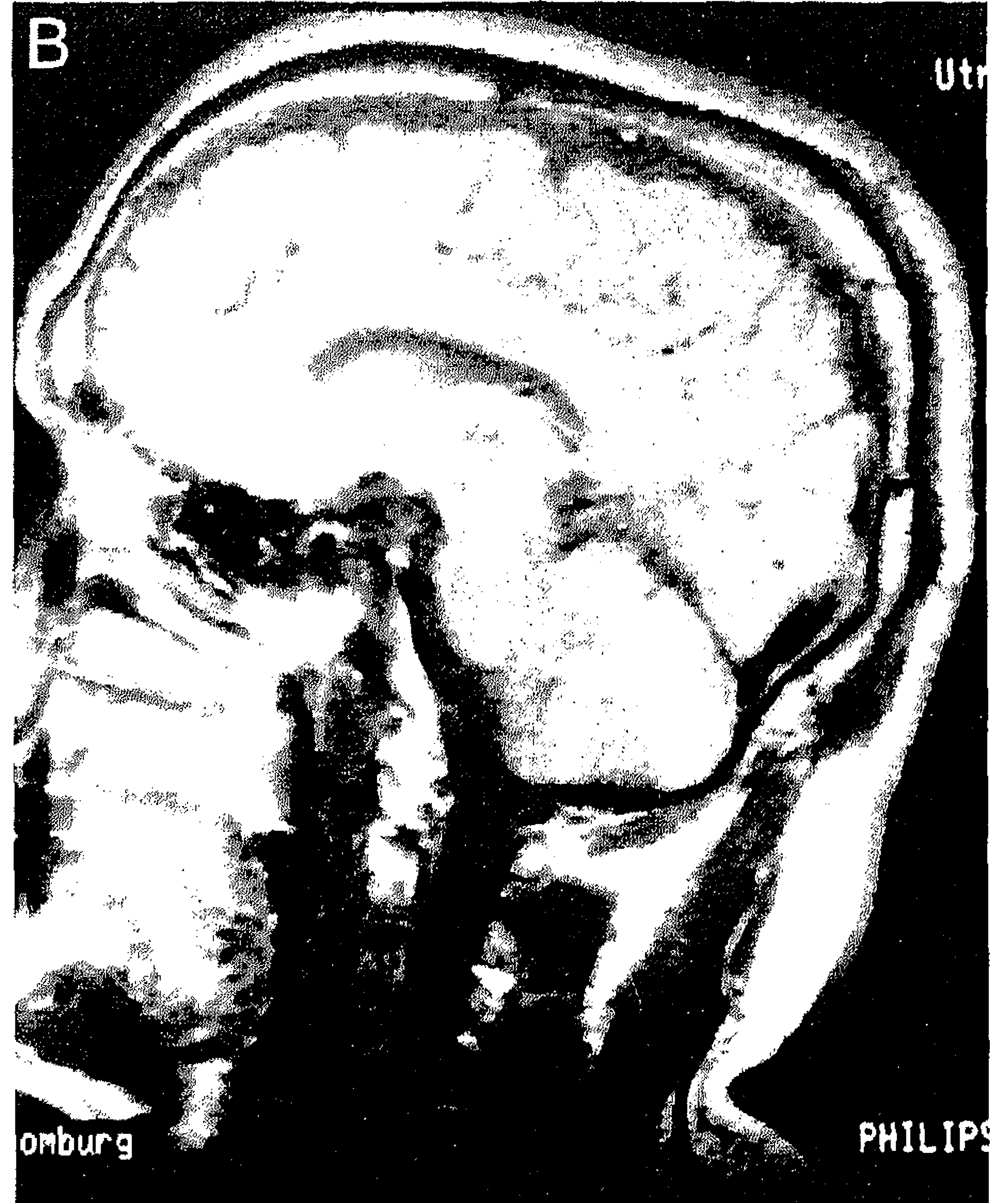
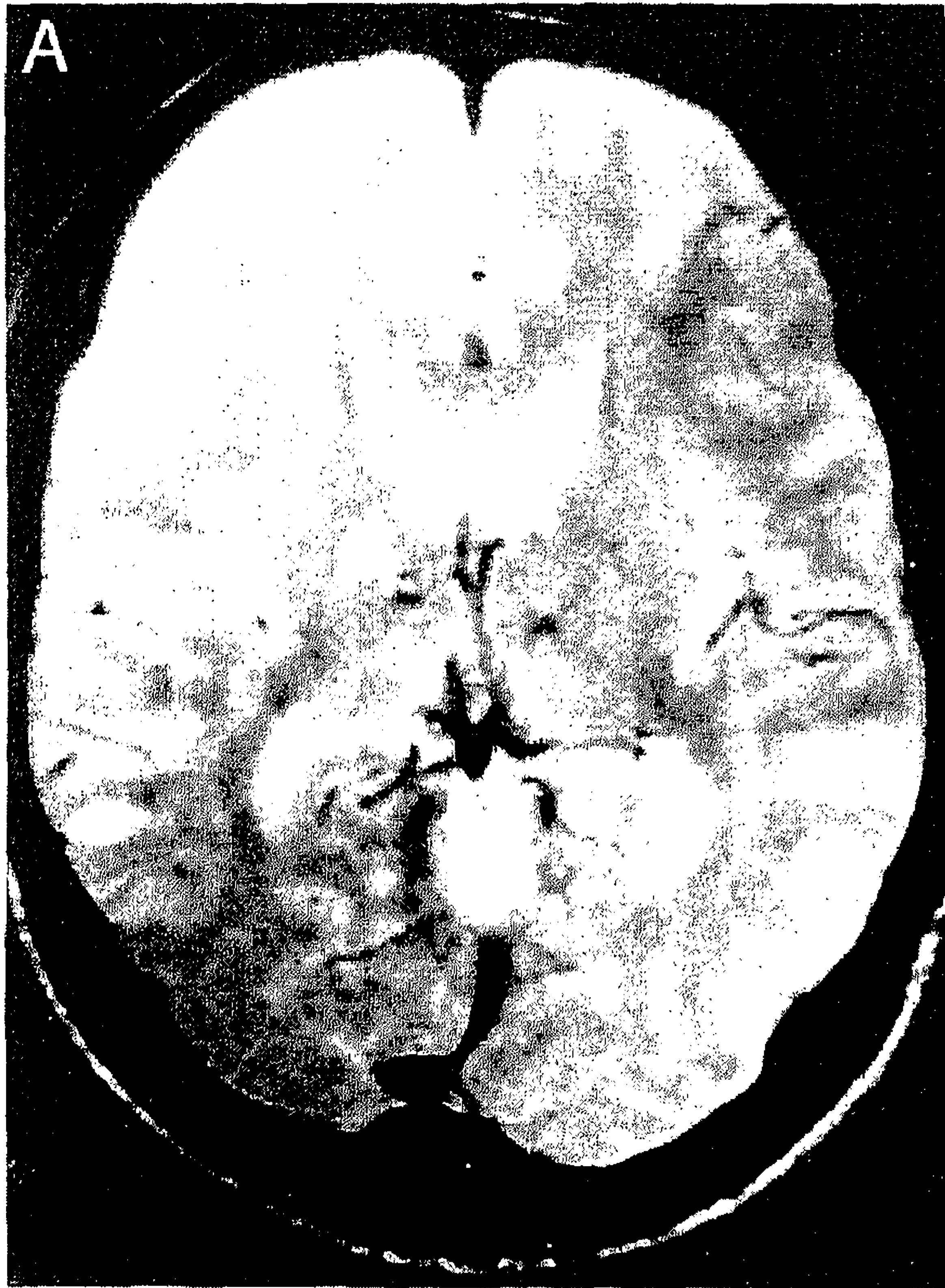


Fig. 4. MRI of the final necrotic area with corresponding schematic representations, drawn to scale. (a) Transversal section. (b) Paramedian sagittal section. (c) Frontal section.

Bogousslavsky et al., 1991). Therefore, the concept of thalamic neglect with hypokinesia, i.e. the failure to respond to relevant stimuli, although not paralysed (Valenstein and Heilman, 1981; Watson et al., 1981), seems more appropriate, and was further consolidated in other studies (Waxman et al., 1986; Heilman et al., 1987; Fleet et al., 1987). This akinetic mute state can be distinguished from athymhormia or 'loss of psychic self-activation', presented in some cases of small bilateral thalamic infarction, more antero-medial located, particularly involving dorsomedial nuclei (Bogousslavsky et al., 1991). Patients with athymhormia, originally reported after bilateral lesions of the striatum and generally with less tendency to full recov-

ery, suffer from a flat affect and loss of drive (lack of interest in things of life), but they may respond if only adequately stimulated (Habib and Poncet, 1988). The slight anatomic variations in vascular supply and thalamic nuclei involved might account for these subtle differences in clinical manifestations (Stuss et al., 1988; Tatemichi et al., 1992).

In our patient the central part of the thalamus was most severely affected, with involvement of intralaminar and midline nuclei. These structures, including intralaminar central medial (centre médian; CeM) and parafascicular (Pf) nuclei, are known to have rather diffusely spread projections to the cortex, and are closely linked to the motor system (Groenewegen and Berendse, 1994). However, they are not the pre-eminent source of diffuse neocortical activation and arousal, as was the conventional view (Vanderwolf and Stewart, 1988; Gloor et al., 1990). The circuitry from intralaminar thalamic (CeM-Pf) nuclei to frontocortical and back to the thalamic enfolding nucleus reticularis (NRT), has been suggested to serve as a kind of gate control, selectively preparing the aroused organism for responses to meaningful stimuli (Skinner and Yingling, 1976; Watson et al., 1981; Crick, 1984). Whereas intralaminar, particularly CeM-Pf, thalamic nuclei seem to control the firing threshold of cortical neurons (Miller, 1992; Steriade and Deschenes, 1984), their activity partly depends on reciprocal connections with the NRT and MRF, which are involved in tonic arousal (Skinner and Yingling, 1976; Watson et al., 1981; Steriade and Llinás, 1988; Miller, 1992). More caudally located thalamic structures, involved in the regulation of gaze, appear to function independently (Waxman et al., 1986; Groenewegen and Berendse, 1994), as was evident in our patient from the early reappearance of the primitive orienting response.

The electroencephalographic findings on the day of admission, showing repeated bursts of 6/sec slow wave and spike-and-wave (SW) discharges (Fig. 3), must result from the initial elimination of the 'non-specific' intralaminar thalamic structures. The EEG pattern was similar, although with double frequency, to that reported in experimental stimulation studies of the massa intermedia in the cat (Jasper and Droogleever-Fortuyn, 1947), and in cases of absence epilepsy (Snead, 1995). Based on both stimulation and ablation studies of selective thalamic structures in animals, the thalamus-enfolding nucleus reticularis thalami (NRT) has been proposed to be either the driving force (Avanzini et al., 1992; Vergnes and Marescaux, 1992), or at least involved in both EEG spindle rhythmicity and the absence-like SW and slow wave discharges, associated with a decreased level of vigilance (Yingling and Skinner, 1975; Gloor et al., 1990; Miller, 1992). Bilateral thalamic lesions, such as in the present study, therefore may be responsible for both the akinetic mute state and dysinhibition of NRT-related SW and slow wave discharge activity, by interruption of thalamocortical and intrathalamic connections. Interestingly, similar changes have been reported

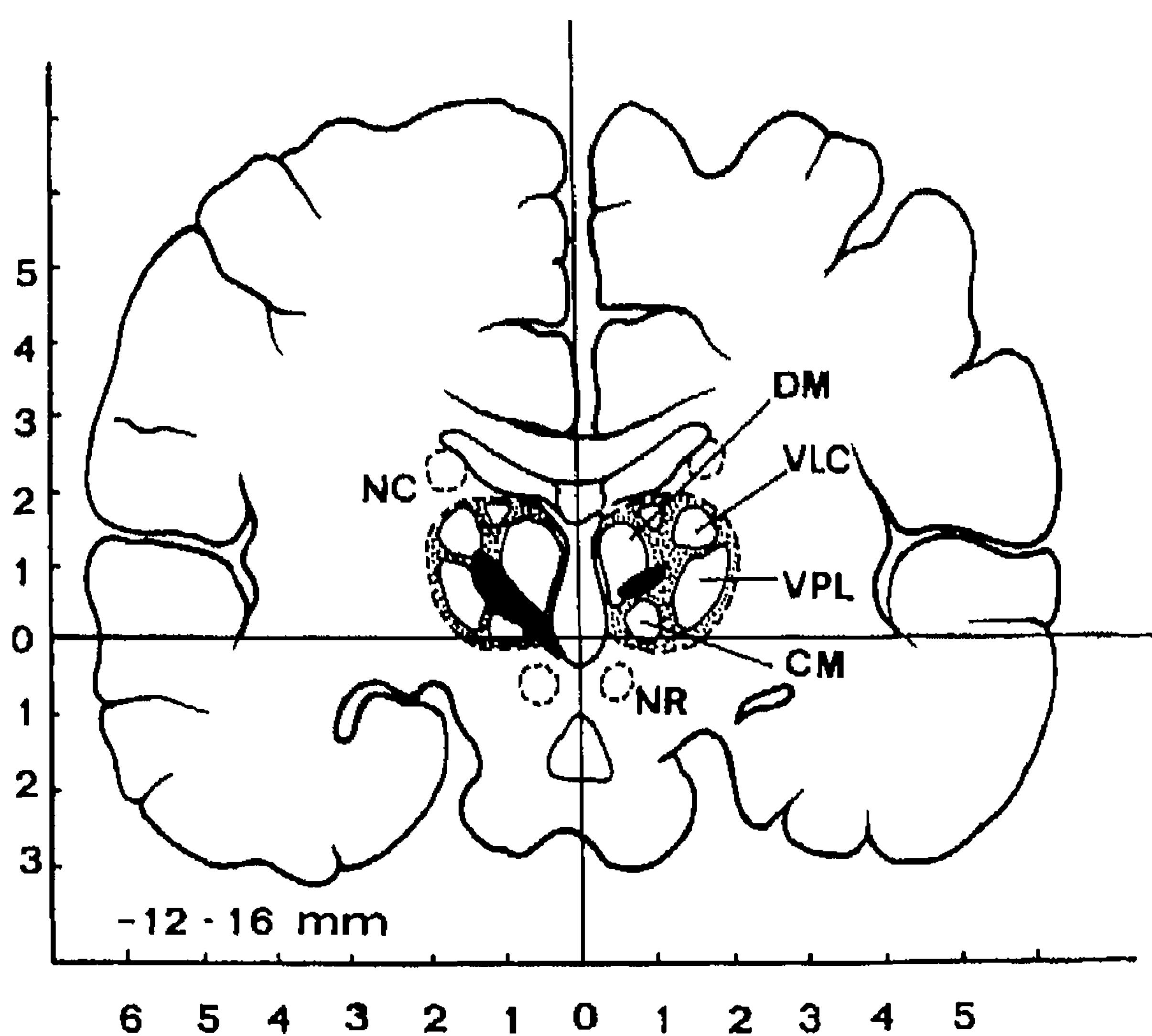
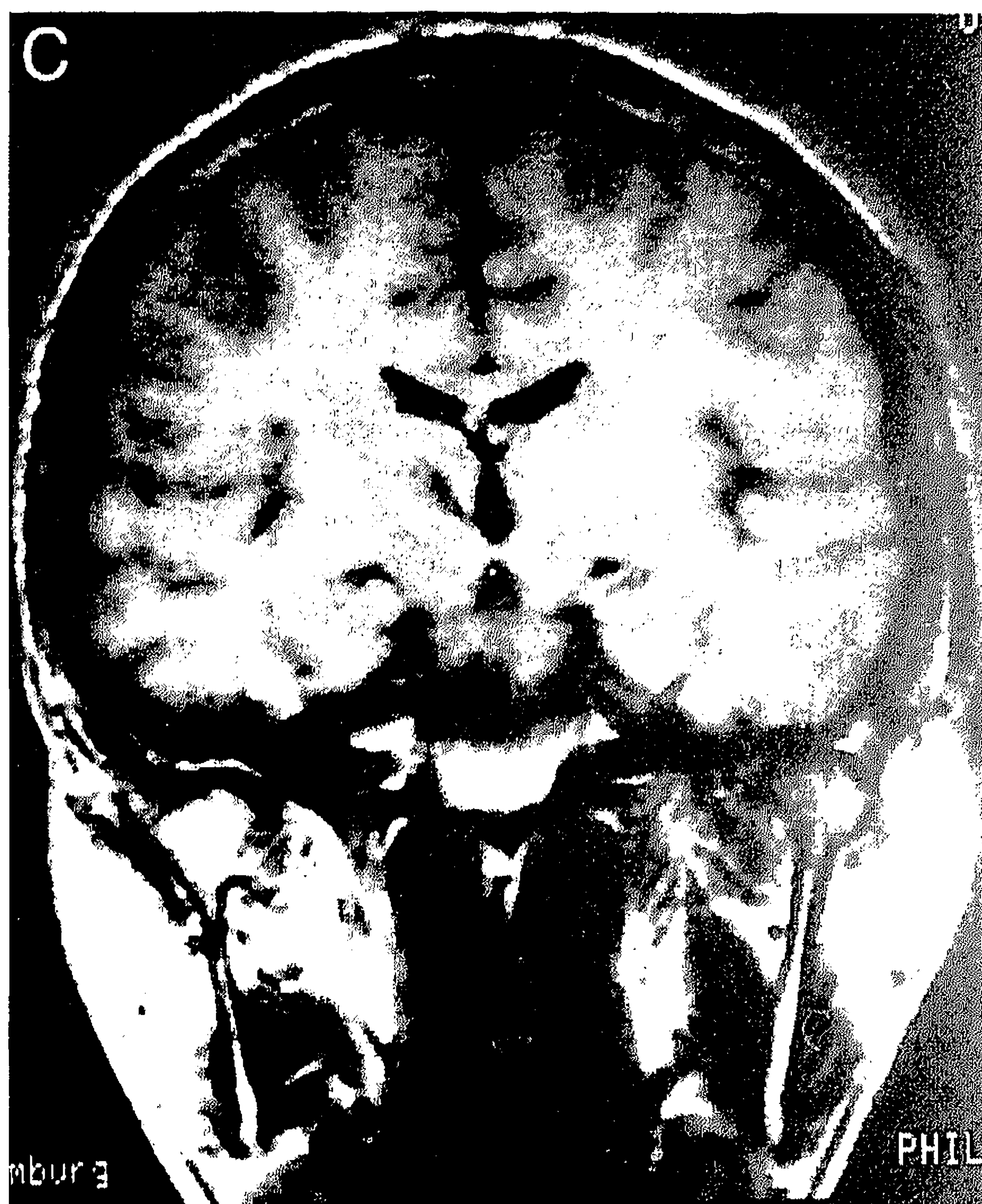


Fig. 4. (continued).

in a case with bilateral deep frontally located infarcts (Kurtz et al., 1988). The EEG findings in our case confirm experimental evidence on the involvement of intralaminar thalamic nuclei in the promotion of absence-like phenomena in man (Snead, 1995), and its association with behavioural inertia or decreased vigilance, so far only demonstrated in animal experiments.

Acknowledgements

We wish to thank J. Jansen for assistance in the preparation of the manuscript, A. Richt, speech therapist, for advice on interpretation of speech disturbances; G. Cho Chia Yuen, for neuropsychological investigation, and Dr. H. Schoonderwaldt for the clinical support during admission.

References

- Avanzini, G., M. de Curtis, C. Marescaux, F. Panzica, R. Spreafico, M. Vergnes (1992) Role of the thalamic reticular nucleus in the generation of rhythmic thalamo-cortical activities subserving spike and waves. *J. Neural. Transm.*, 35[Suppl]: 85–95.
- Bogousslavsky, J., F. Regli, A. Uske (1988) Thalamic infarcts: Clinical syndromes, etiology and prognosis. *Neurology*, 38: 837–848.
- Bogousslavsky, J., F. Regli, B. Delaloye, A. Delaloye-Bishof, G. Assal, A. Uske (1991) Loss of psychic self-activation with bithalamic infarction. Neurobehavioural, CT, MRI and SPECT correlates. *Acta Neurol. Scand.*, 83: 309–316.
- Büttner-Ennever, J.A., U. Büttner, B. Cohen, G. Baumgartner (1982) Vertical gaze paralysis and the rostral interstitial nucleus of the medial longitudinal fasciculus. *Brain*, 105: 125–149.
- Cairns, H. (1952) Disturbances of consciousness with lesions of the brainstem and diencephalon. *Brain*, 75(2): 109–145.
- Cairns, H., R.C. Oldfield, J.B. Pennybacker, D. Whitteridge (1941) Akinetic mutism with an epidermoid cyst of the third ventricle. *Brain*, 64: 273–290.
- Castaigne, P., F. Lhermitte, A. Buge, R. Escourolle, J.J. Hauw, O. Lyon-Caen (1981) Paramedian thalamic and midbrain infarcts: Clinical and neuropathological study. *Ann. Neurol.*, 10: 127–148.
- Crick, F. (1984) Function of the thalamic reticular complex: The search light hypothesis. *Proc. Natl. Acad. Sci.*, 81: 4586–4590.
- Fleet, W.S., E. Valenstein, R.T. Watson, K.M. Heilman (1987) Dopamine agonist therapy for neglect in humans. *Neurology*, 37: 1765–1770.
- Gloor, P., M. Avoli, G. Kostopoulos (1990) Thalamocortical relationships in generalized epilepsy with bilaterally synchronous spike-and-wave discharge. In: Avoli, M. et al. (Eds) *Generalized Epilepsy. Neurobiological Approaches*. Birkhäuser, Boston–Basel–Berlin, pp. 190–212.
- Graff-Radford, N.R., H. Damasio, Th. Yamada, P.J. Eslinger, A.R. Damasio (1985) Nonhaemorrhagic thalamic infarction. Clinical, neuropsychological and electrophysiological findings in four anatomical groups defined by CT. *Brain*, 108: 485–516.
- Groenewegen, H.J. and H.W. Berendse (1994) The specificity of the 'nonspecific' midline and intralaminar thalamic nuclei. *Trends Neurosci.*, 17: 52–56.
- Guberman, A. and D. Stuss (1983) The syndrome of bilateral paramedian thalamic infarction. *Neurology*, 33: 540–546.
- Guilleminault, Ch., M.A. Quera-Salva, M.P. Goldberg (1993) Pseudo-hypersomnia and pre-sleep behaviour with bilateral paramedian thalamic lesions. *Brain*, 116: 1549–1563.
- Habib, M. and M. Poncet (1988) Perte de l'élan vital, de l'intérêt et de l'affectivité (syndrome athymhormique) au cours de lésions lacunaires des corps striés. *Rev. Neurol. (Paris)*, 144: 571–577.
- Halmagyi, G.M., W.A. Evans, J.M. Hallinan (1978) Failure of downward gaze. The site and the nature of the lesion. *Arch. Neurol.*, 35: 22–26.
- Heilman, K.M., R.T. Watson, E. Valenstein, M.E. Goldberg (1987) Attention: Behavior and neural mechanisms. In: Mountcastle, V.B. et al. (Eds) *Hb. Physiol. Section I, The Nervous System. Vol. V, Higher functions of the Brain 2*. Amer. Physiol. Soc., Bethesda, Maryland, pp.461–481.
- Jasper, H.H. and J. Droogleever-Fortuyn (1947) Experimental studies of the functional anatomy of petit mal epilepsy. *Assoc. Res. Nerv. Ment. Dis. Proc.*, 26: 272–298.
- Klee, A. (1961) Akinetic mutism: Review of the literature and report of a case. *J. Nerv. Ment. Dis.*, 133: 536–553.
- Kurtz, D., A. Autret, M. Ruchoux (1988) Mutisme akinétique soudain et anomalies EEG chez une femme de 89 ans. *Rev. Neurol. (Paris)*, 144: 527–533.
- Levasseur, M., J.C. Baron, G. Sette, F. Legault-Demare, S. Pappata, F. Mauguière, N. Benoit, S. Tran Dinh, J.D. Degos, D. Laplane, B. Mazoyer (1992) Brain energy metabolism in bilateral paramedian thalamic infarcts. *Brain*, 115: 795–807.
- Miller, J.W. (1992) The role of mesencephalic and thalamic arousal systems in experimental seizures. *Progr. Neurobiol.*, 39: 155–178.
- Moriaka, T., F. Shima, M. Kato, M. Fukui (1989) Origin and distribution of thalamic somatosensory evoked potentials in humans. *Electroenceph. Clin. Neurophysiol.*, 74: 186–193.
- Németh, G. (1988) Some theoretical and practical aspects of the disturbances of consciousness with special reference to akinetic mutism. *Funct. Neurol.* 3: 9–28.
- Percheron, G. (1973) The anatomy of the arterial supply of the human thalamus and its use for the interpretation of the thalamic vascular pathology. *Z. Neurol.*, 205: 1–13.
- Plum, F. and J.B. Posner (1982) *The Diagnosis of Stupor and Coma*. 3rd. Ed., F.A. Davis Company, Philadelphia.
- Schlesinger, B. (1976) *The Upper Brainstem in the Human: Its Nuclear Configuration and Vascular Supply*. Springer, Berlin Heidelberg, New York.
- Segarra, J.M. (1970) Cerebral vascular disease and behavior: I. The syndrome of the mesencephalic artery. *Arch. Neurol.*, 22: 408–418.
- Skinner, J.E. and C.D. Yingling (1976) Regulation of slow potential shifts in nucleus reticularis thalami by the mesencephalic reticular formation and the frontal granular cortex. *Electroenceph. Clin. Neurophysiol.*, 40: 288–296.
- Snead, O.C. (1995) Basic mechanisms of generalized absence seizures. *Ann. Neurol.*, 37: 146–157.
- Steriade, M. and M. Deschenes (1984) The thalamus as a neuronal oscillator. *Brain Res. Rev.*, 8: 1–63.
- Steriade, M. and R.R. Llinás (1988) The functional states of the thalamus and the associated neuronal interplay. *Physiol. Rev.*, 68(3): 649–742.
- Stuss, D.T., A. Guberman, R. Nelson, S. Larochelle (1988) The neuropsychology of paramedian thalamic infarction. *Brain Cogn.*, 8: 348–378.
- Talairach, J. and P. Tournoux (1988) *Co-Planar Stereotaxic Atlas of the Human Brain*. Thieme, Stuttgart.
- Tatemichi, T.K., W. Steinke, C. Duncan, J.A. Bello, J.G. Odel, M.M. Behrens, S.K. Hilal, J.P. Mohr (1992) Paramedian thalamopeduncular infarction: clinical syndromes and magnetic resonance imaging. *Ann. Neurol.*, 32: 162–171.
- Trojanowski, J.Q. and M.H. LaFontaine (1981) Neuroanatomical correlates of selective downgaze paralysis. *J. Neurol. Sci.*, 52: 91–101.
- Valenstein, E. and K.M. Heilman (1981) Unilateral hypokinesia and motor extinction. *Neurology*, 31: 445–448.

- Vanderwolf, C.H. and D.J. Stewart (1988) Thalamic control of neocortical activation: A critical re-evaluation. *Brain. Res. Bull.* 20: 529–538.
- Vergnes, M. and C. Marescaux (1992) Cortical and thalamic lesions in rats with genetic absence epilepsy. *J. Neural. Transm., [Suppl]* 35: 71–83.
- Watson, R.T., E. Valenstein, K.M. Heilman (1981) Thalamic neglect. Possible role of the medial thalamus and nucleus reticularis in behavior. *Arch. Neurol.*, 38: 501–506.

- Waxman, S.G., G.A. Ricaurte, S.B. Tucker (1986) Thalamic hemorrhage with neglect and memory disorder. *J. Neurol. Sci.*, 75: 105–112.
- Yingling, C.D. and J.E. Skinner (1975) Regulation of unit activity in nucleus reticularis thalami by the mesencephalic reticular formation and the frontal granular cortex. *Electroenceph. Clin. Neurophysiol.*, 39: 635–642.