

## PDF hosted at the Radboud Repository of the Radboud University Nijmegen

The following full text is a publisher's version.

For additional information about this publication click this link.

<http://hdl.handle.net/2066/22079>

Please be advised that this information was generated on 2017-12-05 and may be subject to change.

Case report

## Acute HELLP postpartum with renal failure

Els Th. M. Dams<sup>\*a</sup>, Marloes H.M. de Vleeschouwer<sup>b</sup>, Pieter W.J. van Dongen<sup>b</sup>

<sup>a</sup>*Department of Intensive Care, University Hospital Nijmegen, Nijmegen, The Netherlands*

<sup>b</sup>*Department of Obstetrics and Gynaecology, University Hospital Nijmegen, Nijmegen, The Netherlands*

Received 16 December 1994; accepted 16 March 1995

---

### Abstract

A 33-year-old gravida-II, para-I developed an acute HELLP syndrome with disseminated intravascular coagulation and acute renal failure after a vaginal delivery following an uncomplicated pregnancy.

**Keywords:** HELLP syndrome; Preeclampsia; Postpartum; Renal failure; Disseminated intravascular coagulation

---

### 1. Introduction

The HELLP syndrome (Hemolysis, Elevated Liver enzymes, Low Platelets) is a well known obstetric complication [1]. It is considered to be a variant of severe preeclampsia/eclampsia. The pathogenesis is still poorly understood. Platelet activation and microvascular endothelial damage with imbalance in thromboxane and prostacyclin production seem to play an important role [2]. Serious complications such as pulmonary edema, renal failure, disseminated intravascular coagulation (DIC) and subcapsular liver hematoma contribute to the high maternal and perinatal mortality rate [3].

The HELLP syndrome usually arises antepartum. Postpartum occurrence is rare and is often related to preeclampsia antepartum or durante partu. This case report describes a severe HELLP syndrome complicated by DIC and renal failure developing after vaginal delivery, following a normal pregnancy.

### 2. Case report

A 33-year-old gravida-II, para-I was admitted in labour at 39 weeks' gestation. Her pregnancy had been uncomplicated. One week before admission a blood pressure of 120/85 mmHg was noted. She had no gastrointestinal complaints, no sudden weight gain or edema. Serum creatinine was 84  $\mu\text{mol/l}$ , platelet count  $207 \times 10^9/\text{l}$ , alanine aminotransferase 6 U/l, no proteinuria. Four days later blood pressure and laboratory values were unchanged. On admission she was in good general health, fetal monitoring was normal reactive. Five hours later she had a spontaneous vaginal delivery of a 3930-g healthy male infant.

One hour postpartum she experienced sudden epigastric pain. The diastolic blood pressure rose to 120 mmHg. Laboratory findings showed hemolysis, thrombocytopenia and an increase in serum creatinine and transaminases (Table 1). Intravenous magnesium sulphate and dihydralazin were administered. Abdominal ultrasound disclosed an empty uterine cavity without placenta residue.

Three hours after delivery, the patient was transferred to the intensive care unit (ICU) because of poor urine

---

\* Corresponding author, Department of Internal Medicine, University Hospital Nijmegen, P.O. Box 9101, 6500 HB Nijmegen, The Netherlands. Tel.: +31 80 614782; Fax: +31 80 540788.

Table 1  
Laboratory data on the first day postpartum

Variable	Time postpartum			
	1 h	3 h	19 h	24 h
Hemoglobin (mmol/l)	7.6	6.8	4.4	4.1
Platelet count ( $\times 10^9/l$ )	114	85	<10	29
Fibrinogen (mg/l)		465	780	1561
FDP (mg/l)		>300	>300	110
APTT (s)		56	57	52
Prothrombin time (s)		36	32	22
Antithrombin III (%)		57		
Haptoglobin (g/l)		0.25		
Reticulocytes (‰)		12		
Coombs test		Negative		
Schistocytes		Negative		
Serum urea (mmol/l)	8.9	9.7	11.9	14.8
Serum creatinine ( $\mu\text{mol/l}$ )	113	118	160	232
Total bilirubin ( $\mu\text{mol/l}$ )		67	56	29
ASAT (U/l)	1580	2140	2640	1760
ALAT (U/l)	1610	1730	1910	1540
LDH (U/l)		7780	7670	4409
Glucose (mmol/l)		8.4	12.8	4.0

FDP, fibrin-degradation products; APTT, partial-thromboplastin time; ASAT, aspartate aminotransferase; ALAT, alanine aminotransferase; LDH, lactate dehydrogenase.

output, drowsiness and suspicion of DIC. Total vaginal blood loss at that time was 1300 ml. On examination in the ICU she was a bit sleepy but well orientated and responding adequately; there was no respiratory distress, cyanosis or jaundice. The blood pressure was 160/90 mmHg, the pulse rate was 104/min and the temperature 36.3 °C. There was right upper abdominal tenderness, the liver was not felt. Vaginal bleeding had virtually stopped. Neurological examination, including reflexes,

was negative. The results of laboratory tests are presented in Table 1. There was no hypoxemia or elevated ammonia. Urinalysis showed a mixed pattern of dehydration and acute tubular necrosis; in the urine sediment hematuria and proteinuria but no casts. Urine output was absent in the last hour. An ultrasonographic examination of the abdomen (Fig. 1) revealed multiple small poorly echogenic subcapsular lesions in the right liverlobe, suspected as small hematomas. A radiograph of the chest was normal.

The combination of hemolysis, thrombocytopenia and elevated liver enzymes suggested a postpartum HELLP syndrome, complicated by DIC and acute renal failure. The patient was rehydrated and treatment was instituted with fresh frozen plasma; dihydralazin and magnesium sulphate were continued. Red cell transfusion was given when the hematocrit dropped to 0.18, 7 h postpartum. Twelve hours later platelets were substituted prophylactically at a nadir of  $<10 \times 10^9/l$ .

During the next 2 days the blood pressure normalized; the liver functions and the haematological and coagulation data gradually improved (Fig. 2). Renal function, however, deteriorated with persistent oliguria ( $<400$  ml/day) and an increase in serum creatinine to a maximum level of  $969 \mu\text{mol/l}$  (Fig. 2). Fluid intake was restricted. Urine findings were compatible with acute tubular necrosis. A high dose of furosemide failed to increase diuresis. On the third day postpartum, hemodialysis was started because of azotemia and pulmonary edema. Ultrasonographic examination disclosed ascites; the echogenic liver lesions were unchanged. During the

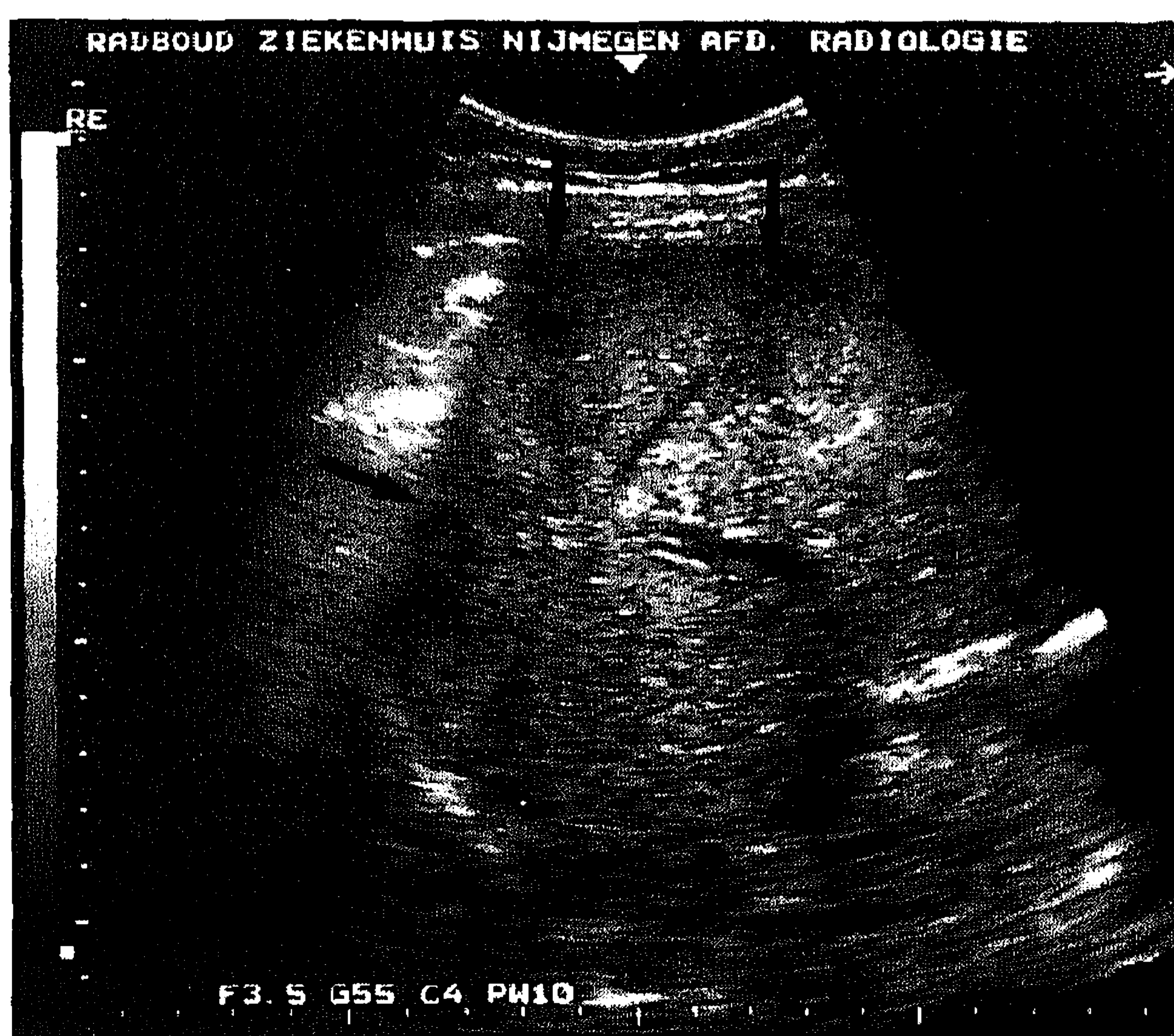

Fig. 1. Ultrasound image of the right upper quadrant, demonstrating multiple small subcapsular lesions in the right liverlobe (arrows).



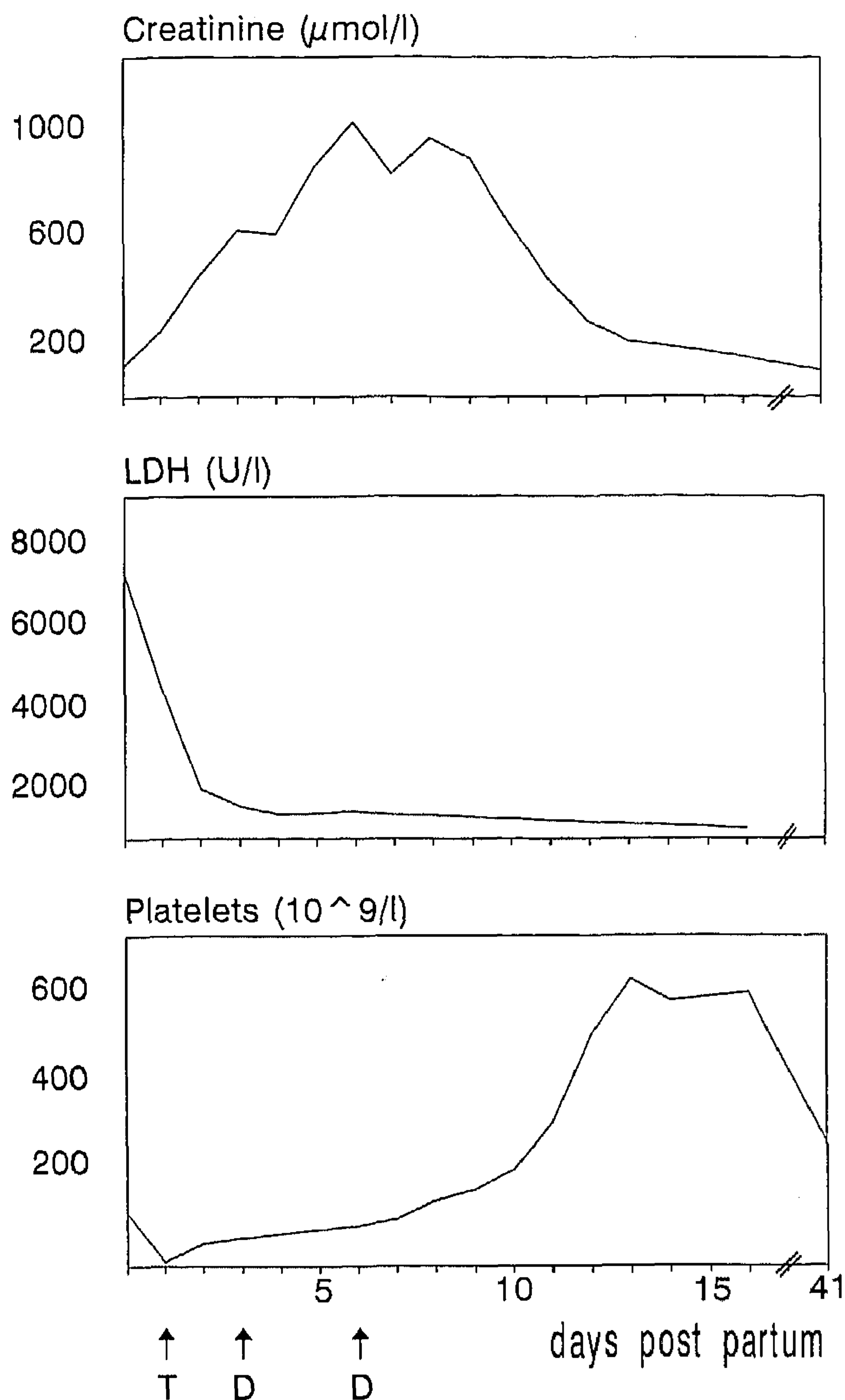


Fig. 2. The course of creatinine, platelets and LDH during the postpartum period. T, transfusion of six donor units of platelet concentrate; D, dialysis.

following days, diuresis increased rapidly with a subsequent decline of the serum creatinine level. On the seventh day postpartum, dialysis could be discontinued. The patient was transferred back to the obstetrical ward. Her recovery was uncomplicated and she was discharged in good clinical condition. Pathological examination of the placenta showed infarction and a intervillous thrombus with no signs of abruption or infection. Six weeks postpartum, the renal function had virtually normalized (serum creatinine 94 μmol/l) with no proteinuria; the patient remained normotensive.

### 3. Discussion

The syndrome of hemolysis, thrombocytopenia and abnormal liver function tests as an obstetric complication has been recognized for many years. First described in 1954 by Pritchard et al. [4], the entity was labeled the HELLP syndrome in 1982 by Weinstein [1], denoting hemolysis (microangiopathic hemolytic anemia), elev-

ated liver enzymes and low platelets. Postpartum development of the HELLP syndrome has been reported since, but usually in close association with pre-existing preeclampsia or complicated delivery [5]. De novo occurrence — as in our patient — is documented only occasionally [5].

The clinical presentation of HELLP is often aspecific. Many patients present with merely malaise and right upper quadrant or epigastric pain; hypertension and proteinuria can be absent [1,6]. This may lead to erroneous diagnoses or even disregard, particularly if the syndrome develops postpartum. The usual short period of observation after an uncomplicated delivery contributes to the risk of missing a potential life-threatening complication.

Schistocytes — hallmark of microangiopathic hemolytic anemia — are not always present, and appear often later in the course of the illness. Haptoglobin and to a lesser degree LDH are reported to be more sensitive markers for hemolysis [7].

The role of DIC in HELLP syndrome is yet unclarified. Clinically evident DIC, as a secondary pathophysiological phenomenon to the primary process, is seen in 4–38% of the patients [1,5]. Others, however, using more sensitive clotting assays, have noted a consumptive coagulopathy in all patients with HELLP, suggesting an important role of DIC in the etiology of this syndrome [3,8].

Acute renal failure (ARF) complicating HELLP is unusual and is strongly associated with other obstetric complications such as abruptio placentae, fetal death, DIC, shock and sepsis [9]. In most reported cases ARF is caused by acute tubular necrosis with generally favourable renal outcome — as in our patient. Irreversible renal damage due to bilateral cortical necrosis is rare and associated with abruptio placentae or preexisting vascular or renal disease [9].

Postpartum HELLP syndrome with renal failure must be distinguished from the postpartum hemolytic uremic syndrome (PPHUS), thrombotic thrombocytopenic purpura (TTP) and acute fatty liver of pregnancy (AFLP). PPHUS typically occurs after a symptom-free interval of 1 day to several weeks following a normal pregnancy and delivery; coagulation studies are usually normal, except for elevated fibrin-degradation products. Prognosis in terms of mortality and renal outcome is poor [10]. In contrast, our patient developed symptoms immediately after delivery with abnormal coagulation studies and had a rapid renal recovery. Time of onset and the absence of fever and neurological symptoms argued against TTP and AFLP.

The management of the HELLP syndrome consists of stabilization of the patient (including antihypertensive and anticonvulsant treatment) and termination of pregnancy as soon as possible. This usually leads to resolution of the illness in 3–4 days [5]. The treatment of

(persistent) postpartum HELLP syndrome is subject to discussion. Several therapeutic modalities are suggested. Some authors recommend exchange plasmapheresis with fresh-frozen plasma if symptoms persist beyond 72 h postpartum or if renal function deteriorates [11,12]. Prostacyclin is also advocated [13]. Others question the value of these therapies. Sibai et al. [5] state that in their experience almost all cases will resolve with supportive care alone. In this case it was decided not to use plasma exchange in view of the rapidly resolving microangiopathy.

If DIC is evident, treatment with fresh-frozen plasma is recommended [14].

In summary, this case demonstrates that a severe HELLP syndrome can develop after a normal pregnancy and delivery. Upper abdominal pain occurring in the postpartum period should therefore prompt further investigation, including appropriate laboratory tests to detect possible evolving HELLP.

## References

- [1] Weinstein L. Syndrome of hemolysis, elevated liver enzymes, and low platelet count: a severe consequence of hypertension in pregnancy. *Am J Obstet Gynecol* 1982; 142: 159–167.
- [2] Roberts JM, Taylor RN, Musci TJ et al. Preeclampsia: an endothelial disorder. *Am J Obstet Gynecol* 1989; 161: 1200–1204.
- [3] van Dam PA, Renier M, Baekelandt M, Buytaert P, Uyttenbroeck F. Disseminated intravascular coagulation and the syndrome of hemolysis, elevated liver enzymes, and low platelets in severe preeclampsia. *Obstet Gynecol* 1989; 73: 97–102.
- [4] Pritchard JA, Weisman R, Ratnoff OD, Vosburgh GJ. Intravascular hemolysis, thrombocytopenia and other hematological abnormalities associated with severe toxemia of pregnancy. *N Engl J Med* 1954; 250: 89–98.
- [5] Sibai BM, Ramadan MK, Usta I, Salama M, Mercer BM, Friedman SA. Maternal morbidity and mortality in 442 pregnancies with hemolysis, elevated liver enzymes, and low platelets (HELLP syndrome). *Am J Obstet Gynecol* 1993; 169: 1000–1006.
- [6] Martin JN, Blake PG, Lowry SL, Perry KG, Files JC, Morrison JC. Pregnancy complicated by preeclampsia-eclampsia with the syndrome of hemolysis, elevated liver enzymes, and low platelet count: how rapid is postpartum recovery? *Obstet Gynecol* 1990; 76: 737–741.
- [7] Schröcksnadel H, Sitte B, Steckel-Berger G, Dapunt O. Hemolysis in hypertensive disorders of pregnancy. *Gynecol Obstet Invest* 1992; 34: 211–216.
- [8] de Boer K, Büller HR, ten Cate JW, Treffers PE. Coagulation studies in the syndrome of haemolysis, elevated liver enzymes and low platelets. *Br J Obstet Gynecol* 1991; 98: 42–47.
- [9] Sibai BM, Ramadan MK. Acute renal failure in pregnancies complicated by hemolysis, elevated liver enzymes, and low platelets. *Am J Obstet Gynecol* 1993; 168: 1682–1690.
- [10] Hayslett JP. Postpartum renal failure. *N Engl J Med* 1985; 312: 1556–1559.
- [11] Martin JN, Files JC, Blake PG et al. Plasma exchange for preeclampsia. I. Postpartum use for persistently severe preeclampsia-eclampsia with HELLP syndrome. *Am J Obstet Gynecol* 1990; 162: 126–137.
- [12] Schwartz ML, Brenner WE. Possible role for exchange plasmapheresis with fresh frozen plasma for maternal indications in selected cases of preeclampsia and eclampsia. *Obstet Gynecol* 1986; 67: 136–139.
- [13] Fox JG, Sutcliffe NP, Walker JJ, Allison MEM. Postpartum eclampsia and acute renal failure; treatment with prostacyclin. Case report. *Br J Obstet Gynecol* 1991; 98: 400–402.
- [14] Sibai BM. The HELLP syndrome (hemolysis, elevated liver enzymes, and low platelets): much ado about nothing? *Am J Obstet Gynecol* 1990; 162: 311–316.