

## PDF hosted at the Radboud Repository of the Radboud University Nijmegen

The following full text is a publisher's version.

For additional information about this publication click this link.

<http://hdl.handle.net/2066/22075>

Please be advised that this information was generated on 2017-12-05 and may be subject to change.

# Functional relationship between the abductor pollicis longus and abductor pollicis brevis muscles: an EMG analysis

E. VAN OUDENAARDE<sup>1</sup> AND R. A. B. OOSTENDORP<sup>2</sup>

<sup>1</sup>University of Nijmegen, the Netherlands, <sup>2</sup>Free University of Brussels, Belgium and National Institute for Research and Postgraduate Education in Physical Therapy, Amersfoort, The Netherlands

(Accepted 8 November 1994)

## ABSTRACT

This study examined the anatomical and functional relationships between the abductor pollicis longus (APL) and the abductor pollicis brevis (APB) muscles. The APL has 2 divisions, a distal superficial division and a more proximal deep one. A direct anatomical connection between the extrinsic and intrinsic muscles of the thumb is made up by the deep division of the APL, the APB and the trapezium. Electromyographic (EMG) recordings were made from these muscles to investigate differences and similarities in muscle activation. The EMG activity was recorded with intramuscular wire electrodes during isometric as well as dynamic contractions in different directions, both for the thumb and for the hand. The EMG activity of the right hand of 8 subjects was scaled relative to the mean EMG value at the maximum voluntary isometric contraction in order to compare relative muscle activity in various directions for different subjects. APB and APL were activated in a number of directions for the thumb as well as for the hand. Cooperation between these muscles is necessary to stabilise the trapezium to the carpus in movements of the thumb. APB is activated in movements of the hand to maintain the tension in the deep APL. The deep APL is activated in movements of the thumb to prevent undesired movements of the hand and the forearm. The APB and superficial APL are prime movers of the thumb.

*Key words:* Electromyography; hand function; abductor pollicis longus; abductor pollicis brevis; trapezium.

## INTRODUCTION

The extrinsic muscles of the thumb are extensor pollicis longus, extensor pollicis brevis, flexor pollicis longus and abductor pollicis longus. These muscles are polyarticular and act at the carpal joint as well as on the joints of the thumb. The intrinsic muscles of the thumb are opponens pollicis, flexor pollicis brevis, adductor pollicis and abductor pollicis brevis. These muscles are smaller than the extrinsic muscles and only cross the joints of the thumb. Little is known about the functional relationships between the extrinsic and intrinsic muscles of the thumb.

The only anatomical connection between the extrinsic and intrinsic muscles of the thumb is made up by abductor pollicis longus (APL), abductor pollicis brevis (APB) and the trapezium (Fig. 1). APL has a distal superficial and a more proximal deep division (van Oudenaarde, 1991*a*). The superficial division (APL<sub>sup</sub>) inserts with one or more tendons into the 1st

metacarpal bone (MCI). The deep division (APL<sub>deep</sub>) has a variable number of insertions into the trapezium, the joint capsule, the capsular ligaments and mostly into the radial muscle belly of APB, sometimes into opponens pollicis (OP). APB, similar to APL, also has more divisions (Simard & Roberge, 1988). This muscle originates from the flexor retinaculum and the

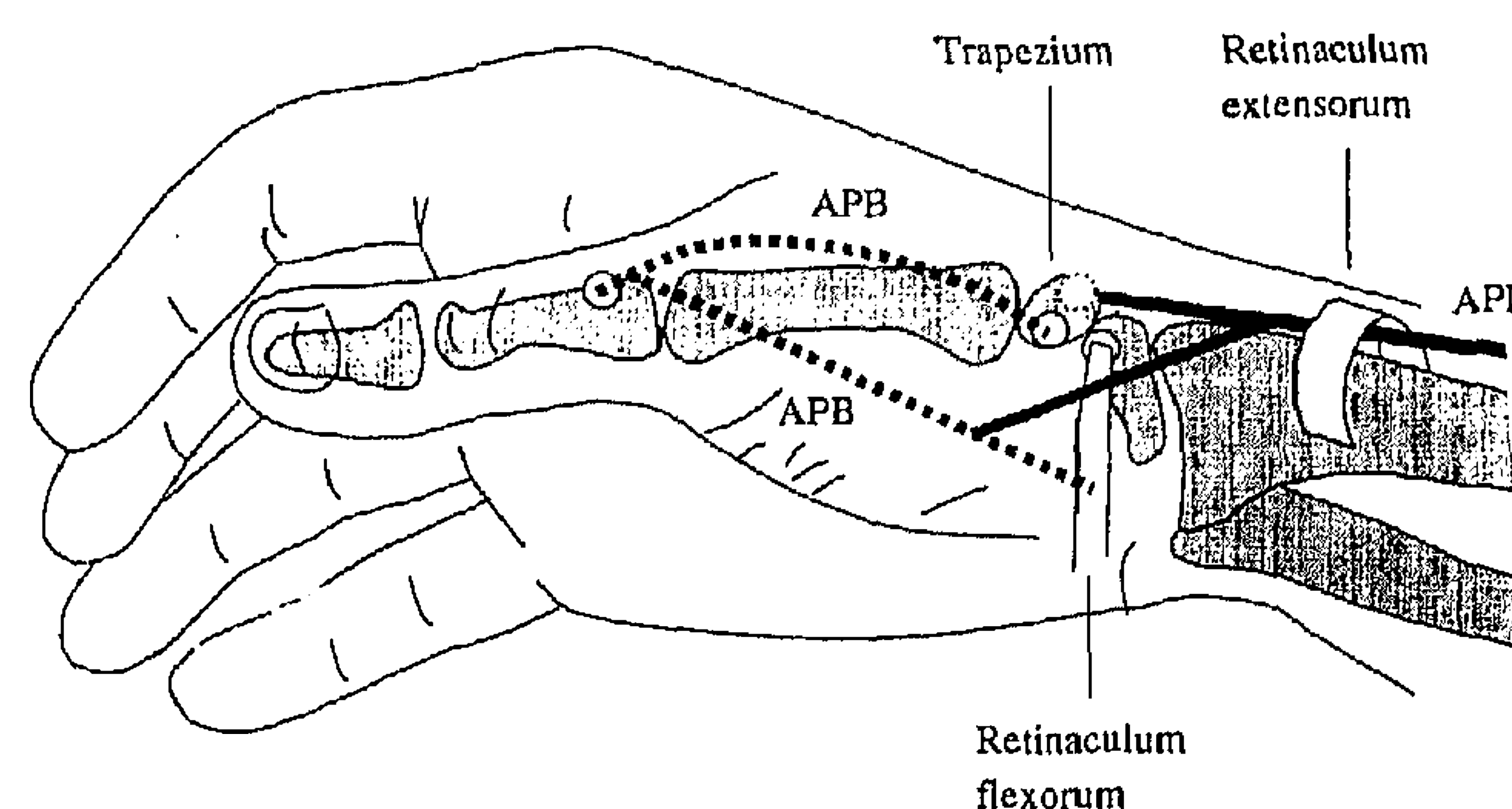


Fig. 1. Anatomical connection between abductor pollicis brevis (APB), the deep division of abductor pollicis longus (APL) and the trapezium.



trapezium and inserts into the proximal phalanx of the thumb. Such an insertion of one tendon into another muscle, is rarely found in the human body (APL deep into APB) but is considered to be of functional importance. APL and APB are innervated by different nerves, the radial and the median nerves, respectively.

The trapezium is part of the radial chain of the carpus (Kauer, 1986). Kauer divided the carpus into 3 longitudinal chains; radial, central and ulnar. The radial chain is formed by the radius, scaphoid, trapezoid and trapezium. The joints of the radial carpal column are for movements dependent on each other as well as on the other chains of the carpus (Kauer, 1986). At the distal end of the radial column is the trapeziometacarpal joint, otherwise referred to as the 1st carpometacarpal joint (CMCI). This is a highly interesting joint, being free moving in contrast to the joints of the radial carpal chain. APL inserts into both sides of CMCI, i.e. into the trapezium (APL deep) as well as into the MCI (APL sup).

Few facts are known as to the role of the trapezium in the function of the carpus. Ruby et al. (1988) labelled most of the bones of the carpus for kinematic analysis, but the trapezium was not included. Kauer & de Lange (1987) noted that the distal carpal row, which includes the trapezoid and trapezium, can be considered as acting as a fixed group. On the other hand, it is known that an interosseous ligament between the trapezium and trapezoid is usually lacking (Warwick & Williams, 1975; Romanes, 1976; Spinner, 1984). Berger & Crowinshield (1982) postulated that the trapezium is a marginal bone in the distal carpal row and hence has less articulatory contact with the other bones of the distal row of the carpus. The trapezium would therefore have more mobility than the other bones of the carpus. Van Oudenaarde (1991b) noted displacement of the trapezium during passive movements of the thumb.

The trapezium moves during dorsopalmar flexion of the hand in relation to the scaphoid (Kauer, 1986), but is fixed to the scaphoid if the thumb moves. In this way the trapezium forms the link between the interconnected movements of the bones of the carpus and the independent movements of CMCI. The fixation of the trapezium to the scaphoid and the trapezoid is a point of some interest. The exact mechanism of this fixation is uncertain. From the displacement of the trapezium during passive movement (from observations on cadaver hands) it would be expected that muscles play an important role in this fixation. No muscles insert into most of the bones of the carpus with the consequence that the movements of these bones in relation to each other are indirect.

An exception is the trapezium into which 2 muscles insert, APL and APB.

The functional relationship between APL and APB, as well as the role of muscles in the fixation of the trapezium to the carpus, is the subject of this study. This relationship is complex and still poorly understood. As there are numerous combinations of movements of the hand in the carpal joint and of the thumb in CMCI, the experiments in this study were performed under controlled conditions to test the hypothesis that both muscles and the trapezium are functionally related. In this study EMG signals from APL and APB were recorded in a number of directions to look for differences and similarities in muscle activation in each of these muscles in the chosen directions. The results will be used to discuss the coordination between these muscles and the functional role of these muscles in stabilisation of the trapezium to the carpus.

#### MATERIALS AND METHODS

The methods were used similar to those described elsewhere (van Oudenaarde et al. 1994). A summary is given below.

#### *Subjects*

Eight adult subjects with normal manual function participated in the study, 4 women and 4 men, aged from 35 to 70 y. In 1 male subject, only the EMG signals from the hand were recorded. All experiments were performed on the right hand.

#### *Terminology*

In this study 'isometric contraction' is defined as muscle activation against a constant load without shortening or lengthening of the muscle and without joint movement. By 'dynamic contraction' we refer to contraction against a constant load in which the thumb or the hand is free to move and in which the length of the muscle can change by movements of the thumb or the hand.

EMG activity was recorded for isometric and dynamic contractions in a number of directions. The isometric contractions in each of 6 directions and the movements in each of the 6 directions for the thumb and the 7 directions of the hand will be referred to as 'directions'. The terminology of the International Federation of Societies for Surgery of the Hand (Terminology for Hand Surgery, 1970) will be used to refer to the directions of the thumb.



### Equipment

EMG signals were recorded by means of intramuscular wire electrodes. Alternately the thumb and the hand were connected to a strain-gauge by means of a thumb splint or a hand splint. The splints were connected to a cable leading to a torque motor used to deliver dynamic loads.

### Procedure

For the directions of the thumb, the forearm was held in midposition between pronation and supination, the hand in midposition between palmar flexion and dorsiflexion. The forearm and hand were positioned from the elbow to the fingers along the armrest of a chair, with the fingers slightly flexed. For dorsiflexion and palmar (dorsopalmar) flexion of the hand, the thumb was held in a relaxed position on the index finger. In the positions of pronation and supination the right forearm rested on the armrest from the elbow up to the wrist. In midposition the forearm down to and including the little finger lay on the armrest. Changes in the amount of EMG activity in isometric and dynamic contractions were determined relative to the mean amplitude of EMG activity in the starting position by subtracting the EMG in the starting position.

All EMG signals were recorded for a period of 3 s. Pronation, supination and midposition of the forearm were combined with dorsiflexion and palmar flexion of the hand in the following directions: (1) *thumb*: palmar abduction, opposition, radial abduction, adduction, reposition, repeated palmar abduction; (2) *forearm and hand*: supination with dorsiflexion and palmar flexion, pronation with dorsiflexion and palmar flexion, midposition with dorsiflexion and palmar flexion, repeated midposition with palmar flexion.

### Data analysis

In order to compare the function of APL and APB, the percentages of EMG activity relative to the maximum EMG activity were calculated for each direction and for each muscle (separately for the directions of the thumb and those of the hand). Finally the results from all subjects were averaged and the s.d. was calculated.

Differences between the amount of EMG activity in the various directions were tested with the Wilcoxon Matched Pairs Test (Krauth, 1988). A significance

level of  $\alpha = 0.05$  was chosen. The null hypothesis was tested that there is no tendency for the EMG signals in one direction to be larger or smaller than in another direction. The alternative hypothesis implies that the outcome of one direction is larger or smaller than in other directions.

### RESULTS

The mean value of EMG signals, relative to the maximum EMG for isometric as well as for dynamic contractions, respectively, for the APB and the APLdeep in various directions are presented in Figures 2, 3, 6 and 7.

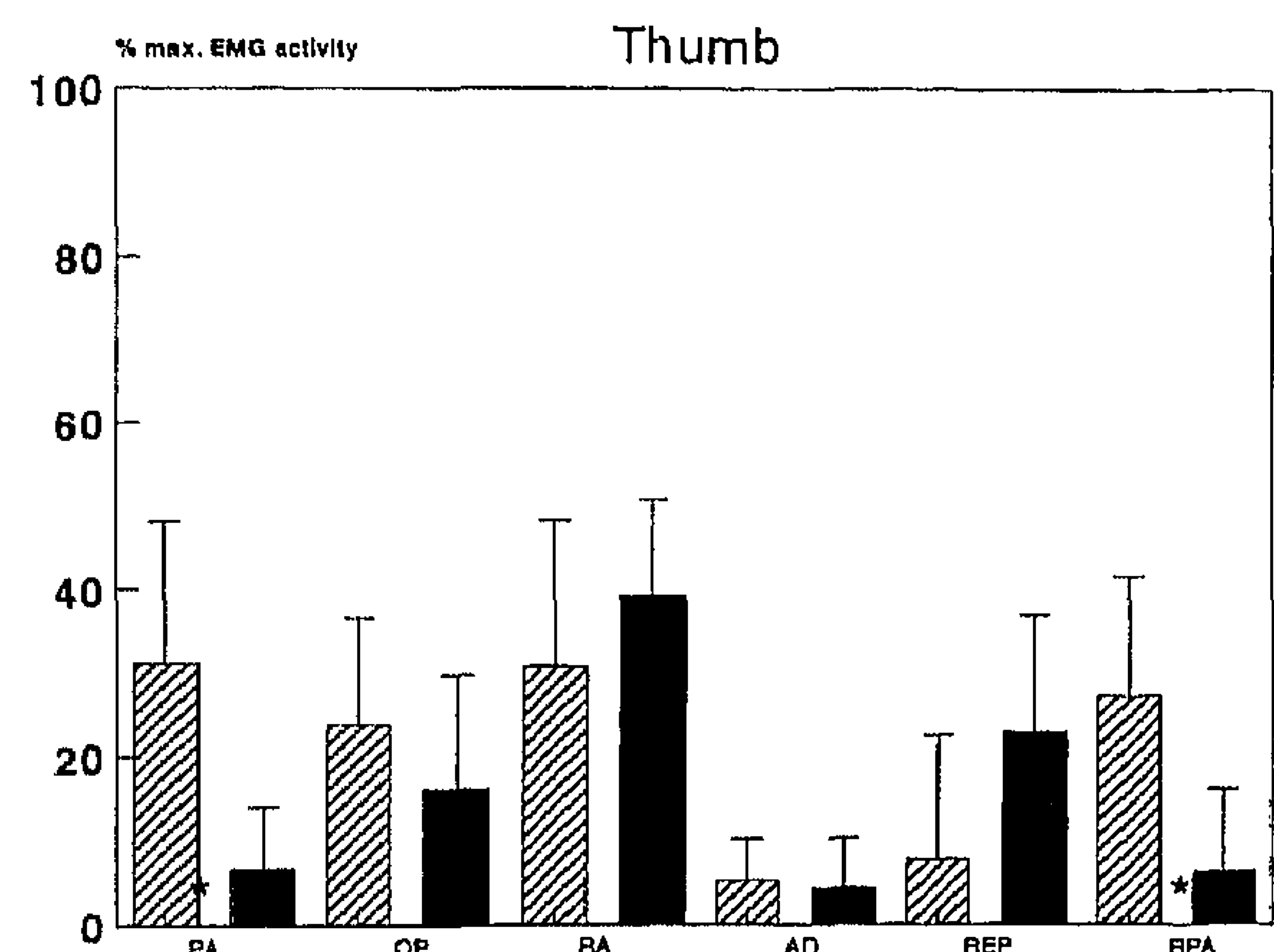


Fig. 2. Mean percentage of EMG activity relative to the maximum EMG activity for isometric contractions for APB and APLdeep in various directions. Bars indicate s.d. Hatched columns, APB; black columns, deep division of APL. PA, palmar abduction; OP, opposition; RA, radial abduction; AD, adduction; REP, reposition; RPA, repeated palmar abduction. \* Correlation significant ( $P \leq 0.05$ ).

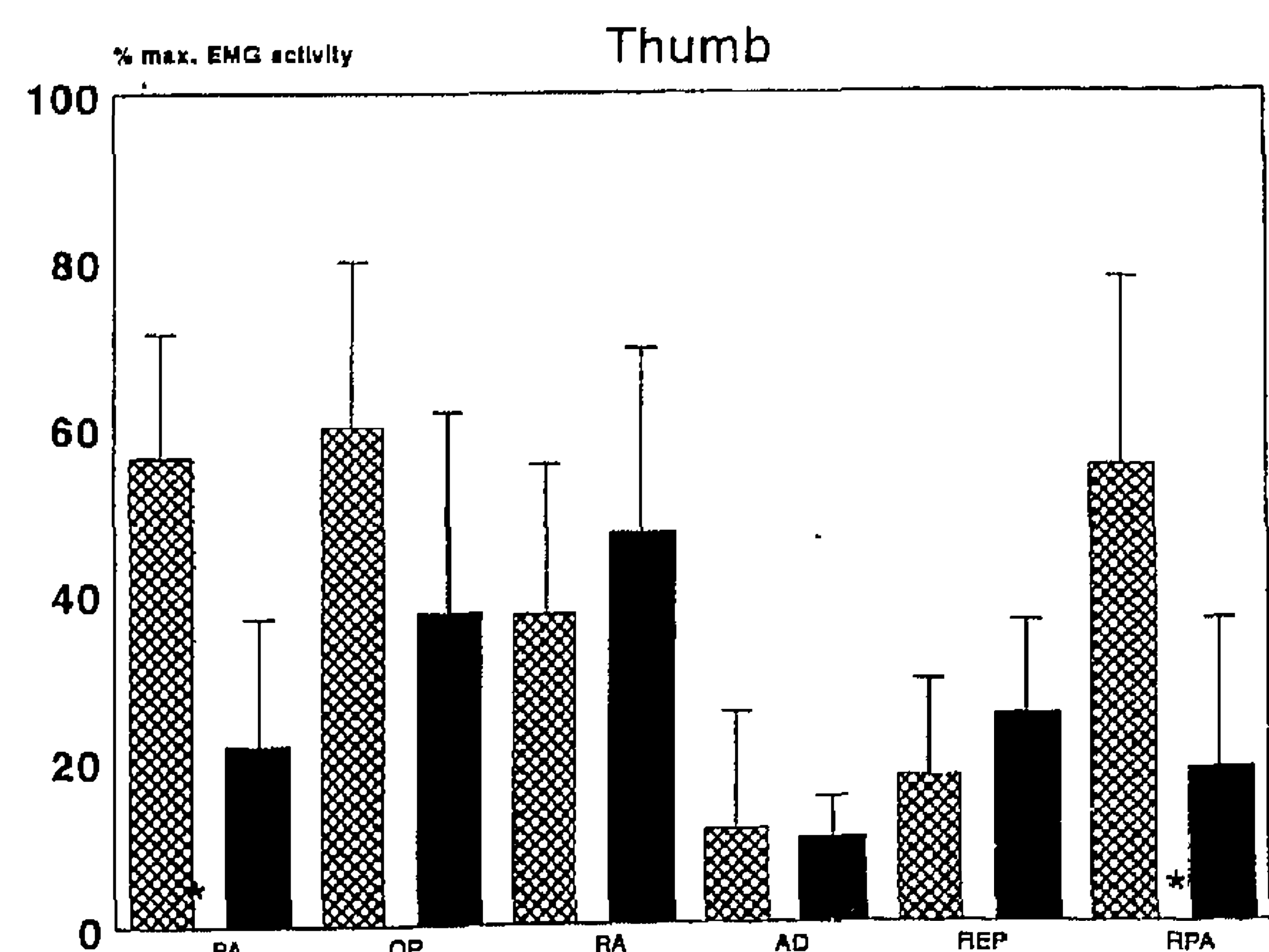


Fig. 3. Mean percentage of EMG activity relative to the maximum EMG activity for dynamic contractions for APB and APLdeep in various directions. Bars indicate s.d. Hatched columns, APB; black columns, deep division of APL. Abbreviations as in Figure 2. \* Correlation significant ( $P \leq 0.05$ ).



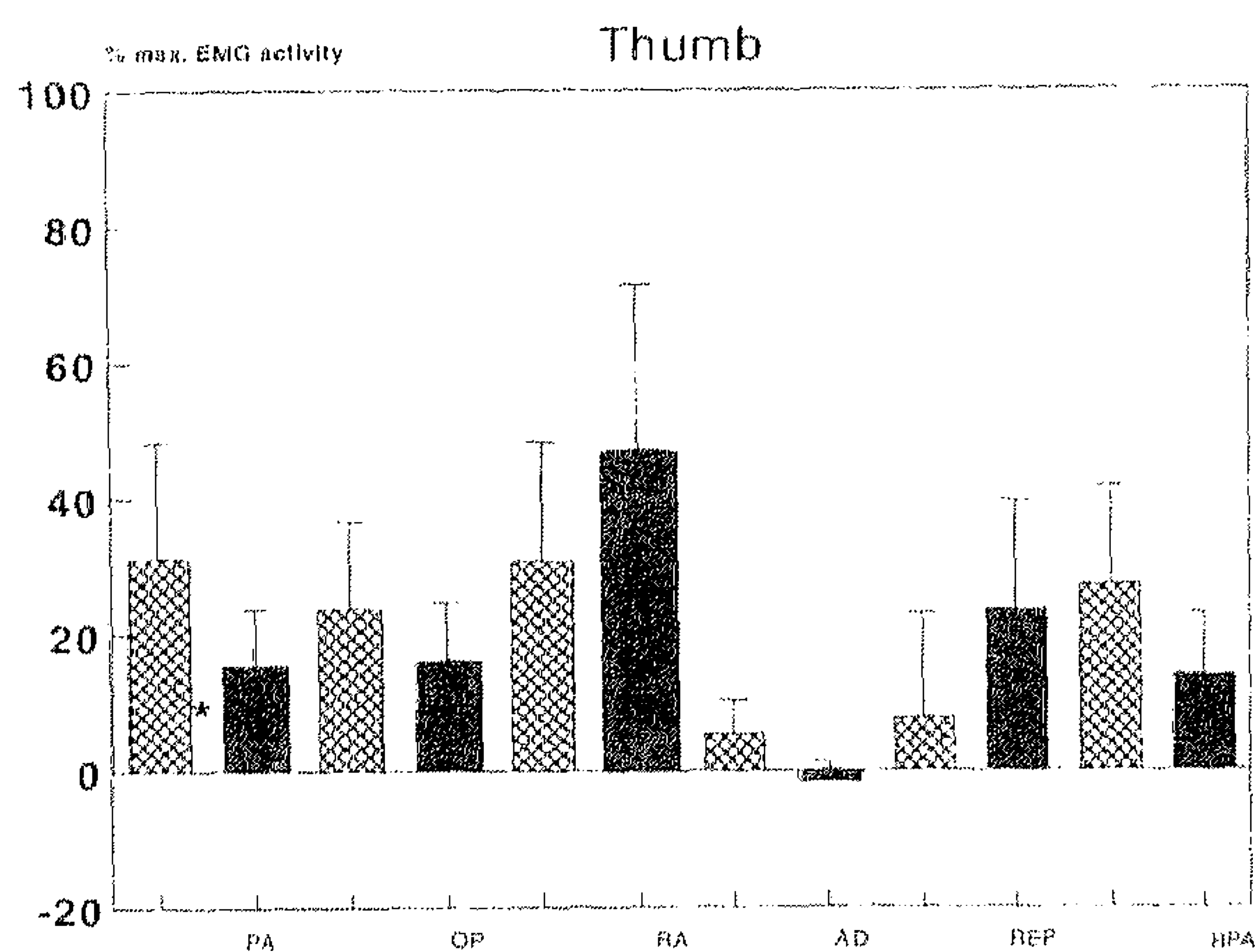


Fig. 4. Mean percentage of EMG activity relative to the maximum EMG activity for isometric contractions for APB and APLsup in various directions. Bars indicate s.d. Hatched columns, APB; black columns, superficial division of APL. Abbreviations as in Figure 2. \* Correlation significant ( $P \leq 0.05$ ).

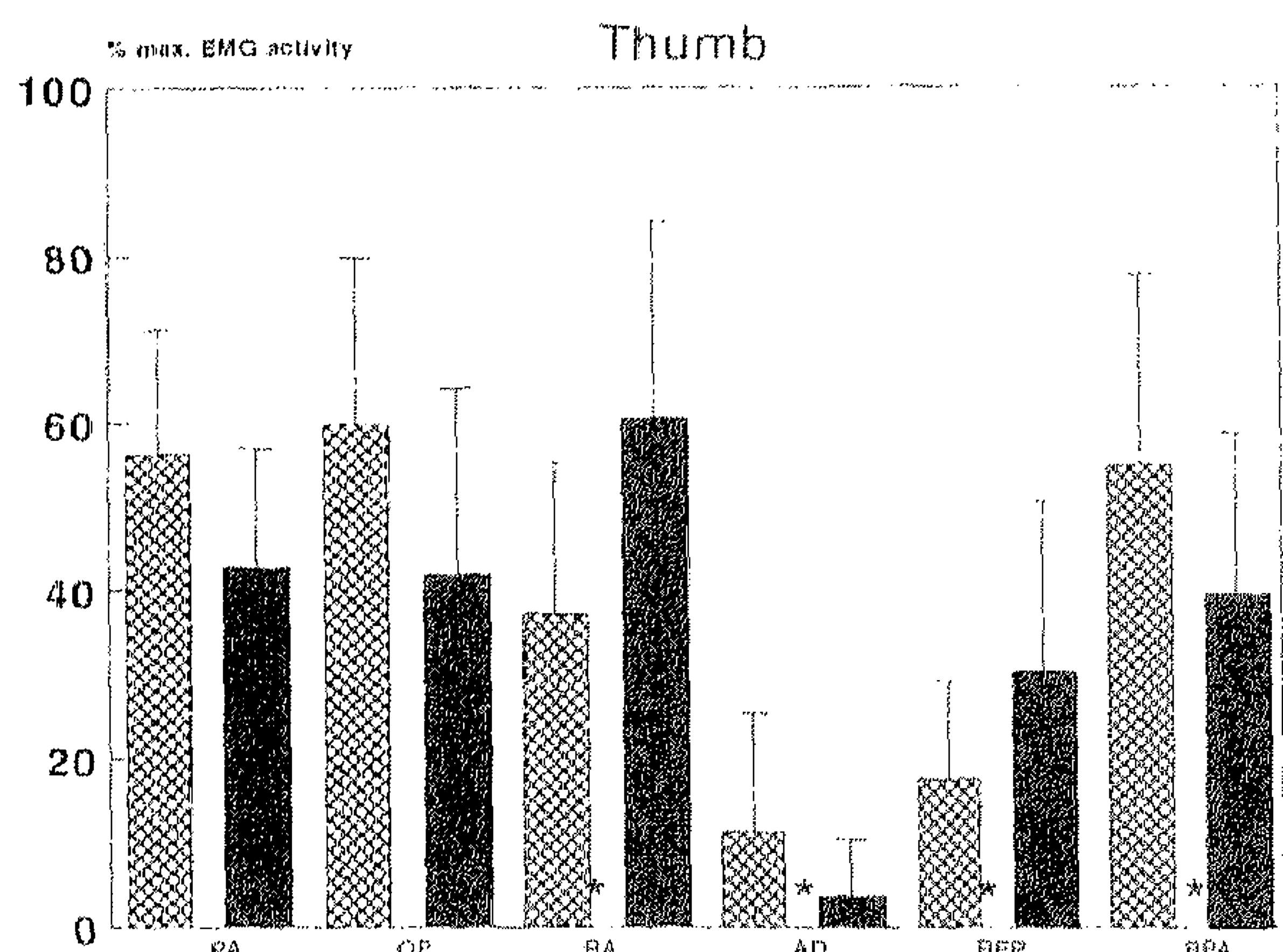


Figure 5. Mean percentage of EMG activity relative to the maximum EMG activity for dynamic contractions for APB and APLsup in various directions. Bars indicate s.d. Hatched columns, APB; black columns, superficial division of APL. Abbreviations as in Figure 2. \* Correlation significant ( $P \leq 0.05$ ).

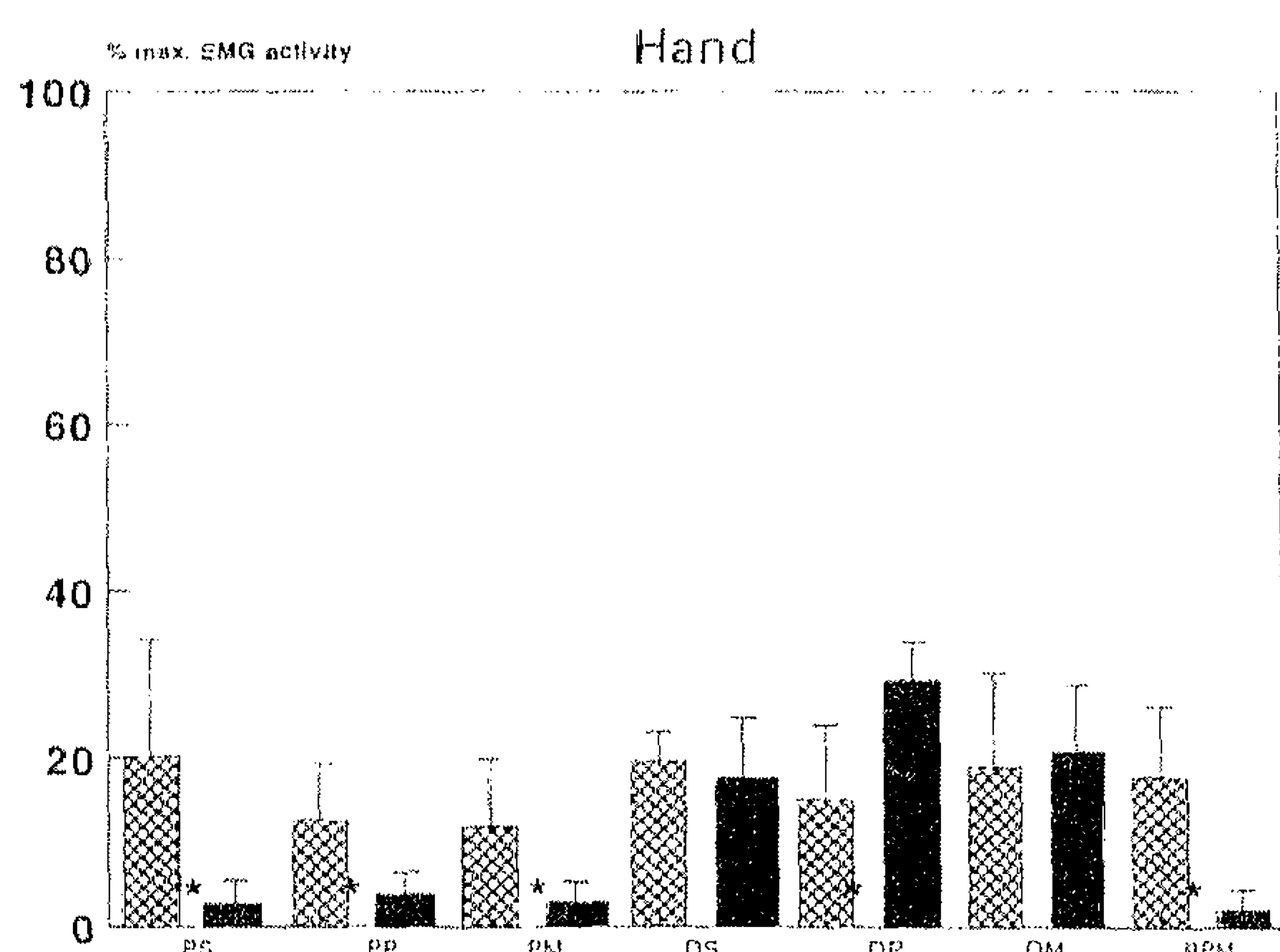


Fig. 6. Mean percentage of EMG activity relative to the maximum EMG activity for isometric contractions for APB and APLdeep in various directions. Bars indicate s.d. Hatched columns, APB; black columns, deep division of APL. PS, palmar flexion/supination; DS, dorsiflexion/supination; PP, palmar flexion/pronation; DP, dorsiflexion/pronation; PM, palmar flexion/midposition; DM, dorsiflexion/midposition; RPM = repeated palmar flexion/midposition. \* Correlation significant ( $P \leq 0.05$ ).

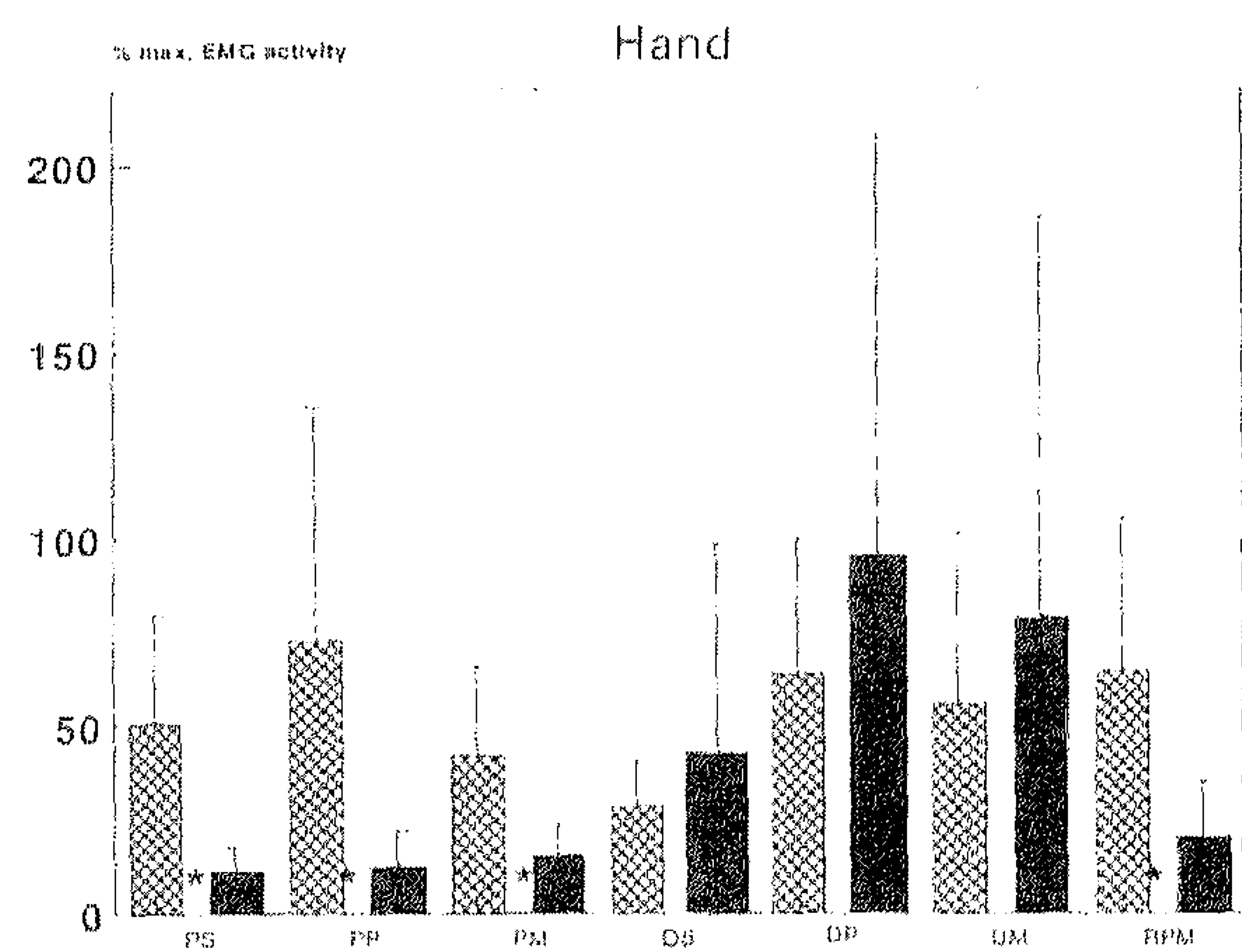


Fig. 7. Mean percentage of EMG activity relative to the maximum EMG activity for dynamic contractions for APB and APLdeep in various directions. Bars indicate s.d. Hatched columns, APB; black columns, deep division of APL. Abbreviations as in Figure 6. \* Correlation significant ( $P \leq 0.05$ ).

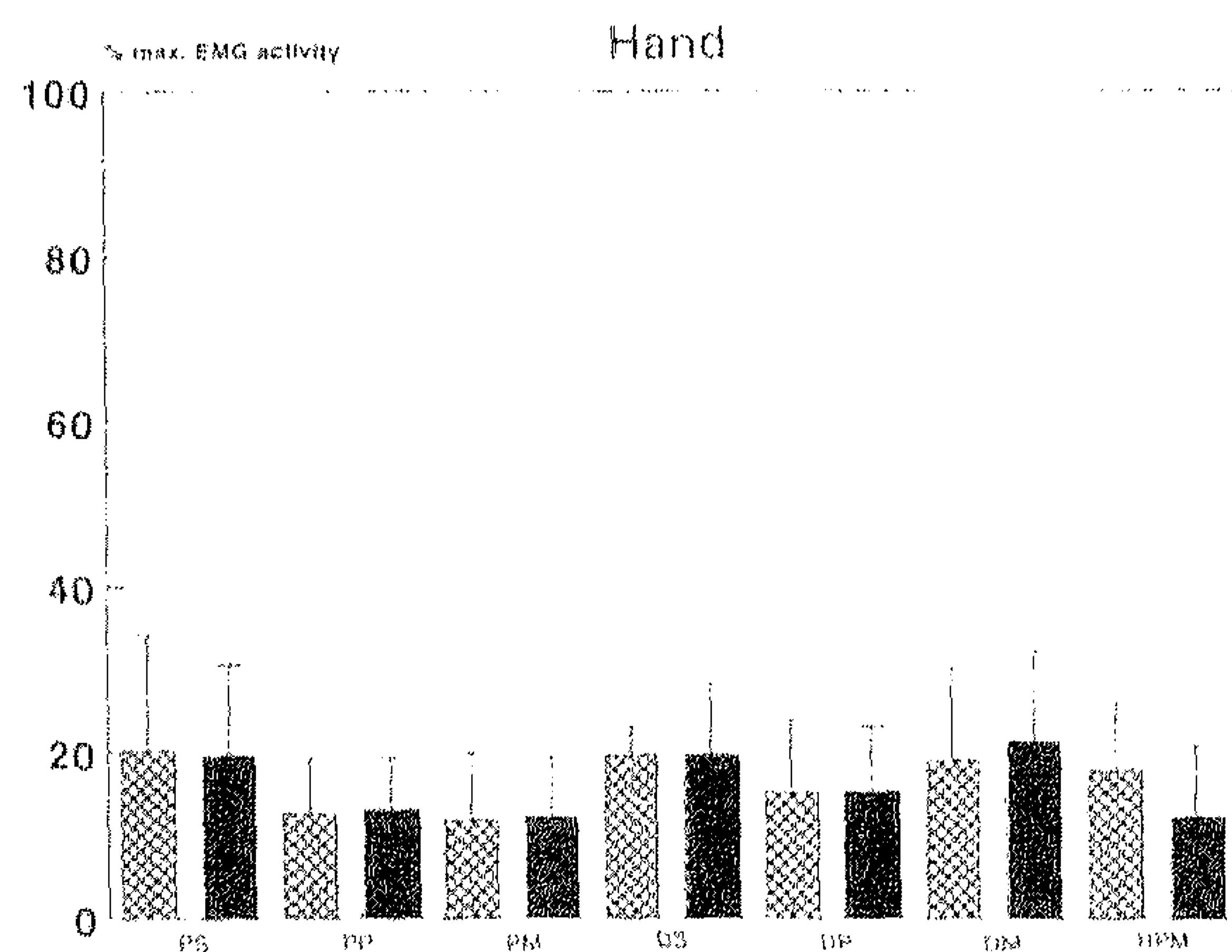


Fig. 8. Mean percentage of EMG activity relative to the maximum EMG activity for isometric contractions for APB and APLsup in various directions. Bars indicate s.d. Hatched columns, APB; black columns, superficial division of APL. Abbreviations as in Figure 6. \* Correlation significant ( $P \leq 0.05$ ).

The mean values of EMG signals, relative to the maximum EMG for isometric as well as for dynamic contractions, respectively, for APB and APLsup in various directions are presented in Figures 4, 5, 8 and 9.

#### APB

APB (without crossing the carpal joint) was activated in actions of the thumb as well as of the hand. In the tested directions of the *thumb*, APB was most strongly activated in palmar abduction, opposition and radial abduction, as is shown in Figures 2 and 4. In the other directions, only low EMG values were found. In the tested directions of the *hand* in isometric contractions of APB, no distinct difference was found in EMG



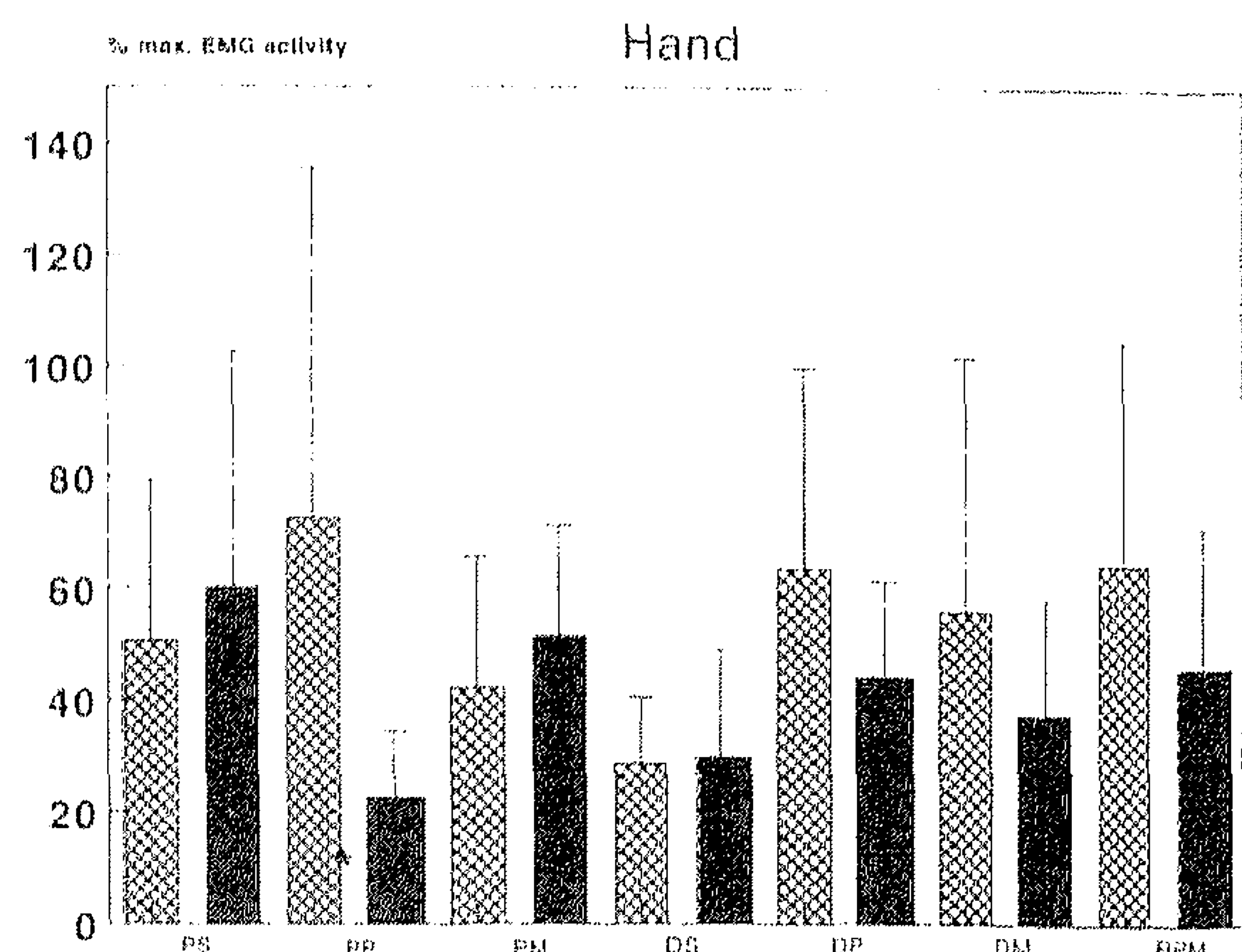


Fig. 9. Mean percentage of EMG activity relative to the maximum EMG activity for dynamic contractions for APB and APLsup in various directions. Bars indicate s.d. Hatched columns, APB; Black columns, superficial division of APL. Abbreviations as in Figure 6. \* Correlation significant ( $P \leq 0.052$ ).

activity between palmar flexion and dorsiflexion (Fig. 6). In dynamic contractions the largest values were found in the pronated position of the forearm (Fig. 7).

#### Deep division of APL

The APLdeep was most strongly activated in dorsiflexion of the hand, but (without crossing CMCI) also in actions of the thumb, especially in radial abduction (Fig. 2). In the tested directions of the *thumb* the APLdeep, without an insertion into the thumb, was activated in opposition, radial abduction and reposition as is shown in Figures 2 and 4. In the tested directions of the *hand* the strongest EMG activity of the APLdeep was found in dorsiflexion of the hand, regardless of the position of the forearm, in isometric as well as in dynamic contractions (Figs 6, 7). EMG activity in isometric palmar flexion of the hand was negligible, about 3–4% of the maximum EMG (Fig. 6).

#### Superficial division of the APL

The EMG activity of the APLsup showed no distinct difference between actions of the thumb or the hand in isometric or dynamic contractions. In the tested directions of the *thumb* in isometric as well as in dynamic contractions, this muscle was most strongly activated in radial abduction (Figs 4, 5). This activation was much greater than for the other directions of the thumb. In isometric contractions of the *hand* no distinct difference in EMG activity was found between the tested directions. The largest value was found in dynamic supinated palmar flexion (Fig. 9), which is similar to the activity in dynamic radial

abduction of the thumb (both 60% of the maximum EMG).

#### Relationship between APB and APLdeep

The anatomical connections between APB and APLdeep are shown in Figure 1. Differences between the mean percentages of EMG signals, relative to the maximum EMG for isometric as well as for dynamic contractions for both APB and the APLdeep in various directions for the thumb and the hand are shown in Figures 2, 3, 6 and 7.

#### Relationship between APB and superficial APL

Differences between the mean percentages of EMG signals, relative to the maximum EMG for isometric as well as dynamic contractions for both APB and APLsup in various directions for the thumb and the hand are shown in Figures 4, 5, 8 and 9.

#### DISCUSSION

The main result of this study is a direct functional relationship between the APLdeep and APB. The APLdeep as well as APB were activated in actions of a joint which is not crossed by these muscles. The APLdeep was activated in movements of the thumb and APB in movements of the hand, as is shown in Figure 1.

APB and the APLdeep are closely connected anatomically. Therefore cooperation between these muscles in movements of the thumb or the hand is very likely. APB is innervated by the median nerve and APL by the radial nerve. In general it is assumed that a separate innervation of muscle parts corresponds to a different function. In this case, to the contrary, in some conditions there is an interaction between 2 muscles innervated by 2 different nerves.

#### Relationship between APB and APLdeep

The APLdeep as well as APB have an insertion into the trapezium. A cooperative function between these muscles to stabilise the trapezium to the carpus is necessary during movements of the thumb or the hand. Both muscles can be considered to act as a force couple on the trapezium (Fig. 1).

In the tested directions of the *thumb* the level of EMG activity in palmar abduction was significantly larger in APB than in the APLdeep for isometric as well as for dynamic contractions (Figs 2, 3). APB can be considered as a prime mover for palmar abduction



and opposition of the thumb (Figs 2, 3). The APLdeep was activated in general to prevent undesired movements of the hand at the carpal joint. In palmar abduction of the thumb the APLdeep has to prevent a palmar flexion of the hand, in opposition a pronation of the forearm, in radial abduction a radial deviation of the hand and in reposition to stabilise the trapezium to the carpus.

In the tested directions of the *hand* in isometric palmar flexion the EMG activity of the APLdeep can be neglected (Figs 6, 7). From this it is clear that APB showed significantly more EMG activity in palmar flexion than the APLdeep. The EMG activity from APB, which does not cross the carpal joint, can be explained by its direct connection to the APLdeep. The insertion from the APLdeep into APB suggests that both muscles together can be considered as one long muscle with 2 bellies. In palmar flexion of the hand the tendon of the APLdeep inserting into the trapezium will lengthen; at the same time the tendon inserting into APB will relax (Fig. 1). It can be hypothesised that both muscles regulate the tension of each other.

In dorsiflexion of the hand, the amount of activation of APB is the same as for palmar flexion; the APLdeep is more strongly activated for dorsiflexion than for palmar flexion. The APLdeep will now shorten, and the tendon which inserts into APB will also regulate the tension of APB.

#### *Relationship between APB and the APLsup*

The APLsup has, in contrast to the deep division, no direct anatomical connection with APB. Both muscles insert into the thumb, the APLsup inserts into MCI and APB into the proximal phalanx. Both muscles can thus be considered as prime movers of the thumb.

In the tested directions of the *thumb*, differences in the EMG signals for these 2 muscles were found. APB was more strongly activated than the APLsup for palmar abduction and opposition and less strongly activated than the APLsup for radial abduction and reposition in isometric as well as in dynamic contractions. The differences between the 2 muscles were not significant in all directions, but in most of the individual subjects these differences were present. The differences in activation between these muscles can be explained anatomically. APB is situated on the palmar side of the hand and is therefore in a better position for palmar abduction and opposition than APL. APB can act directly on the CMCI joint. The APLsup is limited in its function at the same joint because it passes through the retinaculum and inserts directly

after the joint cleft into MCI. The greater amount of EMG activity in radial abduction and in reposition of the APLsup can be explained from the position of this muscle, which originates mainly from the dorsal aspect of the interosseous membrane.

The differences in isometric EMG activity between both muscles in the tested directions of the *hand* are very small (fewer than 1%) and not significant (Fig. 8). Both muscles are short and insert directly into the bones of the thumb.

The results of this study may have implications in clinical assessment and in pathological and surgical conditions in which these muscles are implicated. The following come to mind: voluntary muscle testing, paralysis of APL in radial palsy, use of APL in ulnar and/or median nerve paralysis, and involvement of APL, APB and trapezium in conditions such as tendosynovitis and oosteoarthritis.

#### *Conclusions*

From the EMG analysis of APB and APL it appears that both muscles are activated in the tested directions of the thumb as well as in those of the hand. Cooperation between these muscles is necessary to stabilise the trapezium to the carpus in movements of the thumb. APB is activated in movements of the hand to maintain the tension in the deep division of the APL. The APLdeep is activated in movements of the thumb to prevent undesired movements of the hand and forearm. APB and the superficial division of APL are the prime movers of the thumb.

#### ACKNOWLEDGEMENTS

The authors are grateful to Professor C. C. A. M. Gielen, Department of Medical Physics and Biophysics, University of Nijmegen, the Netherlands, for encouraging this project, supplying some of the material and providing hospitality in his laboratory. The authors wish to thank Peter Snoeren for producing Figure 1.

#### REFERENCES

- BERGER RA, CROWINSHIELD RD (1982) The three-dimensional rotational behaviors of the carpal bones. *Clinical Orthopaedics and Related Research* 167, 303-310.
- KAUER JMG (1986) The mechanism of the carpal joint. *Clinical Orthopaedics and Related Research* 202, 16-26.
- KAUER JMG, DE LANGE A (1987) The carpal joint. *Hand Clinical* 3, 23-29.
- KRAUTH J (1988) *Distribution-free Statistics*, vol. 2. Amsterdam: Elsevier.

- ROMANES GJ (Ed.) (1976) *Cunningham's Textbook of Anatomy*. London: Oxford University Press.
- RUBY LK, COONEY WP, AN KN, LINDSCHEID RL, CHAO EYS (1988) Relative motion of selected carpal bones: kinematic analysis of the normal wrist. *Journal of Hand Surgery* **13A**, 1-10.
- SIMARD TG, ROBERGE J (1988) Human abductor pollicis brevis muscle 'divisions' and the nerva hilla. *Anatomical Record* **222**, 426-436.
- SPINNER M (ed.) (1984). *Kaplan's Functional and Surgical Anatomy of the Hand*, 3th edn. Philadelphia: Lippincott.
- TERMINOLOGY FOR HAND SURGERY (1970) International Federation of Societies for Surgery of the Hand. Reprinted (1972) in *The Hand* **4**, 278-285.
- VAN OUDENAARDE E (1991a) Structure and function of the abductor pollicis longus muscle. *Journal of Anatomy* **174**, 221-227.
- VAN OUDENAARDE E (1991b) The function of the abductor pollicis longus muscle as a joint stabilizer. *Journal of Hand Surgery* **16B**, 420-423.
- VAN OUDENAARDE E, ELVERS JWH, GIELEN CCAM, KAUER JMG, OOSTENDORP RAB, VAN DER STRAATEN JHM (1994) Differences and similarities in electrical muscle activity for the abductor pollicis longus muscle divisions. *Journal of Electromyography and Kinesiology* **4**, in press.
- WARWICK R, WILLIAMS PL (Eds) (1975) *Gray's Anatomy*, 35th edn. Edinburgh: Longman.