Radboud Repository

Radboud University Nijmegen

PDF hosted at the Radboud Repository of the Radboud University Nijmegen

The following full text is a publisher's version.

For additional information about this publication click this link.
http://hdl.handle.net/2066/22015

Please be advised that this information was generated on 2017-12-05 and may be subject to change.

Expression of Plasminogen Activators and Plasminogen Activator Inhibitors in Cutaneous Melanomas of Transgenic Melanoma-susceptible Mice[1]

Teunis J. de Vries, Janice L. Kitson,[2] Willys K. Silvers,[3] and Beatrice Mintz[4]

Institute for Cancer Research, Fox Chase Cancer Center, Philadelphia, Pennsylvania 19111

ABSTRACT

The Tyr-SV40E transgenic mouse model of malignant skin melanoma has been used here to generate melanomas in genetically identical (C57BL/6) mice for analysis of the plasminogen activator (PA) system during tumor development and progression. Twenty-two melanocytic lesions were examined by *in situ* zymography for PA activity and by immunohistochemistry for concomitant visualization of PA proteins; these lesions encompassed 3 nevi and 19 primary melanomas ranging from melanotic through mixed tumors to amelanotic tumors. Although urokinase-type plasminogen activator (u-PA) activity was not detected at premalignant stages, it began to appear early in tumorigenesis and became more prominent in later stages of a majority of the tumors. The activity was largely attributable to the endothelium of sprouting capillaries and to a lesser degree to granulocytes, fibroblastic cells, and occasional melanoma cells within tumors. Tissue-type plasminogen activator (t-PA) was undetectable or low in all cases. Of the PA inhibitors (PAI), PAI-1 was seen in endothelial and fibroblastic cells and in the extracellular matrix, whereas PAI-2 occurred in only one case and was melanoma cell associated. Eleven additional melanomas were analyzed by reverse transcription-PCR for PA expression in RNA extracts from relatively large tumor samples. These were obtained from eight primary melanomas and three metastases, again spanning melanotic, mixed, and amelanotic cases. From four of the mixed primary tumors with distinct melanotic and amelanotic zones, the respective components were propagated separately in transgenic hosts as s.c. transplants to obtain data for clearly identifiable melanotic *versus* amelanotic parts. u-PA and PAI-1 mRNAs were expressed in all. t-PA expression varied greatly and was notably high in several amelanotic tumors or tumor components, possibly as a result of large blood vessels, as such vessels were seen to be t-PA positive in normal tissue. The u-PA activity in sprouting capillaries may indicate a role in neoangiogenesis. Therefore, according to these mouse models, u-PA may indirectly be a potential therapeutic target against melanoma progression.

INTRODUCTION

The melanoma-susceptible transgenic mouse strain introduced in this laboratory (1, 2) affords many possibilities for experimental analysis of mechanisms underlying melanoma progression and metastasis. In the transgene, designated Tyr-SV40E, SV40 oncogenic sequences are under the transcriptional control of the mouse tyrosinase gene promoter; as a result, the transforming sequences are activated specifically in pigment cells. Different levels of transgene expression occur among Tyr-SV40E mouse lines, each of which is composed of lineal descendants from a single egg injected with transgene DNA. Eye melanomas, originating chiefly in the retinal pigment epithelium (3), generally arise before skin melanomas and are fatal at a young age in mice of lines with high transgene expression. To obtain skin melanomas, pieces of skin were grafted from transgenic donors of a high-susceptibility and short-lived line to hosts of a low-susceptibility line in which eye tumors arise late; in this way, the more susceptible skin outlives the donors (4). Melanomas develop reliably in the skin grafts and progress to malignancy. Their histopathogenesis strikingly resembles that of human cutaneous melanomas, and they generate regional as well as distant metastases (5). Because the animals are all of the same standard inbred strain (C57BL/6), tumor progression can be characterized within the context of a constant genetic background. The tumors clearly undergo an orderly series of changes tending toward accelerated growth and diminished pigmentation.[5]

One of the biological parameters of special interest in tumor progression is the increased expression of proteases and their inhibitors in malignant tumors compared with premalignant precursor lesions (6, 7). PAs[6] are part of a proteolytic system thought to be involved in tumor cell spread. Two PAs, t-PA and u-PA, are known. t-PA is secreted as an active enzyme, whereas u-PA is exported as an inactive proenzyme and is activated upon binding to its receptor, u-PAR. The activity of u-PA and t-PA can be inhibited by two specific plasminogen activator inhibitors, PAI-1 and PAI-2 (reviewed in Refs. 6, 8).

The involvement of the PA system in melanoma metastasis has been inferred from experiments with murine or human melanoma cell lines. Metastasis of B16 mouse melanoma cells after injection into mice was reduced when they were preincubated with anti-u-PA antibodies (9) and was increased when they were transfected with the *u-PA* gene (10). The expression of u-PA and PAI-1 in human melanoma cell lines was found to be correlated with their capacity for metastasis in nude mice (11). Moreover, the binding of u-PA to u-PAR promoted migration of human melanoma cells in invasion assays in culture (12). The overexpression of PAI-2 inhibited metastasis of the cells in immunodeficient mice (13). These observations are consistent with the expression pattern of the PA system in human cutaneous melanocytic lesions: Plasminogen activators, u-PAR, and the PAIs are absent in premalignant lesions and emerge in the primary malignant melanomas and in metastases (14, 15). Herein, we describe the presence and activity of plasminogen activators and the occurrence of their inhibitors in mouse skin melanomas derived *in vivo* from melanocytes in Tyr-SV40E transgenic skin grafts.

MATERIALS AND METHODS

Melanomas. One-cm discs of full-thickness body skin were taken from transgenic line 8 hemizygous donors in most cases (in two cases, from line 9 homozygous donors) and were transplanted to line 12 hemizygous recipients. Mice of these lines have high, moderate, and low transgene expression, respectively (1). In addition, some line 8 grafts were taken from the skin of the snout area, in which the vibrissa follicles are situated. The donor skin was

Received 6/2/95; accepted 7/14/95.

The costs of publication of this article were defrayed in part by the payment of page charges. This article must therefore be hereby marked *advertisement* in accordance with 18 U.S.C. Section 1734 solely to indicate this fact.

[1] This work was supported by United States Public Health Services Grants CA-42560 (to B. M.), CA-06927 and RR-05539 to the Fox Chase Cancer Center, and an appropriation to the Fox Chase Cancer Center from the Commonwealth of Pennsylvania. T. J. de V. was the recipient of a stipend jointly awarded by the Dutch Cancer Society, The Netherlands Organization for Scientific Research, and the Dutch Society for Cell Biology while on leave from the Department of Pathology, University Hospital, Nijmegen, the Netherlands.

[2] Present address: Department of Molecular and Cell Biology, The Wellcome Trust, London, United Kingdom.

[3] Visiting Scientist from the University of Pennsylvania, Philadelphia, PA.

[4] To whom requests for reprints should be addressed, at Institute for Cancer Research, Fox Chase Cancer Center, 7701 Burholme Avenue, Philadelphia, PA 19111.

[5] W. K. Silvers, A. J. P. Klein-Szanto, and B. Mintz, unpublished data.

[6] The abbreviations used are: PA, plasminogen activator; t-PA, tissue-type plasminogen activator; u-PA, urokinase-type plasminogen activator; u-PAR, u-PA receptor; PAI, plasminogen activator inhibitor; RT, reverse transcription; GAPDH, glyceraldehyde-3-phosphate dehydrogenase.

grafted on the lateral trunk as described (4). Donor ages varied; hosts were young adults. Tumor-bearing animals and controls were killed by cervical dislocation, and tumors and other tissues were dissected in cold PBS.

For *in situ* studies of the presence and activity of PA proteins, a piece of tissue was blotted to remove excess moisture, embedded in Tissue-Tek (Miles Inc.), and snap frozen in liquid nitrogen. Cryostat sections of the block were stained in hematoxylin and eosin for histological characterization in relation to nearby sections cut at 6 μm for *in situ* zymography and at 4 μm for immunohistochemistry. The sections for *in situ* zymography were frozen immediately and stored at −80°C. Sections for immunohistochemistry were air dried overnight and stored at −80°C. For studies of tumor mRNAs by RT-PCR, the tissue was frozen in liquid nitrogen or dry ice and stored at −80°C.

***In Situ* Zymography.** The *in situ* zymography method was adapted from published procedures (14, 15). Cryostat sections were covered with an overlay mixture containing 2% (w/v) instant nonfat dry milk solution, 0.9% agar (w/v), and 30 μg/ml plasminogen. The dry milk solution was prepared as an 8% (w/v) stock solution in PBS, heated at 95°C for 30 min, centrifuged briefly at 3×10^3 *g*, and the supernatant was used. The overlay solution was prepared at 55°C; 110 μl were applied on freshly defrosted 6-μm sections and spread evenly under 24 × 32 mm glass coverslips. Slides were incubated at 37°C in a humidified chamber. Development of lysis was monitored for up to 10 h; photographic records were taken at 3, 4.5, 6, and 7.5 h of incubation. Serial dilutions of mouse u-PA and mouse t-PA (reagent #119 and #118, respectively; American Diagnostica Inc., Greenwich, CT) were made in small drops of agarose on a glass slide. Addition of amiloride (2 mM) to the overlay solution was found to inhibit mouse u-PA specifically, whereas goat polyclonal antibody against human t-PA (reagent #387; American Diagnostica Inc.) was found to inhibit mouse t-PA specifically. Experiments were performed with the addition to the overlay mixture of 2 mM amiloride to inhibit u-PA activity or of goat polyclonal antibody against human t-PA to inhibit t-PA activity to discriminate between the two types of PA activities.

Antibodies. Polyclonal antibodies used against the different components of the plasminogen activation system are listed in Table 1. Antibodies were either against the mouse component or against the rat or human equivalent. Several antibodies have been used previously in immunohistochemistry of mouse lesions (16–19). Human and mouse PAIs are related immunologically (16, 20). Immunohistochemical staining for u-PA, PAI-1, and PAI-2 was tested on tissue sections of fresh-frozen midgestational mouse placenta, and for t-PA on tissue sections of mouse lung. Staining with the two u-PA, the two PAI-1, and the two PAI-2 antibodies compared well with each other in placenta and in melanocytic lesions. In addition to the reagents listed in Table 1, three anti-human u-PAR and one anti-rat u-PAR polyclonal antibodies were tested on placental tissue. They were excluded from additional study because of very variable reactivity with placental tissue, as well as the limited homology between the human and mouse u-PAR (21).

Immunohistochemistry. Air-dried cryostat sections, cut at 4 μm, were fixed for 10 min in acetone. Polyclonal antibodies were added in 1% BSA in PBS for overnight incubation at 4°C in a humidified chamber. The sections were washed three times for 5 min in PBS, incubated with peroxidase-labeled swine anti-rabbit Ig or with peroxidase-labeled donkey anti-goat Ig for 30 min, and washed again three times for 5 min in PBS.

Bound antibodies were visualized with 3-amino-9-ethylcarbazole as a substrate for peroxidase. After being counterstained with Meyer's hematoxylin, cover slips were mounted with Kaiser's glycerin (Merck, Darmstadt, Germany). A parallel incubation, in which the first antibody was omitted, served as a negative control.

RT-PCR. To gauge semiquantitatively the specific expression of *PA* genes at the mRNA level, other examples of transgenic mouse melanomas were analyzed by RT-PCR. This aspect of the study was concerned partly with comparing expression in melanotic *versus* amelanotic parts of primary tumors; therefore, some of the melanomas were chosen for RT-PCR analysis because they had clearly distinguishable melanotic and amelanotic zones. The two components were separated and cut into fragments of approximately 1 mm^3, and 8–10 pieces of the melanotic or amelanotic phenotype were injected s.c. by trocar into line 12 hemizygous male hosts. After tumors had been obtained, examples were retransplanted s.c. two or more times to verify retention of the melanotic or amelanotic status before samples were collected and stored. Additional cases were chosen from primary or metastatic tumors that appeared to be all-melanotic or all-amelanotic.

Table 1 *Antibodies used in the immunohistochemical analyses*

Antigen	Antibody	Source	Ref.
t-PA	#387 Goat anti-human t-PA	American Diagnostica Inc.	17
u-PA	Pool 6 rabbit anti-mouse u-PA #1189 Rabbit anti-mouse u-PA	Finsen Laboratory American Diagnostica Inc.	18, 19
PAI-1	Batch 4544 rabbit anti-human PAI-1 #1062 Rabbit anti-rat PAI-1	Finsen Laboratory American Diagnostica Inc.	16, 19
PAI-2	Goat anti-human PAI-2 #375 Goat anti-human PAI-2	Behring Werke AG American Diagnostica Inc.	

Total RNA from each tumor sample intended for RT-PCR was isolated with RNAzol B solution (Cinna/Biotecx, Houston, TX). The procedure for RT-PCR was essentially as described (22). Each amplification cycle was carried out in a programmable thermal controller (MJ Research, Inc.) and included 1 min at 55°C annealing temperature for the primers used; this was repeated for 25 cycles for the *PA* genes of interest and for 20 cycles for GAPDH, which was used as the loading control.

The amplification products from each reaction were run on a 2% agarose gel (LE agarose; FMC Bioproducts) along with a DNA size marker. The DNA was transferred to nitrocellulose after denaturing and neutralizing and was then fixed to the filter by UV cross-linking. Oligonucleotide probes specific for the amplified region were end labeled with [γ-^{32}P]ATP (DuPont-NEN, Boston, MA) and polynucleotide kinase (BRL, Gaithersburg, MD) to a specific activity of 2×10^9 dpm/μg, and filters were hybridized overnight. The optimal hybridization temperature was found to be 50°C for t-PA, 55°C for u-PA, and 40°C for PAI-1 and GAPDH. Filters were washed to remove background. To measure the relative levels of specific transcripts recovered as cDNAs, the filters were placed in an AMBIS radioanalytic imager, and the radioactivity in each band of interest was normalized against that in GAPDH in each sample. The levels of the latter remained relatively constant among samples.

The following sets of primers and probes were based on known oligonucleotide sequence data for mouse t-PA, u-PA, and PAI-1 and for rat GAPDH: t-PA primers, 5′-GGGAGGTTCAGAAGAGGAGCCCGG, 3′-GCGTTTCCCTACAAATCCATCAGGG, and probe, GGCTCCGACCCATGCTCAGAAGCAGCCGGG (23); u-PA primers, 5′-TGCCCAAGGAAATTCCAGGG, 3′-GCCAATCTGCACATAGCACC, and probe, CTGGAATGCGCCTGCTGTCCTTC (24); PAI-1 primers, 5′-CACAAGTCTGATGGCAGCAC, 3′-CAGGCATGCCCAACTTCTC, and probe, CAGCATGTTCATCGCTGCACCC (25); and GAPDH primers, 5′-GTGAAGGTCGGTGTCAACG, 3′-GTGAAGACGCCAGTAGACTC, and probe, GTTCCAGTATGATTCTACCCACGG (26).

RESULTS

Melanocytic Lesions Examined *in Situ*. For the *in situ* studies, 22 lesions were examined. Of these, 17 arose in the grafts of transgenic body skin; 2 were classified as nevi, 2 as melanotic tumors, 5 as mixed tumors (in which amelanotic parts were much larger than melanotic ones), and 8 as amelanotic tumors. Five other lesions arose in the grafts of transgenic snout skin; one was classified as a nevus, three as mixed tumors (with substantially larger amelanotic than melanotic parts), and one as an amelanotic tumor (Table 2).

As noted previously (5), the earliest pigmentary change detected histologically in transplanted body skin of transgenic mice is melanocytic hyperplasia and hypermelanization; it is first unequivocally distinguishable in the superficial dermis. The possibility has not been excluded that still earlier changes may occur in melanocytes in the epidermis. In mouse skin of the snout region, in which the vibrissa follicles are especially prominent, spontaneous early melanomas have occasionally been seen within these follicles in Tyr-SV40E mice (1). Therefore, it seemed likely that, by grafting transgenic skin from the snout area, advanced melanomas might be experimentally obtained from intrafollicular melanocytes. This has been proven to be the case.[7]

Zymographic Evidence of Plasminogen Activity. The results of *in situ* zymography to detect plasminogen activation in mouse mela-

[7] W. K. Silvers and B. Mintz, unpublished data.

Table 2 *Plasminogen activation based on in situ zymography[a] of melanocytic lesions in Tyr-SV40E (C57BL/6) transgenic skin grafts*

Tissue or case no.[b]	Melanoma pigmentation[c]			Relative melanoma size			t-PA	u-PA
	M	A > M	A	Small	Medium	Large		
Body skin								
C57BL/6 control							–	–
Line 8 hemi. control							+	–
320[d] nevus							–	–
385[d] nevus							–	–
335	✓			✓			–	+
467	✓					✓	–	+
371P1[e]		✓		✓			–	+++
306		✓			✓		–	++++
385[d]		✓				✓	–	+++
386		✓				✓	–	++++
320[d]		✓				✓	–	++++
390P1[e]			✓	✓			–	–
390P2[e]			✓	✓			–	–
303			✓		✓		–	++
330			✓		✓		–	++++
305			✓			✓	–	++
367			✓			✓	–	++
371P2[e]			✓			✓	–	+++
336			✓			✓	–	++++
Snout skin								
C57BL/6 control							–	–
Line 8 hemi. control							+++[f]	–
340[d] nevus							–	–
339			✓	✓			–	–
340[d]		✓			✓		–	+++
338		✓			✓		–	++
353		✓				✓	–	++++

[a] Graded visually as –, no lysis; ++++, +++, ++, +, lysis present after 3, 4.5, 6, or 7.5 h.
[b] Entries listed only by case no. are melanomas.
[c] Melanoma pigmentation, based on examination at ×15 magnification: M, melanotic; A > M, amelanotic part greater than melanotic; A, amelanotic.
[d] Comparison of a melanoma with premalignant lesions in adjacent skin of a numbered case.
[e] Independent primary melanomas (P1 and P2) in the same skin graft of a numbered case.
[f] t-PA mediated lysis was localized.

nocytic skin lesions are summarized in Table 2. Photographs taken at various times of incubation were examined, and the time of inception of plasminogen activation-mediated lysis was estimated (from – to ++++). Typical examples of the in situ zymographic records are shown in Fig. 1.

t-PA enzyme activity either was usually not detected or was very localized in the melanocytic lesions examined. u-PA enzyme activity was absent in normal and transgenic body and snout skin; it also was not detected in nevi of body skin (Fig. 1*a*) or in intrafollicular nevi of snout skin (Fig. 1*f*). Although only very weak and delayed u-PA-mediated lysis was observed in the two melanotic tumors (as shown in Fig. 1*b*), marked and early u-PA activity was detected in the mixed and amelanotic tumors in body skin (Fig. 1, *c–e*) and in tumors in the vibrissa follicles (Fig. 1*g*). In a mixed tumor (Fig. 1*c*), lysis occurred much more rapidly in the amelanotic part of the tumor. In the mixed and amelanotic tumors in body skin and in the vibrissa-follicle tumors, heterogeneity was observed with respect to the time at which lysis first occurred (Table 2). Within tumors, regions with early lysis occurred along with regions of delayed lysis or no lysis.

In normal mouse lung, the specificity of t-PA plasminogen activation was documented by its virtual abolition when t-PA inhibitory antibody #387 was used (Fig. 1*h*). It is of note that the spotted lysis pattern proved to be correlated with strong t-PA immunostaining of the larger blood vessels with the t-PA antibody.

Immunolocalization of u-PA, PAI-1, and PAI-2. Characteristic examples of the immunolocalization of u-PA, PAI-1, and PAI-2 are shown in Fig. 2. Staining of melanocytic lesions with the two u-PA, the two PAI-1, and the two PAI-2 antibodies compared well with each other.

Visualization of t-PA and u-PA. In contrast with the strong vascular endothelial cell staining for t-PA in the larger blood vessels of normal mouse lung, melanocytic lesions in transgenic skin exhibited relatively little t-PA staining. Endothelial cell staining for t-PA was encountered only in one body-skin melanoma, in snout skin, and in one amelanotic snout-skin tumor. No other cell types or structures stained for t-PA. These immunohistochemical results were consistent with the t-PA activity results obtained with *in situ* zymography.

In the mixed and amelanotic tumors derived from body skin grafts, u-PA staining of blood vessels, especially of small capillaries (Fig. 2*a*), was striking. Of these, 9 of 13 showed staining of the capillary endothelium, 2 showed occasional granulocyte staining (Fig. 2*b*), and 5 showed some u-PA-positive fibroblastic cells. Melanoma cells were u-PA-positive only infrequently, although one tumor had areas with appreciable numbers of u-PA-stained melanoma cells. Capillary staining was observed in all four tumors arising in the vibrissa follicles of snout skin.

Visualization of PAI-1 and PAI-2. PAI-1 staining was observed in the extracellular matrix (Fig. 2*d*), vascular endothelial cells (data not shown), and fibroblastic cells (data not shown). In mixed and amelanotic body skin tumors, extracellular matrix staining was observed in 6 of 13 tumors, capillary staining was observed in 2 cases, and fibroblast cell staining in 5 cases. Endothelial cell staining also was found in one of the tumors obtained in snout skin. Except for epidermal staining in most lesions, no PAI-2 could be detected in the melanocytic lesions themselves, other than in the cells of one melanoma (Fig. 2*h*).

Plasminogen Activation near Ulcerated Skin. Staining for u-PA, PAI-1, and PAI-2 was striking in the thickened epidermis bordering ulcerations over the tumors. Examples of u-PA-positive keratinocytes (Fig. 2*f*) and the PAI-1-positive extracellular matrix (Fig. 2, *e* and *g*) within the same tumors are shown.

RT-PCR Analysis of t-PA, u-PA, and PAI-1 Transcription. Four mixed primary tumors (cases 159, 183, 31, and 222) furnished separate melanotic and amelanotic derivatives for RT-PCR analysis of

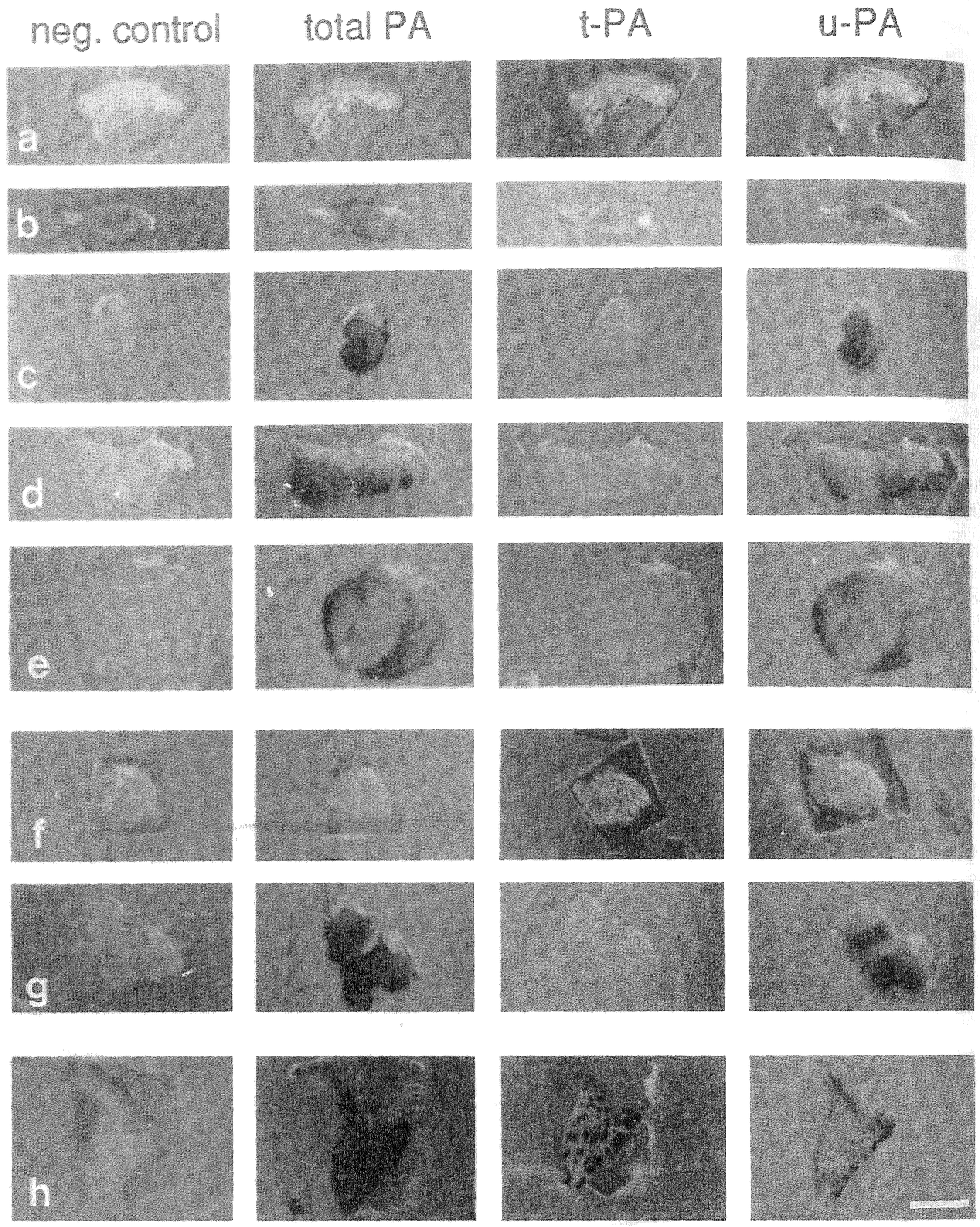

Fig. 1. *In situ* zymography comparing plasminogen activation in nevi and melanomas of transgenic mouse body skin (*a–e*) and snout skin (*f* and *g*) with normal mouse lung (*h*). The frozen, unfixed sections were photographed against a black background so that lysed areas appear dark. Plasminogen activation was absent or low in nevi (*a* and *f*) and was u-PA mediated in melanotic (*b*), mixed (*c*), and amelanotic (*d*, *e*, and *g*) melanomas; u-PA activity is in the amelanotic part of the mixed melanoma. The foci positive for t-PA activity in normal lung (*h*) correspond to areas with larger blood vessels. *Columns*, negative (*neg.*) control, with casein layer and no plasminogen; *total PA*, casein layer and added plasminogen; *t-PA*, casein, plasminogen, and amiloride; and *u-PA*, casein, plasminogen, and polyclonal antibody against human t-PA. *Magnification bar*, 0.25 cm. Incubation times at 37°C: 3 h (*a*, *c*, and *h*); 4.5 h (*f* and *g*); and 7.5 h (*b*, *d*, and *e*). Optimal lysis is shown. Nevi in *a* and *f* displayed no t-PA- or u-PA-mediated lysis even at 7.5 h of incubation.

t-PA and u-PA expression (Fig. 3). In three of the original tumors, the amelanotic zone was larger than the melanotic zone, and the reverse was true in one tumor (case 31). The results are based on the respective melanotic and amelanotic components after s.c. propagation in Tyr-SV40E hosts. u-PA expression was substantial in all tumors, except for low expression in one amelanotic derivative. t-PA expression was much more variable, but it was relatively higher in the amelanotic part from each tumor, with notably high expression in case 183.

In addition to the components from four mixed primary tumors in Fig. 3, seven other tumor samples were analyzed by RT-PCR for mRNAs of t-PA, u-PA, and/or PAI-1. These comprised four primary skin melanomas (case 7, in which the amelanotic zone predominated, and cases 24, 35, and 187, which appeared to be entirely amelanotic), as well as three metastases (an amelanotic lung metastasis from primary tumor 24, a melanotic lung metastasis from primary tumor 159, and a melanotic lymph node metastasis from primary tumor 159). All of these tumors were positive for the markers analyzed (data not shown). Only three displayed a notably strong hybridizing signal for t-PA under similar RT-PCR conditions. They were two of the three all amelanotic primary tumors (cases 35 and 187) and the amelanotic lung metastasis (from the skin tumor in case 24).

DISCUSSION

The PA system has been implicated in melanoma metastasis through experiments based on human or mouse melanoma cell lines and on models in which the cultured cells were introduced into mice (9–13, 27). Those studies were limited by genetic and other differences among melanoma cell lines and between long-established cell lines and primary melanomas. Established cell lines are, in fact, likely to be homogeneous with respect to production of certain proteins, whereas melanomas may be heterogeneous. For example, in human melanomas, only a minority of tumor cells, often at the periphery of the tumor, produce u-PA (14, 15). Moreover, different components of the PA system may vary quantitatively among melanocytic lesions, depending on their stages in tumor progression. Herein, we report the first *in vivo* investigation of the PA system in an animal model of melanoma.

The melanocytic lesions observed in this study arose in genetically

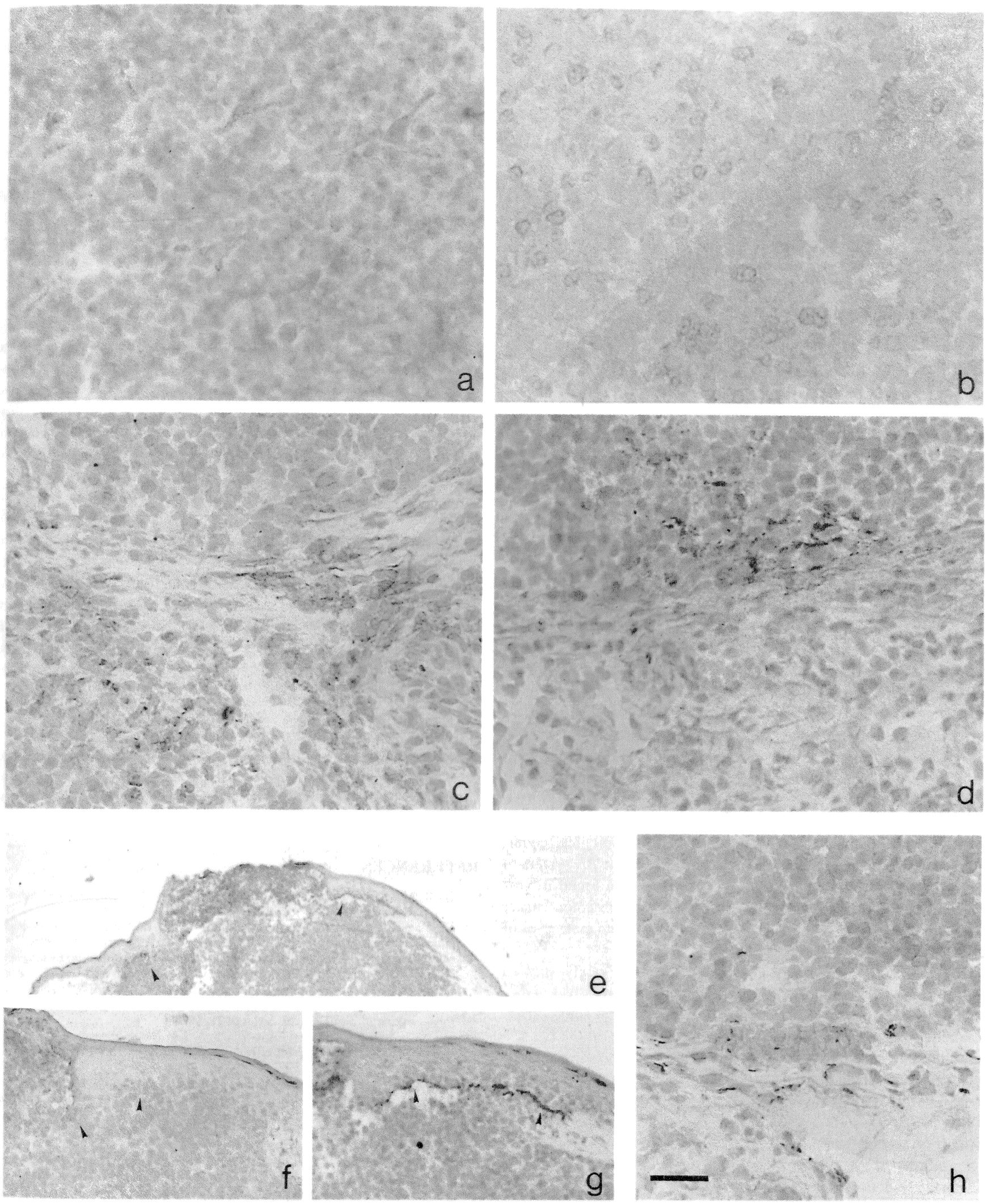

Fig. 2. Immunohistochemical visualization of the u-PA (*a–c* and *f*), PAI-*1* (*d, e,* and *g*), and PAI-2 (*h*) components of the PA system is demonstrated in stained frozen sections of mouse melanomas. u-PA was found in capillary sprouts in most melanomas (*a*), only occasionally in some melanoma cells and in granulocytes (the cells with lobulated nuclei; *b*), and in the stroma (*c*). PAI-1 was found in the extracellular matrix (*d*). PAI-2 was rarely present; an example in tumor cells is shown in *h*. In the ulcerated area of a melanoma (*e*) with a thickened epidermis (*arrowheads*) bordering the ulcer, there is enhanced staining for u-PA in the epidermis (*f*) and for PAI-1 (*e*, detail shown in *g*). Examples of u-PA staining in *a, b,* and *c* are from the same lesions as those shown in the zymography study (*e, c,* and *d*, respectively, in Fig. 1). *Magnification bar,* 13 μm (*a–d* and *h*), 26 μm (*f* and *g*), and 67 μm (*e*).

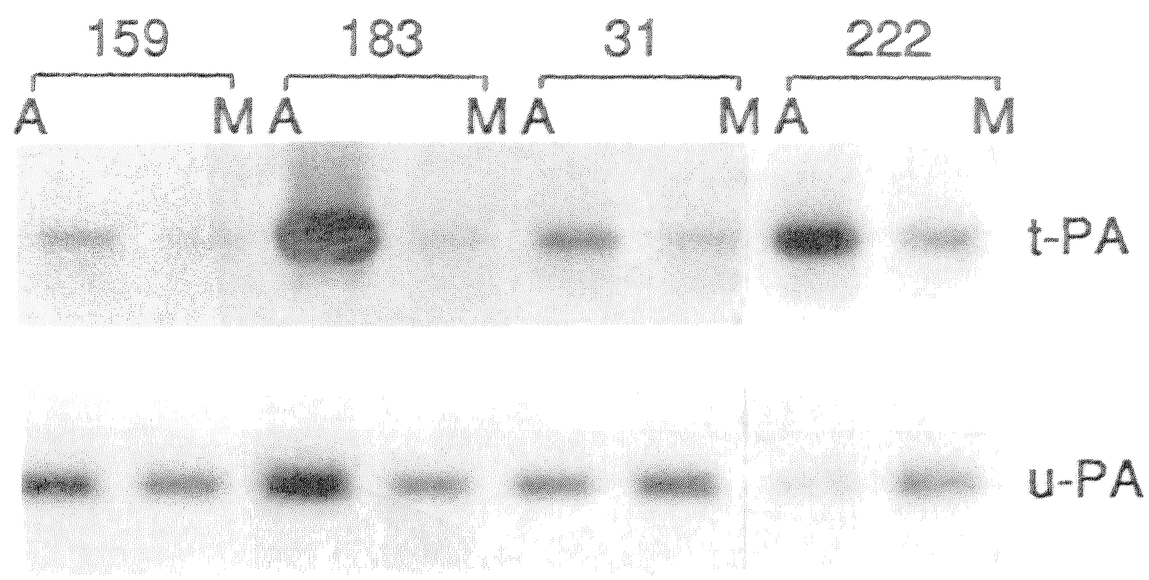

Fig. 3. Southern blots representing relative levels of expression of mouse t-PA and u-PA transcripts in mouse melanoma samples after RNA extraction, RT-PCR, and visualization of the cDNAs with specific radiolabeled hybridizing probes. GAPDH control levels were similar for all samples (data not shown). Each of the four numbered primary skin melanomas originally comprised a distinct amelanotic (*A*) and melanotic (*M*) zone. The *A* and *M* pairs shown here were obtained after s.c. propagation of the separated parts in transgenic hosts. Although t-PA was expressed at a higher level in the *A* than in the *M* component from each tumor, u-PA was expressed more consistently.

uniform transgenic mice (1, 4) and represent different stages in tumor development and progression (5). Intra- and inter-tumoral heterogeneity were found with respect to plasminogen activation. Within tumors, some regions exhibited earlier PA-mediated lysis than did others. The time of onset of lysis also differed greatly among tumors.

u-PA-mediated plasminogen activation predominated in the melanomas. With the methods used, it was undetectable in the premalignant lesions represented by nevi, and in normal or transgenic mouse skin. Similarly, u-PA activity has not been detected in human premalignant lesions (14, 15). By using adjacent sections of the transgenic mouse lesions for *in situ* zymography and immunohistochemistry, we could establish that u-PA activity was associated spatially with the presence of the protein.

Immunohistochemical localization of u-PA in the endothelium of sprouting capillaries in the large majority of mouse melanomas was particularly striking. PAI-1 also was present in capillaries, albeit less frequently. This localization of mouse u-PA and PAI-1 in growing capillaries suggests a role in angiogenesis. Indeed, in models relying on cell lines, u-PA (28, 29), its receptor (30), and PAI-1 (31) have been found to be expressed in angiogenesis. u-PA and PAI-1 also are believed to be involved in angiogenesis under physiological conditions (32). Little is known about the involvement of the PA system in tumor angiogenesis, although PAI-1 mRNA has been found in vascular endothelial cells at the tumor-stroma interface in colon cancer (33), and angiogenesis is thought to facilitate growth and metastasis of tumors in general (reviewed in Ref. 34).

Melanoma cells in the transgenic mouse tumors rarely showed u-PA activity, except for one tumor in which some areas had appreciable numbers of u-PA-positive cells. This may signal some difference between mouse and human melanomas, because, in the latter, a larger minority of the tumor cells produce u-PA. It is possible that the melanoma cells do not directly use u-PA for metastasis and depend on other proteases for this function. Experimentally gene-deficient mice lacking both u-PA and t-PA, or lacking PAI-1 are, in fact, capable of fibrinolysis and are healthy (17, 35).

In addition, u-PA and the PAIs were concurrently found at the thickened epidermal edges bordering sites of tumor ulceration, thereby implying a role in wound healing, as has been proposed for the PA system (19, 36–38).

In contrast to the u-PA results, t-PA was absent or low in the mouse melanocytic lesions, based on *in situ* zymography and immunohistochemistry. This finding was especially noteworthy in view of the abundant t-PA expression in melanoma cell lines and in human uveal melanoma (11, 14, 15, 39–41). In this study, t-PA protein and activity were detected by visual criteria only in the larger blood vessels of normal lung. It appears that t-PA is very low in the smaller caliber blood vessels of mouse tissues, but that it may be seen in small human vessels and benign tumor cells (14, 15).

The RT-PCR analyses allowed the PA study to be carried out on much larger tissue samples than is feasible with tissue sections. We also expanded the study by comparing melanotic and amelanotic components from primary melanomas and by comparing metastases with the skin melanoma of origin. Most of the skin melanomas chosen for RT-PCR had pronounced melanotic and amelanotic zones, and some had metastasized, whereas the mixed tumors fortuitously available when the *in situ* analyses were undertaken were largely amelanotic and had very small metastases. In agreement with the *in situ* visualization of PA proteins and activity, the RT-PCR results demonstrated that u-PA and PAI-1 mRNAs are more consistently expressed than is t-PA mRNA. Novel observations were the relatively greater expression of t-PA in the amelanotic than in the melanotic parts derived from mixed primary tumors, and the high t-PA expression in most all-amelanotic primary tumors and metastases. One possible explanation, based on preliminary observations of these tumors during dissection,[8] is that the amelanotic tumors or parts may more often contain large blood vessels, which could account for higher t-PA expression, as in normal lung.

Therefore, u-PA is the paramount PA in the *in vivo* mouse melanoma model, and its presence and activity increase with malignant progression. Because u-PA and, to a lesser extent, PAI-1 are localized predominantly in the endothelial cells of new vascular sprouts rather than in the melanoma cells, u-PA or both u-PA and PAI-1 might provide an experimental therapeutic target against neoangiogenesis in melanomas and indirectly against melanoma progression. One caveat is the low expression at early stages and the variable expression within and among melanomas.

ACKNOWLEDGMENTS

We thank John Rømer of the Finsen Laboratory, Copenhagen, Denmark; Robert Cohen of Genentech, San Francisco, CA; and David Teicher of American Diagnostica Inc., Greenwich, CT for generously supplying antibodies and mouse u-PA and t-PA standards.

REFERENCES

1. Bradl, M., Klein-Szanto, A., Porter, S., and Mintz, B. Malignant melanoma in transgenic mice. Proc. Natl. Acad. Sci. USA, *88:* 164–168, 1991.
2. Klein-Szanto, A., Bradl, M., Porter, S., and Mintz, B. Melanosis and associated tumors in transgenic mice. Proc. Natl. Acad. Sci. USA, *88:* 169–173, 1991.
3. Mintz, B., and Klein-Szanto, A. J. P. Malignancy of eye melanomas originating in the retinal pigment epithelium of transgenic mice after genetic ablation of choroidal melanocytes. Proc. Natl. Acad. Sci. USA, *89:* 11421–11425, 1992.
4. Mintz, B., and Silvers, W. K. Transgenic mouse model of malignant skin melanoma. Proc. Natl. Acad. Sci. USA *90:* 8817–8821, 1993.
5. Mintz, B., Silvers, W. K., and Klein-Szanto, A. J. P. Histopathogenesis of malignant skin melanoma induced in genetically susceptible transgenic mice. Proc. Natl. Acad. Sci. USA, *90:* 8822–8826, 1993.
6. Danø, K., Andreasen, P. A., Grøndahl-Hansen, J., Kristensen, P., Nielsen, L. S., and Skriver, L. Plasminogen activators, tissue degradation and cancer. Adv. Cancer Res., *44:* 139–266, 1985.
7. Duffy, M. J. The role of proteolytic enzymes in cancer invasion and metastasis. Clin. Exp. Metastasis, *10:* 145–155, 1992.
8. Pöllänen, J., Stephens, R. W., and Vaheri, A. Directed plasminogen activation at the surface of normal and malignant cells. Adv. Cancer Res., *50:* 273–328, 1991.
9. Hearing, V. J., Law, L. W., Corti, A., Appella, E., and Blasi, F. Modulation of metastatic potential by cell surface urokinase of murine melanoma cells. Cancer Res., *48:* 1270–1278, 1988.
10. Yu, H., and Schultz, R. M. Relationship between secreted urokinase plasminogen activator activity and metastatic potential in murine B16 cells transfected with human urokinase sense and antisense genes. Cancer Res., *50:* 7623–7633, 1990.

[8] J. L. Kitson and B. Mintz, unpublished data.

11. Quax, P. H. A., Van Muijen, G. N. P., Weening-Verhoeff, E. J. D., Lund, L. R., Danø, K., Ruiter, D. J., and Verheijen, J. H. Metastatic behaviour of human melanoma cell lines in nude mice correlates with urokinase-type plasminogen activator, its type-1 inhibitor and urokinase mediated matrix degradation. J. Cell. Biol., *115:* 191–199, 1991.
12. Stahl, A., and Mueller, B. Binding of urokinase to its receptor promotes migration and invasion of human melanoma cells *in vitro*. Cancer Res., *54:* 3066–3071, 1994.
13. Mueller, B. M., Yu, Y. B., and Laug, W. E. Overexpression of plasminogen activator inhibitor 2 in human melanoma cells inhibits spontaneous metastasis in *scid/scid* mice. Proc. Natl. Acad. Sci. USA, *92:* 205–209, 1995.
14. de Vries, T. J., Quax, P. H. A., Denijn, M., Verrijp, K. N., Verheijen, J. H., Verspaget, H. W., Weidle, U. H., Ruiter, D. J., and Van Muijen, G. N. P. Plasminogen activators, their inhibitors, and urokinase receptor emerge in late stages of melanocytic tumor progression. Am. J. Pathol., *144:* 70–81, 1994.
15. Delbaldo, C., Masouye, I., Saurat, J.-H., Vassalli, J.-D., and Sappino, A.-P. Plasminogen activation in melanocytic neoplasia. Cancer Res., *54:* 4547–4552, 1994.
16. Kristensen, P., Pyke, C., Andreasen, P. A., and Danø, K. Plasminogen activator inhibitor-type 1 in Lewis lung carcinoma. Histochemistry, *93:* 559–566, 1990.
17. Carmeliet, P., Schoonjans, L., Kieckens, L., Ream, B., Degen, J., Bronson, R., De Vos, R., van den Oord, J. J., Collen, D., and Mulligan, R. C. Physiological consequences of loss of plasminogen activator gene function in mice. Nature (Lond.), *368:* 419–424, 1994.
18. Larsson, L. I., Skriver, L., Nielsen, L. S., Grøndahl-Hansen, J., Kristensen, P., and Danø, K. Distribution of urokinase-type plasminogen activator immunoreactivity in the mouse. J. Cell Biol., *98:* 894–903, 1984.
19. Rømer, J., Lund, L. R., Eriksen, J., Ralfkiaer, E., Zeheb, R., Gelehrter, T. D., Danø, K., and Kristensen, P. Differential expression of urokinase-type plasminogen activator and its type-1 inhibitor during healing of mouse skin wounds. J. Invest. Dermatol., *97:* 803–811, 1991.
20. Wohlwend, A., Belin, D., and Vassalli, J.-D. Plasminogen activator-specific inhibitors in mouse macrophages: *in vivo* and *in vitro* modulation of their synthesis and secretion. J. Immunol., *139:* 1278–1284, 1987.
21. Kristensen, P., Eriksen, J., Blasi, F., and Danø, K. Two alternatively spliced mouse urokinase receptor mRNAs with different histological localization in the gastrointestinal tract. J. Cell Biol., *115:* 1763–1771, 1991.
22. Lipson, K. E., and Baserga, R. Transcriptional activity of the human thymidine kinase gene determined by a method using the polymerase chain reaction and an intron-specific probe. Proc. Natl. Acad. Sci. USA, *86:* 9774–9777, 1989.
23. Rickles, R. J., Darrow, A. L., and Strickland, S. Molecular cloning of complementary DNA to mouse tissue plasminogen activator mRNA and its expression during F9 teratocarcinoma cell differentiation. J. Biol. Chem., *263:* 1563–1569, 1988.
24. Friezner Degen, S. J., Heckel, J. L., Reich, E., and Degen, J. L. The murine urokinase-type plasminogen activator gene. Biochemistry, *26:* 8270–8279, 1987.
25. Prendergast, G. C., Diamond, L. E., Dahl, D., and Cole, M. D. The c-*myc*-regulated gene *mrl* encodes plasminogen activator inhibitor 1. Mol. Cell. Biol., *10:* 1265–1269, 1990.
26. Tso, J. Y., Sun, X-H., Kao, T-H., Reece, K. S., and Wu, R. Isolation and characterization of rat and human glyceraldehyde-3-phosphate dehydrogenase cDNAs: genomic complexity and molecular evolution of the gene. Nucleic Acids Res., *13:* 2485–2502, 1985.
27. Meissauer, A., Kramer, M. D., Hofmann, M., Likell, L. J., Jacob, E., Schirrmacher, V., and Brunner, G. Urokinase-type and tissue-type plasminogen activators are essential for *in vitro* invasion of human melanoma cells. Exp. Cell Res., *192:* 453–459, 1991.
28. Pepper, M. S., Vassalli, J-D., Montesano, R., and Orci, L. Urokinase-type plasminogen activator is induced in migrating capillary endothelial cells. J. Cell Biol., *105:* 2535–2541, 1987.
29. Yasunaga, C., Nakashima, Y., and Sueishi, K. A role of fibrinolytic activity in angiogenesis. Lab. Invest., *61:* 698–704, 1989.
30. Pepper, M. S., Sappino, A-P., Stöcklin, R., Montesano, R., Orci, L., and Vassalli, J-D. Upregulation of urokinase receptor expression on migrating endothelial cells. J. Cell. Biol., *122:* 673–684, 1993.
31. Pepper, M. S., Sappino, A-P., Montesano, R., Orci, L., and Vassalli, J-D. Plasminogen activator inhibitor-1 is induced in migrating endothelial cells. J. Cell. Physiol., *153:* 129–139, 1992.
32. Bacharach, E., Itin, A., and Keshet, E. *In vivo* patterns of urokinase and its inhibitor PAI-1 suggest a concerted role in regulating physiological angiogenesis. Proc. Natl. Acad. Sci. USA, *89:* 10686–10690, 1992.
33. Pyke, C., Kristensen, P., Ralfkiaer, E., Eriksen, J., and Danø, K. The plasminogen activation system in human colon cancer: messenger RNA for the inhibitor PAI-1 is located in endothelial cells in the tumor stroma. Cancer Res., *51:* 4067–4071, 1991.
34. Folkman, J. Tumor angiogenesis. *In:* J. Mendelsohn, P. M. Howley, M. A. Israel, and L. A. Liotta (eds.), The Molecular Basis of Cancer, pp. 206–232. Philadelphia: W. B. Saunders, 1995.
35. Carmeliet, P., Stassen, J. M., Schoonjans, L., Ream, B., van den Oord, J. J., De Mol, M., Mulligan, R. C., and Collen, D. Plasminogen activator inhibitor-1 gene-deficient mice. II. Effects on hemostasis, thrombosis, and thrombolysis. J. Clin. Invest., *92:* 2756–2760, 1993.
36. Grøndahl-Hansen, J., Lund, L. R., Ralfkiaer, E., Ottevanger, V., and Danø, K. Urokinase- and tissue-type plasminogen activators in keratinocytes during wound reepithelialization *in vivo*. J. Invest. Dermatol., *90:* 790–795, 1988.
37. Rømer, J., Lund, L. R., Eriksen, J., Pyke, C., and Danø, K. The receptor for urokinase-type plasminogen activator is expressed by keratinocytes at the leading edge during reepithelialization of mouse skin wounds. J. Invest. Dermatol., *102:* 519–522, 1994.
38. Schäfer, B. M., Maier, K., Eickhoff, U., Todd, R. F., and Kramer, M. D. Plasminogen activation in healing human wounds. Am. J. Pathol., *144:* 1269–1280, 1994.
39. Kwaan, H. C., Radosevich, J. A., Zu, C. G., and Lastre, C. Tissue plasminogen activator and inhibitors of fibrinolysis in malignant melanoma. Tumor Biol., *9:* 301–306, 1988.
40. Cottam, D. W., Rees, R. C., Parsons, M. A., Benson, M. T., and Rennie, I. G. Degradative enzyme expression in uveal melanoma. Invest. Ophthalmol. Vis. Sci., *33:* 979, 1992.
41. de Vries, T. J., Mooy, C. M., Van Balken, M. R., Luyten, G. P. M., Quax, P. H. A., Verspaget, H. W., Weidle, U. H., Ruiter, D. J., and Van Muijen, G. N. P. Components of the plasminogen activation system in uveal melanoma: a clinico-pathological study. J. Pathol., *175:* 59–67, 1995.