

PDF hosted at the Radboud Repository of the Radboud University Nijmegen

The following full text is a publisher's version.

For additional information about this publication click this link.

<http://hdl.handle.net/2066/21933>

Please be advised that this information was generated on 2017-12-05 and may be subject to change.

Y. L. Ie
E. H. Verdonschot
M. J. M. Schaecken
M. A. van't Hof

Department of Cariology and
Endodontology, Trikon: Institute for Dental
Clinical Research, University of Nijmegen,
The Netherlands

Electrical Conductance of Fissure Enamel in Recently Erupted Molar Teeth as Related to Caries Status

Key Words

Electrical conductance
Enamel maturation
Occlusal caries, diagnosis

Abstract

Pit-and-fissure caries lesions contribute greatly to the caries incidence in permanent molar teeth in children. To date, the diagnosis of occlusal caries is still performed mainly by visual inspection, periodically aided by bite-wing radiography. However, in detecting small occlusal carious lesions, these methods perform inadequately, especially in low caries prevalence populations or individuals. The use of electrical conductance measurements (ECMs) has been evaluated to improve the diagnosis of small occlusal carious lesions. The aim of this study was to monitor the electrical conductance of fissure enamel in recently erupted molar teeth and to relate these measurements to the caries status. 50 children aged 5-15 years, having first or second permanent molars that were not exposed to the oral environment for more than 6 months, participated in the study. The diagnostic systems evaluated were visual inspection and ECMs. Following baseline data recording, diagnostic measurements were repeated three times within 18 months. Data were collected at predefined sites in the fissures. 18 months after baseline recording, 179 sites at 60 molar teeth in 27 children were judged to require a sealant based on visual inspection. After removal of carious tissue, two examiners jointly decided on the status of decay as per the criteria: 0=no caries or caries limited to enamel, and 1=caries involving dentine. The sensitivity of ECM continued to increase with time after a slight initial dip, whereas the specificity continuously increased after baseline measurements as a result of the decreasing amount of false-positive diagnoses. ECMs obtained after each 6-month interval from sites that developed caries were significantly higher than those from sites that remained caries free (all $p < 0.02$). Furthermore, ECMs obtained from sites that exhibited dentinal caries upon validation were significantly higher than those obtained from sites that showed no caries or caries limited to enamel on validation ($p < 0.001$). The areas under the receiver operating characteristic curves of visual inspection and ECMs were 0.67 and 0.77, respectively, a difference that was not statistically significant ($p > 0.05$). It was concluded from this study that ECMs can aid the detection of fissure caries in recently erupted molar teeth. The results imply that an ECM value of 6.5 can be considered as the cut-off between no caries or caries limited to enamel and dentinal caries. Furthermore, ECMs can be used to predict the probability that a sealant or a sealant restoration will be required within 18-24 months after eruption.

Received:
March 2, 1994
Accepted after revision:
September 5, 1994

Ying L. Ie, DMD
Department of Cariology and Endodontology/117
Trikon, Faculty of Medical Sciences
University of Nijmegen, PO Box 9101
NL-6500 HB Nijmegen (The Netherlands)

© 1995 S. Karger AG, Basel
0008-6568/95/0292-0094
\$8.00/0

The pits and fissures in permanent molars of children have frequently been identified as caries predilection sites [Ripa et al., 1988; Wenzel et al., 1993]. At age 15, the average DMFS score for occlusal surfaces in Western communities has been reported to be 4.3 in contrast to 2.9 for proximal surfaces [Kalsbeek et al., 1993]. The caries susceptibility of pits and fissures has been attributed to plaque retention at these sites and to the incomplete closure of the fissure enamel. Part of the caries vulnerability at a young age has also been attributed to the low degree of enamel maturation during the first years following eruption [Crabb, 1976; Fejerskov et al., 1984; Driessens et al., 1985].

The diagnosis of occlusal carious lesions is still performed mainly by visual inspection, periodically aided by bite-wing radiography [Angmar-Månsson and ten Bosch, 1993]. Radiographic diagnosis has been shown to be accurate, particularly when focused on large dentinal lesions [Weerheijm et al., 1989, 1992; Creanor et al., 1990; Wenzel et al., 1990, 1991; Pitts and Kidd, 1992]. Other studies concluded that visual inspection performed poorly in the detection of small occlusal carious lesions [Verdonschot et al., 1992; Wenzel and Fejerskov, 1992]. The value of electrical conductance measurements (ECMs) in caries diagnosis was described first by Pincus [1951]. Later, this method was the subject of many *in vitro* [White et al., 1978; Flaitz et al., 1986; Verdonschot et al., 1993b] and *in vivo* [White et al., 1978; 1981a, b; Williams et al., 1978; Rock and Kidd, 1988; Verdonschot et al., 1992], studies. The reported sensitivities of ECMs in diagnosing dentinal carious lesions at occlusal surfaces of permanent premolar and molar teeth ranged from 0.67 to 0.96, whereas the specificities ranged from 0.71 to 0.98, reflecting an acceptable performance. A recent meta-analysis comparing the performance of various diagnostic systems in occlusal caries diagnosis showed that ECMs were superior to visual inspection, fibre-optic transillumination (FOTI), and radiography [Ie and Verdonschot, 1994]. However, the material used in reports on *in vitro* studies consisted of extracted teeth of unknown history, whereas *in vivo* studies used almost exclusively premolar and third molar teeth which had been scheduled for extraction. It is estimated that many teeth which had been extracted for orthodontic reasons, as well as third molars, had comparatively poorly matured enamel. Since the pore volume of immature enamel is an important variable in the measurement of its electrical conductance, the degree of posteruptive maturation quantified by the time elapsed after eruption might have influenced the results of some of the above-mentioned studies, as the measurement of high electrical conductance has been associated with both a high pore volume [Huysmans et al., 1995] and dentinal caries [Flaitz et al., 1986].

Hence, it was the aim of this study, to monitor the electrical conductance of fissure enamel of recently erupted molar teeth and to relate these measurements to caries status.

Materials and Methods

From the Department of Paediatric Dentistry, 50 children aged 5–15 years were recruited by pedodontists during recall visits. Criteria for inclusion in the study were that the first permanent molar teeth in 5- to 6-year-old and the second permanent molar teeth in 11- to 15-year-old participants had not been exposed to the oral environment for more than 6 months. The children received regular preventive care at 6-month intervals. Immediately prior to the first diagnostic measurements, an impression was made from the occlusal surfaces of the selected teeth and the impression poured in stone. Baseline diagnostic measurements were subsequently conducted at three or four predefined sites in maxillary molars (distal, central, and mesial fossae and in the middle of the palatal fissure, if present) and at three sites in the fissures of mandibular molar teeth (distal, central, and mesial fossae). The sites were marked on the stone replicas of the teeth for standardization. In some cases, diagnostic measurements in the palatal fissure and in the distal fossa could not be performed due to incomplete eruption or presence of an operculum.

Each site was examined by visual inspection, and subsequently the electrical conductance at this site was measured. The findings upon visual inspection were recorded using an ordinal rating scale: 0 = sound enamel; 1 = carious lesion restricted to enamel; 2 = carious lesion reaching the dentino-enamel junction; 3 = carious lesion in dentine. ECMs were conducted using a Vanguard (Massachusetts Manufacturing Company, Cambridge, Mass., USA) as described by Verdonschot et al. [1992]. The electrical conductance of enamel measured at the probe tip (fig. 1) is converted automatically into ordinal integer ratings ranging from 0 (indicating sound enamel) to 9 (indicating a dentinal lesion). Because the Vanguard was taken out of production by its manufacturer and to secure the continuity of this follow-up study, it was replaced by an Electronic Caries Monitor (Borsboom Sensortechnology, Westeremden, The Netherlands) at the time that the measurements 12 months after baseline had yet to be conducted. The Electronic Caries Monitor was built such that it converted the measured electrical conductance into ordinal ratings in exactly the same manner as did the Vanguard (ECM manual; $r = 1.00$), albeit its rating scale was continuous and extended to range from about -1.00 to 13.00 . The logarithm of the unit of electrical resistance (R ; $M\Omega$) is a third power function of ECM readings [Huysmans et al., 1995]:

$$\log(R) = -0.002196 \text{ ECM}^3 + 0.042114 \text{ ECM}^2 - 0.37869 \text{ ECM} + 4.5341$$

For the purpose of this study, all negative ratings from the Electronic Caries Monitor were set to Vanguard rating 0, whereas ratings 9.00–13.00 were set to 9. All Electronic Caries Monitor ratings between 0.00 and 9.00 were then rounded to the nearest integer. Following baseline data recording, the diagnostic measurements were repeated three times at 6-month intervals. Both visual inspection and ECMs were conducted by the same observer. A random 10% of all measurements was also carried out independently by a second observer to evaluate interobserver reliability.

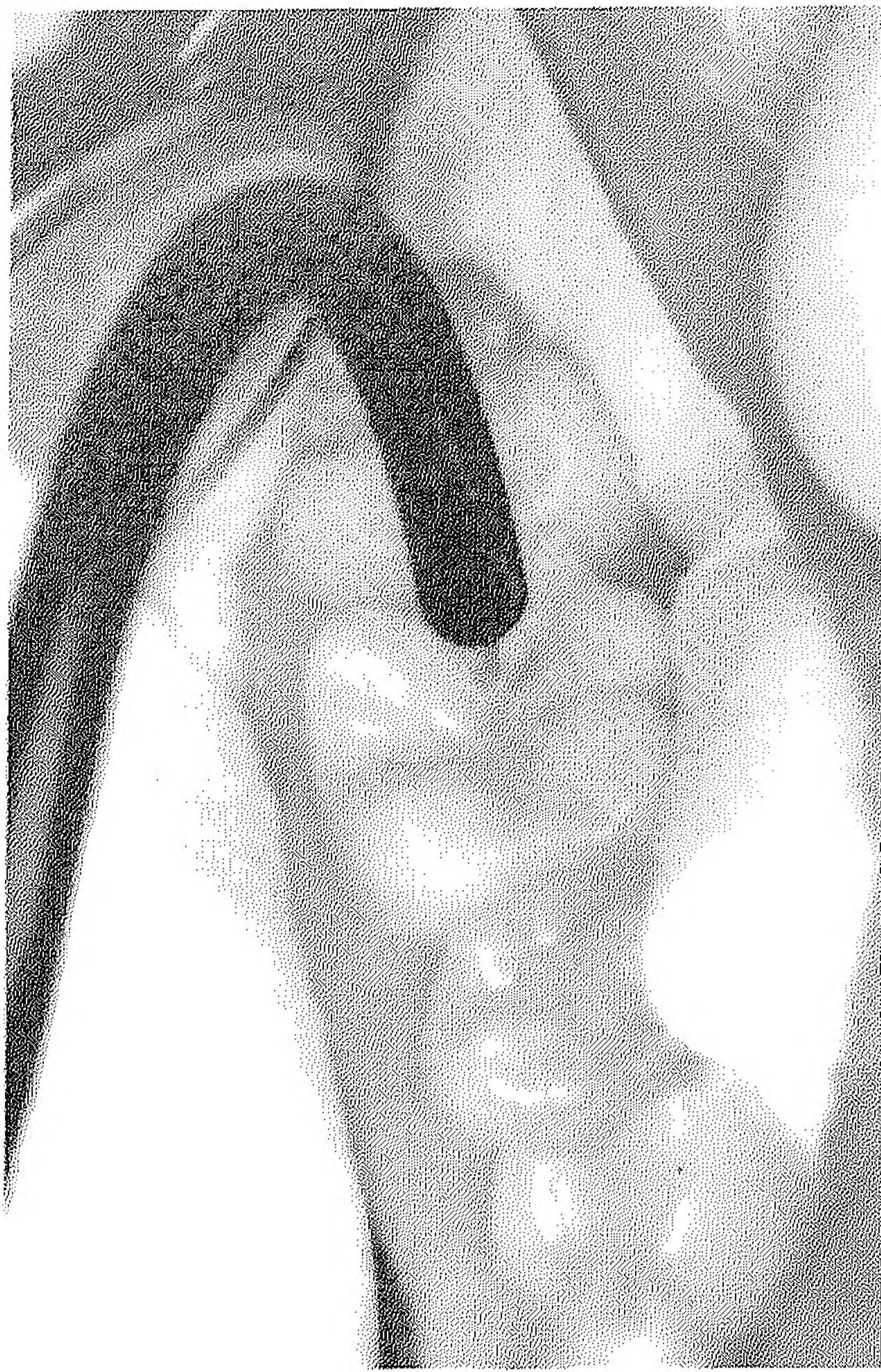

Fig. 1. ECM at a predefined site in the fissure of a molar tooth.

Following visual diagnosis by two examiners, teeth with occlusal surfaces which exhibited signs of caries at the beginning of the study, and during recall visits, to such an extent that a sealant or sealant restoration was required were included in the validation procedure, but then excluded from further assessment. Thus, visual validation of sites that remained caries free throughout the study was not conducted. To evaluate the caries status at the affected surfaces and sites, carious tissues and discolourations were removed with a small cone-shaped diamond bur. This bur was also used to make the base of irregular and deep fissures accessible to visual inspection. Thereafter, two examiners decided jointly on the decay status at each of the three or four sites as per the criteria: 0 = no caries or caries limited to enamel and 1 = caries involving dentine. These ratings served as 'gold standard' diagnoses.

To study the influence of developing carious lesions on the electrical conductance of fissure enamel, the averaged ECMs from sites that showed no caries or caries limited to enamel and from sites that showed caries involving dentine after validation were plotted as a function of time. The mean ECMs from sites that remained caries free throughout the study (as judged by visual inspection) were also plotted in this graph. Paired *t*-tests and Mann-Whitney U tests were conducted to test the differences between ECMs.

Kappa statistics were calculated to evaluate interobserver reliability [Fleiss et al., 1979]. To calculate sensitivities and specificities, all diagnostic measurements were dichotomized with the cut-off between 1 and 2 for visual inspection and between ratings 8 and 9 for the ECMs. The sensitivity of a diagnostic test is the number of true-positive test results relative to the total number of actually positive cases, i.e., all sites at which dentinal caries was found upon validation. Specificity reflects the proportion of true-negative test outcomes and the total number of actually negative cases.

Receiver operating characteristic (ROC) analysis was applied to evaluate the sensitivity relative to the specificity. The area under a

Table 1. Sensitivity and specificity values of ECMs and visual inspection of the locations validated at baseline and after 6, 12, and 18 months

	Time after baseline, months				Total (n = 179)
	0 (n = 30)	6 (n = 90)	12 (n = 47)	18 (n = 12)	
<i>ECMs</i>					
Sensitivity	0.86	0.68	0.86	1.00	0.77
Specificity	0.43	0.65	0.77	0.50	0.62
<i>Visual inspection</i>					
Sensitivity	0	0.05	0.05	0	0.04
Specificity	0.91	1.00	0.96	1.00	0.97

ROC curve, denoted A_z , represents observer performance in using a diagnostic system. Differences between the A_z -values of visual inspection and ECMs were tested for statistical significance using a Z-score test at $\alpha = 0.05$ [Hanley and McNeil, 1983].

Results

Baseline recordings were made in 23 children aged 5–6 and in 27 children aged 11–15 years. During the course of the study, 2 children moved to other cities and, therefore, cancelled their participation. Within 18 months after baseline, 74 sites of 24 first permanent molars in 11 5- to 6-year-old children and 105 sites of 36 second permanent molars in 16 11- to 15-year-old children were judged to require treatment. Thus, a total of 179 sites of 60 molar teeth in 27 children had received a sealant or a sealant restoration at the end of the study. The numbers of sealed and restored sites at baseline and 6, 12, and 18 months after baseline measurements were 30, 90, 47, and 12, respectively (table 1). The total FS score occlusal surfaces at the end of the study was 36 for first and 43 for second molar teeth. The incidence of occlusal caries in the study population was 1.46 occlusal surface per child per year. Kappa statistics for interexaminer reliability were 0.57 for visual inspection and 0.76 for ECMs, indicating moderate and acceptable reproducibility, respectively.

The distribution of ECMs obtained immediately prior to validation is shown in figure 2. Rating 9 accounted for approximately 50% of all measurements. Consequently, the selected cut-off between 'no caries or caries limited to enamel' and 'dentinal caries' implied that about 50% of the sites received a positive ECM test outcome, of which 60% (54 sites) actually showed dentinal caries upon validation.

The data in figure 3 depict the mean ECM values against time of sites that showed no caries or caries limited to enam-

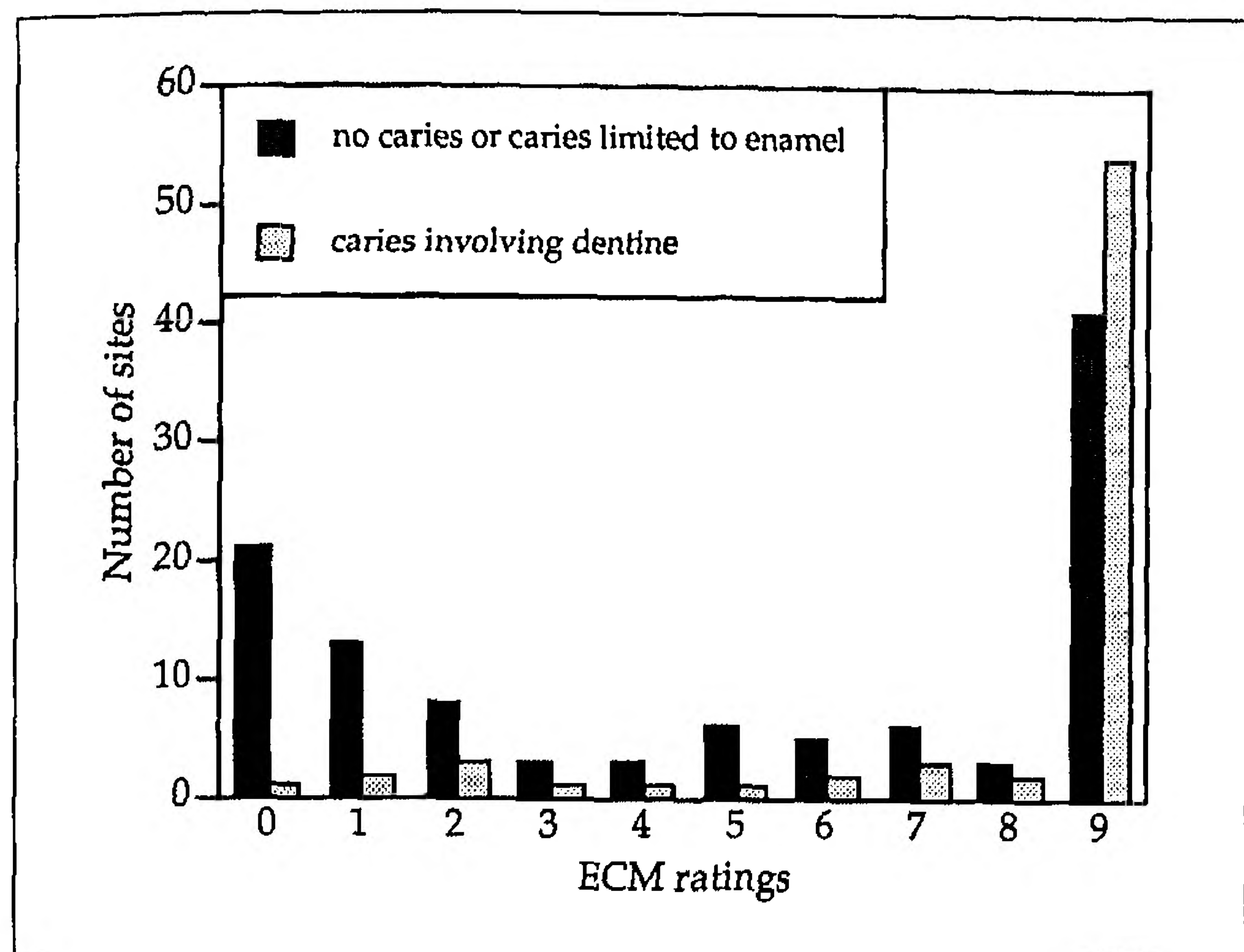


Fig. 2. Histogram of ECMs obtained immediately prior to validation ($n = 179$).

el and dentinal caries upon validation at baseline and after 6, 12, and 18 months and of the sites that remained caries free throughout the study as judged by visual inspection. The mean ECM value from the caries-free sites obtained at baseline was significantly higher than those obtained 6, 12, and 18 months after baseline (paired t -test; $p < 0.05$). ECMs obtained after each 6-month interval from sites that developed caries were significantly higher than those from sites which remained caries free (Mann-Whitney U tests; all $p < 0.02$). Also, ECMs obtained from sites that exhibited dentinal caries upon validation were significantly higher than those obtained from sites that showed no caries or caries limited to enamel upon validation (Mann-Whitney U test; $p < 0.001$). Sensitivity and specificity of ECMs in predicting the need for a sealant or sealant restoration 18 months after baseline were 0.75 and 0.63, respectively.

The sensitivities and specificities of visual inspection and ECMs performed at the 179 sites which were validated are presented in table 1. There is a tendency for the sensitivities and specificities of ECMs to increase during the course of the observation period, whereas those of visual inspection remained almost constant. The sensitivity of the pooled measurements for visual inspection was low (0.04), whereas the specificity was high (0.97). The ECMs were characterized by moderate sensitivity (0.77) and specificity (0.62). The areas under the ROC curves (pooled data from one observer) of visual inspection and ECMs were 0.66 and 0.76, respectively (fig. 4). The difference between both areas was not statistically significant (Z -score test; $p = 0.08$).

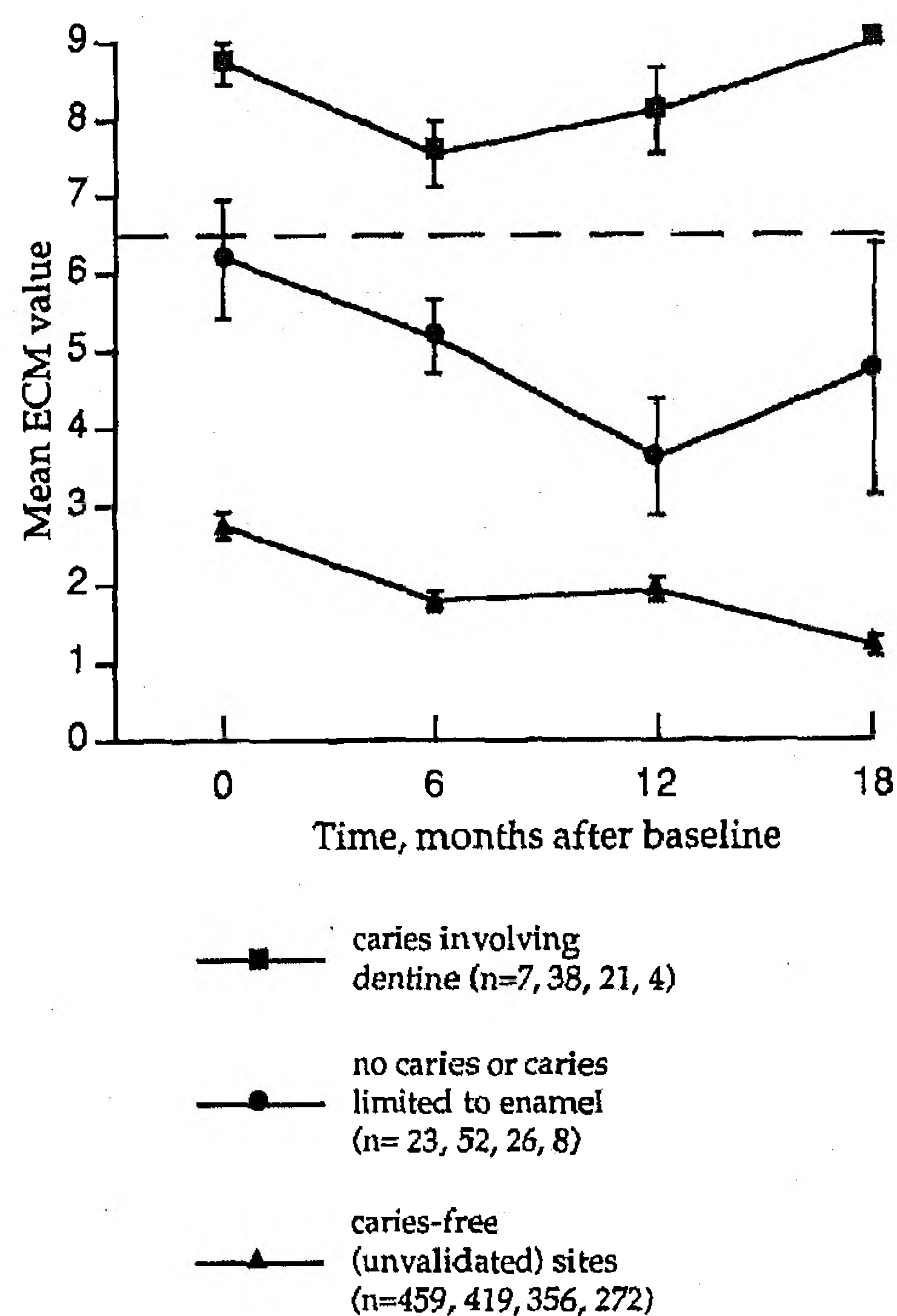


Fig. 3. Mean ECMs (\pm SEM) from validated sites at baseline and 6, 12, and 18 months after baseline and from sites that remained caries free throughout the study as judged by visual inspection.

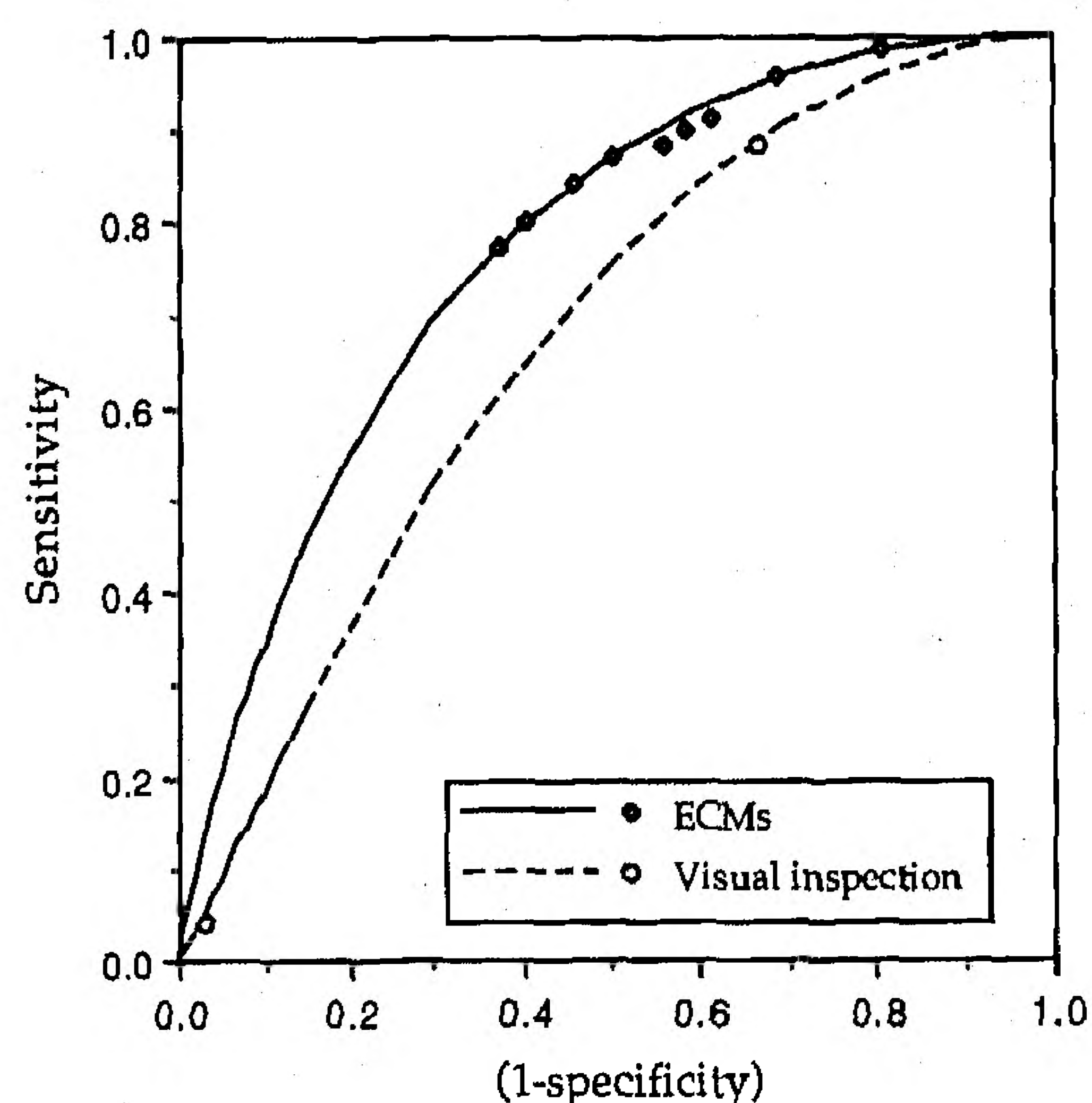


Fig. 4. ROC graphs depicting the performance of ECMs and visual inspection in occlusal caries diagnosis. The landmarks indicate the observed operating points. (For visual inspection rating 3 had not been recorded which resulted in two operating points for this diagnostic system.)

Discussion

Because of the high resistivity of human enamel, the electrical conductance becomes measurable only when the enamel is either very thin or when a connection exists between the probe tip and the electrolyte-containing dentine. In this study in which ECMs were used as a caries-diagnostic system, high and true-positive measurements were associated with the presence of dentinal caries. High, but false-positive test outcomes could originate from fissure enamel defects, a high pore volume due to low enamel maturation, or from an incorrectly performed measurement during which electrons 'escape' from the probe tip through a superficial layer of moisture to the contra-electrode which is held by the patient. Immediately after eruption, the escape of electrons is facilitated by the small distance between the probe tip and the gingiva or the operculum. As these situations were seen quite often at baseline, it is estimated that the false positives were, in part, caused by this phenomenon.

The results of this study indicate that about 50% of the ECM diagnoses which were conducted immediately prior to validation were positive (fig. 2), of which 60% actually showed dentinal caries upon validation (true positives). Thus ECMs, when used as a caries-diagnostic tool, still produced a considerable number of false-positive results. Since the majority of data from validated sites were obtained 6–12 months after eruption, most of the validated teeth were measured when fully erupted. As the numbers of false positives caused by incomplete eruption should have decreased after baseline measurements, the observed false-positive rate of 40% cannot be explained fully by incomplete eruption. At least part of this percentage should be attributed to the presence of porosities in enamel. Several studies have demonstrated that the outer enamel layer is highly porous at the time of eruption [Crabb, 1976; Fejerskov et al., 1984; Driessens et al., 1985; Deutsch and Shapira, 1987]. Low matured, highly porous enamel of recently erupted molar teeth will, therefore, increase the probability of false-positive test outcomes when using ECMs for caries diagnosis.

Data in figure 3 illustrate that the averaged electrical conductance of sound fissure enamel from sites that remained caries free (as judged by visual inspection) throughout the evaluation period decreased with time. The mean ECM value from these sites obtained at baseline was significantly higher than those obtained 6, 12, and 18 months after baseline. Hoppenbrouwers et al. [1986] found that the resistivity of erupted premolar enamel was considerably higher than that of unerupted premolar enamel. White et al. [1981a] observed an increased electrical resistance of demineralized

enamel after surface treatment with fluoride, suggesting that an increase of mineralization was associated with a decrease in electrical conductance. Both studies, therefore, support the hypothesis that enamel mineralization and electrical conductance are inversely related. This finding is confirmed by the results from this study, as the number of false-positive ECMs decreased during the successive measurements which is reflected by increasing specificities.

In figure 3 a cut-off can be placed at a mean ECM value of 6.5 to distinguish ECMs from sites that developed no caries (or caries limited to enamel) from those that developed dentinal caries during the course of 18 months. Thus, sites which had an ECM value of 6.5 or higher, measured within 6 months after eruption, had an increased probability of developing dentinal caries. This cut-off for dentinal caries is in accordance with the findings of Flaitz et al. [1986] who reported a mean ECM reading of 6 ± 0.5 for the group of molars which showed dentinal caries upon histological validation. A sensitivity of 0.75 and a specificity of 0.63 indicate that ECMs can be used to predict the need for a sealant or sealant restoration within 18 months after baseline.

To explain further the high false-positive ECM rate in this study, it is hypothesized that defective fissure enamel may play a role. Enamel defects could form a connection between the dentine and the oral environment, through which electrons can pass easily when electrical conductance is being measured. Such defects may develop during enamel formation and consist of a chain of large pores in a comparatively thin layer of fissure enamel. Although enamel defects will generate false-positive test results when the sites are validated for caries, they are in fact true positives when the ECMs are used to detect enamel 'leakages'. Assuming that enamel fissure defects can be colonized by cariogenic microorganisms, dentinal caries may result without the adjacent enamel being involved. The onset of 'hidden occlusal caries' [Weerheijm et al., 1989; Verdonschot et al., 1992] could hence be predicted, in part, by ECMs. As this clinical study continues, measurements made 5–10 years after baseline will produce further data to investigate this hypothesis in more detail. At baseline, 30 sites were judged to require a sealant. All lesions which had actually reached dentine were judged to have caries restricted to the enamel by visual inspection. This finding supports further the 'hidden-caries' theory, according to which carious lesions develop and progress while obscured by visually intact enamel.

In figure 4 a larger area under the ROC curve for ECMs ($A_z = 0.76$) than for visual inspection ($A_z = 0.66$) is shown, although this difference was not statistically significant. The study of Verdonschot et al. [1993a] yielded an area of

0.82 for ECMs and of 0.76 for visual inspection. The difference between the areas was also not statistically significant. The investigators used extracted third molar teeth without visible cavitation from 18- to 20-year-old adolescents. Thus, ECMs were conducted on molar teeth which had probably been erupted for only a short period. Consequently, immature enamel might have influenced the results as in the present study. This explanation is consistent with the results of another study by the same group [Verdonschot et al., 1993b]. Here, teeth which had not erupted recently were

used, and it was reported that a much larger area for ECMs ($A_z = 0.94$) was found than in the other two studies.

It is concluded from this study that ECMs can aid the detection of fissure caries in recently erupted molar teeth. The results imply that an ECM value of 6.5 can be considered as the cut-off between no caries (or caries restricted to enamel) and dentinal caries. Furthermore, ECMs can be used to predict the probability that a sealant or a sealant restoration will be required within 18–24 months after eruption.

References

- Angmar-Månsson B, ten Bosch JJ: Advances in methods for diagnosing coronal caries: A review. *Adv Dent Res* 1993;7:70–79.
- Crabb HSM: The porous outer enamel of unerupted human premolars. *Caries Res* 1976;10:1–7.
- Creanor SL, Russell JI, Strang DM, Stephen KW, Burchell CK: The prevalence of clinically undetected occlusal dentine caries in Scottish adolescents. *Br Dent J* 1990;169:126–129.
- Deutsch D, Shapira L: Changes in mineral distribution and concentration during enamel development in the deciduous human maxillary and mandibular teeth. *Growth* 1987;51:334–341.
- Driessens FCM, Heijligers HJM, Borggreven JMPM, Wöltgens JHM: Posteruptive maturation of tooth enamel studied with the electron microprobe. *Caries Res* 1985;19:390–395.
- Fejerskov O, Josephsen K, Nyvad B: Surface ultrastructure of unerupted mature human enamel. *Caries Res* 1984;18:302–314.
- Flaitz CM, Hicks MJ, Silverstone LM: Radiographic, histologic, and electronic comparison of occlusal caries: An in vitro study. *Pediatr Dent* 1986;8:24–28.
- Fleiss JL, Fischman SL, Chilton NW, Park MH: Reliability of discrete measurements in caries trials. *Caries Res* 1979;13:23–31.
- Hanley JA, McNeil BJ: A method of comparing the areas under receiver operating characteristic curves derived from the same cases. *Radiology* 1983;148:839–843.
- Hoppenbrouwers PMM, Scholberg HPF, Borggreven JMPM: Measurement of the permeability of dental enamel and its variation with depth using an electrochemical method. *J Dent Res* 1986;65:154–157.
- Huysmans MCDNJM, Verdonschot EH, Rondel P: Electrical conductance and electrode area on sound smooth enamel in extracted teeth. *Caries Res* 1995;29:88–93.
- Ie YL, Verdonschot EH: Performance of diagnostic systems in occlusal caries detection compared. *Community Dent Oral Epidemiol* 1994;22:187–191.
- Kalsbeek H, Kwant GW, Groeneveld A, Backer Dirks O, van Eck AAJM, Theuns HM: Caries experience of 15-year-old children in The Netherlands after discontinuation of water fluoridation. *Caries Res* 1993;27:201–205.
- Pincus P: A new method of examination of molar tooth grooves for the presence of dental caries. *J Physiol (Lond)* 1951;113:13–14.
- Pitts NB, Kidd EAM: Some factors to be considered in the prescription and timing of bitewing radiography in the diagnosis and management of dental caries. *J Dent* 1992;20:74–84.
- Ripa LW, Leske GS, Varma AO: Longitudinal study of the caries susceptibility of occlusal and proximal surfaces of first permanent molars. *J Public Health Dent* 1988;48:8–13.
- Rock WP, Kidd EAM: The electronic detection of demineralisation in occlusal fissures. *Br Dent J* 1988;164:243–247.
- Verdonschot EH, Bronkhorst EM, Burgersdijk RCW, König KG, Schaeken MJM, Truin GJ: Performance of some diagnostic systems in examinations for small occlusal carious lesions. *Caries Res* 1992;26:59–64.
- Verdonschot EH, Wenzel A, Bronkhorst EM: Assessment of diagnostic accuracy in caries detection: An analysis of two methods. *Community Dent Oral Epidemiol* 1993a;21:203–208.
- Verdonschot EH, Wenzel A, Truin GJ, König KG: Performance of electrical resistance measurements adjunct to visual inspection in the early diagnosis of occlusal caries. *J Dent* 1993b;21:332–337.
- Weerheijm KL, van Amerongen WE, Eggink CO: The clinical diagnosis of occlusal caries: A problem. *J Dent Res* 1989;56:196–200.
- Weerheijm KL, Groen HJ, Bast AJJ, Kieft JA, Eijkman MAJ, van Amerongen WE: Clinically undetected occlusal dentine caries: A radiographic comparison. *Caries Res* 1992;26:305–309.
- Wenzel A, Fejerskov O: Validity of diagnosis of questionable caries lesions in occlusal surfaces of extracted third molars. *Caries Res* 1992;26:188–194.
- Wenzel A, Fejerskov O, Kidd E, Joyston-Bechal S, Groeneveld A: Depth of occlusal caries assessed clinically, by conventional film radiographs, and by digitized, processed radiographs. *Caries Res* 1990;24:327–333.
- Wenzel A, Larsen MJ, Fejerskov O: Detection of occlusal caries without cavitation by visual inspection, film radiographs, xeroradiographs, and digitized radiographs. *Caries Res* 1991;25:365–371.
- Wenzel A, Pitts N, Verdonschot EH, Kalsbeek H: Developments in radiographic caries diagnosis. *J Dent* 1993;21:131–140.
- White GE, Ogihara K, Williams DL, Tsamtsouris A: The effect of multiple APF treatments on electrical resistance in situ and in vitro. *J Pedodont* 1981a;6:34–44.
- White GE, Tsamtsouris A, Williams DL: Early detection of occlusal caries by measuring the electrical resistance of the tooth. *J Dent Res* 1978;57:195–200.
- White GE, Tsamtsouris A, Williams DL: A longitudinal study of electronic detection of occlusal caries. *J Pedodont* 1981b;5:91–101.
- Williams DL, Tsamtsouris A, White GE: Electrical resistance correlation with tactile examination on occlusal surfaces. *J Dent Res* 1978;57:31–35.