Radboud Repository

Radboud University Nijmegen

PDF hosted at the Radboud Repository of the Radboud University Nijmegen

The following full text is a publisher's version.

For additional information about this publication click this link.
http://hdl.handle.net/2066/21908

Please be advised that this information was generated on 2017-12-05 and may be subject to change.

Int. J. Oral Maxillofac. Surg. 1995; 24: 344–347
Printed in Denmark . All rights reserved

Copyright © Munksgaard 1995

International Journal of
Oral & Maxillofacial Surgery
ISSN 0901-5027

Effectiveness of primary correction of traumatic telecanthus

Matthias A. W. Merkx[1], Hans Peter M. Freihofer[1], Wilfred A. Borstlap[1], Martin A. van 't Hoff[2]
Departments of [1]Oral and Maxillofacial Surgery and [2]Medical Statistics, University Hospital St Radboud, Nijmegen, The Netherlands

M. A. W. Merkx, H. P. M. Freihofer, W. A. Borstlap, M. A. van 't Hoff: Effectiveness of primary correction of traumatic telecanthus. Int. J. Oral Maxillofac. Surg. 1995; 24: 344–347. © Munksgaard, 1995

Abstract. To assess the aesthetic and functional results of primary treatment of telecanthus in patients with naso-orbito-ethmoidal fractures, the results in 36 patients were evaluated in a retrospective study. Twenty had double-sided telecanthus: 13 required an indirect technique of canthopexy and seven a direct technique. Sixteen had unilateral telecanthus, of whom six were treated by the indirect and 10 by the direct technique. The intercanthal distance (ICD) was measured directly postoperatively and more than 12 months after reconstruction. The late ICD after application of the direct technique was nearly 3 mm smaller (ANOVA, $P \leq 0.02$, mean 34.3 mm) and yielded 2 mm less relapse (ANOVA, $P \leq 0.02$) as compared with the indirect technique. Delayed or late-primary treatment showed a significantly higher frequency of epiphora (chi-square test, $P \leq 0.05$). Early primary treatment of traumatic telecanthus produced the best aesthetic and functional result.

Key words: traumatic canthal dystopia; canthopexy; telecanthus; epiphora.

Accepted for publication 15 June 1995

In frontobasal or naso-orbito-ethmoidal (NOE) trauma, the base of the nose may be wedged between the orbits or the nasal skeleton may be shattered so that telecanthus occurs. This type of traumatic telecanthus in NOE fractures may be corrected in two ways. If the canthal ligament is still fixed to a piece of bone of reasonable size, the intercanthal distance may be restored by fixing this fragment by using a three-dimensional microplate or wire ligature[1,5,17]. This is called "indirect canthopexy" (Fig. 1). If the piece of bone holding the canthal ligament is too small for fixation or if it has been torn loose from the bone completely, a "direct canthopexy" may be carried out[1,6,7,17]: the ligament is fixed with a transnasal 0.2-mm stainless-steel wire to the opposite medial orbital wall. In cases of bilateral displacement, the two canthal ligaments are wired transnasally (Fig. 2).

Many authors have discussed the functional and aesthetic results of either technique[5,7,11,12,18,19]. The purpose of this retrospective study was to compare the results of the direct with the indirect technique, and early primary with late primary reconstruction.

Material and methods

At the Department of Oral and Maxillofacial Surgery, data were available for assessment of 36 patients treated primarily for NOE fractures with traumatic telecanthus during the years 1982–91. Sixteen patients had one-sided telecanthus. Six received indirect canthopexy, whereas 10 patients were treated with direct canthopexy. Twenty patients had double-sided telecanthus: 13 cases required indirect reconstruction and seven cases received direct reconstruction (Table 1).

Twenty-four patients received early primary treatment, whereas 12 received late primary treatment (more than 14 days after trauma). Secondary treatment subsequent to unsatisfactory primary treatment was not included in this retrospective evaluation but is described elsewhere[9,10].

For all these patients, the immediate postoperative and late postoperative transverse intercanthal distances (ICD) were measured with a pair of calipers. This was achieved by placing the legs of the calipers on the medial canthi so that the distance could be read with a precision of 0.5 mm. Duplicate measurements showed that the measurement error was not higher than 0.5 mm. Since the direct postoperative vertical canthal discrepancies were not completely recorded, the data were insufficient to permit an assessment.

The resulting ICD was assessed in relation to the type of injury (unilateral versus bilateral fracture), fixation technique, and the time interval between injury and repair by using a three-way analysis of variance (ANOVA). As a measure of the postoperative stability, i.e., the relapse, the three-way ANOVA could be utilized (fixation technique, type of injury, time interval injury to repair). The

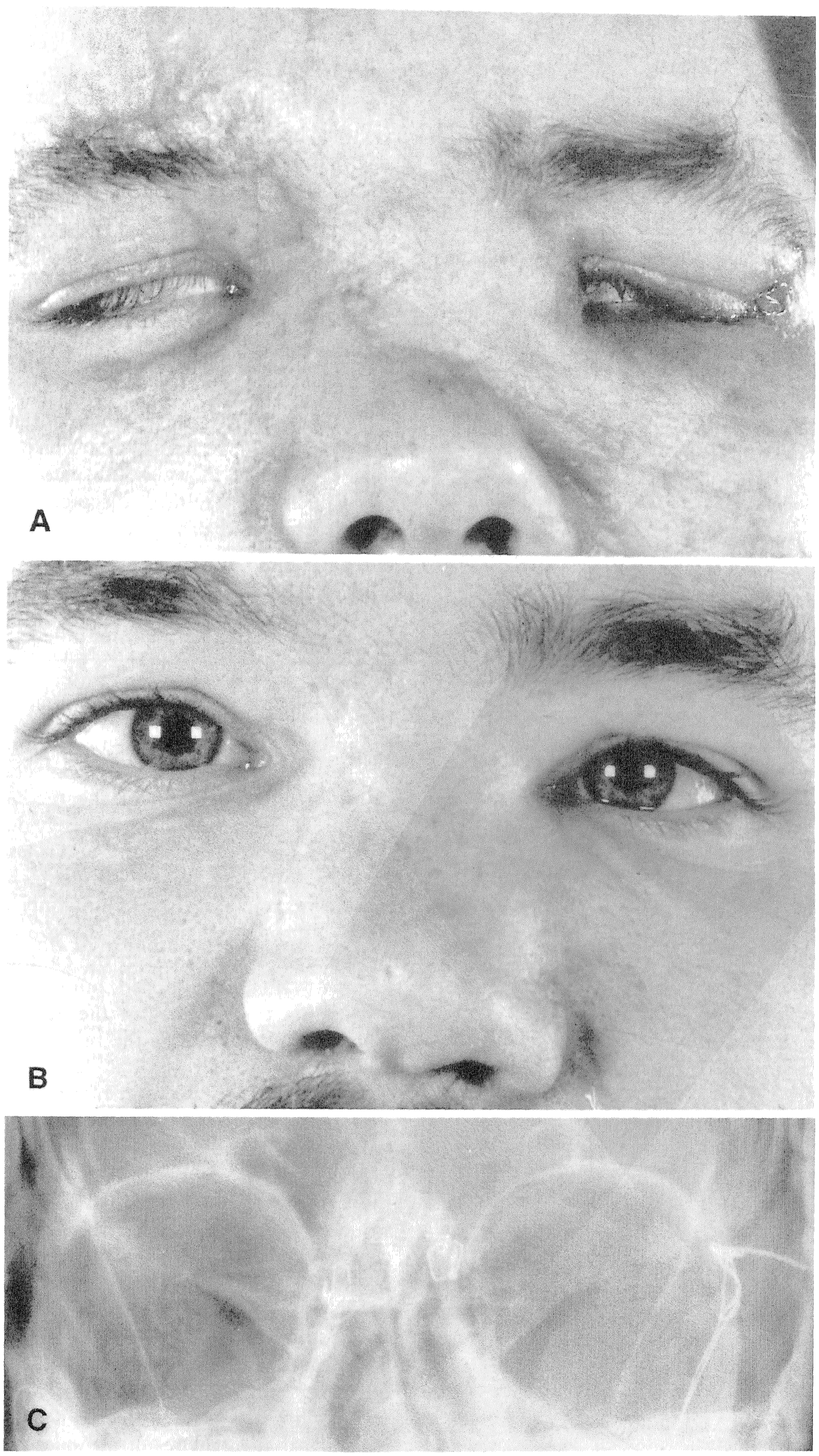

Fig. 1. Late primary case of bilateral telecanthus. A) Patient view before reconstruction; B) patient view 1 year after reconstruction; C) radiograph after reconstruction with indirect technique.

method used for approaching the fractures in "direct-canthopexy-cases" (17 patients) was via a coronal incision ("retrograde indirect approach") or via an approach through wounds or additional incisions over the bridge of the nose. This was also examined by applying a three-way analysis of variance (fracture approach, type of injury, and time interval injury to repair). The relation between the time interval injury to repair and disturbed lacrimal drainage resulting in epiphora or dacryocystitis was also taken into consideration.

Results

When the direct fixation technique was applied, the average resulting late ICD (mean 31.3 mm) was 3.0 mm smaller (ANOVA, $P<0.02$) than that of the indirect technique (Table 2). In cases of one-sided telecanthus, the treatment resulted in a mean ICD of 34.4 mm, which, on average, was 2.7 mm smaller than for patients with a bilateral telecanthus (mean 37.1 mm; ANOVA, $P=0.02$). No significant statistical differences in ICD could be demonstrated in relation to the time interval injury to repair (ANOVA, $P=0.18$).

Direct canthopexy yielded a relapse of 1.9 mm, which was 2.1 mm less than with the indirect technique (ANOVA, $P<0.02$; Table 2). No significant differences in relapse were found for unilateral (mean 2.3 mm) versus bilateral (mean 3.5 mm) telecanthus (ANOVA, $P=0.13$) or for early primary (mean 2.6 mm) versus late primary (mean 3.8 mm) treatment (ANOVA, $P=0.17$). The way of approach did not affect the resulting ICD (ANOVA, $P=0.66$) or the amount of relapse (ANOVA, $P=0.98$).

Epiphora or dacryocystitis was found in two of the 24 patients (8%) who received early primary treatment and five of the 12 patients (42%) who received late primary treatment (Table 3). Fisher's exact test demonstrated a significantly higher frequency of epiphora (chi-square test, $P<0.05$) in late primary treatment. No relationship was found between the unilateral and bilateral cases or with the method of fixation (chi-square test, $P<0.05$).

Discussion

NOE fractures are frequently part of more extensive fractures of the face and cranium. Several publications have examined various aspects of the complexity of the treatment[4,7,9,10,14,15]. Gruss et al.[11] recommend immediate treatment of fractures in the NOE region. This is called "early primary" reconstruction. By 10–14 days after injury, it becomes increasingly more difficult to reconstruct the fractures[11,12]. If treatment is performed about 2 weeks or later after injury, it is called "late primary" reconstruction.

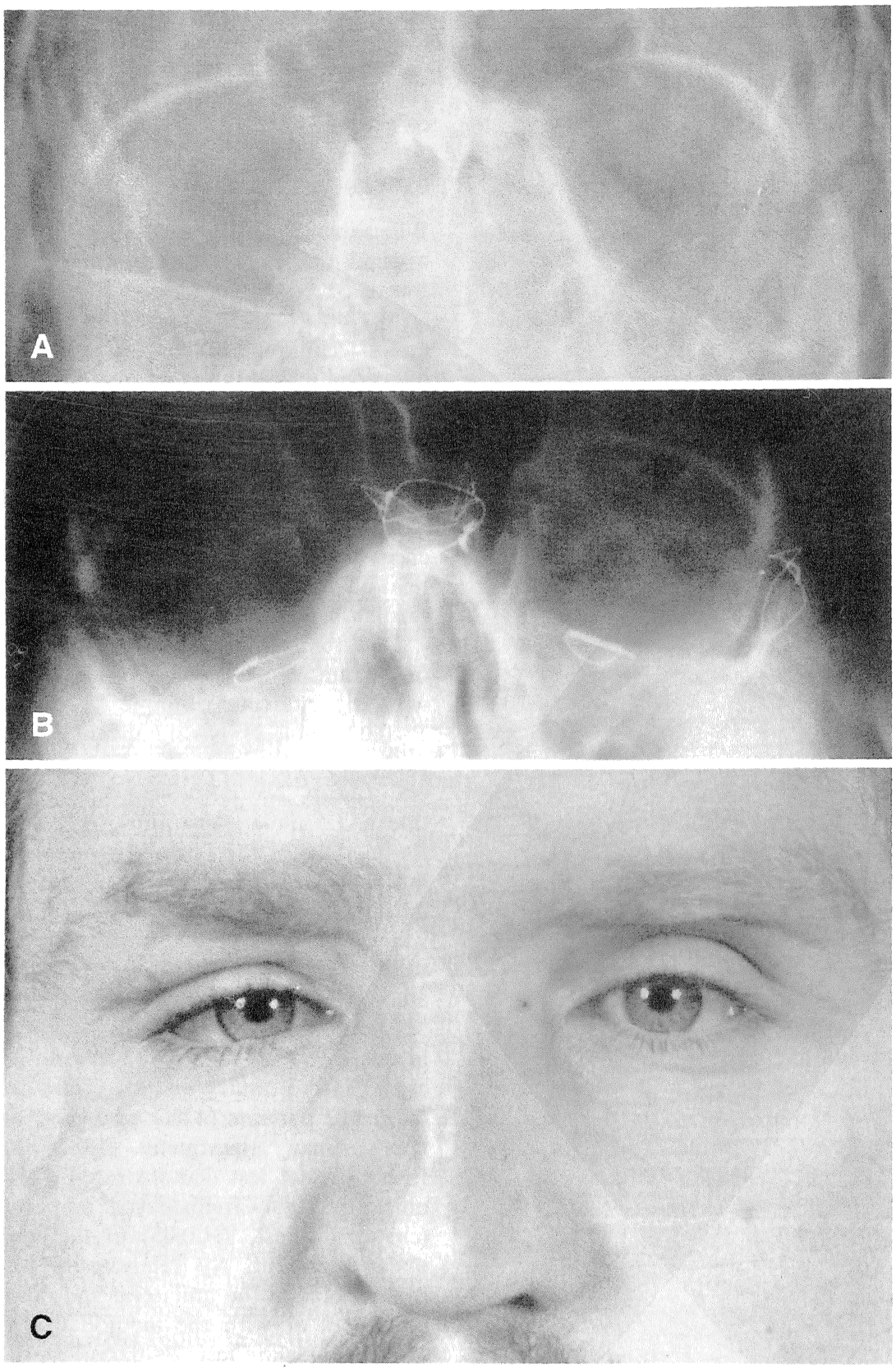

Fig. 2. Early primary case of bilateral telecanthus. A) Radiograph after trauma: note bilateral displacement of medial orbital walls; B) radiograph after reconstruction by direct technique; C) patient view 1 year after reconstruction.

Table 1. Subjects

Technique applied	Frequency	%	Time of reconstruction: Early primary	Time of reconstruction: Late primary
One-sided indirect	6	16.7	4	2
One-sided direct	10	27.8	5	5
Double-sided indirect	13	36.1	11	2
Double-sided direct	7	19.4	4	3

Obviously, any statistical assessment of our data will be subject to "confounding": the method and the time of treatment will closely depend on the extent and seriousness of the trauma.

Our data show that the average intercanthal distance after correction of unilateral telecanthus is 2.7 mm smaller than after correction of bilateral cases. This confirms that the result of one-sided canthopexy cannot be compared with that of double-sided canthopexy because the contralateral side will be used as a means for control and fixation in cases of unilateral canthopexy.

Ellis[5] argues that the intercanthal distance should be half of the interpupillary distance. However, if there are extensive facial fractures, displacement of the orbits and orbital contents may have disturbed those proportions, precluding the use of this parameter. It is probably better to use standard values, which vary from 28 to 35 mm independently of age and sex[8,13,16].

Compared with indirect canthopexy, the result of direct canthopexy showed the intercanthal distance to be 3.0 mm smaller, while also less relapse was seen (2.1 mm). The position of the medial canthus is apparently more precisely determined with direct fixation[6] and is less sensitive to relapse. When indirect techniques are applied, there is not only a possibility of miscalculating the size of the piece of bone to which the canthal ligament remained attached, but also of misjudging the firmness of the attachment of the ligament to the bone fragment.

Whenever direct fixation of the canthal ligament is necessary, a "direct" or "open sky approach" of the naso-orbital region[1] may be used to identify the canthal ligament through existing wounds, or through a W-shaped incision over the lateral wall of the nose[2,3]. However, a "retrograde approach" via a coronal incision with a transconjunctival incision is used in most cases. This appears to make no difference for the final result. Thus there is no reason to justify additional incisions that might result in unaesthetic scars[5].

The anatomic relationship of the medial canthal ligament and periosteum usually protects the lacrimal sac against trauma. In his description of 25 cases of NOE fractures, Stranc[19] did not see a single case in which "the upper lacrimal pathways" were damaged. Obstruction of the drainage system in cases

Table 2. Variance of late intercanthal distance and relapse

	Late intercanthal distance Grand mean 35.91 mm		Relapse Grand mean 3.01 mm	
	Adjusted for independent deviation	ANOVA *P* value	Adjusted for independent deviation	ANOVA *P* value
Indirect fixation technique	+1.41 mm	0.013	+1.00 mm	0.012
Direct fixation technique	−1.57 mm		−1.11 mm	
Unilateral telecanthus	−1.51 mm	0.021	−0.69 mm	0.124
Bilateral telecanthus	+1.20 mm		+0.55 mm	
Primary treatment	−0.54 mm	0.179	−0.39 mm	0.168
Late-primary treatment	+1.08 mm		+0.78 mm	

Table 3. Relation between time interval injury to repair and epiphora

Primary reconstruction	Late primary or secondary
None	Direct left plus DCRS left
None	Direct left plus LRS left
None	Direct right plus DCRS right
None	Direct dbs. plus DCRS right
None	Direct dbs. plus DCRS left
Indirect dbs	Direct left plus DCRS left
Indirect dbs	No second intervention

Primary reconstruction: 0–14 days after injury; late primary reconstruction: >14 days after injury; indirect: indirect canthopexy; direct: direct canthopexy (right, left or both sides); DCRS: dacryocystorhinostomy; LRS: lacorhinostomy; dbs: double-sided.

treated with closed reduction and "compression" lead plates with transnasal wires occur in the area of the osseous nasolacrimal duct, as STRANC[19] was able to confirm in 10 out of 25 patients by using dacryocystorhinograms: five of them (20%) presented with complaints of epiphora or dacryocystitis.

In our group, seven patients (19%) complained of unilateral epiphora or dacryocystitis. Notably, five of them did not receive early primary treatment of their NOE fractures (Table 3). In the other two cases, the early primary bilateral indirect canthopexy relapsed. Six of these patients underwent a second operation and were treated by direct canthopexy – in five cases combined with dacryocystorhinostomy (DCRS) and in one case combined with lacorhinostomy (LRS). From our results, it can be concluded that careful early primary reconstruction may prevent post-traumatic epiphora (chi-square test, $P \leq 0.05$). This is in agreement with the results reported in the literature[5,11,19]. MARKOWITZ et al.[18] pointed out that only 5% of their group of primarily treated NOE fractures needed a DCRS. Apart from damage to the canaliculi, we did not find any indication to include the lacrimal drainage pathways in the early primary treatment.

Traumatic telecanthus should receive early primary treatment. This will produce the best possible results, both aesthetically and functionally. However, this requires adequate diagnosis and thus the decision to apply either a direct or indirect technique. In case of doubt, the direct technique should be used. One should try to achieve overcorrection of approximately 2 mm when using a direct technique and 4 mm when using the indirect technique. If early primary treatment fails to achieve adequate reduction of the intercanthal distance, the risk of epiphora will increase.

References

1. BOWERMAN JE. Fractures of the middle third of the facial skeleton. In: ROWE N, WILLIAMS J, eds.: Maxillofacial injuries. 3rd ed. Edinburgh: Livingstone, 1985: 363–434.
2. CONVERSE JM, HOGAN MV. Open sky approach for reduction of naso-orbital fractures. Plast Reconstr Surg 1970: **46**: 396–8.
3. CRUSE CW, BLEVERS PK, LUCE EA. Naso-ethmoid-orbital fractures. J Trauma 1980: **20**: 551–6.
4. VAN DAMME PA, FREIHOFER HPM. Disturbance of smell and taste after high central midface fractures. J Cranio-Max-Fac Surg 1992: **20**: 248–50.
5. ELLIS E. Sequencing treatment for naso-orbito-ethmoid fractures. J Oral Maxillofac Surg 1993: **51**: 543–58.
6. FIRMIN F. La canthopexie transnasale. Medical thesis, Faculté de Médecine Cochin – Port Royal, Paris, 1972.
7. FREIHOFER HPM. Experience with transnasal canthopexy. J Max-Fac Surg 1980: **8**: 119–24.
8. FREIHOFER HPM. Inner intercanthal and interorbital distances. J Max-Fac Surg 1980: **8**: 324–6.
9. FREIHOFER HPM. Effectiveness of secondary periorbital reconstruction. J Cranio-Max-Fac Surg 1995: **23**: 143–50.
10. FREIHOFER HPM, VAN DAMME PA. Secondary post-traumatic periorbital surgery. Incidence and results. J Cranio-Max-Fac Surg 1987: **15**: 183–7.
11. GRUSS JS, HURWITZ JJ, NIK NA, KASSEL EE. The pattern and incidence of lacrimal injury in naso-orbital-ethmoid fractures: the role of delayed assessment and dacryocystorhinostomy. Br J Plast Surg 1985: **38**: 116–21.
12. GRUSS JS, PHILLIPS JH. Complex facial trauma: the evolving role of rigid fixation and immediate bone grafting reconstruction. Clin Plast Surg 1989: **16**: 93–104.
13. GÜNTHER G. Konstitutionelle Anomalien des Augenabstands und der Interorbitalbreite. Virchows Arch A Pathol Anat Histopathol 1933: **290**: 373–9.
14. IOANNIDES CH, FREIHOFER HPM, BRUASET I. Trauma of the upper third of the face. Management and follow-up. J Max-Fac Surg 1984: **12**: 255–61.
15. IOANNIDES CH, FREIHOFER HPM, VRIENS J. Fractures of the frontal sinus: a rationale of treatment. Br J Plast Surg 1993: **46**: 208–14.
16. LAESTADIUS BA, AASE JM, SMITH DW. Normal inner canthal and outer orbital dimensions. J Pediatr 1969: **74**: 465–8.
17. LEIPZIGER LS, MANSON PN. Nasoethmoid orbital fractures: current concepts and management principles. Clin Plast Surg 1992: **19**: 167–93.
18. MARKOWITZ BL, MANSON PN, SARGENT L, et al. Management of the medial canthal tendon in the nasoethmoid orbital fractures: the importance of the central fragment in classification and treatment. Plast Reconstr Surg 1991: **87**: 843–53.
19. STRANC MF. The pattern of lacrimal injuries in naso-ethmoid fractures. Br J Plast Surg 1970: **23**: 339–46.

Address:
M. A. W. Merkx, MD, DMD
University Hospital Nijmegen
Department of Oral and Maxillofacial Surgery
PO Box 9101
NL 6500 HB Nijmegen
The Netherlands