

PDF hosted at the Radboud Repository of the Radboud University Nijmegen

The following full text is a publisher's version.

For additional information about this publication click this link.

<http://hdl.handle.net/2066/21782>

Please be advised that this information was generated on 2017-12-05 and may be subject to change.

A SINGLE, MIDLINE, EXTRAPERITONEAL INCISION FOR INTERNAL FIXATION OF TYPE C UNSTABLE PELVIC RING FRACTURES

R. Jan A. Goris, M.D., PH.D., and Jan Biert, M.D.

OSTEOSYNTHESIS of type C pelvic ring fractures are considered to be among the most difficult operations in trauma surgery. Huge shearing and compression forces lead to dislocation of large fragments, and repositioning can be very cumbersome. Concomitant acetabular fractures only make things more difficult*. Often a combination of incisions is necessary for adequate exposure. During these combined approaches, the patient must be turned on the operating table, which is time consuming and impractical. The repositioning of one fracture fragment can be impossible as long as the other fracture fragments of the pelvic ring have not been reduced, but also if these already have been operatively stabilized through another incision. Also, there may be a contraindication to lateral positioning because of multiple rib fractures or unstable extremity or spine fractures. Meanwhile, considerable blood loss from the pelvic fractures, especially during the operation, requires a swift and short procedure. In this article a novel technique is presented: the approach to almost the complete pelvic ring by a single, extraperitoneal, midline abdominal incision, which helps to overcome most of the aforementioned problems.

METHODS

The patient is positioned in the supine position with the hips and knees slightly flexed to relax the psoas muscles. A midline incision is made from a point distal from the symphysis to a few centimeters proximal of the umbilicus. The anterior rectus sheath is opened in the midline, carefully avoiding the opening of the peritoneal sac. The rectus abdominis muscles are pulled laterally. The posterior rectus sheath must be incised as far laterally as possible, on both sides (Fig. 1). Now the peritoneal sac can be pulled

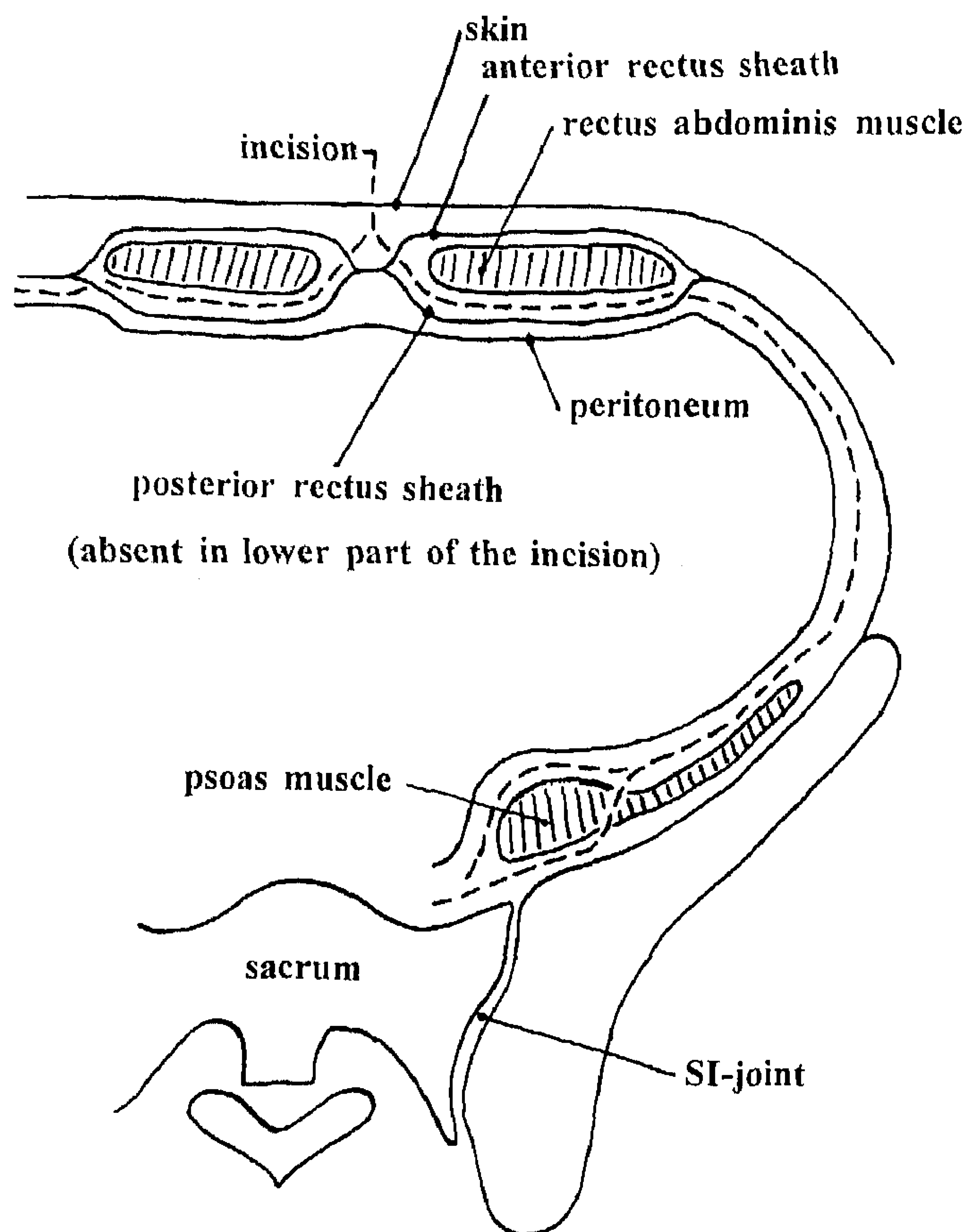


FIG. 1. The posterior rectus sheath is incised as far laterally as possible. The peritoneal sac remains intact. Approach of both sacroiliac joints and sacrum is possible. SI, Sacroiliac.

upward and medially to expose the inner surface of the pelvis. Several structures must be identified as in the ilio-inguinal incision: femoral arteries and veins are isolated in their common sheath, and spermatic cords are localized. The psoas and iliacus muscles must be mobilized together with the femoral nerve and held in a rubber sling. Both sacroiliac (SI) joints are exposed, as well as the pelvic side of the sacrum.

After obtaining exposure of all fragments, internal fixation of the sacroiliac area(s) is done first. After this, working from posterior to anterior, the other fracture fragments are stabilized.

Accepted for publication February 9, 1995.
From the Department of Surgery, University Hospital Nijmegen, The Netherlands.
Correspondence address: Dr. J. Biert, P. O. Box 9101, 6500 HB, Nijmegen, The Netherlands.

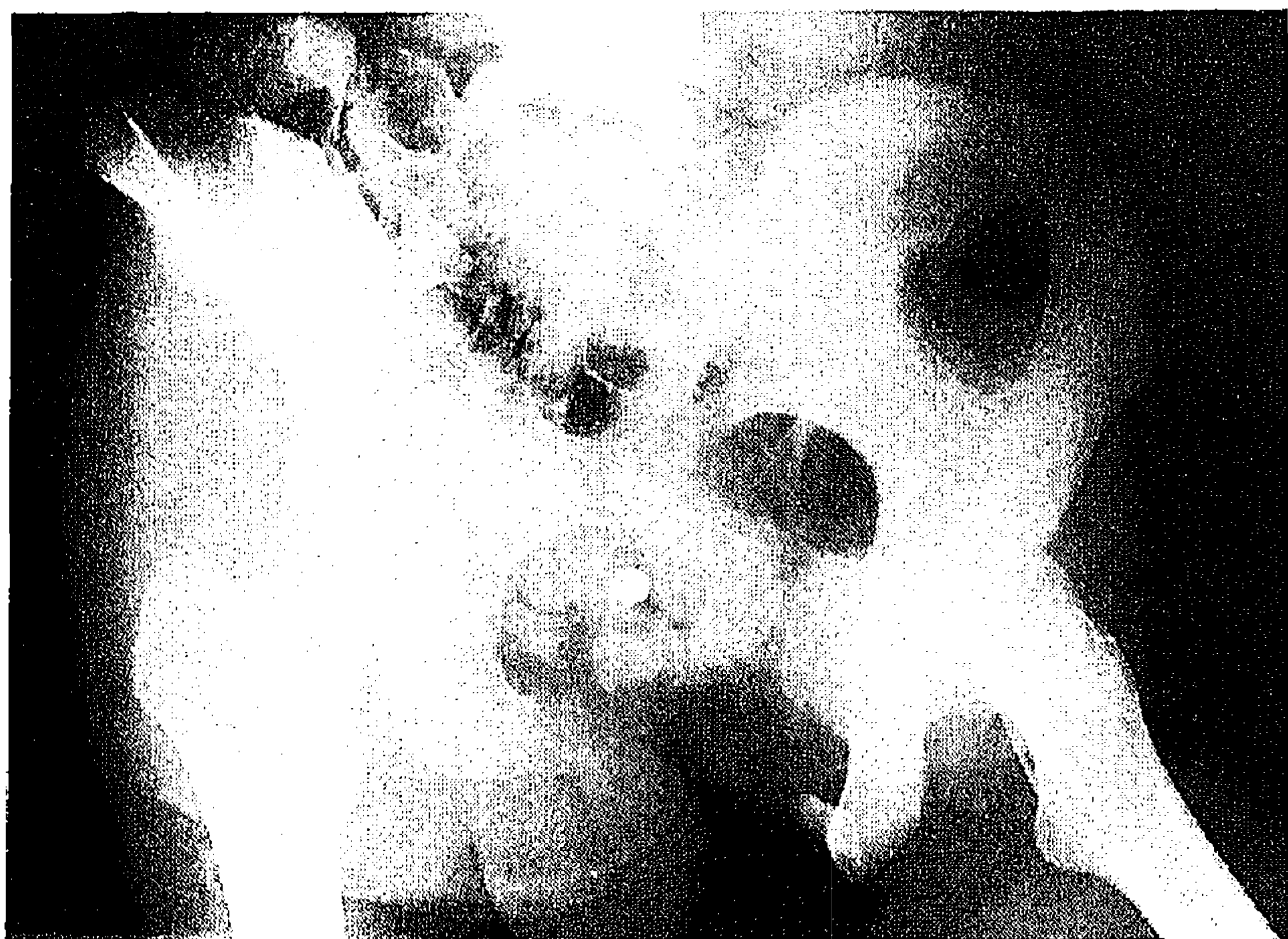

FIG. 2

FIG. 2. Female, 15-years of age. Severe pelvic crush after being run over by a truck. Pelvic ring fracture type C2.

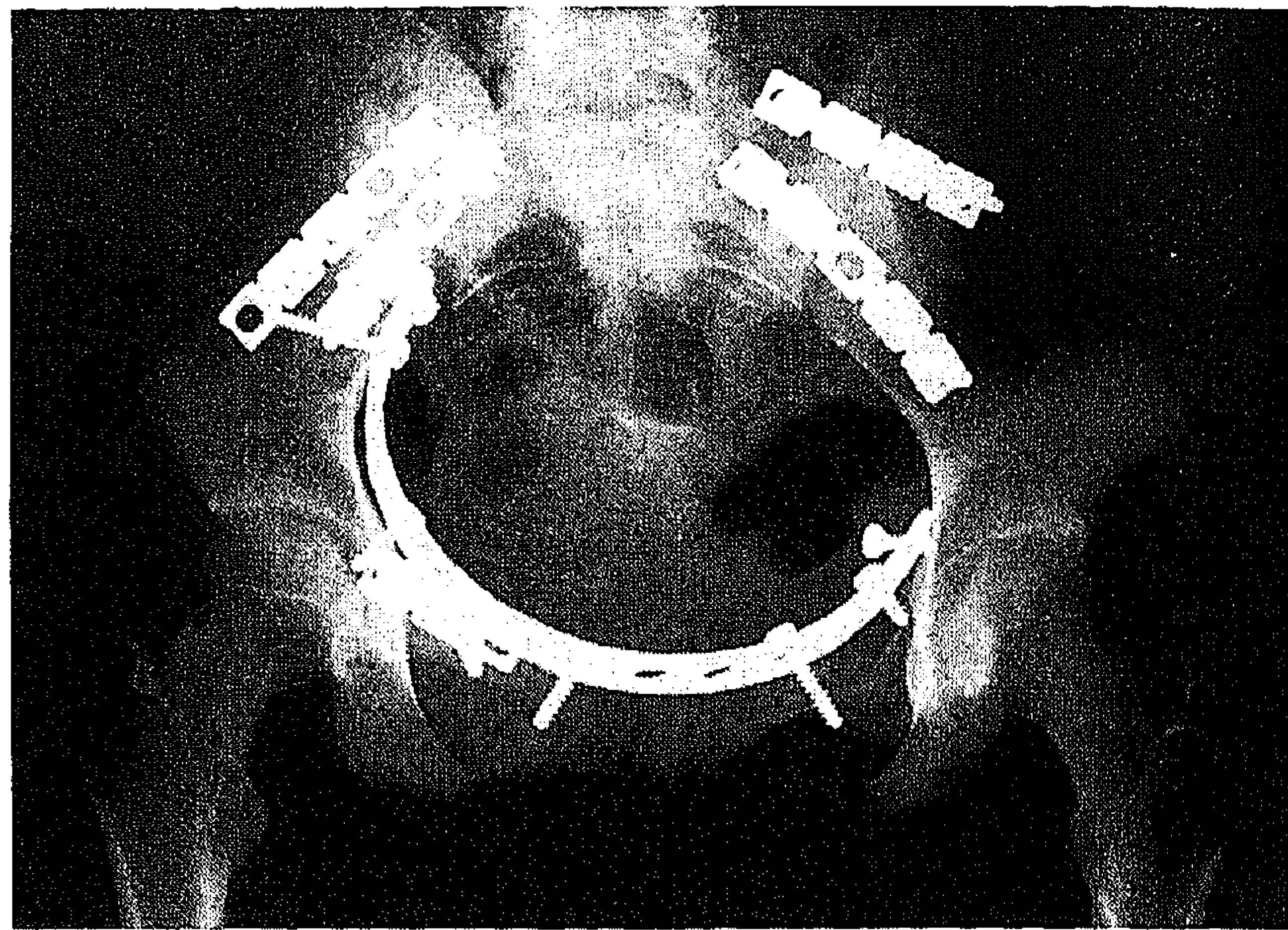


FIG. 3

FIG. 3. Approach through a midline extraperitoneal incision. First two plates for the sacroiliac (SI) joint on the left side. Temporary fixation of SI joint on the right side. Plate fixation of the pubic bone right side. Large pelvic reconstruction plate (Roman arch type), only a few screws are necessary. Definitive fixation SI joint right side.

For reconstruction and stabilization of the fractures, reconstruction plates and screws are utilized. On the anterior side of the pelvis, these plates should be as large as possible, bridging as many fractures as possible along the innominate line. In this way, maximal stability is obtained, according to the principle of the ancient Roman arch (Figs. 2 and 3). The plate must be bent with a slightly larger radius than the pelvic ring, so that the fracture fragments are pushed outward slightly, due to the spring effect. Only a few screws are needed to obtain optimal stability. Sometimes it is necessary to insert small plates, which provide additional reposition and stabilization. Care must be taken to avoid inserting screws through the sacral foramina and nerves, and the hip joint. In some cases, maximal stability can only be obtained by an additional external fixator.

We used this incision as a single operative ex-

posure for stabilizing type C pelvic ring fractures. It allows access to the symphysis pubis, and bilaterally to the superior rami pubis, the innominate line with the anterior column of the acetabulum, the iliac wings, the SI joints, and the anterior surface of the sacrum. Even plating of a sacral fracture proved possible. Also, reconstruction of the anterior column in acetabular fractures is possible.

The advantages of a single exposure are obvious: there is no need to turn the patient, and operative time is considerably reduced. Another advantage is that the lateral femoral cutaneous nerve is not as much in danger as in the ilio-inguinal incision.

REFERENCE

*Letournel, E., and Judet, R. Surgical approaches to the acetabulum. In: *Fractures of the Acetabulum*. 2nd ed., pp. 363-395. Berlin: Springer-Verlag, 1992.