

## PDF hosted at the Radboud Repository of the Radboud University Nijmegen

The following full text is a publisher's version.

For additional information about this publication click this link.

<http://hdl.handle.net/2066/21463>

Please be advised that this information was generated on 2017-12-05 and may be subject to change.



## Variant of Odontoonychodermal Dysplasia?

W.P. Arnold, M.A.W. Merkx, and P.M. Steijlen

Departments of Dermatology (W.P.A., P.M.S.), and Oral and Maxillofacial Surgery (M.A.W.M.),  
University Hospital Nijmegen, Nijmegen, The Netherlands

In this case report we describe a patient with all the manifestations seen in the odontoonychodermal dysplasia syndrome, except for the shape of teeth and mild mental deficiency.

© 1995 Wiley-Liss, Inc.

**KEY WORDS:** hydrotic ectodermal dysplasia, palmoplantar hyperkeratosis, odontoonychodermal dysplasia syndrome

### INTRODUCTION

Fadhil et al. [1983] presented in this journal 7 individuals from a total of 24 belonging to 3 inbred Lebanese sibships affected with hyperhidrotic, transgradient palmar and plantar hyperkeratosis, deciduous teeth persisting during adulthood, dry and sparse hair, dystrophic nails, and a mild erythema over the cheeks and nose. They called the condition "odontoonychodermal dysplasia." The pedigree was consistent with autosomal-recessive transmission. To the best of our knowledge, no other patients affected with this condition have been reported.

Here we describe an individual born to nonconsanguineous parents, who had findings very similar to those described above, as well as mild mental deficiency.

### CLINICAL REPORT

A 31-year-old man had had skin problems since early childhood. He complained of progressive thickening of palmar skin, with painful chapping and increased sweating in these areas. These symptoms inhibited his great passion: playing the accordion. He lived in a so-called "Family Replacing Home" due to mild mental retardation. His general health status was good, but he was treated with carbamazepine, prescribed after a single epileptic episode he had suffered 15 years ago. His Dutch parents were nonconsanguineous, and his parents, the parents of his father, and his two brothers

Received for publication September 24, 1994; revision received April 5, 1995.

Address reprint requests to W.P. Arnold, M.D., Ph.D., University Hospital Nijmegen, 802 Department of Dermatology, P.O. Box 9101, 6500 HB Nijmegen, The Netherlands.

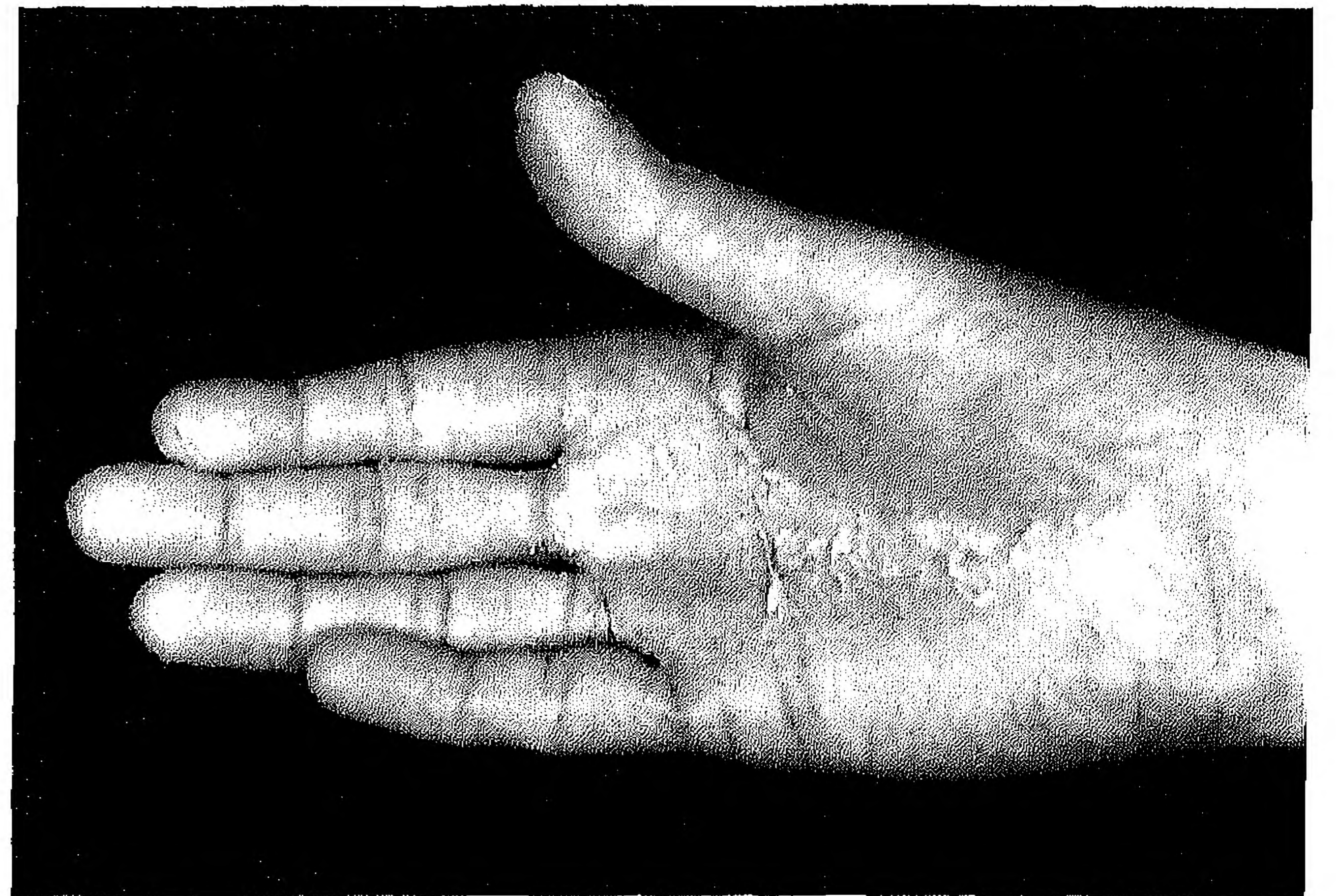

Fig. 1. Palmar erythematousquamous plaques with a relatively sharp boundary.

and one sister as well, appeared to have normal intelligence, without abnormalities of skin and dentition. No data were available regarding the parents of his mother.

Examination showed mild palmoplantar erythematousquamous plaques with a relatively sharp boundary, extending to the dorsal aspects (Figs. 1, 2), with severely dystrophic nails. The palms were severely chapped, and both palms and soles were very clammy.

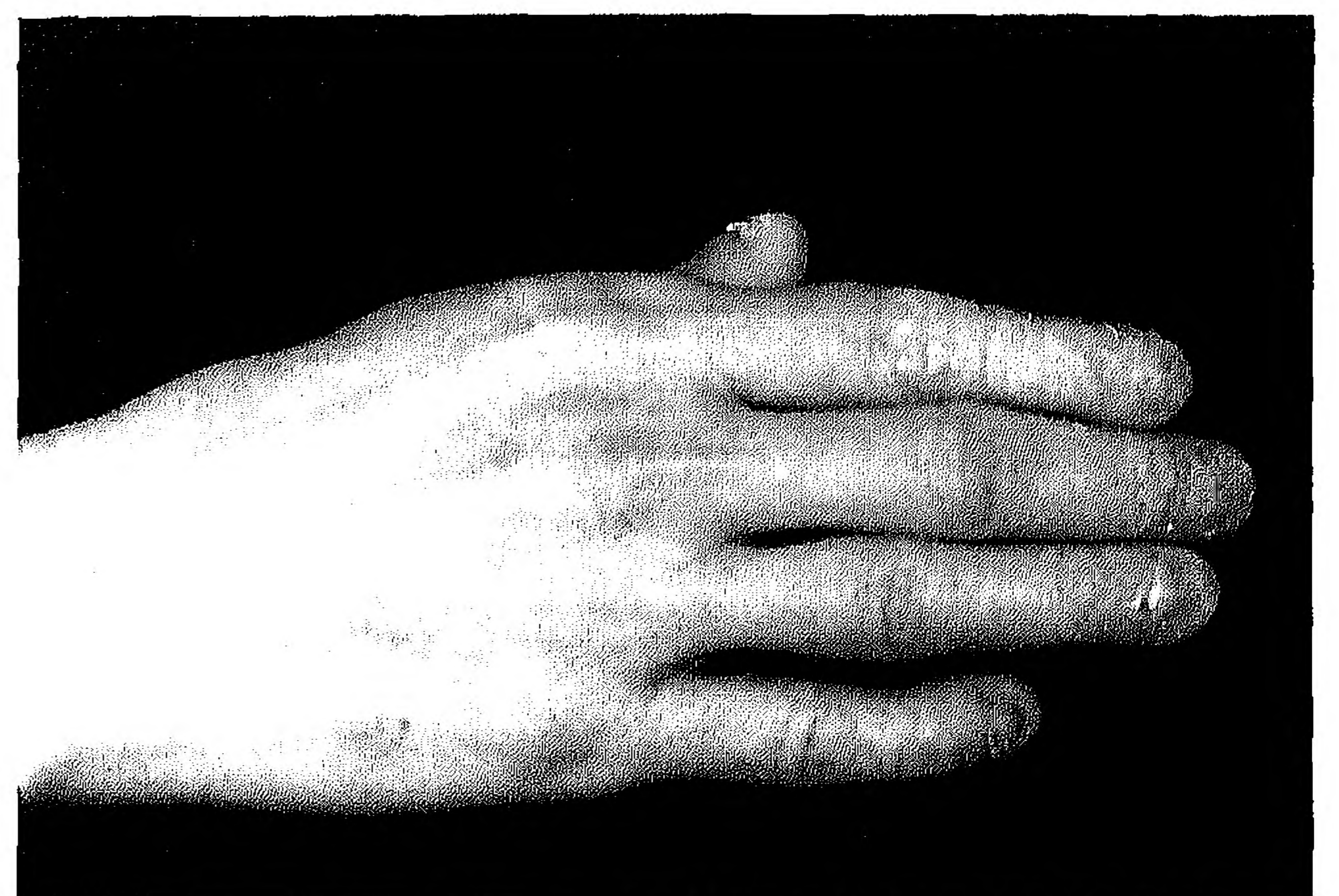

Fig. 2. Erythematousquamous plaques extending to the dorsal aspects, with severely dystrophic nails.



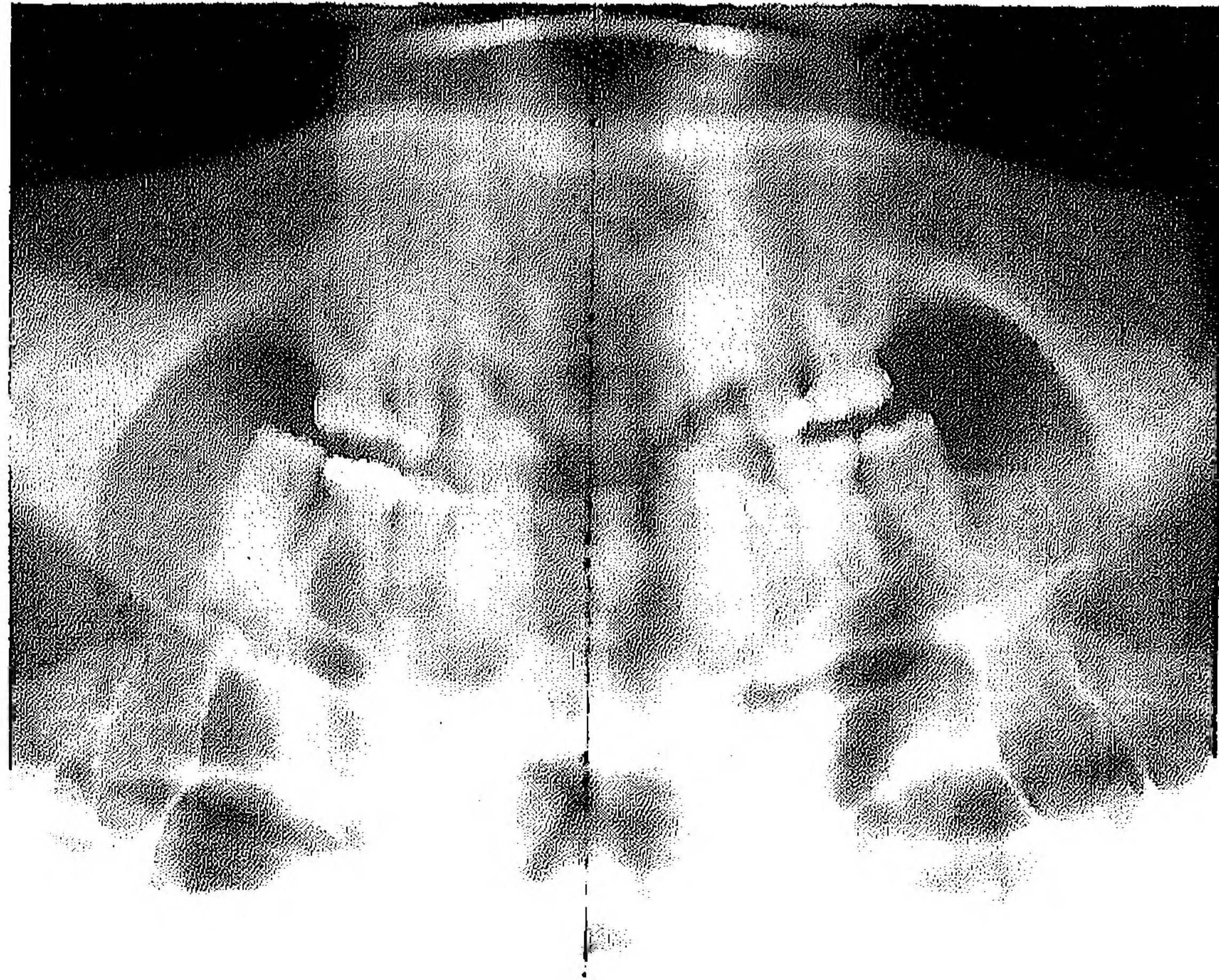


Fig. 5. Panorex film of the jaws.

laxity of the dermis, which showed a tendency to increase around sweat glands (Fig. 6). Roentgenographic examination of the skull showed normal adult bone structures; intracranial calcifications were absent. G-banded chromosomes from cultured lymphocytes were

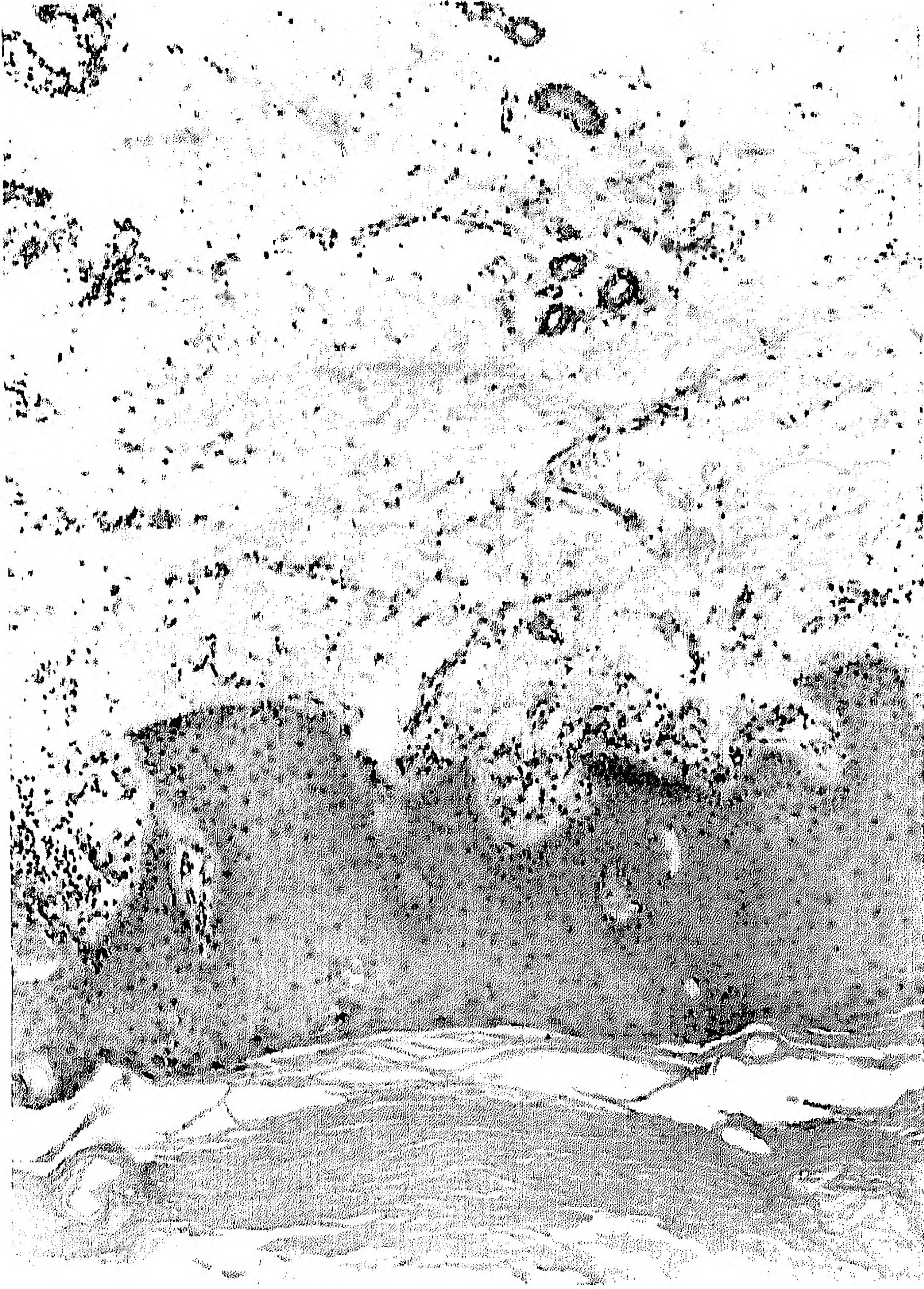


Fig. 6. Histology of palmar biopsy (Hematoxylin & Eosin staining).

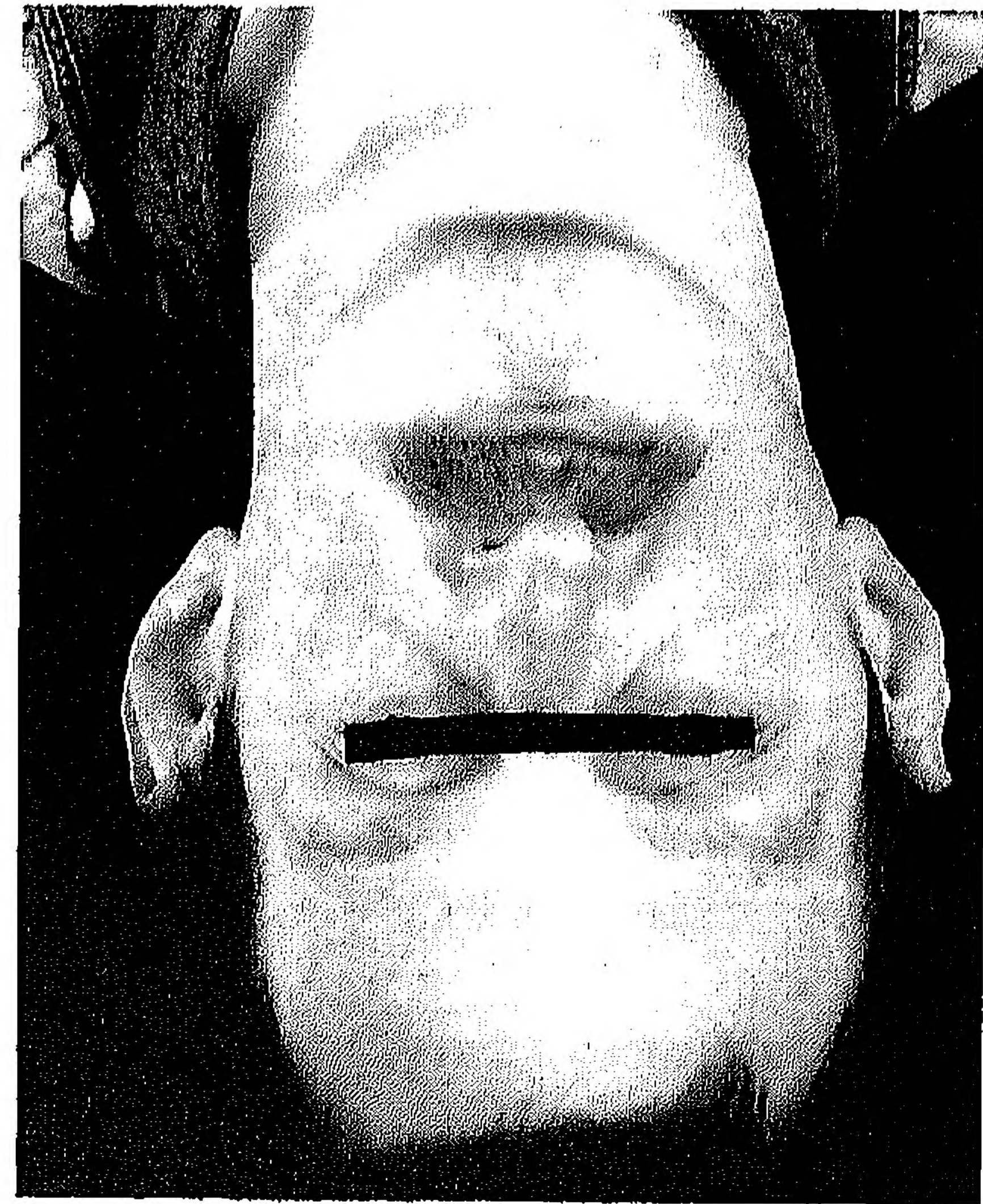


Fig. 3. Sparse eyebrows and eyelashes with atrophy, erythema, and telangiectasia of the skin of the nose and cheeks.

Scalp hair was dry, sparse, thin, and blond to faintly brownish. Eyebrows and eyelashes were sparse. The skin of the nose and cheeks manifested atrophy, erythema with fine scaling, and telangiectasia, compatible with solar elastosis or ultraviolet radiation-induced changes. In general, the patient suffered from dry, scaly skin. Intraoral examination showed hypodontia of the permanent dentition; the deciduous teeth were still present (Fig. 4). No other physical abnormalities were noticed, nor any hearing problems.

A Panorex film of the jaws (Fig. 5) showed that the deciduous teeth were still in situ, except 74 and 84. Only 16, 26, 34, and 44 of the permanent dentition were present and erupted. The histology of a palmar biopsy showed an acanthotic epidermis with prominent hyperkeratosis, mainly of orthokeratotic but focally of the parakeratotic type. The stratum granulosum did show an alternating breadth. A small, round-nuclear, perivascular infiltrate was visible in the stratum papil-

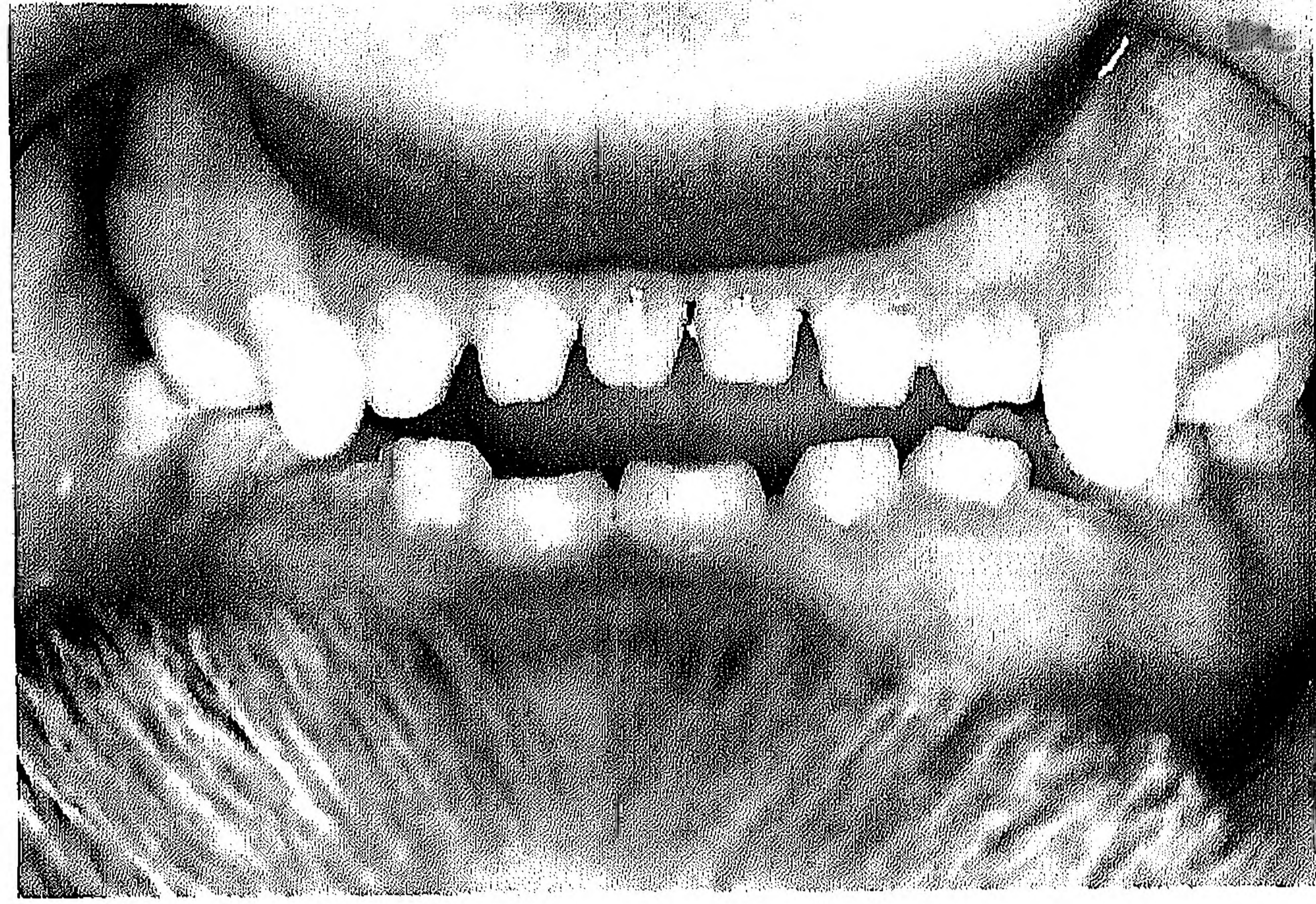

Fig. 4. Hypodontia of the permanent dentition; the deciduous teeth are still present.



normal. Hair shaft light microscopy showed thin hair with relatively varying diameter.

### DISCUSSION

Three forms of hydrotic ectodermal dysplasia with palmoplantar hyperkeratosis and dystrophic nails have been described: "genuine" hydrotic ectodermal dysplasia (Clouston syndrome) [Clouston, 1939], hydrotic ectodermal dysplasia with calcification of basal ganglia (Copeland syndrome) [Copeland et al., 1977], and odontoonychodermal dysplasia syndrome (Fadhil syndrome) [Fadhil et al., 1983]. Clouston syndrome is characterized by an autosomal-dominant mode of inheritance, and the face and teeth are usually normal. Copeland syndrome is characterized by alopecia and intracranial calcifications. Fadhil syndrome, finally, includes most of the manifestations seen in our patient, except for the shape of teeth and mild mental deficiency. The description of Fadhil et al. [1983] of the two peg-shaped permanent maxillary central incisors could not be confirmed because of the absence of these permanent teeth. The deciduous teeth were wide-spaced and had a marked erosion of their occlusal surfaces and incisal edges as described by Fadhil et al. [1983], with hypodontia of the permanent dentition (small 16 and 26, and peg-shaped 34 and 44; Fig. 5). All data are summarized in Table I.

To our knowledge, no additional report has yet appeared in the English language medical literature to confirm odontoonychodermal dysplasia syndrome as a new entity. Pinheiro et al. [1985] described a similar odontoonychodysplasia syndrome, which, however, is characterized by a nonhydrotic ectodermal dysplasia with partial syndactyly, alopecia totalis, and completely developed permanent teeth. We think that our patient is a variant of the condition described by Fadhil et al. [1983], or a new entity, with a possible autosomal-recessive pattern of inheritance. We hope that the present report will increase awareness of the existence of odontoonychodermal dysplasia with variable clinical presentations.

### REFERENCES

- Clouston HR (1939): Major forms of hereditary ectodermal dysplasia. *Can Med Assoc J* 40:1-7.
- Copeland DD, Lamb WA, Klintworth GK (1977): Calcification of basal ganglia and cerebellar roof nuclei in mentally defective patient with hydrotic ectodermal dysplasia. *Neurology* 27:1029-1033.
- Fadhil M, Ghabra TA, Deeb M, Der Kaloustian VM (1983): Odontoonychodermal dysplasia: a previously apparently undescribed ectodermal dysplasia. *Am J Med Genet* 14:335-346.
- Pinheiro M, Freire-Maia N, Gollop TR (1985): Odontoonychodysplasia with alopecia: a new pure ectodermal dysplasia with probable autosomal recessive inheritance. *Am J Med Genet* 20:197-202.

TABLE I. Clinical Signs of Hydrotic Ectodermal Dysplasia Syndromes With Palmoplantar Hyperkeratosis

Syndrome	Mental deficiency	Inheritance	Teeth	Hair	Nails	Other features
Clouston	+/-	AD	Usually normal	Dry, sparse, and thin	Dystrophic	
Copeland	+	AR?	Hypodontia	Alopecia	Dystrophic	Intracranial calcification
Fadhil	-?	AR	Hypodontia, deciduous teeth	Dry and normal to sparse	Dystrophic	"Solar elastosis" and dry skin
Present case	+/-	AR?	As above	Dry, sparse, and thin	Dystrophic	Ulerythema ophryogenes